

ORIGINAL ARTICLE

Histopathological Changes on Wistar Rat Wounds after Topical Application of Fig Leaves Extracts

Intan Nirwana^{1}, Anita Yuliati¹, Asti Meizarini¹, R. Mohammad Yogiartono¹, Hikmah Putri Sary¹,*

Muhammad Yudhistira Rendra Kusuma¹, Muhammad Alviandi Hefni¹

¹Department of Dental Material, Faculty of Dental Medicine, Universitas Airlangga. Jln. Prof. Dr. Moetopo 47 Surabaya Indonesia

Abstract:

Background: The incision in the oral cavity is also taken for gingivectomy. Fig leaves (*Ficus carica Linn*) extract contains compounds of flavonoid, terpenoids and tannins and has anti-inflammatory and antioxidant activities. The important markers of wound healing were fibroblasts, macrophages and collagen density. **Aim and Objectives:** To investigate the topical application of fig leaves extracts on Wistar rat wounds on the number of macrophages, fibroblasts and collagen density after treatment for three and seven days. **Material and Methods:** This research was performed on 24 rats by making incision wounds on the backs of Wistar rats and divided into control and treatment groups. The control groups were left untreated and the treatment groups were given fig leaves extract gel on the incision wound once every day during three and seven days, and then the animals were sacrificed. Wound tissue was removed and fixed in 10% formalin solution for histopathological test. Then it was embedded in paraffin, and stained with Hematoxylin-Eosin to observe fibroblasts and macrophages. The collagen density was observed by Masson's Trichome staining. Statistical analyses of fibroblasts and macrophages were using One-way Anova and Tukeys HSD. Collagen density was analyzed by using Kruskal-Wallis and Mann-Whitney test. **Results:** There were significant differences among the groups ($p < 0.005$) on the number of fibroblasts, macrophages and collagen density after treatment for three and seven days. **Conclusion:** Application of fig

leaves extract on Wistar rat wounds could increase the number of fibroblasts and macrophages but not collagen density in the wound healing process.

Keywords: Fig leaves (*Ficus carica Linn*), wound healing, fibroblasts, macrophages, collagen

Introduction

Wound is a discontinuity of a tissue that can be caused by sharp objects or blunt trauma, changes in temperature, chemicals, explosion, electric shock, animal bites and contact heat [1]. An oral incision is also performed in gingivectomy. Incision wounds were included in the classification of open wounds. This incision can occur intentionally (surgical wound) or accidentally (accidental injury) due to sharp objects. Wounds can be classified in general, namely acute wounds and chronic wounds. Acute wounds are injuries that occur with the normal healing process, such as surgical cuts (incisions), non-surgical (burns) and trauma. Chronic wound is a process of wound healing that has been delayed, such as decubitus ulcer, diabetic wounds [2].

Treatment of wounds generally uses drugs with many chemical ingredients available in the community. Povidone Iodine 10% solution is still widely used because it is suitable for dirty wounds or infected by Gram-positive or Gram-negative bacteria, spores, fungi and protozoa. However,

some reports on povidone iodine 10% have raised concerns over allergy, ineffective penetration, and toxic effects on host cells [3].

Innovation in the use of herbal or traditional medicines is now widely done because it is easier to obtain, economical and has low side effects. One alternative medicinal plant that can be utilized is fig leaves (*Ficus carica* Linn). Fig trees were cultivated in Indonesia, especially in East Java. Fig leaves contain flavonoid compounds, terpenoids and tannins [4]. This compound in tin leaves is known to have biological activity as an antioxidant, anticancer, anti-inflammatory, antiviral, and antibacterial [5].

The study was conducted on Wistar rats (*Rattus norvegicus*) which were given incisions on the vertebralis thoracis as model animals because there was a structural equation of tissue between the skin epithelium and the oral mucosal epithelium in Wistar rats. Overall the healing process of the skin and mucosa has a similar mechanism [6]. The healing process begins immediately after injury and occurs in three phases: inflammation and migration, proliferation, and remodelling and maturation [7].

This study observed the number of macrophages, fibroblasts and collagen density in the wound healing process after treatment for three and seven days, at this time the wound healing process was still in the inflammatory and proliferation phase. The selection of three and seven days was because in previous studies said that macrophages reach seventy-two hours after wounding, and it was necessary to know the pattern of trends in the increase and decrease of macrophages number. Fibroblasts begun to appear for seventy-two hours after wounding and reach a peak on proliferation

phase [8], as well as collagen. One of the inflammatory cells that play a role in the inflammatory process is macrophages. Fibroblast is one component of wound healing in the form of cell that is widely distributed in connective tissue. Fibroblasts produce collagen precursor substance, elastic fibers and reticular fibers. Fibroblasts play a role in the process of fibrosis namely the migration and proliferation of fibroblasts and deposition of extracellular matrix by fibroblasts [9].

Based on the explanation above, it is necessary to examine the administration of fig leaves extract in the wound, because there are no data on histopathological changes on Wistar rat wounds after topical application of fig leaves extracts. The aim of this study was to investigate the topical application of fig leaves extracts on Wistar rat wounds on the number of macrophages, fibroblast and collagen density after treatment once every day during three and seven days.

Material and Methods

Ethical Approval

This research was approved by the Institutional Ethics Committee of the Faculty of Dental Medicine, Universitas Airlangga, Indonesia. Number 242/ HRECC.FODM/X/2017. The following materials were used: fig leaves (*Ficus carica* Linn) extract, Sodium carboxymethyl cellulose (CMC-Na) 3% as the basic ingredient of gel (Darmstadt, Germany), Materials used for histopathological staining were Hematoxylin & Eosin (HE) and *Masson's Trichome* (MT).

Animals

Twenty-four Wistar strain of *Rattus norvegicus* aged 2.5 months weighing 150-200 g, were used as animal models in this research. Those rats were

adapted for one week prior to commencement of the research and were randomly allotted into four groups, as below:

C3 group is the Control Group (untreated)

T3 group is the Study Group given fig leaves extract once a day for three days

C7 group as a Control Group (untreated)

T7 group is the Study Group given fig leaves extract once a day for seven days.

The groups consisted of six rats each. Twenty-four rats were utilized in this research, were fed a standard chow and tap water *ad libitum*.

Preparation of Plant Material:

Criteria of fig leaves were 4-6 months green Jordan types which could be picked approximately on the fifth leaves and so on from the top of the fig tree. Fig leaves extract was prepared using maceration method with 96% ethanol solvent. The phytochemical screening of fig leaves extract showed positive results on flavonoids, terpenoids, and tannins [4]. Fig leaves extract was made in gel form using CMC Na (3%).

Experimental Procedure:

After the adaptation period, the combination of ketamine HCl and diazepam were used to anesthetize those animals (1:1 ml, with a dose of 1 ml/kg body weight. intramuscularly) [10]. The skin around the area to be incised (vertebralis thoracis muscle) was disinfected using 70% alcohol, and shaved. An incision of full thickness made by 20 x 2 mm (width x depth) using a surgical blade No. 15 (Swann-Morton, Sheffield, England). The wound was given with fig leaves extract topically at about 0.5 ml once a day, but the Control Group was left untreated. The incision wounds in the control and the treatment groups were covered by

hypoallergenic tape (Hypafix, Germany). Both the control and treatment groups were then sequentially sacrificed on days 3 and 7 to obtain subepithelial incision samples.

The tissue was removed and fixed in 10% formalin solution for histopathological tests. Then it was embedded in paraffin. Cutting of paraffin blocks was carried out with a rotary microtome with a thickness of 4 μ m. HE staining was performed on tissues for calculating the number of macrophages and fibroblasts. Staining using MT was done to observe the density of collagen. Collagen density was observed according to the criteria of the score that has been determined as follows [11]:

0 = no collagen

1 = Low collagen density (< 10% per field of view)

2 = Medium collagen density (10-50% per field of view)

3 = Density of collagen is tight (50 to 90% per field of view)

4 = Density of collagen is very tight (90 to 100% per field of view)

Calculation of macrophages, fibroblasts and collagen density were performed using a light microscope (Binocular Olympus XC-23) with 400x magnification.

Statistical Analysis

Mean \pm SD was used for descriptive statistics. For each variable, the normal distribution was evaluated and confirmed using the one-sample Kolmogorov test. One-way ANOVA test was used for comparing the variables between groups and LSD test was used for pair wise comparisons. Statistical significance was defined as $P < 0.05$ and analysis was done using SPSS (Version 11; SPSS Inc., Chicago, USA.)

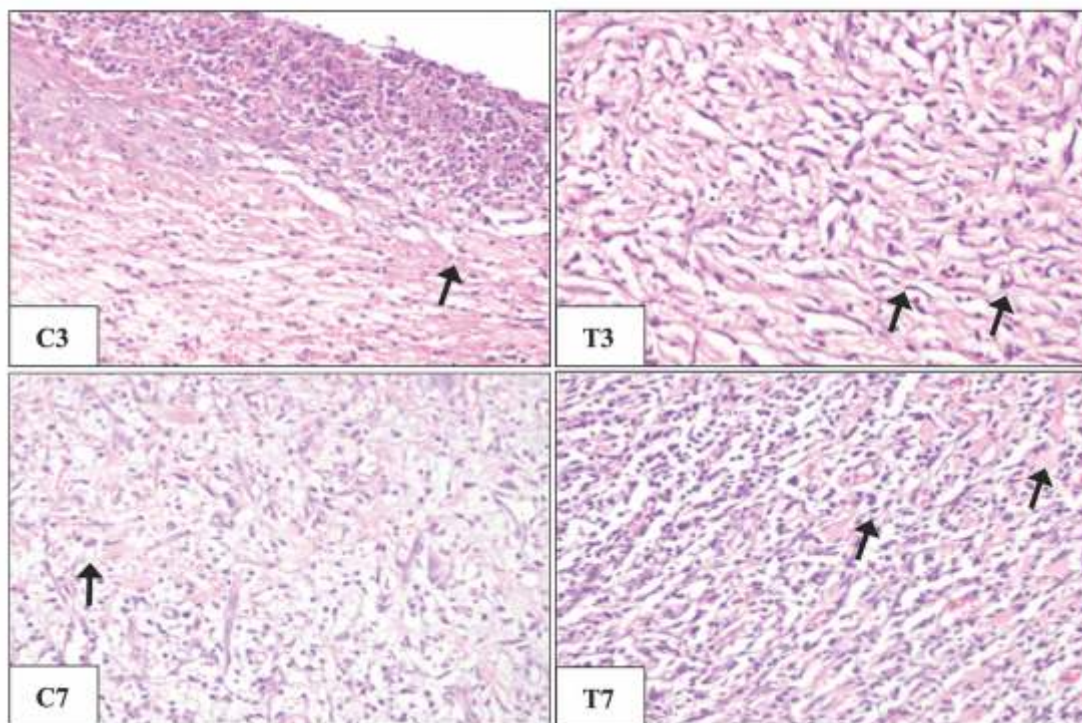


Fig. 1: Microscopic Description of Macrophages with 400× Magnification. C3) Group C3; T3) Group T3; C7) Group C7; T7) Group T7

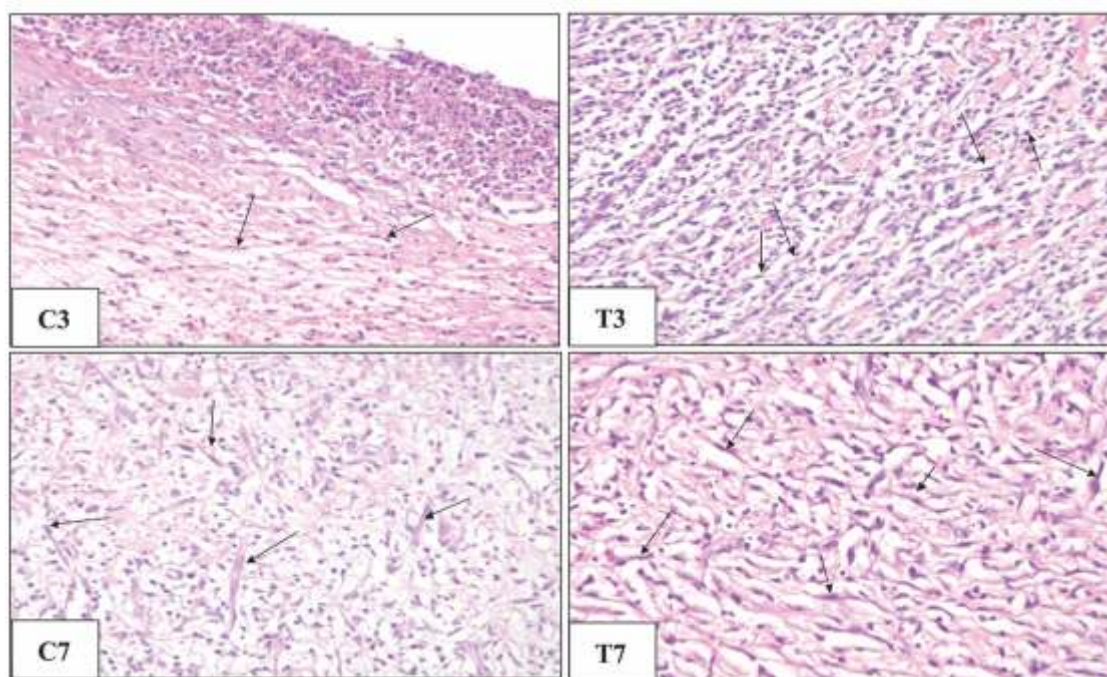


Fig. 2: Microscopic Description of Fibroblast with 400× Magnification. C3) Group C3; T3) Group T3; C7) Group C7; T7) Group T7

Results:

The result of HE staining of macrophages and fibroblasts on each group was shown in Fig.1 and Fig. 2. The results of MT staining of collagen on each group was shown in Fig.3 while the mean and standard deviation could be summarized in Table 1. The statistical analysis of macrophage and fibroblast was performed using one-way ANOVA and has value of 0.00 ($P < 0.05$) which was followed by Tukey's *Post hoc* test which was presented as the superscript on each group. The statistical analysis of collagen was performed using *Kruskall-Wallis* and has value of 0.00 ($P < 0.05$) which was followed by *Mann-Whitney test* which was presented as the superscript on each group (Table 1).

Values expressed in Mean \pm SD. ^{a, b} Means within each column showing different lowercase letters are significantly different ($P < 0.05$). From the data obtained, found that C3 group showed the lowest number of macrophages while the highest number of macrophages was found on T7 group. In the T3

group were significantly higher as compared to the C3 group and the T7 group were significantly higher as compared to the C7 group. There was significant difference between C3 and C7 group, T3 and T7 group. Interestingly, the T3 group has the same number of macrophages with C7 group. The same occurrence was found between the C3 and T3 groups, the lowest number of fibroblasts was found on C3 group while the highest number of fibroblasts was found on T7 group. In the T3 group were significantly higher compared with the C3 group and the T7 group were significantly higher compared with the C7 group. There was significant difference between C3 and C7 groups, T3 and T7 groups.

The difference pattern occurred in the collagen density, there were no significant difference between C3 and T3 groups, C7 and T7 groups but there was significant difference between C3 and C7 groups, T3 and T7 groups.

Table 1: Values of Fibroblasts, Macrophages and Collagen Density

| Group (n=6) | Macrophage | Fibroblasts | Collagen |
|-------------|------------------------------|------------------------------------|-------------------------------|
| C3 | 15.5 \pm 3.27 ^a | 13.3333 \pm 2.16025 ^a | 2.00 \pm 0.000 ^a |
| T3 | 26.5 \pm 3.44 ^b | 31.1667 \pm 2.22860 ^b | 2.00 \pm 0.000 ^a |
| C7 | 23 \pm 3.22 ^b | 47.0000 \pm 6.60303 ^c | 3.00 \pm 0.000 ^b |
| T7 | 39.5 \pm 2.94 ^c | 58.0000 \pm 5.69210 ^d | 3.00 \pm 0.000 ^b |

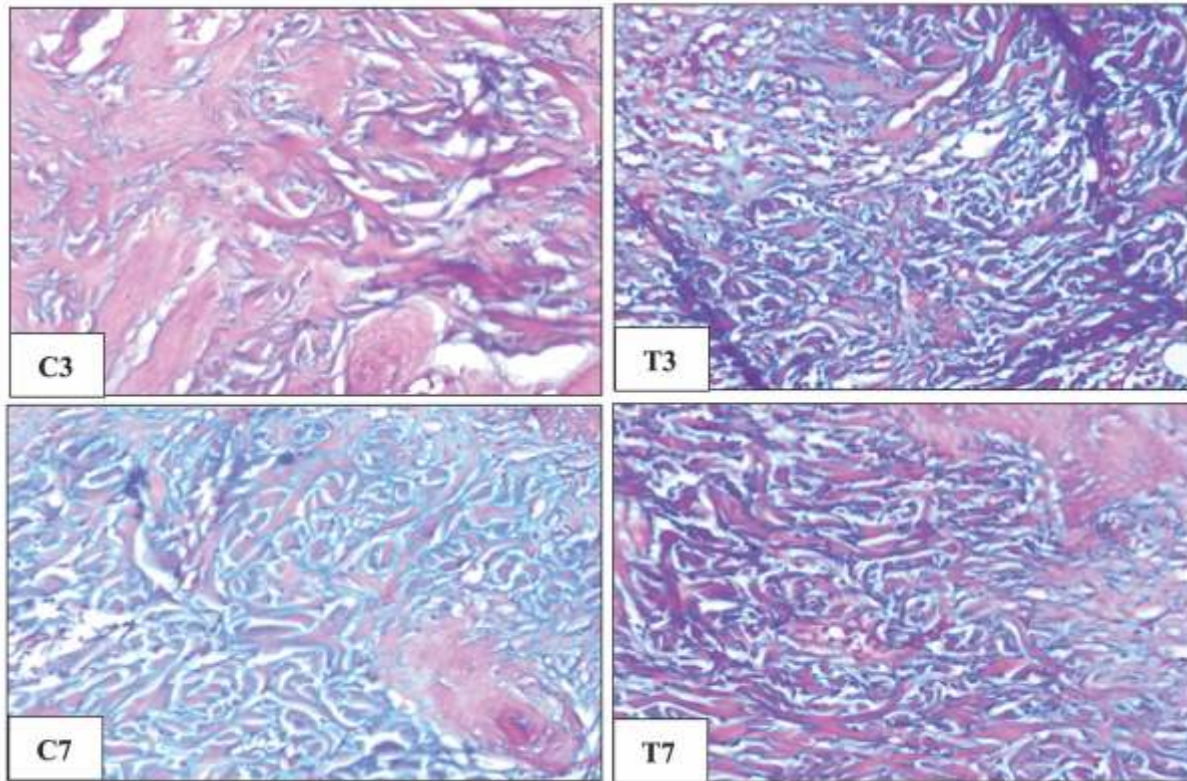


Fig. 3: Microscopic Description of Density of Collagen with 400× Magnification. C3) Group C3; T3) Group T3; C7) Group C7; T7) Group T7

Discussion:

Macrophages have an important role in wound healing, and have the ability to produce factors that stimulate angiogenesis and fibroplasias [12]. Macrophages have several main functions in wound healing, which produce collagenase, elastase, and enzymes that harm wound tissue and produce cytokines such as TNF- α , IL-1, IL-6. Macrophage numbers increase during the inflammation phase, peaking during the granulation tissue formation phase on Day 5 and declining during the maturation phase [13]. Thus, in addition to resident macrophages, the main population of macrophages in the lesion is recruited from the blood in response to chemotactic products, as can be seen in extracellular matrix

protein fragments, TGF- β , MCP-1 (protein 1 chemotactic for monocytes) [14]. Macrophages can be classified as classically activated (M1 pro-inflammatory) and alternatively activated (M2 anti-inflammatory and pro-angiogenic) [15]. These macrophages release growth factors, such as PDGF and VEGF, which are commonly necessary for the triggering and propagation of new tissue in the area of lesion.

The results of this study showed that the number of macrophages is increased in the study groups after given fig leaves extract compared to the control group. This phenomenon shows that there is an acceleration of activation and infiltration of macrophages in injured tissue in the treatment

group, which was given fig leaves extract compared to the control group. The extract contains various active compounds, namely flavonoids, terpenoids, and tannins [4]. Flavonoids have the ability to activate T-lymphocytes to increase interferon (IFN-) production which activates macrophages thus increasing the number of macrophages in the area of injury or inflammation, thereby accelerating the inflammatory stages [16]. Interestingly, the group which was given fig leaves extract gel once a day for three days had the same number of macrophages as given once a day for seven days in control group. It was seen that the treatment group which was given fig leaves extract gel for three days was effective in increasing the number of macrophages, to equal the number of macrophages in the seven days control group. The results of the study in the treatment groups on three days as compared to seven days showed a high number of macrophages significantly. This is in accordance with the result of previous research, showed that the expression of macrophage increased significantly from three to five days after wounding and remained high on seven days and the expression trend of macrophages did not mirror that observed in wounds because macrophages do not constitute a homogeneous population of cells but exists as multiple phenotypes classified as M1 and M2 phenotypes [17].

Based on the profiles of genic expression, macrophages can be classified as classically activated (M1 pro-inflammatory) and alternatively activated (M2 anti-inflammatory and pro-angiogenic). These macrophages release growth factors, such as Platelet Derived Growth Factor (PDGF) and Vascular Endothelial Growth Factors

(VEGF), which are commonly necessary for the triggering and propagation of new tissue in the wound area [18]. Therefore, the high level of macrophage between three and seven days is an anti-inflammatory. The presence of alternatively activated macrophages and accelerated infiltration of macrophages, suggest an acceleration of the inflammatory process that leads to wound healing [12].

The results of the fibroblast number showed that the administration of fig leaves extract for three and seven days increased the number of fibroblast cells as compared to the control group. The increase in the number of fibroblast cells in the treatment groups on three and seven days was probably due to the anti-inflammatory activity of fig leaves extract. When inflammation occurs, fig leaves extract as an anti-inflammatory could increase the number of macrophages that will phagocytose pathogenic cells and secrete cytokines and growth factors. Macrophages play an important role in the release of pro inflammatory cytokines such as tumor necrosis factor- (TNF-), Interleukin-1 (IL-1) and IL-6. Fig leaves extract can reduce proinflammatory cytokines that will influence the formation of growth factors such as PDGF, Transforming Growth Factor (TGF- 1), Fibroblast Growth Factors (FGF), Epidermal Growth Factors (EGF) and VEGF [19]. These factors stimulate the migration and proliferation of fibroblast cells, as well as collagen production while VEGF stimulates angiogenesis. Good wound healing process occurs if there is a decrease in pro-inflammatory cytokines, so that inflammation can be regulated, as a result the release of growth factors increases, which affects the increase in the number of fibroblasts. This migration and

proliferation of fibroblast cells has an important role in tissue regeneration so that wound healing occurs. Fibroblast cells form collagen tissue and further cause epithelialization in the healing process.

Histological observations, collagen density between three- and seven-days control groups differed in collagen density from moderate to solid (score 2 to 3), as well as to the three- and seven-days treatment groups. Comparison between the control group and the treatment did not show differences in collagen density.

The results of this study indicated that an increase in the number of fibroblasts does not coincide with an increase in collagen production. Calculation of the number of fibroblasts showed an increase in the control and treatment groups. Collagen synthesis continues until about 4-5 weeks after the wound. The increase in the rate of collagen synthesis

during wound healing depends not only on the increase of fibroblast cells number, but also on the collagen production of each fibroblast cell, because each fibroblast cell does not always produce the same amount of collagen [20]. The 50% fig extract gel used in this study has not shown the effect of increasing the maximum collagen density for three- and seven-days treatment. Further research is needed to give topical leaves extract gel to the wound with a concentration of more than 50% and a longer time span.

Conclusion:

Application of fig leaves extract on Wistar rat wounds could increase the number of fibroblast cells, macrophages and not collagen density in the wound healing process after treatment for three and seven days.

References

1. Barbul A, Efron, D. Wound Healing in Schwartz Principle of Surgery. 9th Edition. McGraw Hill. New York: USA; 2010. 210-219.
2. Eming SA, Martin P, Canic MT. Wound repair and regeneration: mechanisms, signaling, and translation. *Sci Transl Med* 2014; 6(256):265sr6
3. Bigliardi P, Stefan Langer S, Cruz JJ, Kim SW, Nair H, Srisawasdi G. An Asian Perspective on Povidone Iodine in Wound Healing. *Dermatology* 2017; 233(2-3):223-233.
4. Nirwana I, Rianti D, Soekartono R.H, Listyorini R.D and Basuki D.P. Antibacterial activity of fig leaf (*Ficus carica* Linn.) extract against *Enterococcus faecalis* and its cytotoxicity effects on fibroblast cells. *Vet World* 2018; 11(3):342-347
5. Lee YS, Cha JD. Synergistic antibacterial activity of fig (*Ficus carica*) leaves extract against clinical isolates of methicillin resistant staphylococcus aureus. *Kor J Microbio Biotech* 2010; 38(4):405-413.
6. Johnson A, Francis M, DiPietro LA. Differential apoptosis in mucosal and dermal wound healing. *Adv Wound Care* 2014; 3(12): 751-761.
7. Song G, Nguyen DT, Pietramaggiore G, Scherer S, Chen B, Zhan Q, et al. Use of the parabiotic model in studies of cutaneous wound healing to define the participation of circulating cells. *Wound Repair Regen* 2010; 18(4):426-432.
8. Sorg H, Tilkorn DJ, Hager S, Hauser J, Mirastschijski U. Skin Wound Healing: An Update on the Current Knowledge and Concepts. *Eur Surg Res* 2017; 58(1-2):81-94.
9. Yuslianti ER, Bachtiar BM, Suniarti DF, Sutjatmo AB, Yuslianti ER, Bachtiar BM, et al. Effect of topical Rambutan honey pharmaceutical grade on oral mucosa wound healing based on tissue wound closure and fibroblasts proliferation in vivo. *Int J Pharmacol* 2015; 11(7): 864-869.

-
10. Flecknell P. Laboratory Animal Anaesthesia. 3rd Edition. Academic Press, USA. 2009. 204-210.
 11. Theunissen D, Seymour B, Forder M, Cox SG, Rode H. Measurements in wound healing with observations on the effects of topical agents on full thickness dermal incised wounds. *Burns* 2016;42(3): 556–563
 12. Koh TJ, DiPietro LA. Inflammation and wound healing: the role of the macrophage. *Expert Rev Mol Med* 2011;13:e23
 13. Mahdavian DB, van der Veer WM, van Egmond M, Niessen FB, Beelen RH. Macrophages in skin injury and repair. *Immunobiology* 2011; 216(7): 753-762.
 14. Thuraisingam T, Xu YZ, Eadie K, Heravi M, Guiot MC, Greemberg R, et al. MAPKAPK-2 signaling is critical for cutaneous wound healing. *J Invest Dermatol* 2010; 130(1):278-286.
 15. Rodero MP, Khosrotehrani K. Skin wound healing modulation by macrophages. *Int J Clin Exp Pathol* 2010; 3(7):643-653.
 16. Duffield JS. The inflammatory of macrophage: a story of Jekyll and Hyde. *Clin Sci (Lond)* 2003; 104(1):27-38
 17. Meizarini A, Ariyati, Riawan W, Puteri A. Anti-inflammatory properties of a wound dressing combination of zinc oxide and turmeric extract. *Vet World* 2018;11(1):25-29.
 18. Gonzalez AC, Costa TF, Andrade ZA, Medrado AR. Wound healing - A literature review. *An Bras Dermatol* 2016; 91(5):614-620.
 19. Farahpour MR, Habibi M. Evaluation of the wound healing activity of an ethanolic extract of ceylon cinnamon in mice. *Vet Med* 2012; 57(1):53-7.
 20. Diegelmann RF. Analysis of collagen synthesis. *Methods Mol Med* 2003;78: 349.
-

**Author for Correspondence: Intan Nirwana, Department of Dental Material. Faculty of Dental Medicine, Universitas Airlangga, Surabaya, Indonesia. Email: intan-n@fkg.unair.ac.id*