

FOLIA MEDICA INDONESIANA

Vol. 45 No. 3 July – September 2009

COMPARISON OF APOPTOTIC INDEX AND THE AMOUNT OF BRAIN'S PYRAMIDAL NEURON BETWEEN NEWBORN MICE RECEIVING AND NOT RECEIVING DOCOSAHEXANOIC ACID DURING PREGNANCY
(Muhammad Maksum, Hermanto Tri Joewono and Widjiati)

NUCLEOTIDE SEQUENCE AND SEQUENCE COMPARISON OF THE REPEAT SEQUENCE 529 (R529) OF AN INDONESIAN *TOXOPLASMA GONDII* ISOLATE
(Sri Hartati, Asmarani Kusumawati, Hastari Wuryastuti, Sri Widada)

HUMAN SPERM PRESERVATION USING FREEZE-DRYING
An Experimental Laboratory Study
(MP Budyandini Dyah Pramesti, Hamdani Lunardhi, Reny I'tishom)

CORRELATION BETWEEN P53 PROTEIN EXPRESSIONS IN THE INCIDENCE OF METASTASIS IN WELL-DIFFERENTIATED THYROID CANCER
(Yan Efrata Sembiring, Sunarto Reksoprawiro, Tulus Panuwun)

HEPATOPROTECTIVE ACTIVITY OF BARKS EXTRACT OF SIX CINNAMOMUM SPECIES ON CARBON TETRACHLORIDE-INDUCED IN ALBINO RATS
(Muthiah Maridass)

THE EFFICACY OF COMBINED CREAM BROMELAIN - LIPOSOME AS ENZYMATIC DEBRIDING AGENT FOR DEEP BURN PATIENTS
(Magda Hutagalung, M. Sjaifuddin Noer)

DETERMINANT OF SOCIAL MATURITY LEVEL AMONG THE VISITORS OF HEALTHY INFANTS CLINIC
(Dina Djojohusodo, Soetjningsih, Windhu Purnomo)

"HUMANITY FIRST, TECHNOLOGY SECOND" REDUCING INFANT MORTALITY RATE WITH KANGAROO MOTHER CARE: PRACTICAL EVIDENCE FROM SOUTH AFRICA
(Risa Etika et al)

IDENTIFICATION OF THE VICTIMS OF KM SENOPATI NUSANTARA USING DNA PROFILING
A Case Report of Disaster Victim Identification
(Ahmad Yudianto, Agung Sosiawan, Soekry Erfan Kusuma)

Case Report:
NODULAR SCLERITIS WITH PRE-SUSPECTED RETINOBLASTOMA
(Reni Prastyani, Hera Dwi Novita, Moestidjab)

ACUPUNCTURE THERAPY TO RELIEVE PAIN IN DEXTRAL HYPOCHONDRIAL AREA
A Case Study on Referred Pain
(Abdurachman)

Review Article and Clinical Experiences:
A NOVEL OAD WITH BROADSPEACTRUM THERAPEUTIC VALUE FOR PTS WITH T2DM
The Roles of Galvus® for Pts with T2DM, MODY, TxDM, Pre-DM, and T1DM
(Askandar Tjokroprawiro)

International Online Distribution by ProQuest™
www.proquest.com

Folia Medica Indonesiana	Vol. 45	No. 3	Page 174 - 243	Surabaya Jul-Sept 2009	ISSN 0303 - 7932
-----------------------------	---------	-------	----------------	---------------------------	---------------------

ACUPUNCTURE THERAPY TO RELIEVE PAIN IN DEXTRAL HYPOCHONDRIAL AREA A Case Study on Referred Pain

Abdurachman

Department of Anatomy-Histology, Faculty of Medicine Airlangga University

ABSTRACT

Complain on certain part of the body (pain, for example) often indicates a pathologic condition originating at the location of complain. If the pathologic condition does not originate at the location of pain, in modern medical science, this phenomenon is known as referred pain. Pain, either local or referred pain can be explained based on one of the foundations of medical science, which is anatomy. In the following case study, a phenomenon of hypochondriac pain was found. This phenomenon was unexplainable by basic anatomy which was commonly acknowledged in modern science. In the following case study, it will be shown that there was pain at the right hypochondrium and the pain was caused by a wound located on infra malleolus lateralis dextra. A therapy using acupuncture technique was applied to the patient. After the acupuncture needle was inserted at the point Gb-34 (right under the meeting point of caput fibula dextra and tibia bone), pain and other complaints on right hypochondrium region was relieved.

Keywords: Pain, hypochondrium dextra, infra malleolus lateralis dextra.

Correspondence: Abdurachman, Department of Anatomy-Histology, Faculty of Medicine Airlangga University, Jl Prof. Dr Moestopo 47, Surabaya 60131.

INTRODUCTION

Complaint on certain part of the body (pain, for example) often indicates a pathologic condition originating at the location of the complaint. If the pathologic condition does not originate at the location of pain, in modern medical science, this phenomenon is known as referred pain. Pain, either local or referred pain can be explained based on one of the foundations of medical science, which is anatomy. In the following case study, a phenomenon of hypochondriac pain was found. This phenomenon was unexplainable by basic anatomy which was commonly acknowledged in modern science.

CASE REPORT

The first case was an 11-year-old male child came with his parents to the practice. He complained about discomfort/pain on his right hypochondrium region which had appeared since three days before. He also complained about feeling nauseous. The child had been examined and given several medicines by some previous physicians. Those medicines included painkiller and antiemetic, but the child complains still persisted. His parents decided to find another physician.

After writer did anamnesis and several other medical procedures, writer found an old wound on his infra malleolus lateralis dextra region. As an acupuncturist,

writer immediately remembered about the energy communication path (meridian) between the region of the wound and the region of pain in the child's stomach.

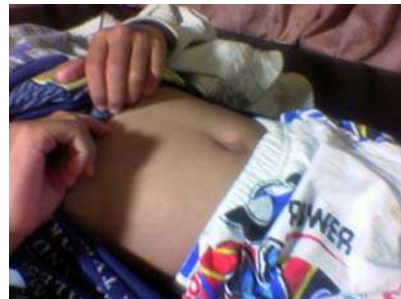

Figure 1. Patient complained about pain on his right hypochondrium region

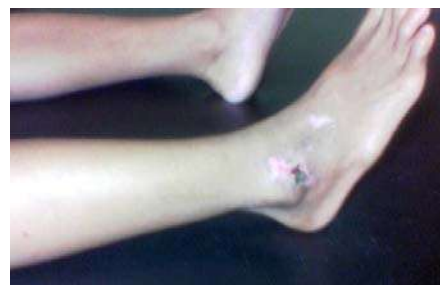

Figure 2. Location of the wound on infra malleolus lateralis dextra region

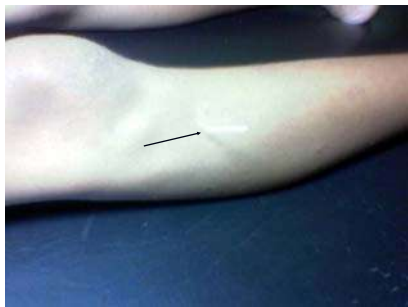


Figure 3. Location of needle insertion (location of therapy) at point Gb-34

After informing the consent to the parents, writer did a treatment by inserting a needle between caput fibula and tibia bone, right at the meeting point of both bones. In acupuncture medicine technique, the point was called point gallbladder-34 (Gb-34). The decision to choose that point was based on the theories of acupuncture therapy (Yanfu et al. 2002^(a,b)). The needle was turned around clockwise for approximately twenty seconds. After this was done, the entire patient's complains were instantly gone.

Second Case was A 57-year-old woman complained about pain, discomfort on her hypochondrium sinistra which appeared three days before. She also complained about feeling nauseous. In physical examination, an old wound was found on her infra malleolus lateralis sinistra region.



Figure 4. Location of pain

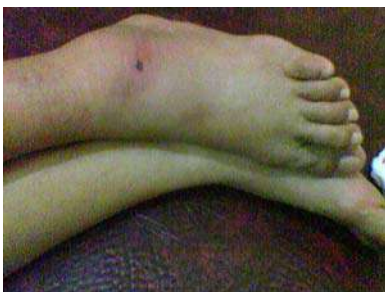

Figure 5. Location of wound

The description of the above case was similar with the description of the previous case. The only difference was that this case affected the left side. In the previous case, complains were on the right side of the body, while in this case, complains were on the left side of the body. The above figures (figure 1, 2, 3, 4, 5) were taken using Nokia 9500 cell phone camera.

DISCUSSION

In acupuncture medicine technique, a communication path exists aside from nervous, blood vessels, and lymph vessels communication path. This particular communication path is known as energy communication path (chi) or is specifically named as meridian. In acupuncture theory, it is mentioned that chi flows through the body's meridians. If this chi flow is disrupted, complains or symptoms according to the degree of disruption and which meridian is disrupted will appear. The map of energy communication path (meridian) in a human's body is shown in the following picture:

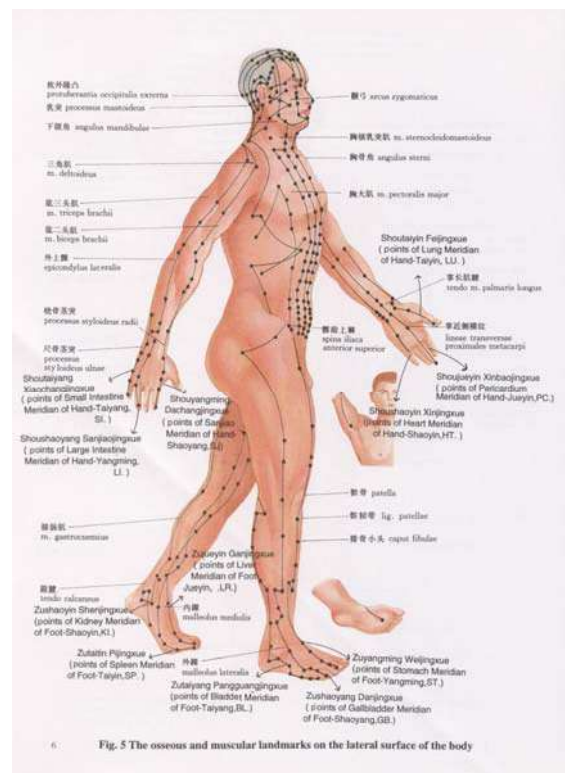


Fig. 5 The osseous and muscular landmarks on the lateral surface of the body

Figure 6. Meridian map (Hualing 1999)

According to Gellman (2002), the body's bio energy flows through specific channels called meridian, and regulates the whole functions of the body's organs. Meridian is channels which connect all of the body's

components. Aside from connecting all of the body's energy internally, meridian also connects the body's internal energy with external energy (natural energy) through "doors" called acupuncture points.

Stimulation on acupuncture points will be transmitted through meridian communication path. Then the stimulation will affect the circulation of the existing energy system, creating a healing effect, especially to organs connected directly to the stimulated acupuncture points (Gellman 2002). Diameters of the acupuncture points are approximately between one to three millimeters.

The depths from the surface of the skin are according to the place and different in each individual (Wensel 1980). It has long been known that acupuncture points have some specific characteristics, at superficial acupuncture points, there are high electric potential (can reach as high as 300mV), high electric capacitance (0.1-1mF), low electric resistance, increased skin respiration, high local temperature, radiating light which spontaneously visible from Jing and Yuan points, and sound signals (frequency= 2-15 Hz, amplitude = 0.5-1 mV). At profound acupuncture points, there are low perception threshold to electric stimulation, high capacitance, electric resonance with the other acupuncture points, high conductivity to isotopic tracers (Starwyn 2001),




Figure 7. (a) Shows an injection on a control point (not an acupuncture point). There was no migration of the isotope material for 307 seconds following the time the isotope was injected.
 (b) Shows an injection on an acupuncture point. There was an isotope migration at the speed of 6 cm/minute along the path (Darras et al. 1992).

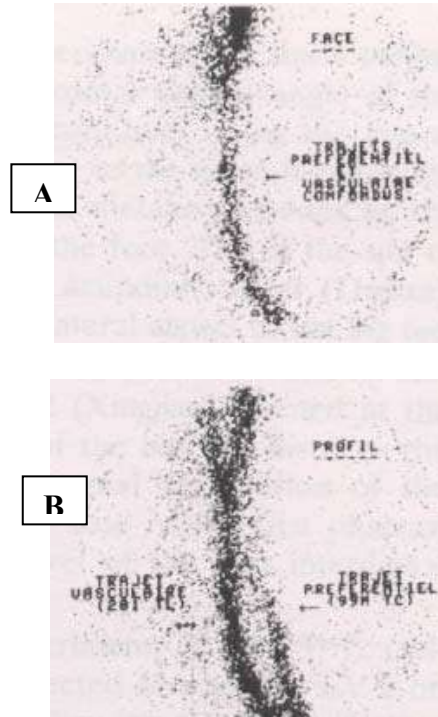


Figure 8. (a) Shows frontal view of ^{99m}Tc injection on acupuncture point LV-2 and thallium isotope (²⁰¹Tl) injection on a small vein right next to LV-2 acupuncture point. Both injection points had no significant difference.
 (b) Shows a clear difference of the paths they followed (a = vein path and b= meridian path) (Darras et al. 1992).

Related to high conductivity to isotopic tracers, Darras et al. (1992) once proved this fact by injecting technetium-99m (^{99m}Tc) isotope as pertechnetate sodium through an acupuncture point and then scanning it with gamma camera. The isotope was found "moving" along the path which matched the meridian path in TCM. That path was different from that of blood vessels or lymph vessels.

These last decades had presented a new discovery on specific cell-to-cell communication path which was called Gap Junctions (GJ). The content of GJ is folded by ten times on acupuncture points. GJ was an old depiction of the cell-to-cell communication evolution. (Rakovic 2001, Shang 2001;2002) (Figure 9).

Gap Junctions in Cellular Homeostasis

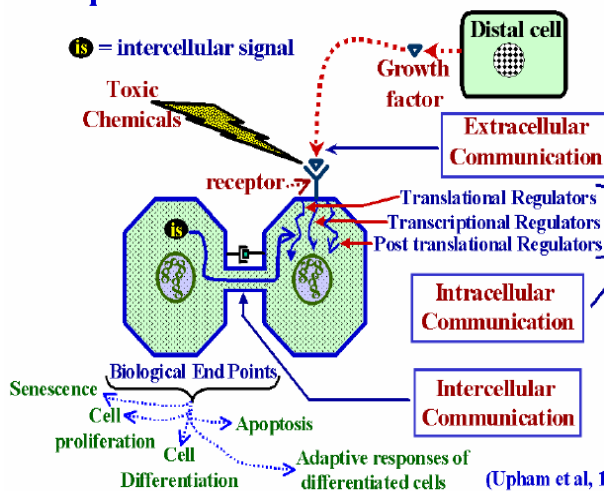


Figure 9. Schematic gap junctions of normal cell. Gap junctions function as a cell-to-cell communication path; homeostatic, electrical synapse, metabolic support, increasing the speed of tissue response to stimulation, growth control, differentiation and apoptosis (Upham et al. 1998).

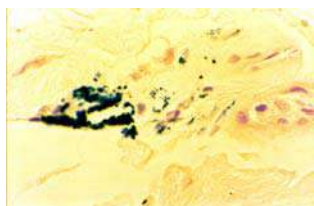


Figure 10. Observation using a photonic microscope on acupuncture point on the dermic layer around glandula sudorifera (Perls Coloration). The black spots spreading in the dermic layer were Fe₃O₄ magnetic crystals (Moal, 2002).

A research by Moal (2002), showed that there was a magnetic field increase on acupuncture points. This was shown by an increase of ferri oxide (Fe₃O₄) magnetic crystal concentration on acupuncture points, as could be seen at figure 10. In the first case, an old wound on the patient caused pain on hypochondrium region and nauseous feeling. In acupuncture technique, all those complain matched the symptoms of gallbladder (Gb) meridian chi disruption according to the meridian map showed in figure 11.

The wound in the first case did affect Gb meridian on the point Gb-40. According to acupuncture theories about wound on that point, in certain time span, it would cause pain on hypochondrium, accompanied by some

digestive problems. According to the acupuncture theories also, a therapy could be done to resolve all complains, including efforts to accelerate the wound healing on point Gb-40 could be done by stimulating the point Gb-40 itself (Yanfu et al. 2002^(a,b)).

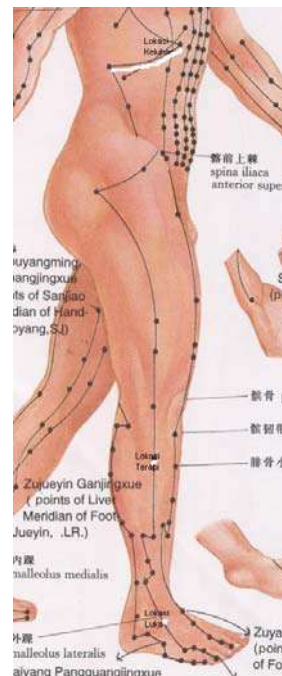

Figure 11. White (bright) dots in the Figure above each show the locations of wounds and the locations of therapies. Bright line shows the location of complains. The line connecting bright dots and bright line is gallbladder meridian (Hualing, 1999).

CONCLUSION

The above phenomenon still needs to be studied and given scientific foundation. The goal is to avoid misdiagnosis, mitherapy, and more importantly it is very possible that complains on thoracal region, cranial region, or even other body regions have causes actually existed on locations far from the locations of complains. The complains spreading and main causes can be far different from medical morphologic anatomy description which is commonly recognized and taught in modern medical science.

REFERENCES

Darras JC, Vernejoul P, Albarerdè P, 1992. Nuclear Medicine an Acupuncture: A Study on the Migration

- of Radioactive Tracers After Injection at Acupoint. American Journal of Acupuncture Vol. 20, No. 3.
- Gellman H, 2002. Acupuncture Treatment for Musculoskeletal Pain. A Textbook for Orthopedics, Anesthesia, and Rehabilitation. Taylor & Francis, New York.
- Hualing G, 1999. The Atlas of Layered Anatomy of Acupoints. Foreign Languages Press, Beijing.
- Moal P, 2002. Search of Magnetosomes type magnetite grains in the dermis layer at acupuncture points. Visualisation via Photonic and Electronic Microscopes (SEM & TEM). Microprobe Bombardments. WFAS International Symposium On Acupuncture, Rome, November 7-9, pp 127-128.
- Rakovic D, 2001. Biophysical Bases of the Acupuncture and Microwave Resonance Stimulation. Physics of the Alive Vol 9, No.1: pp 23-32.
- Shang C, 2001. The Past, Present, and Future of Meridian System Research. Clinical Acupuncture. Scientific Basic. Springer-Verlag Berlin Heidelberg, pp 69-82.
- Shang C, 2002. The mechanism of Acupuncture. Acupuncture.com. School of Medicine, Boston University.
- Starwynn D, 2001. Electrophysiology And The Acupuncture Systems. Medical Acupuncture vol. 13, Number 1.
- Wensel MD, 1980. Acupuncture for Americans. Virginia: Reston Publ. Comp. Inc. A Prentice Hall Company.
- Yanfu Z et al., 2002. Basic Theory of Traditional Chinese Medicine. Publishing House of Shanghai University of Traditional Chinese Medicine. Shanghai. China.
- Yanfu Z et al., 2002. Chinese Acupuncture and Moxibution. Publishing House of Shanghai University of Traditional Chinese Medicine. Shanghai. China.