Volume 10, Number 2, March–April 2019

ISSN: 0976-3661

Special Issue: The Rise of Shoulder Arthroscopy

Guest Editor: Bijayendra Singh

Journal of Clinical Orthopaedics and Trauma

An Official Publication of Delhi Orthopaedic Association

"Roots of Responsibility, Wings of Professional Excellence"

ELSEVIER

Now in PubMed

Journal of Clinical Orthopaedics and Trauma
An Official Publication of Delhi Orthopaedic Association

Editorial Board

Editor-in-Chief

Raju Vaishya, Dept. of Orthopaedics, Indraprastha Apollo Hospitals, New Delhi, India
email: raju.vaishya@gmail.com

EDITORS

Rajesh Malhotra, Department of Orthopaedics, AIIMS, New Delhi, India

AK Sud, Department of Orthopaedics, Lady Hardinge Medical College, New Delhi, India

EXECUTIVE EDITORS

Hitesh Lal, Central Institute of Orthopaedics, Safdarjung Hospital & Vardhman Mahavir Medical College, New Delhi, India

Lalit Maini, Dept. of Orthopaedic Surgery, Maulana Azad Medical College, New Delhi, India

SECTION EDITORS

A) LOWER LIMB

i) Hip & Pelvis:

Mark D. Haseneuer, Department of Orthopaedic Surgery, University of Pennsylvania, Philadelphia, USA

Rohit Hasija, Hip & Knee Center, NYC Health & Hospitals/Elmhurst, Elmhurst, USA

Venu Kavarthapu, Department of Orthopaedics, King's College Hospital, London, UK

Videsh Raut, Centre for Hip Surgery, Wrightington Hospital, Lancashire, UK

Jatin Talwar, Central Institute of Orthopaedics, Safdarjung Hospital & Vardhman Mahavir Medical College, New Delhi, India

ii) Knee

Laszlo Bucsi, St.George University Teaching Hospital, Székesfehérvár, Hungary

SJ Kim, Uijeongbu St. Mary's Hospital, Catholic University Medical College, Seoul, South Korea

Norimasa Nakamaru, Institute for Medical Science in Sports, Osaka Health Science University, Japan

AA Shetty, Professor of Orthopaedics, Canterbury Christ Church University, Kent, UK

Kimberly L Stevenson, Department of Orthopaedic Surgery, University of Pennsylvania, Philadelphia, USA

Rajiv Thukral, Dept. of Orthopedics, Max Super Speciality Hospital, Saket, New Delhi, India

Saket Tibrewal, Department of Trauma & Orthopaedic Surgery, Lewisham & Greenwich NHS Trust, University Hospital Lewisham, High Street, London, UK

Sheo Tibrewal, Spire Roding Hospital, London, UK

iii) Foot & Ankle

Gurinder Bedi, Department of Orthopaedics, Fortis Hospital, Vasant Kunj, New Delhi, India

M S Dhillon, Dept. of Orthopaedics, Post Graduate Institute of Medical Education and Research, Chandigarh, India

Jitendra Mangwani, Consultant Foot & Ankle Surgeon, Leicester General Hospital, UK

Balvinder Rana, Department of Foot and Ankle surgery, Fortis Hospital, Gurgaon, India

Rajesh Sethi, Dept. of Trauma & Orthopaedics, Northern Lincolnshire and Goole NHS Foundation Trust, North Lincolnshire, UK

Maninder Singh Shah, Senior Consultant Orthopaedics, Chief of Foot and Ankle Services, Indian Spinal Injuries Centre, New Delhi, India

B) UPPER LIMB

i) Shoulder:

J Maheshwari, Deapartment of Orthopaedics, Max Hospital, Saket, New Delhi, India

Puneet Monga, Dept. of Orthopaedics, Wrightington Hospital, Lancashire, UK

Radha Kant Pandey, Dept. of Orthopaedics, Leicester Royal Infirmary, Leicester, UK

Bijayendra Singh, Consultant Orthopaedic Surgeon, Medway NHS Trust, UK

Keshav Singhal, Bridgend General Hospital, South Wales, UK

ii) Elbow and Hand:

Anand Arya, Department of Orthoapedics, Kings College Hospital, London, UK

Vikas Gupta, Department of Hand surgery, Max Hospital, Saket, New Delhi, India

P. P. Kotwal, Deaprtment of Orthopaedics, PSRI Hospital, Saket, New Delhi, India

Raj Murali, Dept. of Orthopaedics, Wrightington Hospital, Lancashire, UK

C) SPINE

Birendra Balain, Robert Jones and Agnes Hunt Orthopaedic Hospital, Oswestry, UK

Bhaskar Borgohain, Department of Orthopaedics, NEIGRIHMS, Shillong, India

Kamal Bose, Consultant Orthopaedic Surgeon, Mount Elizabeth Hospital, Singapore

HS Chabra, medical director , chief of spine services, Indian Spinal Injuries Centre, New Delhi, India

Ujjwal Debnath, Consultant Orthopaedics Surgeon, AMRI Hospitals, Kolkata, India

Bhavuk Garg, Deaprtment of Orthopaedics, All India Institute of Medical Sciences, New Delhi, India

Thamer Hamdan, University of Basrah, Basra, Iraq

Ramesh Kumar, Central Institute of Orthopaedics, Safdarjung Hospital & Vardhman Mahavir Medical College, New Delhi, India

S Rajasekharan, Managing Director, Ganga Hospital, Coimbatore, India

Ashish Upadhyay, Bristol Hospital, Bristol, Connecticut, USA

D) PAEDIATRIC ORTHOPAEDICS

Anil Agarwal, Department of Orthopaedics, Chacha Nehru Bal Chikitsalaya, Geeta Colony, Delhi, India

James P Hui, Department of Orthopaedics, National University Hospital, Singapore

Ashok Johari, Cumballa Children's Center, Cumballa Hill, Mumbai, India

Ritesh Runu, Department of Orthopaedics, Indira Gandhi Institute of Medical Sciences (IGIMS), Patna, India

Vipul Vijay, Department of Orthopaedics, Indraprastha Apollo Hospitals, New Delhi, India

E) TUMORS

Sudhir Kapoor, Department of Orthopaedics, Indian Spinal Injuries Centre, Vasant Kunj, New Delhi, India

Shah Alam Khan, Department of Orthopaedics, AIIMS, New Delhi, India

Shishir Rastogi, Department of Orthopaedics, Majeedia Hospital, New Delhi, India

Gurpal Singh, National University Hospital, Singapore

Akshay Tiwari, Department of Orthopaedic Oncology, Max Hospital, Saket, New Delhi, India

F) ARTHROPLASTY

Ajit Deshmukh, Department of Orthopaedic Surgery, NYU Langone Medical Center, VA New York Harbor Healthcare System, New York, NY, USA

Atul Joshi, Wheaton Franciscan Healthcare, Convenant Medical Center, Lubbock, USA

Yugal Karkhur, Department of Orthopaedics, Max Hospital, New Delhi, India

Aditya Vikram Maheshwari, Department of Orthopaedic Surgery, State University of New York (SUNY) Downstate Medical Center, Brooklyn, NY, USA

Jatin Prakash, Department of Orthopaedics, CIO, Safdarjung Hospital, New Delhi, India

Neil V. Shah, Department of Orthopaedic Surgery, State University of New York (SUNY) Downstate Medical Center, Brooklyn, NY, USA

G) ARTHROSCOPY & SPORTS MEDICINE

Amit Kumar Agarwal, Dept. of Orthopaedics, Indraprastha Apollo Hospitals, New Delhi, India

Jack Farr, Knee Restoration Centre of Indiana, USA

Ankit Goyal, Sports Injury Centre, Safdarjung Hospital, New Delhi, India

William Murrell, Emirates Integra Medical & Surgery Centre, Dubai Healthcare City, Dubai, United Arab Emirates

Divya Prakash, Sandwell and West Birmingham Hospitals NHS Trust, Birmingham, UK

Seth Sherman, Department of Orthopedic Surgery, Hospital for Special Surgery, Weill Medical College of Cornell University, New York, USA

Abhishek Vaish, Dept. of Orthopaedics, Indraprastha Apollo Hospitals, New Delhi, India

H) TRAUMA & REHABILITATION

Thaddeus Chika Agu, Consultant Orthopedic Surgeon and Lecturer, Imo State University, Owerri, Nigeria

Ashok Bajracharya, Capital Hospital, Putalisadak, Kathmandu, Nepal

Vijay Jain, Department of Orthopaedics, Dr. Ram Manhohar Lohia Institute of Medical Sciences, New Delhi, India

Samarth Mittal, Trauma Centre, AIIMS, New Delhi, India

Mohit Kumar Patralekh, Central Institute of Orthopaedics, Safdarjung Hospital & Vardhman Mahavir Medical College, New Delhi, India

Iqbal Qavi, National Institute of Trauma and Orthopaedics, Dhaka, Bangladesh

Bikram Shrestha, BP Koirala Institute, Darhan, Nepal

I) BIOMEDICAL ENGINEERING

Saurabh Ghosh, Indian Institute of Technology (IIT) Delhi, New Delhi, India

Abid Haleem, Dept. of Mechanical Engineering, Jamia Hamdard University, New Delhi, India

SS Panda, Indian institute of technology (IIT) Patna, Patna, India

Rupesh Pandey, Indian institute of technology (IIT) Patna, Patna, India

J) STATISTICS

Nilesh Kumar, Consultant Statistician, Indraprastha Apollo Hospitals, New Delhi, India

K) HEALTH CARE POLICY

Tanu Jain, National Centre for Disease Control, Delhi, India

Jugal Kishore, Safdarjung Hospital & Vardhman Mahavir Medical College, New Delhi, India

Sujeet Singh, Director, National Centre for Disease Control, Delhi, India

L) PLASTIC & RECONSTRUCTIVE SURGERY

Pawan Agarwal, Dept. of Surgery, NSCB Goverment Medical College, Jabalpur, India

M) BASIC SCIENCE

Elizabeth Vinod, Dept. of Physiology, Christian Medical College, Vellore, India

Copyright © 2019 Elsevier Inc. All rights reserved. | Privacy Policy | Terms & Conditions | Use of Cookies | About Us | Help & Contact | Accessibility

Journal of Clinical Orthopaedics and Trauma
An Official Publication of Delhi Orthopaedic Association

RSS Feeds Mobile

Subscribe | Login | Register | Claim Subscription

Articles and Issues For Authors Journal Info How to Get Published Society Information Subscribe More Periodicals

All Content Search Advanced Search

March–April 2019

Volume 10, Issue 2, p221-460

< Previous

The rise of Shoulder Arthroscopy

Edited by Bijayendra Singh



Enlarge Cover

Receive New Issues & Articles: Email Alert | RSS Feed

Search within this issue

Select All View Abstracts | Export Citations | Email a Colleague | Add to Reading List

Editorial

The rise of shoulder arthroscopy
Raju Vaishya
p221
Published in issue: March-April, 2019
Full-Text HTML | PDF

Special Symposium on Shoulder Arthroscopy

Surgical treatment outcomes after primary vs recurrent anterior shoulder instability
Jonathan D. Barlow, Timothy Grosel, John Higgins, Joshua S. Everhart, Robert A. Magnussen
p222–230
Published online: October 24, 2018
Full-Text HTML | PDF | Supplemental Materials

Bone block procedures for glenohumeral joint instability
Obinna Nzeako, Nik Bakti, Rajesh Bawale, Bijayendra Singh
p231–235
Published online: December 1, 2018
Full-Text HTML | PDF

Single Vs Double row repair in rotator cuff tears – A review and analysis of current evidence
Al-achraf Khoriati, Tony Antonios, Abhinav Gulihar, Bijayendra Singh
p236–240
Published online: February 2, 2019
Full-Text HTML | PDF | Supplemental Materials

Mid-term clinical outcome following rotator cuff repair using all-suture anchors
Baljinder Singh Dhinsa, Jagmeet Singh Bhamra, Mikel Aramberri-Gutierrez, Tony Kochhar
p241–243
Published online: February 27, 2018
Full-Text HTML | PDF

Role of platelet rich plasma in rotator cuff tendinopathy- clinical application and review of literature
Akshay Phadke, Bijayendra Singh, Nik Bakti
p244–247
Published online: October 23, 2018
Full-Text HTML | PDF

Biceps tenodesis versus biceps tenotomy for biceps tendinitis without rotator cuff tears
Syed Hassan, Vipul Patel
p248–256
Published online: January 4, 2019
Full-Text HTML | PDF | Supplemental Materials

Early versus delayed mobilization following rotator cuff repair
Nik Bakti, Tony Antonios, Akshay Phadke, Bijayendra Singh
p257–260
Published online: February 6, 2019
Full-Text HTML | PDF | Supplemental Materials

Diabetic and non-diabetic patients report equal symptom relief after arthroscopic capsular release of frozen shoulder
Johanne M. Lyhne, Jon R. Jacobsen, Søren J. Hansen, Carsten M. Jensen, Søren R. Deutch
p261–264
Published online: May 19, 2018
Full-Text HTML | PDF

Chronic adhesive capsulitis (Frozen shoulder): Comparative outcomes of treatment in patients with diabetes and obesity
Francisco Barbosa, Girish Swamy, Hatem Salem, Tim Creswell, Marius Espag, Amol Tambe, David Clark
p265–268

Browse By Issue
Vol. 10
March–April, 2019 Issue 2, p221-46(
List of Issues Go

Published online: February 27, 2018
Full-Text HTML | PDF

Basic Science

Human-induced pluripotent stem cells derived hematopoietic progenitor cells for treatment of hematopoietic failure among trauma hemorrhagic shock patients
Manoj Kumar, Sanjeev Bhoi, Keshava Sharma
p269–273
Published online: April 27, 2018
Full-Text HTML | PDF

Cadaveric study of the infrapatellar branch of the saphenous nerve: Can damage be prevented in total knee arthroplasty?
Sung R. Lee, Nicholas J.P. Dahlgren, Jackson R. Staggers, Cesar de Cesar Netto, Amit Agarwal, Ashish Shah, Sameer Naranje
p274–277
Published online: March 17, 2018
Full-Text HTML | PDF

Variations of extensor pollicis brevis tendon in Indian population: A cadaveric study and review of literature
Praveen Kumar Ravi, Jerina Tewari, Pravash Ranjan Mishra, Sujit Kumar Tripathy, Saurav Narayan Nanda, Amrit Gantaguru
p278–281
Published online: March 1, 2018
Full-Text HTML | PDF

Trauma

A systematic review and meta-analysis of complications in conversion arthroplasty methods for failed intertrochanteric fracture fixation
Daniel B. Dix, Ibukunoluwa B. Araoye, Jackson R. Staggers, Chee P. Lin, Ashish B. Shah, Amit Kumar Agarwal, Sameer M. Naranje
p282–285
Published online: February 26, 2018
Full-Text HTML | PDF

Effects of tranexamic acid on reducing blood loss in pelvic trauma: A randomised double-blind placebo controlled study
Vahid Monsef Kasmaei, Amin Javadi, Seyed Ahmad Naseri Alavi
p286–289
Published online: April 25, 2018
Full-Text HTML | PDF

Comparison of Intra- and Extramedullary Implants in Treatment of Unstable Intertrochanteric Fractures
Tahir Mutlu Duymus, Suavi Aydogmus, İbrahim Ulusoy, Tolga Kececi, Levent Adiyeke, Bahar Dernek, Serhat Mutlu
p290–295
Published online: April 13, 2018
Full-Text HTML | PDF

Comparison of complications and functional results of unstable intertrochanteric fractures of femur treated with proximal femur nails and cemented hemiarthroplasty
Angad Jolly, Rahul Bansal, Avadut Ramrao More, Manikanta Babu Pagadala
p296–301
Published online: March 22, 2018
Full-Text HTML | PDF

Mismatch of long Gamma intramedullary nail with bow of the femur: Does radius of curvature of the nail increase risk of distal femoral complications?
A. Shetty, P.M. Shenoy, R. Swaminathan
p302–304
Published online: January 1, 2018
Full-Text HTML | PDF

Does delay in surgical debridement increase the risk of infection in open tibia fractures in Saudi patients? A retrospective cohort study
Faisal Mohammedsaleh Konbaz, Suhail Saad Alassiri, Sami Ibrahim Al Eissa, Wael Sadek Taha, Fahad Hilal Al Helal, Rayed Meshal Al Jehani
p305–309
Published online: March 1, 2018
Full-Text HTML | PDF

Biomechanical evaluation of medial malleolus fractures treated with headless compression screws
Robert M. Corey, Lisa K. Cannada, Gary Bledsoe, Heidi Israel
p310–314
Published online: April 30, 2018
Full-Text HTML | PDF

Periarticular large bone defects treatment with ring external fixator
Thanase Ariyawatkul, Kamolporn Kaewpornsawan, Perajit Eamsobhana
p315–321
Published online: April 27, 2018
Full-Text HTML | PDF | Supplemental Materials

Orange city tapping nail: An innovative implant for humeral diaphyseal fractures
Maroti R. Koichade, Abhishek P. Bhalotia, Milind V. Ingle

p322–328
Published online: April 17, 2018
Full-Text HTML | PDF

Knee Arthroplasty

Bone stock reconstruction for huge bone loss using allograft-bones, bone marrow, and teriparatide in an infected total knee arthroplasty
Masataka Nishikawa, Shoichi Kaneshiro, Kenji Takami, Hajime Owaki, Takeshi Fuji
p329–333
Published online: March 10, 2018
Full-Text HTML | PDF

Obesity and racial characteristics drive utilization of total joint arthroplasty at a younger age
J. Logan Brock, Atul F. Kamath
p334–339
Published online: April 21, 2018
Full-Text HTML | PDF

Influence of early mobilization program on pain, self-reported and performance based functional measures following total knee replacement
Karvannan Harikesavan, R.D. Chakravarty, Arun G. Maiya
p340–344
Published online: May 4, 2018
Full-Text HTML | PDF

The effect of a 12 week prehabilitation program on pain and function for patients undergoing total knee arthroplasty: A prospective controlled study
Ebru Aytekin, Erhan Sukur, Nuran Oz, Atakan Telatar, Saliha Eroglu Demir, Nil Sayiner Caglar, Yusuf Ozturkmen, Levent Ozgonenel
p345–349
Published online: April 24, 2018
Full-Text HTML | PDF

Hip Arthroplasty

Low failure rate at short term for 40 mm heads and second generation triple annealed HCLPE liners in hybrid hip replacements
Rajkumar Thangaraj, Jan Kuiper, Ralph D. Perkins
p350–357
Published online: January 9, 2018
Full-Text HTML | PDF

Clinical and radiological evaluation of post total hip arthroplasty patients with acetabulum defect
Mohammad Zaim Chilmi, Yesa Adietra Suwandani, Dwikora Novembri Utomo, Jeffry Andrianus
p358–363
Published online: May 23, 2018
Full-Text HTML | PDF

Resection arthroplasty in radiation-induced osteonecrosis of the hip
Hyung Suk Kang, Taehun Kim, So Hak Chung
p364–367
Published online: March 6, 2018
Full-Text HTML | PDF

Mid-term results of an uncemented tapered femoral stem and various factors affecting survivorship
Mayank Vijayvargiya, Vivek Shetty, Kiran Makwana, Harpreet Singh Suri
p368–373
Published online: May 22, 2018
Full-Text HTML | PDF

Arthroscopy and Sports Medicine

Epidemiological profile of soccer-related injuries in a state Brazilian championship: An observational study of 2014–15 season
Jair José Gaspar-Junior, Giuliano Moreto Onaka, Fernando Sérgio Silva Barbosa, Paula Felippe Martinez, Silvio Assis Oliveira-Junior
p374–379
Published online: May 17, 2018
Full-Text HTML | PDF

General Orthopaedics

Current status and challenges of Additive manufacturing in orthopaedics: An overview
Mohd. Javaid, Abid Haleem
p380–386
Published online: May 23, 2018
Full-Text HTML | PDF

Musculoskeletal etymology: What's in a name?
Anuj Agrawal
p387–394
Published online: February 28, 2018
Full-Text HTML | PDF

Novel approach to improve patient satisfaction in the outpatient clinic setting
Chester J. Donnally III, Jose R. Perez, William H. Cade II, Julianne Muñoz, Clifton L. Page, Thomas M. Best, Lee D. Kaplan, Michael G. Baraga
p395–400
Published online: March 8, 2018
Full-Text HTML | PDF

Effectiveness of extra-corporeal shock wave therapy (ESWT) vs methylprednisolone injections in plantar fasciitis
Bibhuti Nath Mishra, Rishi Ram Poudel, Bibek Banskota, Babu Kaji Shrestha, Ashok Kumar Banskota
p401–405
Published online: March 1, 2018
Full-Text HTML | PDF

Surgical management of sternoclavicular joint septic arthritis
Alexander von Glinski, Emre Yilmaz, Valentin Rausch, Matthias Koenigshausen, Thomas Armin Schildhauer, Dominik Seybold, Jan Geßmann
p406–413
Published online: May 22, 2018
Full-Text HTML | PDF

Case Reports

Severe life-threatening hypersensitivity reaction to polidocanol in a case of recurrent aneurysmal bone cyst
Gaurav Gupta, Ram Sagar Pandit, Nameet Jerath, Ramani Narasimhan
p414–417
Published online: May 23, 2018
Full-Text HTML | PDF

"Banana patella", fibrous dysplasia of patella: A rare case report
Srikant Konchada, Debashish Mishra, Vijoy Kumar Sinha, Prita Pradhan, Abhijeet Ashok Salunke
p418–421
Published online: May 25, 2018
Full-Text HTML | PDF

Technical tips

Use of high-speed burr and water-based lubricant in the partial removal of surgical plates: A technique Guide
Jon E. Hammarstedt, Grigory E. Gershkovich, Daniel P. Mass
p422–426
Published online: May 31, 2018
Full-Text HTML | PDF

Safe corridor for iliosacral and trans-sacral screw placement in Indian population: A preliminary CT based anatomical study
Vivek Trikha, Sahil Gaba, Arvind Kumar, Samarth Mittal, Atin Kumar
p427–431
Published online: January 15, 2018
Full-Text HTML | PDF

Safe corridor for fibular transfixation wire in relation to common peroneal nerve: A cadaveric analysis
Ranjit Kumar Baruah, S V Harikrishnan, Jishnu Prakash Baruah
p432–438
Published online: May 29, 2018
Full-Text HTML | PDF

BMCRI method for measuring cup anteversion after total hip replacement
Manjunath K.S., Gopalakrishna K.G., Hemanth H.P.
p439–458
Published online: February 26, 2018
Full-Text HTML | PDF

Letter to Editor

Letter to the Editor
Ankur Sharma, Abhishek Mishra
p459
Published online: May 14, 2018
Full-Text HTML | PDF

Select All View Abstracts | Export Citations | Email a Colleague | Add to Reading List

ELSEVIER Copyright © 2019 Elsevier Inc. All rights reserved. | Privacy Policy | Terms & Conditions | Use of Cookies | About Us | Help & Contact | Accessibility
The content on this site is intended for health professionals.

We use cookies to help provide and enhance our service and tailor content and ads. By continuing you agree to the use of cookies.
Advertisements on this site do not constitute a guarantee or endorsement by the journal, Association, or publisher of the quality or value of such product or of the claims made for it by its manufacturer.

RELX Group™

Journal of Clinical Orthopaedics and Trauma 10 (2019) 358–363

Contents lists available at ScienceDirect

Journal of Clinical Orthopaedics and Trauma

journal homepage: www.elsevier.com/locate/jcot

Clinical and radiological evaluation of post total hip arthroplasty patients with acetabulum defect

Mohammad Zaim Chilmi*, Yesa Adietra Suwandani, Dwikora Novembri Utomo, Jeffry Andrianus

Department of Orthopedics and Traumatology, Dr. Soetomo General Hospital / Universitas Airlangga, Surabaya, Indonesia

ARTICLE INFO

Article history:
Received 28 March 2018
Received in revised form 9 April 2018
Accepted 19 May 2018
Available online 19 May 2018

Keywords:
acetabulum
Defect
Total hip arthroplasty

ABSTRACT

Background: Total Hip Arthroplasty (THA) is one of many therapies given to hip joint injury patients. The main indication for THA in elderly patients is degenerative diseases of the joints. One of the difficulties encountered in this THA procedure is to overcome the acetabulum deficiency, with Paprosky Classification. This study aims to evaluate patients with acetabulum defect that have undergone THA at Dr. Soetomo Hospital in 2014–2016.
Methods: This was an observational retrospective study with descriptive analysis. The sample amount was 20 patients, from 80 patients who had THA procedure. Patients were evaluated based on the wear from acetabulum, migration from a cup, the presence of bone loss, heterotopic ossification, and also clinical condition based on Harris Hip Score. The presented results were analyzed by using Kruskal-Wallis on SPSS 19.0 for Windows Program.
Results: Hypothesis testing was performed on THA patients based on acetabulum defect type I, II, and III in one, two, and three years after surgery respectively. Massin Score resulted no differences with $p = 0.156$, $p = 0.574$, and $p = 0223$. Bone Loss Classification resulted no differences with $p = 0.296$, $p = 0.287$, and $p = 0223$. No difference on Wear Rate with $p = 0.072$, $p = 0.110$, and $p = 0.325$. There was no difference of Harris Hip Score with $p = 0.320$, $p = 0.082$, and $p = 0.472$.
Conclusion: There were no significant differences in radiological evaluation of the Migration Rate, Heterotopic Ossification or Bone Loss, Wear Rate, and on clinical evaluation of Harris Hip Score in all three groups of evaluated acetabulum defects.

© 2018

1. Introduction

Total Hip Arthroplasty (THA) is one of many therapies given to hip joint injury patients, that can increase patient's quality of life, decrease pain, and provide a functional result.[1] Degenerative diseases of the joints, including osteoarthritis or necrosis of the femoral head with major dysfunction, or sequel after proximal femoral fracture are some of the main indication for THA in elderly patients.[2] THA demand is increasing as the number of elderly patients increases, and the incidence of femoral neck fracture increases in elderly patients.[3] Indonesia is in the top 10 countries with large elderly population.[4] However all operative procedures have its own risks, including postoperative complications. With the increasing number of patients that undergo THA procedure, the number of patients who experienced a complication that needs revision will also increase (Fig. 1).

Osteolysis is a response to debris caused by wear. First, debris particulates can be formed from 3 types of wear: adhesive wear, abrasive wear, and third body wear. Adhesive wear is the most important wear in the osteolytic process. Polyethylene attaches microscopically to the prosthesis and disengaged debris. Abrasive wear occurs because of friction, looks like grated, on the prosthesis that causes particulates. While third body wear occurs because of the foreign body particles in joint space that cause abrasion and wear. Osteolysis is also triggered by macrophages. With the activation of macrophages, another macrophage will be called, and secrete osteolytic factors (cytokines), including Tumor Necrosis Factor-α (TNF-α), Transforming Growth Factor-β (TGF-β), osteoclast activating factor, oxide radicals, hydrogen, peroxide, acid phosphatase, interleukins (IL- 1, IL-6), and prostaglandins. Then there will be osteoclast and osteolysis activation because of the increase of TNF-α which will increase Receptor Activator of Nuclear Factor κ B (RANK), the increase of Vascular Endothelial Growth Factor (VEGF) with Ultra-High-Molecular-Weight Polyethylene (UHMWPE) that will

* Corresponding author.
E-mail addresses: m-zaim-chilmi@fk.unair.ac.id (M.Z. Chilmi), suwandani2@gmail.com (Y.A. Suwandani), dwikora-novembri-u@fk.unair.ac.id (D.N. Utomo), drjuportho@icloud.com (J. Andrianus).

https://doi.org/10.1016/j.jcot.2018.05.013
0976-5662/© 2018

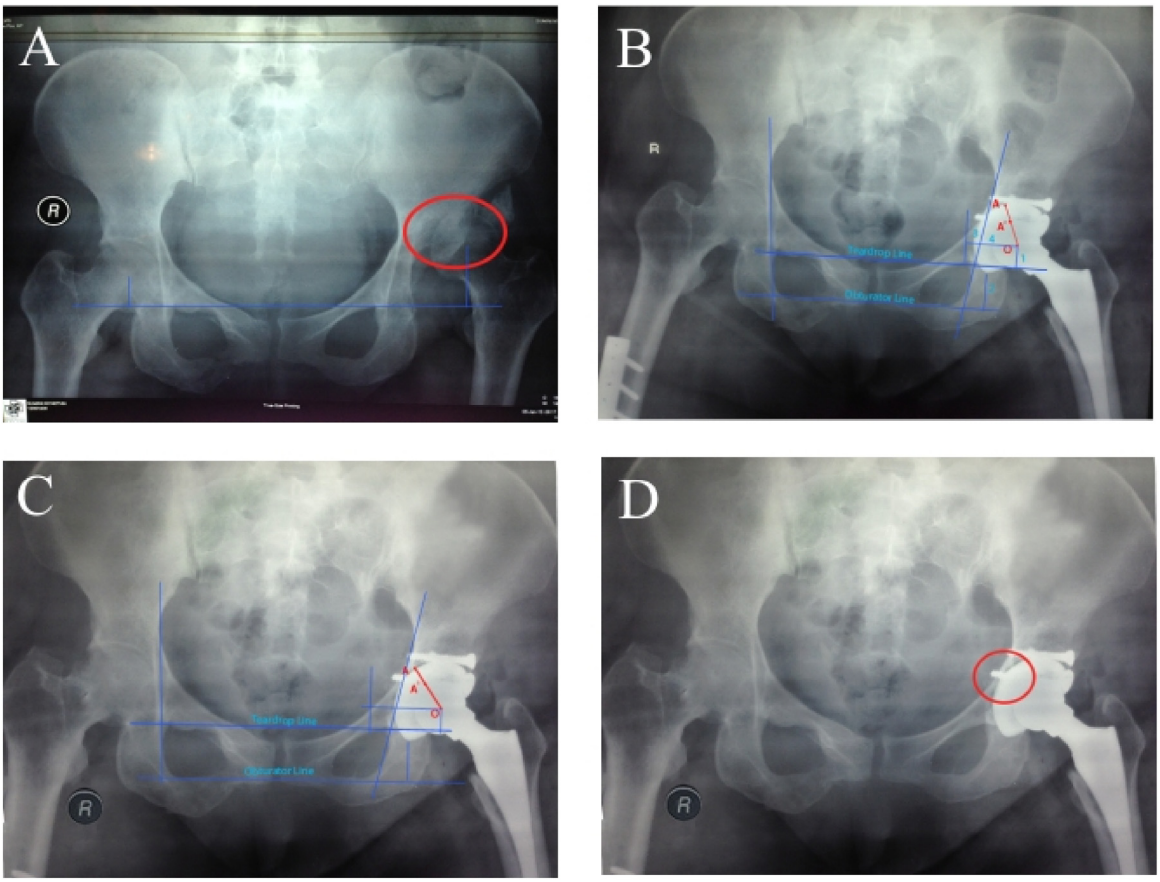

Fig. 1. (A) Preoperative X-ray of a patient with Type III Paprosky defect, marked by a significant dome destruction, with migration from center femoral head to superolateral. (B) Postoperative X-ray after THA procedure performed. Measurements to know migration of acetabulum components were (1) vertical center length from cup to teardrop line, (2) vertical length of lower border cup with obturator line, (3) horizontal length between centers from cup to vertical line of teardrop, and (4) horizontal length from center cup to Kohler's Line. (C) X-ray evaluation after 3 years of surgery. The AA' line was measured and compared the difference with AA' line from postoperative X-ray to know Wear Rate from the acetabulum. (D) X-ray evaluation after 3 years of surgery. There was radiolucent area in 50% interface of bone-cement showed possible loosening.

activate RANK and Receptor Activator of Nuclear Factor κ B Ligand (RANKL), and micromotion from prosthesis. RANKL may mediate bone resorption, also the increased transcription of RANK and RANKL genes will increase osteolysis. Then osteolysis around the prosthesis will cause a micromotion, which will lead to increased wear particle and further make the process of loosening prosthesis due to the dissemination of debris particulates worse. Hydrostatic pressure causes the dissemination of debris into effective joint space. Increased hydrostatic pressure is caused by an inflammatory response. Dissemination of debris into effective joint space will make osteolysis process wider.

A study in 2009 by Bozic found that the most frequent revision of the THA procedure was the revision of all components.[5] The most common cause of the revision was dislocation or instability (22.5%), followed by mechanical loosening (19.7%), and infection (14.8%).[5] It was found that revision from THA is more common than in Total Knee Arthroplasty,[6] with dislocation and mechanical loosening that is more frequent in THA than in Total Knee Arthroplasty.[6]

The loosening aseptic from cemented acetabular component needs revision and even re-revision of the component.[7] Beckenbaugh found the signs of loosening in 24% of cases that are evaluated, presumably due to the quality and fixation of the cement, and not because of the implant position.[8] While Schmalzried found there was a histological bone resorption process in THA that showed a macrophage containing polyethylene debris.[9] The study showed that debris may extend to all areas that were in contact with a synovial fluid, including periprosthetic area around the implant.[9]

One of the difficulties encountered in this THA procedure is to overcome the acetabulum deficiency.[10] Bone loss or acetabulum deficiency may occur in cases of hip arthroplasty revision because of aseptic loosening, as well as in primary cases after post infection or sequel post-trauma,[11] or in the treatment of the bone tumor.[12] The deficiency of the bone stock acetabulum is a technical challenge, because of the reduced support from anterior and posterior collum, and also medial wall and deficiency from the dome. In addition, the more bone loss, the more difficult it is to get the bone for the placement of the uncemented cup and the screw for fixation. Limited contact of the host bone with acetabular implant component will also inhibit osteointegration and long-term biologic fixation.[12] Paprosky is one of the most commonly used classifications for acetabulum defect, which is using assessment from radiological and clinical findings. Paprosky also provides treatment recommendations based on their classification.[13]

THA itself has many postoperative complications, one of the most common is heterotopic ossification,[14] dislocations or subluxation, loosening of the acetabular or femoral components, ischiadica or femoral nerve palsy, and surgical wound infection.[15] In THA revision case, Gie suggested that postoperative outcomes in patients with impacted cancellous bone graft were better than the ones using bone cement, and the result was equivalent to primary arthroplasty.[16]

As in Dr. Soetomo Hospital Surabaya has done many acetabuloplasty and THA procedure in various cases, such as hip joint osteoarthritis, either caused by sequel from post-trauma in the past or due to hip joint degeneration, or other backgrounds with various condition of preoperative acetabulum defect; therefore it is necessary to do clinical and radiological evaluation in patients with acetabulum defect that have undergone primary total hip arthroplasty in Dr. Soetomo Hospital Surabaya.

This study aims to evaluate patients with acetabulum defect that have undergone THA at Dr. Soetomo Hospital in 2014–2016 with radiological and clinical parameters. The more specific goal in this study is to evaluate complication emerging postoperatively in patients with acetabulum defect that have undergone THA in Dr. Soetomo Hospital by evaluating the wear from the acetabulum, migration from a cup, the presence of bone loss and heterotopic ossification, and also clinical condition based on Harris Hip Score.

2. Methods

This was an observational retrospective study with descriptive analysis. The subject of this study was patients with acetabulum defect that went on THA procedure at Dr. Soetomo Hospital Surabaya in 2014 until 2016. The inclusion criteria in this study are patients of Orthopedic and Traumatology Department at Dr. Soetomo Hospital Surabaya who went on Total Hip Arthroplasty in January 2014 until December 2016, patients were alive at the time of research, the location of patients could be traced for evaluation, and patients accepted to have the clinical and radiologic evaluation. The exclusion criteria in this study are patients who were unwilling to have evaluation, patients were deceased, the location of patients could not be traced (loss of control), and patients who had surgery or other trauma on lower extremity neuromusculoskeletal or vertebrae that do not have the association with complication of THA.

The independent variable in this study is the type of acetabulum defect based on Paprosky classification and time interval between post operation and evaluation. The dependent variables in this study are the clinical condition of patient based on Harris Hip Score; including pain, function, deformity, motion and the radiologic result of pelvic X-Ray; including migration of acetabular component, wear rate of acetabular component, bone loss or heterotropic ossification in the periacetabular region. The confounding variables are age and sex.

Evaluation was divided into clinical and radiological. Clinical evaluation was done with Harris Hip Score,[17] which can evaluate based on rating scale with a maximum score of 100 points, including pain, function, deformity, and motion. The function was divided into daily activity and gait.[18]

Radiological evaluation was performed based on anteroposterior X-ray of pelvic after surgery, interval radiography if available, and final examination. Correction of magnification was done with measurable concentric circle template, and femoral head diameter of implant was compared with radiography measurement.[19]

Wear rate from acetabular component was defined with Livermore technique,[20] by measuring the diameter of acetabular cup at the shortest line which connects midline from femoral head to acetabular cup-cement interface. The measurement was done on the latest photo, compared with post-operation, using caliper with 0.025 mm accuracy. The difference determines linear migration from femoral head, considering the magnification difference between both photos.

Bone loss or cystic area in the periacetabular region was noted. If there was heterotopic ossification, it would be graded in Brooker classification,[21],[14] which divided into 4 classes. Class 1 is described as islands of bone within the soft tissues about the hip. Class 2 includes bone spurs originating from the pelvis or proximal end of the femur, leaving at least 1 cm between opposing bone surfaces. Class 3 consists of bone spurs originating from the pelvis or proximal end of the femur, reducing the space between opposing bone surfaces to less than 1 cm. Class 4 shows apparent bone ankylosis of the hip.[14]

The first step of this study is the data were collected by recording all cases of total hip arthroplasty from operation room logbook, update collection and database of Lower Extremity Division at Dr. Soetomo Hospital Surabaya in 2014 until 2016. Then data were grouped by preoperative radiology result based on the condition of acetabulum defect as in Paprosky classification. Home visit in each group to evaluate clinical condition with Harris Hip Score. The last step of this study is to evaluate the radiology result with anteroposterior pelvic X-ray at Dr. Soetomo Hospital or if not possible, the examination was done in a laboratory with radiology equipment in the closest area of patient origin.

Descriptive analysis was performed using SPSS 19.0 program. Before doing the analysis, the data had been processed with cleaning, coding, tabulation, and computing input.

3. Results

In this research, there were 82 patients who had THA procedure at Dr. Soetomo Hospital in 2014–2016, with the proportion of 26 patients in 2014, 32 patients in 2015, and 24 patients in 2016. From that population, 20 patients could be evaluated, divided into 4 patients who had THA surgery in 2014, 6 patients in 2015, and 10 patients in 2016. Distribution frequency of patients evaluation who had THA is shown in Table 1.

In the distribution based on Paprosky Classification, 9 patients categorized on type 1 (45%). Most of evaluation time interval between postoperative and evaluation was 1 year or in the group undergoing THA surgery in 2016 were 10 patients (50%). In the distribution based on the migration of acetabular component with Massin Criteria, the most of it was possible loosening, about 11 patients (55%). Based on bone loss and heterotopic ossification with Brooker Classification, 15 patients (75%) categorized on class 1. And in the Harris Hip Score, patients categorized on excellent (50%) and good (50%).

Hypothesis testing was performed on THA patients in 2016 (1 year after surgery), to find differences in clinical evaluation based on Harris Hip Score and radiological evaluation based on

Table 1
Distribution frequency of patients who had THA procedure.

Parameter	N	(%)
Paprosky Classification		
Type I	9	45
Type II	7	35
Type III	4	20
Time Interval of Evaluation		
1 year	10	50
2 years	6	30
3 years	4	20
Migration of acetabular component based on Massin Criteria		
No loosening	9	45
Probable loosening	0	–
Possible loosening	11	55
Definitive loosening	0	–
Bone loss and heterotopic ossification based on Brooker Classification		
Class 1	15	75
Class 2	5	25
Class 3	0	–
Class 4	0	–
Harris Hip Score Classification		
Excellent (90–100)	10	50
Good (80–89)	10	50
Fair (70–79)	0	–
Poor (≤69)	0	–

Massin Criteria, Wear Rate, and Bone Loss Classification according to Paprosky Classification. Kruskal-Wallis test was done and showed there were no differences on Harris Hip Score (p = 0.320), Massin Score (p = 0.156), Bone Loss Classification (p = 0.296), Wear Rate (p = 0.072) based on acetabulum defect type I, type II, and type III (Tables 2–5).

The same hypothesis testing was performed on THA patients in 2015 (2 years after surgery). Kruskal-Wallis test was done and showed there were no differences on Harris Hip Score (p = 0.082), Massin Score (p = 0.574), Bone Loss Classification (p = 0.287), Wear Rate (p = 0.110) based on acetabulum defect type I, type II, and type III.

Then, hypothesis testing was performed on THA patients in 2014 (3 years after surgery). Kruskal-Wallis test was done and showed there were no differences on Harris Hip Score (p = 0.472), Massin Score (p = 0.223), Bone Loss Classification (p = 0.223), Wear Rate (p = 0.325) based on acetabulum defect type I, type II, and type III.

4. Discussion

In this research, from 20 patients who had THA and could be evaluated, 10 of them had the procedure within last one year. According to radiological evaluation, 9 patients (45%) with acetabulum defect categorized in type 1 Paprosky classification.

Hypothesis test performed on patient which had THA in 2016 (a year post surgery), 2015 (two years postsurgery), and 2014 (three years postsurgery) to find difference result in clinical evaluation

Table 2
Hypothesis Test of Clinical Evaluation Based on Harris Hip Score.

Paprosky Classification	1 year				2 years				3 years			
	Excellent		Good		Excellent		Good		Excellent		Good	
	n	%	n	%	n	%	n	%	n	%	n	%
Type I	3	60	2	40	3	100	0	0	1	100	0	0
Type II	2	66.7	1	33.3	0	0	2	100	1	50	1	50
Type III	0	0	2	100	0	0	1	100	0	0	1	100
Total	5	50	5	50	3	50	3	50	2	50	2	50
P value	0.320				0.082				0.472			

*Kruskall-Wallis Test.

Table 3
Hypothesis Test of Radiological Evaluation Based on Massin Score.

Paprosky Classification	1 year				2 years				3 years			
	No Migration		Possible		No Migration		Possible		No Migration		Possible	
	n	%	n	%	n	%	n	%	n	%	n	%
Type I	4	80	1	20	2	80	1	20	1	100	0	0
Type II	1	33.3	2	66.7	1	50	1	50	0	0	2	100
Type III	0	0	2	100	0	0	1	100	0	0	1	100
Total	5	50	5	50	3	50	3	50	1	25	3	75
P value	0.156				0.574				0.223			

*Kruskall-Wallis Test.

Table 4
Hypothesis Test of Radiological Evaluation Based on Bone Loss Classification.

Paprosky Classification	1 year				2 years				3 years			
	Class I		Class II		Class I		Class II		Class I		Class II	
	n	%	n	%	n	%	n	%	n	%	n	%
Type I	5	100	0	0	2	66.7	1	33.3	1	100	0	0
Type II	2	66.7	1	33.3	2	100	0	0	2	100	0	0
Type III	1	50	1	50	0	0	1	100	0	0	1	100
Total	5	50	5	50	4	66.7	2	33.3	3	75	1	25
P value	0.296				0.287				0.223			

*Kruskall-Wallis Test.

Table 5
Hypothesis Test of Radiological Evaluation Based on Wear Rate.

Paprosky Classification	1 Year		2 Years		3 Years	
	n	Wear Rate	n	*Wear Rate*	n	*Wear Rate*
Type I	5	0.1 (0.1–0.2)	3	0.1 (0.1–0.2)	1	0.3 (0.3–0.3)
Type II	3	0.2 (0.1–0.2)	2	0.5 (0.4–0.6)	2	0.6 (0.5–0.7)
Type III	2	0.3 (0.3–0.3)	1	0.9 (0.9–0.9)	1	0.7 (0.7–0.7)
P value	0.072			0.110	0.325	

*Kruskall-Wallis Test. Data presented in median (minimum-maximum).

determined by Harris Hip score and radiological evaluation determined by Massin Criteria, Wear Rate, and Bone Loss Classification in defect based on Paprosky Classification.

We found that there is no difference between radiological evaluation determined by Massin Score on acetabulum defect type I, II, and III in a year after surgery (p = 0.156), 2 years after surgery (p = 0.574), and three years after surgery (p = 0223).

In 1995, Stocks et al. described that initial migration in two years post THA can predict migration in advance stage.[22] It was also found that migration level can be related with continued aseptic loosening event (until 6.5 years). The acetabular cup that migrates rapidly due to implant failure, can lead faster aseptic loosening than without implant failure. This finding is similar to femoralis prosthesis report. From any measurement that has been used, the strongest predictor of continued aseptic loosening is the average rate of migration of acetabulum in the first two years.

Currently, there is no study available that associate migration rate with acetabulum defect through Paprosky classification. Our study showed that there is no significant difference among three groups of Paprosky Classification. It may be caused by the administered therapy, as Paprosky Classification recommends therapy such as bone graft according to initial defect. Therefore, it is difficult to use Paprosky classification as a predictor of prognosis in post-THA patients due to different treatment in sample of the population in this study.

Kruskal-Wallis test on Bone Loss Classification showed no difference between radiological evaluation on acetabulum defect type I, II, and III in a year after surgery (p = 0.296), 2 years after surgery (p = 0.287), and three years after surgery (p = 0223).

Heterotopic Ossification (HO) is associated with arthroplasty especially in the hip joint. Iorio et al reported that HO after arthroplasty procedure had an incidence rate from 2% to 90% with an incidence of severe HO from 3% to 55% depending on the population, risk factors, prophylaxis, and the surgical techniques used.[23]

There has been no study comparing HO (Bone Loss Classification) with acetabulum defect through Paprosky classification. In our study, there is no significant difference with HO among Paprosky Classification. It may be due to many risk factors that give effect to bone loss, such as demography, history of osteoarthritis, the variation of surgical approach, operation time, and loss of blood.[24]

A recent study about HO development after arthroplasty surface replacement showed incidence ranged from 26% to 60%.[23] Randomized clinical trial comparing SRA and THA found an increase six times greater in severe HO with SRA[3] although the overall incidence of HO was not statistically significant (44% for SRA, 31% for THA; p = 0.057).[25,26]

Shapiro-Wilk test on radiological evaluation data of Wear Rate gives p-value <0.05, it showed that data is not distributed normally. Kruskal-Wallis was tested on radiological evaluation and showed no difference on Wear Rate type I, type II and type III acetabulum defect for 1 year after surgery (p = 0.072), 2 years after surgery (p = 0.110), and 3 years after surgery (p = 0.325).

Kreder et al found that fracture of acetabulum posterior wall with associating fractures on posterior collum causes acetabulum defect has a poor prognosis as increased risk of hip arthritis. The anatomical reduction is not enough to revert the function to normal.[27] The increased risk of arthritis is related to another study conducted by Gallo stating that the acetabulum wear rate has a strong correlation with 4 (four) major factors, (1) the relative position of acetabular cup against the Kohler line; (2) increased acetabular cup abduction angle; (3) history of inflammatory and traumatic arthritis; and (4) body height. The third point is the history of pelvic arthritis into a linkable red thread, although in the study the relative position of the acetabular cup against the Kohler line is the strongest factor in predicting an increase in wear rate.[28]

Later in the study, Gallo et al concluded that there are three factors associated with the formation of bone defects in the acetabulum, i.e. wear rate, higher acetabulum cup location, and body height. Among the three factors, the strongest factor is the wear rate. However, no research has been done to associate the acetabulum defect by Paprosky classification by changing the wear rate. This is most likely caused by the assumption that the wear rate is damaging the integrity of the acetabulum, causing a defect, not the other way around. In this research, there is no significant correlation between acetabulum defect and wear rate. This is most likely due to the use of bone graft which affects the clinical outcome in which defects obtained before surgery are overcome so that no red thread can be drawn as a conclusion.[28]

Clinical evaluation of patients undergoing THA was assessed using Harris Hip Score. In the distribution based on Harris Hip Score, the most distribution data is the excellent and good results, 10 patients of each (50%). Statistical test results of the Kruskal-Wallis test non-parametric test were tested on Harris Hip Score's result of the clinical evaluation result. There was no difference of clinical result of Harris Hip Score on type I, type II and type III acetabulum defect for 1 year after surgery (p = 0.320), 2 years after surgery (p = 0.082), and 3 years after surgery (p = 0.472).

This insignificant difference is different from the study conducted by Ho who also found clinical improvement findings but differed in terms of significance. In the study, patients underwent THA with bone graft with indication of acetabulum defects. The clinical improvement of the study was conducted using Visual Analogue Pain Scale (VAS) and Harris Hip Score (HHS). The mean VAS of the study fell from 9.5 to 3.3 (p = 0.005) with mean HHS increased from 32.7 to 73.9 (p = 0.005).[29] This study was supported by findings Jialiang T who received clinical improvement of pain with mean HHS score of 29 (range 20–41) before surgery to 81 (range 73–89) after surgery.[30] A study conducted by Philippe also found similar findings of an increase in HHS score from 36 to 71.1 with $p < 0.001$ in other words significant.[31]

We conclude that there were no significant differences in radiological evaluation of the Migration Rate, Heterotopic Ossification or Bone Loss, Wear Rate, and on clinical evaluation of Harris Hip Score in all three groups of evaluated acetabulum defects. Therefore, Paprosky Classification alone was difficult to use as a predictor of prognosis in post-THA patients regardless of other treatment factors in patients either during surgery or postoperative. We suggest for future investigation with more patient and more time for evaluation.

Conflict of interest statement

The author(s) have no conflicts of interest relevant to this article.

Funding/SupportStatement

This research did not receive any specific grant from funding agencies in the public, commercial, or not-for-profit sectors, and no material support of any kind was received.

Acknowledgments

None.

References

1. Freeman MA, Plante-Bordeneuve P. Early migration and late aseptic failure of proximal femoral prostheses. *J Bone Jt Surg Br*. 1994;76:432–438.
2. Ekelund A, Rydell N, Nilsson OS. Total hip arthroplasty in patients 80 years of age and older. *Clin Orthop Relat Res*. 1992;101–106.
3. Wallace WA. The increasing incidence of fractures of the proximal femur: an orthopaedic epidemic. *Lancet*. 1983;1:1413–1414.
4. Ferdiansyah Mahyudin LW, Hermawan Hendra. Biomaterials in orthopaedics. In: Ferdiansyah Mahyudin HH, ed. *Biomaterials and medical devices - a perspective from an emerging Country*. Switzerland: Springer Link; 2016.

5. Bozic KJ, Kurtz SM, Lau E, Ong K, Vail TP, Berry DJ. The epidemiology of revision total hip arthroplasty in the United States. *J Bone Jt Surg Am*. 2009;91:128–133.
6. Bozic KJ, Kamath AF, Ong K, et al. Comparative epidemiology of revision arthroplasty: failed THA poses greater clinical and economic burdens than failed TKA. *Clin Orthop Relat Res*. 2015;473:2131–2138.
7. Paprosky WG, Magnus RE. Principles of bone grafting in revision total hip arthroplasty. Acetabular technique. *Clin Orthop Relat Res*. 1994;147–155.
8. Beckenbaugh RD, Ilstrup DM. Total hip arthroplasty. *J Bone Jt Surg Am*. 1978;60:306–313.
9. Schmalzried TP, Jasty M, Harris WH. Periprosthetic bone loss in total hip arthroplasty. Polyethylene wear debris and the concept of the effective joint space. *J Bone Jt Surg Am*. 1992;74:849–863.
10. Ibrahim MS, Raja S, Haddad FS. Acetabular impaction bone grafting in total hip replacement. *Bone Jt J*. 2013;95-B:98–102.
11. Shon WY, Santhanam SS, Choi JW. Acetabular reconstruction in total hip arthroplasty. *Hip Pelvis*. 2016;28:1–14.
12. Nieminen J, Pakarinen TK, Laitinen M. Orthopaedic reconstruction of complex pelvic bone defects. Evaluation of various treatment methods. *Scand J Surg*. 2013;102:36–41.
13. Paprosky WG, Perona PG, Lawrence JM. Acetabular defect classification and surgical reconstruction in revision arthroplasty. A 6-year follow-up evaluation. *J Arthroplast*. 1994;9:33–44.
14. Hug KT, Alton TB, Gee AO. Classifications in brief: brooker classification of heterotopic ossification after total hip arthroplasty. *Clin Orthop Relat Res*. 2015;473:2154–2157.
15. Coventry MB, Beckenbaugh RD, Nolan DR, Ilstrup DM. 2,012 total hip arthroplasties. A study of postoperative course and early complications. *J Bone Jt Surg Am*. 1974;56:273–284.
16. Gie GA, Linder L, Ling RS, Simon JP, Slooff TJ, Timperley AJ. Impacted cancellous allografts and cement for revision total hip arthroplasty. *J Bone Jt Surg Br*. 1993;75:14–21.
17. Harris WH. Traumatic arthritis of the hip after dislocation and acetabular fractures: treatment by mold arthroplasty. An end-result study using a new method of result evaluation. *J Bone Jt Surg Am*. 1969;51:737–755.
18. Soderman P, Malchau H. Is the Harris hip score system useful to study the outcome of total hip replacement? *Clin Orthop Relat Res*. 2001;189–197.
19. Schulte KR, Callaghan JJ, Kelley SS, Johnston RC. The outcome of Charnley total hip arthroplasty with cement after a minimum twenty-year follow-up. The results of one surgeon. *J Bone Jt Surg Am*. 1993;75:961–975.
20. Livermore J, Ilstrup D, Morrey B. Effect of femoral head size on wear of the polyethylene acetabular component. *J Bone Jt Surg Am*. 1990;72:518–528.
21. Brooker AF, Bowerman JW, Robinson RA, Riley Jr LHJr. Ectopic ossification following total hip replacement. Incidence and a method of classification. *J Bone Jt Surg Am*. 1973;55:1629–1632.
22. Stocks GW, Freeman MA, Evans SJ. Acetabular cup migration. Prediction of aseptic loosening. *J Bone Jt Surg Br*. 1995;77:853–861.
23. Iorio R, Healy WL. Heterotopic ossification after hip and knee arthroplasty: risk factors, prevention, and treatment. *J Am Acad Orthop Surg*. 2002;10:409–416.
24. Cohn RM, Schwarzkopf R, Jaffe F. Heterotopic ossification after total hip arthroplasty. *Am J Orthop (Belle Mead NJ)*. 2011;40:E232–235.
25. Back DL, Smith JD, Dalziel RE, Young DA, Shimmin A. Incidence of heterotopic ossification after hip resurfacing. *ANZ J Surg*. 2007;77:642–647.
26. Rama KR, Vendittoli PA, Ganapathi M, Borgmann R, Roy A, Lavigne M. Heterotopic ossification after surface replacement arthroplasty and total hip arthroplasty: a randomized study. *J Arthroplasty*. 2009;24:256–262.
27. Kreder HJ, Rozen N, Borkhoff CM, et al. Determinants of functional outcome after simple and complex acetabular fractures involving the posterior wall. *J Bone Jt Surg Br*. 2006;88:776–782.
28. Gallo J, Havranek V, Zapletalova J. Risk factors for accelerated polyethylene wear and osteolysis in ABG I total hip arthroplasty. *Int Orthop*. 2010;34:19–26.
29. Ho KT, Wong KY. Use of structural bone graft for reconstruction of acetabular defects in primary total hip arthroplasty: a 13-year experience. *J Orthop Trauma Rehabil*. 2016;20:30–34.
30. Jialiang TL, Luyin S, Hu RY, Xiaobin T. Cementless total hip arthroplasty with structural allograft for massive acetabular defect in hip revision. *Chin J Traumatol*. 2014;17:331–334.
31. Philippe R, Gosselin O, Sedaghatian J, Dezaly C, Roche O, Sirveaux F, Mole D. Acetabular reconstruction using morselized allograft and a reinforcement ring for revision arthroplasty with paprosky type II and III bone loss: survival analysis of 95 hips after 5 to 13 years. *Orthop Traumatol Surg Res*. 2012;98:129–137.