

EFFECT OF VITAMIN E (α -TOCOPHEROL) ADMINISTRATION ON SPERM MOTILITY AND MORPHOLOGY OF SPRAGUE DAWLEY STRAIN RATS AFTER CISPLATIN TREATMENT

¹Dimas Visa Aditya, ¹Tarmono Djojodimedjo, ¹Doddy M. Soebadi.

¹Department of Urology, Faculty of Medicine/Universitas Airlangga, Soetomo General Hospital, Surabaya.

ABSTRACT

Objective: To evaluate the protective effects of vitamin E α -tocopherol isomer against the toxicity of cisplatin on sperm motility and morphology in Sprague Dawley rats. **Material & Methods:** Twenty-four rats were grouped into four groups ($n=6$). The control group (CN) was injected with normal saline, second group (CP) was injected with cisplatin, the third group (P1) was injected with cisplatin and vitamin E 50 mg/kgBW for 7 weeks P.O, the fourth group (P2) was injected with cisplatin and vitamin E 200 mg/kgBW for 7 weeks P.O. Vitamin E was given from 3 weeks before cisplatin injection and 4 weeks following cisplatin injection. At 7th week, all the samples were undergoing bilateral orchidectomy. Vitamin E that being used in this study was α -tocopherol isomer. **Results:** Cisplatin decreased motility and morphology of spermatozoa significantly against controls. Vitamin E 50 mg/kgBW and 200 mg/kgBW significantly increased motility of spermatozoa ($p<0.05$) compared to those in the cisplatin group only. Vitamin E 50 mg/kgBW, and 200 mg/kgBW did not have a significant difference in spermatozoa motility compare to control groups. Vitamin E 50 mg/kgBW and 200 mg/kgBW could increase the spermatozoa morphology significantly compare to those cisplatin only group. Vitamin E 50 mg/kgBW, and 200 mg/kgBW did not have a significant difference in spermatozoa morphology compared to control groups. **Conclusion:** α -tocopherol 50 mg/kgBW and 200 mg/kgBW provided a same protective effect against spermatozoa damage especially in motility and morphology aspect due to cisplatin exposure. Therefore, in this study it was more recommended to use α -tocopherol in 50 mg/kgBW dose than 200 mg/kgBW.

Keywords: Vitamin E, spermatozoa, motility, morphology, cisplatin.

ABSTRAK

Tujuan: Untuk mengevaluasi efek protektif dari isomer α -tocopherol vitamin E terhadap toksisitas cisplatin pada motilitas sperma dan morfologi pada tikus Sprague Dawley. **Bahan & Cara:** Dua puluh empat sampel dibagi secara acak menjadi 4 kelompok ($n=6$). Kelompok kontrol (CN) mendapat injeksi normal saline 0.9% 1 cc, kelompok kedua (CP) diberikan injeksi cisplatin 5 mg/kgBB, kelompok ketiga (P1) diberikan injeksi cisplatin 5 mg/kgBB dan vitamin E 50 mg/kgBB, kelompok keempat (P2) diberikan vitamin E 200 mg/kgBW selama 7 minggu per sonde dan injeksi cisplatin 5 mg/kgBW di minggu ketiga, 1x i.p. Vitamin E diberikan dari 3 minggu sebelum injeksi cisplatin dan 4 minggu sesudahnya. Di akhir minggu ke 7 dilakukan orkidektomi analisa sperma. Vitamin E yang digunakan pada penelitian ini adalah isomer α -tocopherol. **Hasil:** Cisplatin menurunkan motilitas dan morfologi yang signifikan terhadap kelompok kontrol. Vitamin E 50 mg/kgBB dan 200 mg/kgBB meningkatkan motilitas sel sperma secara signifikan ($p<0.05$) dibandingkan dengan kelompok dengan perlakuan cisplatin saja. Pada aspek morfologi sperma, Vitamin E 50 mg/kgBB dan 200 mg/kgBB meningkatkan morfologi sperma secara signifikan dibandingkan dengan kelompok yang hanya diberikan cisplatin. Vitamin E 50 mg/kgBB dan 200 mg/kgBB tidak memiliki perbedaan yang signifikan terhadap peningkatan morfologi sperma dibandingkan dengan kelompok kontrol. **Simpulan:** α -tocopherol 50 mg/kgBB dan 200 mg/kgBB memberikan efek protektif yang sama terhadap kerusakan spermatozoa terutama dalam aspek motilitas dan morfologi karena paparan cisplatin. Oleh karena itu, dalam penelitian ini lebih disarankan menggunakan α -tocopherol dalam dosis 50 mg/kgBB dibandingkan dengan dosis 200 mg/kgBB.

Kata Kunci: Vitamin E, spermatozoa, motilitas, morfologi, cisplatin.

Correspondence: Tarmono Djojodimedjo; c/o: Department of Urology, Faculty of Medicine/Universitas Airlangga, Soetomo General Hospital, Surabaya. Jl. Mayjen. Prof. Dr. Moestopo 6-8 Surabaya 60286. Phone: +62 31 5501318; Fax: +62 31 5024971. Mobile phone: 08123255443. Email: tar_urology@yahoo.com.

INTRODUCTION

Cancer is an age-related disease, and the risk is increasing with age. Based on GLOBOCAN data, International Agency for Research on Cancer (IARC), it is known that there are 14.1 million cancer new cases and 8.2 million of death because of cancer all over the world in 2012.^{1,2} Approximately 1 in 285 children in the United States will be diagnosed with cancer before their 20th birthday. The cancer case has been increasing 1% in children and 1.5% in adolescents.³ Some malignancies that occur in adolescence have shown a significant increase for the last 20 years, especially testicular tumor, Testicular Germ Cells Tumour (TGCT). TGCT is common cancer in men aged 20 to 39 years, representing 21% of invasive cancer. At this time, children and adults that diagnosed with cancer have higher survival rates because of the new medical protocol, including operative, chemotherapy combination, and radiation.^{3,4} Among the various type of multiagent chemotherapy, cisplatin is one of the most frequent multiagent chemotherapy that was used to the various type of cancer, including testicular, ovarium, bladder, liver, lungs, hand-and-neck, uterus, cervix, and leukaemia.^{2,4}

Cisplatin has proven as an optimal chemotherapy agent for various malignancies. However, it has an uncomfortable side effect. Most of the patient who gets cisplatin therapy belong to productive age group and experience permanent infertility because of the azoospermia caused by cisplatin.^{3,4} The maximum safe dose of cisplatin that will not cause infertility is 400 mg/m². If the dosage is higher than the "safe dose" then it will have a negative impact on sperm production and sperm quality.⁵

Cisplatin will cause cell damage through the various mechanism, including cisplatin binding to guanine base of DNA, cross chain formation, and increasing production of Reactive Oxygen Species (ROS), that will cause lipid peroxidation. Eventually, it will cause cell inflammation and oxidative stress (OS) formation.⁶ OS happened because of the imbalance of free radical production and the antioxidant defense mechanism so it will cause damage to the cell, nucleic acid, protein, lipid, and induce DNA mutation.^{6,7} Free radical is an atom, molecule, or ion products from a chemical process that has one or more unpaired electron. Free radical has a reactive character that can oxidize lipid, amino acid, carbohydrate, and cause DNA mutation.⁷ OS

cause peroxidative damage in sperm membrane and DNA fragmentation in the cell nucleus and mitochondria level so that it will cause sperm damage or infertility.⁸

Some study has proved that cisplatin will induce testicular disintegration, sperm dysfunction, germ cell apoptosis, Leydig cell damage, membrane rigidity caused by the toxicity, lipid peroxidation, oxidative damage, and decreasing of the antioxidant defense inside the body.⁹ This toxicity happened because of the oxidative stress caused by the increase of ROS. Cisplatin also increases lipid peroxidation by the enhancement of malondialdehyde (MDA) formation.¹⁰ Men infertility that experience OS caused by adverse effect or spermatozoa damage, just like the increasing amount of spermatozoa with low motility, spermatozoa membrane cell damage, decreasing amount of normal spermatozoa morphology, decreasing sperm viability and ability to fertilize the ovum.¹⁰ Continuous ROS exposure will cause cellular dysfunction and apoptosis. Exogenous antioxidant consumption is an example to avoid sperm cell damage from this process.⁶

Various kinds of substances, especially antioxidant, have been widely investigated for its protective effect against cisplatin-induced toxicity, one of which is resveratrol.¹¹ Resveratrol has various protective mechanisms against cisplatin-induced testicular toxicity by improving the damage on testis that caused by OS, improving steroidogenesis and spermatogenesis, also restoring testicular architecture.¹¹ Many studies also investigated other substances, one of which is arjunolic acid.¹² It concluded that administration of arjunolic acid can significantly improve biochemical parameters and histopathology of damaged testis. Arjunolic acid has a significant protective role in Cisplatin-induced testicular injury by weakening the parameters of oxidative stress along with downregulation of expression of testicular iNOS, TNF- α , and p38-MAPK.¹² Because of this, researchers assume that the administration of anti-oxidants can provide a protective effect against damage caused by cisplatin.

Vitamin E is one of the antioxidants that has potent anti-oxidant activity. Study on the protective effects of vitamin E on cisplatin toxicity has not been widely carried out, therefore researchers want to examine the protective effects of vitamin E against cisplatin-induced testicular toxicity.

Vitamin E can give a protection effect by reducing or preventing tissue damage or oxidative cell. Vitamin E works by preventing lipid

peroxidation in membrane cell from the reaction that caused by ROS that known as a non-enzymatic antioxidant.¹³ The Vitamin E consumption can neutralize free radical effect is expected to reduce OS caused by cisplatin therapy. Reducing OS in tissue or cell is expected to minimalize tissue or cell damage from spermatozoa, testicle, nerve, and other organs. Vitamin E also expected to increase the amount of spermatogonium, Leydig cell, and Sertoli cell followed by increasing amount of testosterone hormone and improvement of the spermatogenesis process, so it will restore the motility and morphology of spermatozoa cell.

OBJECTIVE

To evaluate the protective effects of vitamin E α -tocopherol isomer against the toxicity of cisplatin on sperm motility and morphology in Sprague Dawley rats.

MATERIAL & METHODS

The design of this study was an experimental laboratory study with post test only control group design, using male, white rat strain Sprague Dawley as an experimental animal. This study has got the ethical feasibility from Faculty of Veterinary, Ethical and Research Committee of Universitas Airlangga, with number 2.KE/140.08.2018.

Twenty-four male, white rats (Sprague Dawley strain) were obtained from Lembaga Penelitian Terpadu (LPT) Gadjah Mada University Yogyakarta (200-250g in weight, 10-12 weeks old) in which adaptation process was first carried out in the cage for two weeks with 12 hours bright, 12 hours dark-light cycle. The rats were maintained in 1500 cm² for a group of 6 rats. The temperature of the cage was approximately 20-26°C with air humidity around 40-70%. Each group was put down in a separate cage, given partition and preserve in order not to interact. Food and water were provided by ad libitum. The type of food provided was commercial pellet hi pro vite 593, 20-25 grams each day and fresh water are given sufficiently.

The sample of this study was randomly divided into four groups (n=6). The control group (CN) was injected with normal saline 0.9% 1 cc, intraperitoneal (i.p), one time as a placebo in the third week. The second group (CP) was injected with cisplatin (Cisplatin Kalbe Farma Indonesia) 5 ml/kgBW, i.p, one time in the third week. The third

group (P1) was administered with vitamin E (Blackmores, Catalent, Australia) 50 mg/kgBW by gavage for 7 weeks and cisplatin injection 5 mg/kgBW in the third week, i.p, one time. The fourth group (P2) was given vitamin E 200 mg/kgBW by gavage for 7 weeks and cisplatin injection 5 mg/kgBW in the third week, i.p, one times. Vitamin E was given by gavage started from 3 weeks before cisplatin injection and 4 weeks following cisplatin injection. Vitamin E that being used in this study was α -tocopherol isomer.

All samples were undergo bilateral orchidectomy in the 7th week administration of vitamin E. The entire procedure was done in a sterile condition. Rats were anesthetized with ketamine 75 mg/kgBW intraperitoneal.

Spermatozoa were taken from the incised epididymis cauda, then put on a petri dish filled with 1 ml of physiologic NaCl, cut into the small size and left for 1-2 minutes to let the spermatozoa come out from the epididymis and spreads. For motility examination 1 drop of semen was put on an object glass added by 1 drop of physiologic NaCl, and then stirred until homogenous. The examination was done under the microscope with a magnification of 400x. Evaluation was counted according to non-motile spermatozoa (score = 0) until the motile-spermatozoa that moves very fast (score = 4).

For morphology/viability examination, the making of preparation was done in Eosin Negrosin coloring. The living sperm will not be colored by eosin coloration substance. Dead spermatozoa will be stained red-purplish because of the destruction of spermatozoa plasma membrane cell. A Pathologist did the preparation reading in Faculty of Veterinary Universitas Airlangga Surabaya.

The result of motility and morphology calculation which was ratio kind of data will be done normality and variance test. If the data distribution was normal, then the hypothesis test of one-way ANOVA was done. In the other hand, if the data distribution was not in the normal distribution and the variance was not equal, so Kruskal-Wallis was chosen as alternative test.¹⁴

The hypothesis was determined according to the significance value obtained. This study was significant if the value of $p < 0.05$. If one-way ANOVA significance value $p < 0.05$, the next step was doing second comparison test or Post hoc Test LCD (if the variation was equal) or Post Hoc test Tamhane (if the variation was not equal). If the significance value of the Kruskal-Wallis test was

<0.05, then the analysis will continue using Mann Whitney test. The result was significantly different if the $p < 0.05$.¹⁴ The entire data formulation was analyzed with a computer using software statistical product and service solution 25 (SPSS 25) for windows.

RESULT

Research has been conducted to see the effect of vitamin E on preventing the cisplatin-induced spermatotoxic in experimental animals. Characteristics of the sample can be seen in table 1. The distribution of body weight in each group was

Table 1. Sample characteristics.

Body weight pre-treatment (gram)	Median (Min-Max)	p-value
CN	250 (220 -270)	0.57 ^a
CP	250 (220 -280)	
P1	245 (220 -290)	
P2	275 (210 -280)	

CN: Control group
 CP: Cisplatin group
 P1: Cisplatin + Vitamin E 50 mg/kgBW group
 P2: Cisplatin + Vitamin E 200 mg/kgBW group
 a: Kruskal-Wallis test

Table 2. Comparison of spermatozoa motility between groups.

Groups	n	Mean ± SD	p-value
CN	6	66.67 ± 6.83	0.004*
CP	6	14.17 ± 3.76	
P1	6	52.50 ± 20.43	
P2	6	59.17 ± 21.30	

*p < 0.05: statistically significant

Table 3. Games-Howell post hoc analysis of spermatozoa motility in each group

Comparison between groups	Mean Differences	95% CI		p-value
		Lower Bound	Upper Bound	
CN vs CP	54.50	42.24	62.76	0.000*
CN vs P1	14.17	-16.12	44.45	0.438
CN vs P2	7.50	-24.10	39.10	0.843
CP vs P1	-38.33	-68.87	-42.24	0.020*
CP vs P2	-45.00	-76.87	-7.79	0.012*
P1 vs P2	-6.67	-43.55	30.22	0.944

* p < 0.05: statistically significant

not normally distributed with p-value <0.05. Therefore, in this study, the body weight data were analyzed using the Kruskal-Wallis test. There was no significant difference in mean body weight in each group with p-value >0.05.

Shapiro-Wilk test showed that the distribution of spermatozoa motility was normally distributed with p-value >0.05. From the homogeneity test, the data was not homogeneous with p-value <0.05. Based on the result, the spermatozoa motility data were analyzed using the One-Way ANOVA Brown-Forsythe test as seen in table 2. There was a significant difference in each group with p-value <0.05, therefore, the data was analyzed using the post hoc Games-Howell test to find out the differences and comparisons between the group.

In this study, based on the Games-Howell post hoc test, there were significant differences between the CP compared to CN with p-value <0.05 (Table 3). Therefore, it was proven that cisplatin could reduce spermatozoa motility. This study found that vitamin E has a protective effect on spermatozoa motility. There was a significant difference in spermatozoa motility in P1 group compared to CP with p-value <0.05. The spermatozoa motility was higher in P1 group compared to the CP group. When compared to the CN, there were no significant differences with p-value >0.05 (Table 3). This result shows that vitamin E 50 mg/kgBW can maintain spermatozoa motility.

P2 group also have a significant difference compared to the CP with p-value <0.05. The spermatozoa motility was higher in P2 compared to the CP. When compared to the CN, there were no significant differences with p-value >0.05 (Table 3). This result shows that vitamin E 200 mg/kgBW can maintain spermatozoa motility.

Shapiro-Wilk test shown that the distribution of spermatozoa morphology data was normally distributed with p-value >0.05. Homogeneity test also showed that the data was homogenous (p>0.05). Based on the variance and homogeneity result, the data was analyzed using One Way ANOVA test. There were significant differences between groups with a value p<0.05 (Table 4), therefore the data then analyzed using Least Significant Difference (LSD) post hoc test to determine the differences between groups.

LSD post hoc analysis showed that there were significant differences between the CP and CN with p-value <0.05. Therefore, it was proven that cisplatin could reduce spermatozoa morphology. Vitamin E treatment was expected to provide a protective effect on spermatozoa morphology. Spermatozoa morphology on P1 and P2 group was higher and significantly difference with CP group (p<0.05) but not significantly difference with CN (p>0.05).

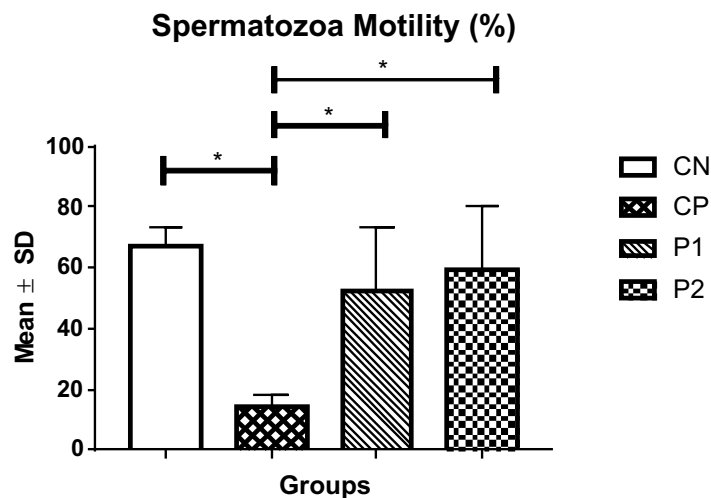


Figure 1. Comparison of spermatozoa motility in each group.

Table 4. Comparison of spermatozoa morphology between groups.

Groups	n	Mean ± SD	p-value
CN	6	72.00 ± 7.95	0.01*
CP	6	48.00 ± 19.99	
P1	6	69.00 ± 12.00	
P2	6	75.00 ± 13.57	

* p<0.05 statistically significant

Table 5. LSD post hoc analysis of spermatozoa morphology in each group.

Comparison between groups	Mean Differences	95% CI		p-value
		Lower Bound	Upper Bound	
CN vs CP	24.00	7.07	40.93	0.00*
CN vs P1	3.00	-13.93	19.93	0.72
CN vs P2	-3.00	-19.93	13.93	0.72
CP vs P1	-21.00	-37.93	-4.07	0.02*
CP vs P2	-27.00	-43.93	-10.07	0.00*
P1 vs P2	-6.00	-22.93	10.93	0.47

* p<0.05 statistically significant

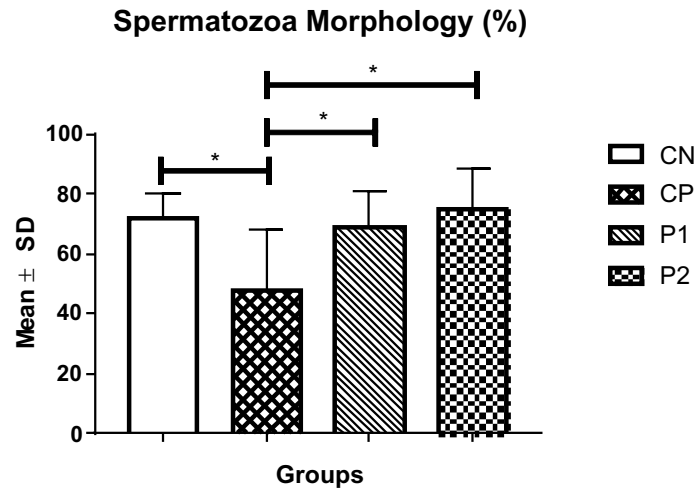


Figure 2. Comparison of spermatozoa morphology in each group.

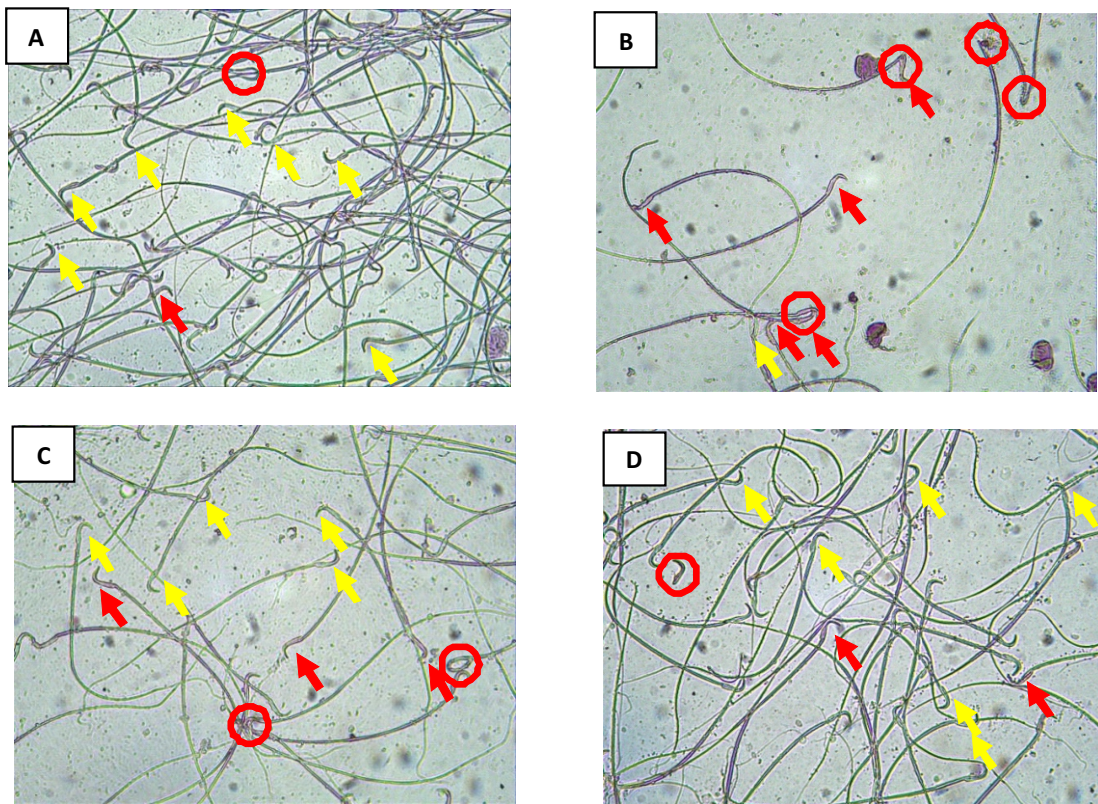


Figure 3. Spermatozoa histopathology (400x magnification) on A.CN group; B.CP group; C.P1 group; D.P2 group. Yellow arrow shows healthy sperm; red arrow shows damaged sperm, and red circle shows sperm with abnormal morphology.

DISCUSSION

Cis-diamminedichloridoplatinum (II) or cisplatin is the first platinum-based chemotherapy drug that is used throughout the world. Cisplatin also is known as an unspecific cell cycle and can be used

in combination with other chemotherapy drugs. Besides the benefits, cisplatin also has toxic effects on several organs, including the digestive tract, nephrotoxicity, and neurotoxicity when used at high dosage.¹⁵ Also, cisplatin also has long-term toxic effects on testicular dysfunction.⁶

In this study, cisplatin 5 mg/kgBW significantly decreased the morphology of spermatozoa compared to control group ($p < 0.05$). Cisplatin also significantly decreased the motility of spermatozoa compared to control group ($p < 0.05$). According to a study by Ciftci et al., cisplatin causes toxicity to the reproductive system through increased oxidative stress, histological damage, decreased serum testosterone levels and changes in spermatozoa characteristics.¹⁶

The mechanism of cisplatin cytotoxicity which results in cell damage occurs in several ways, namely binding of Cisplatin to the guanine base in DNA, cross chain formation and through increased production of ROS, which can cause fat peroxidation that leads to inflammation and OS.^{6,15} OS occurs because of an imbalance between the production of free radicals with antioxidant defenses in the body. OS can cause various damage to cells, nucleic acids, proteins, fat and also induce DNA mutation.^{6,7}

Free radical is an atom, molecule, or ion product from a chemical process that has one or more unpaired electron. Free radical has a reactive characteristic that can oxidize lipid, amino acid, carbohydrate, and cause DNA mutation.⁷ OS cause peroxidative damage in sperm membrane and DNA fragmentation in the cell nucleus and mitochondria level so that it will cause sperm damage or men infertility.⁸

Testicular tissue is one example of tissues that have a sensitivity to both free radicals and ROS. Free radicals that bind with the testicular cell membrane (spermatogonium, Sertoli cell, and Leydig cell) will cause lipid peroxidation and another mechanism that will trigger the apoptosis process from the cells.⁸ The cellular testicle damage that was caused by the chemotherapy agent, especially cisplatin, was a maturation arrest process that can be known from the reduced sperm parameter and tubules seminiferous diameter after exposure of the chemotherapy agent.

Some study has been proven that cisplatin will induce testicular disintegration, sperm dysfunction, germ cell apoptosis, Leydig cell damage, membrane rigidification caused by the toxicity, lipid peroxidation, oxidative damage, and decrease in antioxidant defense inside the body.^{9,17} This toxicity happened because of the oxidative stress caused by increasing ROS. Cisplatin also increases lipid peroxidation by the enhancement of malondialdehyde (MDA) formation.¹⁰ ROS will be produced by spermatozoa in small quantities under

normal condition. ROS is important for sperm regulation, sperm capacity, and sperm acrosomal reaction. But in large numbers, ROS will cause normal cell oxidation, especially spermatozoa cell that will cause sperm damage through increased apoptosis and DNA mutation. The damage also was seen in seminiferous tubules. Some tubules area has shown germ cell depletion, while the other tubules area has shown primer spermatocyte or spermatogonia. Sertoli cell show degenerative modification in the cellular process and cell junction. The disturbance of the spermatid membrane nucleus and the loss of intercellular bridge also proven that it will cause sperm morphology disturbance.^{16,18}

High concentration of ROS will trigger oxidative polyunsaturated lipid acid damage inside the plasma sperm membrane, and it will start the lipid peroxidation cascade. When the lipid peroxidation happened, it will deposit in the sperm surface, and this will reduce phospholipid sperm membrane fluidity that will cause sperm flagella works ineffectively and reduce the motility. Excessive ROS expenditure from mitochondria in sperm midpiece also can harm mitochondria itself so it will reduce the sperm motility. Therefore, oxidative stress can make infertility by disturbing sperm transition through women reproduction tract. Furthermore, acrosome membrane damage will reduce acrosin activity and inhibit sperm capacity to bind with the oocyte. As a result, it will cause poor fertilization capacity. Exogenous antioxidant consumption is an example to avoid sperm cell damage from this process.⁶

From this study, we can see that both in P1 and P2 group that was given vitamin E for 3-4 weeks after 5 mg/kgBW intraperitoneally cisplatin injection had statistically significant differences in spermatozoa morphology compared to CP group ($p < 0.05$). In the CN group, we can see that there were no statistically significant differences between the CN and P1 or P2 group ($p > 0.05$). We can see that the administration of vitamin E 50 mg/kgBW and 200 mg/kgBW in the cisplatin group had protection effect to morphology spermatozoa cell.

It was also seen that spermatozoa motility in P1 and P2 was higher than CP group. This result showed that administration of vitamin E at a dose of 50 mg/kgBW and 200 mg/kgBW can provide optimal protection against cisplatin-induced spermatozoa motility damage. Descriptively, spermatozoa motility in P2 group was higher than spermatozoa motility in P1, but it was not

statistically significant ($p > 0.05$). It still not known that increasing the dose of vitamin E may provide a better protective effect, therefore further research is needed.

The antioxidant has been known as an intracellular defense mechanism from testicular damage induced by cisplatin. Some research has shown that it has a protective effect from an antioxidant substance in cisplatin-induced toxicity.^{19,20} Vitamin E is an antioxidant that has unsaturated phospholipid protective effect from oxidative degradation caused by reactive oxygen species (ROS) and other free radicals. As the most important antioxidant cell membrane, it has the lipid-soluble characteristic. Vitamin E has two biologically active substances (tocopherol and tocotrienols).²¹

There are four tocopherol isomers in Vitamin E, α -, β -, γ -, and δ -. Antioxidant activity of the tocopherols in vivo is in the order $\alpha > \beta > \gamma > \delta$.⁵ We investigated α -tocopherol because of its antioxidant activity is the strongest among other. As a lipid-soluble antioxidant, vitamin E plays a role in binding free radicals. Haryatmi (2004) said from her research that vitamin E could stop the lipid peroxidation by donating its hydrogen atom from its OH form to the lipid peroxide that has radical characteristic, so that it become tocopheryl radical that has a less reactive effect and does not have a damaging effect. Free radicals start from carbon-centered free radical form; then it will bind with free oxygen to form ROS. ROS can be neutralized by poly-unsaturated fat to become hydroperoxide. This process was assisted by vitamin E (especially tocopherol) that can neutralize ROS faster than lipid. The lipid peroxidation process in the cell membrane can be avoided and reduced by Vitamin E.²²

From this research, we can see that both in cisplatin injection group and 200 mg/kgBW vitamin E group had higher spermatozoa morphology compared to cisplatin injection and 50 mg/kgBW vitamin E group although it did not have statistical differences descriptively ($p > 0.05$). However, if 200 mg/kgBW vitamin E group was compared to cisplatin only group, from the Post Hoc statistic test, we can see that it had differences ($p < 0.05$) statistically. This indicates that 200 mg/kgBW vitamin E has significant influence in preventing spermatozoa morphology decreasing caused by cisplatin injection administration and the effectivity was better compared to 50 mg/kgBW vitamin E administration, descriptively.

We can see that there was a significant improvement in spermatozoa morphology and motility, especially in higher vitamin E dose (200 mg/kgBW). This data has shown that it had gradual sperm toxicity suppression that depends on vitamin E dosage supplementation. Vitamin E protective effect towards stress oxidative that caused by cisplatin administration was shown from the linear progression of morphology and motility, which the linear response depended on vitamin E dosage that the higher dosage had better protection effect.

Vitamin E has a role in inhibiting lipid peroxidation, reducing spermatozoa malondialdehyde, increasing spermatozoa motility, reducing spermatozoa DNA fragmentation, and increasing other antioxidant activity that has the free radicals binding ability.^{23,24} Vitamin E can neutralize hydroxyl form, superoxide, peroxide hydrogen radical, and prevent sperm agglutination. Some damage that caused by free radicals happened in cell membrane and lipoprotein with low density that composed by lipid molecule. It shows that vitamin E is the most effective antioxidant because of its lipid-soluble characteristic.²⁴

In the intracellular stage, MHC and ROS in the mitochondria will induce a reaction called mitochondria stress. Mitochondria stress will activate Bax and Bak (pro-apoptotic protein from the Bcl-2 family group). Bax and Bak will activate Mitochondrial Permeability Transition Pore (MPTP) between the Outer Matrix Membrane (OMM) and Inner Matrix Membrane (IMM) called mitochondria matrix. Bax, Bak, and t-bid that respond to apoptotic stimulation will translocate to mitochondria. Then, mitochondria will release the cytochrome-C to the cytosol. This process happened simultaneously with Apoptotic Inducing Factor (AIF) and dATP release. The release of this molecule will cause procaspase-9 breakage into its active form, caspase-9. Caspase-9 will initiate caspase-7 and caspase-3 (caspase effector). Caspase-3 causes cleavage of poly (ADP-ribose) polymerase (PARP) and DNA fragmentation that leads to apoptosis.²⁵

This result corresponds to Fikret et al., study which is shown that cisplatin also causes testicular apoptosis through protein apoptosis Cas-3 and Bax. Cisplatin increases the expression of the protein in apoptosis, Caspase-3, and Bax. Furthermore, it also decreases the expression of the anti-apoptotic protein, Bcl-2 that will cause testicular apoptosis. Vitamin E supplementation could give protection effect by reducing the apoptotic protein expression

(Cas-3, Bax) and decrease the Bax and Bcl-2 ratio.²⁶

The decreasing of Bax and Bax/Bcl-2 ratio will reduce the apoptosis of spermatogonium, Sertoli cell, and Leydig cell. Vitamin E also prevents the cytochrome-C release (pro-apoptotic), so it could prevent the mitochondria membrane from getting damage and reduce the ROS production. If the ROS production were decreased, the Scavenger and ROS ratio would be balanced or even higher scavenger ratio, so it can neutralize the ROS and reduce stress oxidative. This process will simultaneously reduce the free radical reaction with the cell membrane, spermatogonium mitochondria, and Sertoli cell. Finally, the apoptosis will decrease, spermatogonium and the Sertoli cell will increase, the sperm morphology and motility will get some improvement.

Limitations of this study are the optimal doses of α -tocopherol is still unknown, duration of α -tocopherol administration until it can give protective effect is still unknown and prolonged use of α -tocopherol side effects is also not known yet. Therefore, further research that analyze our limitations needs to be done to clearly understand the protective effect mechanism of α -tocopherol.

CONCLUSION

α -tocopherol 50 mg/kgBW and 200 mg/kgBW provided the same protective effect against spermatozoa damage especially in motility and morphology aspect due to cisplatin exposure. Therefore, in this study it was more recommended to use α -tocopherol in 50 mg/kgBW dose than 200 mg/kgBW.

REFERENCES

1. Bott R. Data and health information of cancer situation. *Igarss*. 2014; (1): 1-5.
2. IARC. Estimated cancer incidence, mortality, and prevalence worldwide in 2012. *Estim cancer Incid mortality, Preval Worldw*. 2012; GLOBOCAN 2.
3. Moon E-K, Park HJ, Oh C-M, Jung K-W, Shin HY, Park BK, et al. Cancer incidence and survival among adolescents and young adults in Korea. *PLoS One*. 2014; 9(5): e96088.
4. Nichols CR. Testicular cancer: a prototypic tumor of young adults. *J Clin Oncol*. 2010; 36(5): 432-8.
5. Kamal-Eldin A, Appelqvist LÅ. The chemistry and antioxidant properties of tocopherols and tocotrienols. *Lipids*. 1996; 31(7): 671-701.
6. Bujan L, Walschaerts M, Moinard N, Hennebicq S, Saias J, Brugno F, et al. Impact of chemotherapy and radiotherapy for testicular germ cell tumors on spermatogenesis and sperm DNA: a multicenter prospective study from the CECOS network. *Fertil Steril*. 2013; 100(3): 673-80.
7. Guthrie H, Welch G. Effects of reactive oxygen species on sperm function. *Theriogenology*. 2012; 78: 1700-8.
8. Wagner H, Cheng JW, Ko EY. Role of reactive oxygen species in male infertility: an updated review of literature. *Arab J Urol*. 2018; 16(1): 35-43.
9. Hejazi S. Toxicity effect of cisplatin-treatment on rat testis tissue. *J Mens health*. 2011; 8(3): 208-35.
10. Soni KK, Kim HK, Choi BR, Karna KK, You JH, Cha JS, et al. Dose-dependent effects of cisplatin on the severity of testicular injury in sprague dawley rats: reactive oxygen species and endoplasmic reticulum stress. *Drug Des Devel Ther*. 2016; 10: 3959-68.
11. Reddy KP, Madhu P, Reddy PS. Protective effects of resveratrol against cisplatin-induced testicular and epididymal toxicity in rats. *Food Chem Toxicol*. 2016; 91: 65-72.
12. Sherif I, Abdel-Aziz A, Sarhan O. Cisplatin-induced testicular toxicity in rats: the protective effect of arjunolic acid. *J Biochem Mol Toxicol*. 2014; 28(11): 515-21.
13. Uzunhisarcikli M, Kalender Y. Protective effects of vitamins C and E against hepatotoxicity induced by methyl parathion in rats. *Ecotoxicol Environ Saf*. 2011; 74(7): 2112-8.
14. Dahlan MS. *Statistik untuk kedokteran dan kesehatan: uji hipotesis*. Jakarta: Bina Mitra Press; 2006.
15. Salem EA, Salem NA, Maarouf AM, Serefoglu EC, Hellstrom WJG. Selenium and lycopene attenuate cisplatin-induced testicular toxicity associated with oxidative stress in Wistar rats. *Urology*. 2012; 79(5): 1184.e1-1184.e6.
16. Ciftci O, Beytur A, Cakir O, Gurbuz N, Vardi N. Comparison of reproductive toxicity caused by cisplatin and novel platinum-n-heterocyclic carbene complex in male rats. *Basic Clin Pharmacol Toxicol*. 2011; 109(5): 328-33.
17. Marullo R, Werner E, Degtyareva N, Moore B, Altavilla G, Ramalingam SS, et al. Cisplatin induces a mitochondrial-ros response that contributes to cytotoxicity depending on mitochondrial redox status and bioenergetic functions. *PLoS One*. 2013; 8(11): 1-15.
18. Abdel-Mohsen A, Elmarakby D, Elgendy M, Eldsouky D. Histological study on the role of ginger against cisplatin-induced testicular toxicity in albino rats. *Egypt J Histol*. 2013; 36(2): 312-20.
19. Kaya K, Ciftci O, Cetin A, Doğan H, Başak N. Hesperidin protects testicular and spermatological damages induced by cisplatin in rats. *Andrologia*. 2015; 47(7): 793-800.
20. Anand H, Misro MM, Sharma SB, Prakash S. Protective effects of eugenia jambolana extract versus n-acetyl cysteine against cisplatin-induced damage in rat testis. *Andrologia*. 2015; 47(2): 194-208.

21. Galagher M. Krause's food and nutrients therapy, 12th. Elsevier Saunders; 2008. p. 113-8.
22. Jungwirth A, Diemer T, Dohle G, Kopa Z, Krausz C, Tournaye H. Guidelines on male infertility. Eur Assoc Urol. 2016; 46(March): 1-24.
23. Muhammad Z. Effects of dietary vitamin E on male reproductive system. Asian Pacific J Reprod. 2017; 6(4): 145-50.
24. Gadallah K. Role of antioxidants in the treatment of male infertility. Surg Med Open Acc J. 2018; 1(2): 1-10.
25. Ganga UK, Kishori B, Reddy PS. Cisplatin and/or etoposide induces oxidative stress in testicular, hepatic and kidney tissues in male albino mice. J Biol Earth Sci. 2013; 3(2): B249-54.
26. Gevrek F, Erdemir F. Investigation of the effects of curcumin, vitamin E and their combination in cisplatin-induced testicular apoptosis using immunohistochemical technique. Türk Üroloji Dergisi/Turkish J Urol. 2018; 44(1): 16-23.