

Case Report

A case of juvenile dermatomyositis responding to methotrexate and steroid

Gunawan PI¹, Saharso D²

Abstract

A 4-year-old patient presented with skin rash and muscle weakness. She was diagnosed with juvenile dermatomyositis based on Bohan and Peter criteria as well as laboratory testing. She received steroid and combined with methotrexate. The treatment resulted in a good response.

Keywords: juvenile dermatomyositis; steroid; methotrexate

Bangladesh Journal of Medical Science Vol. 17 No. 04 October '18. Page : 675-677

DOI: <http://dx.doi.org/10.3329/bjms.v17i4.38336>

Introduction

Juvenile dermatomyositis (JDM) is the majority common of the idiopathic inflammatory myopathies group that occur during childhood. The incidence is estimated in 2-3 per million children per year.^{1,2} Most cases of JDM occur between 5 and 14 years old. Females are affected more commonly than males. Although the etiology of dermatomyositis is unknown, autoimmunity is suspected to be the underlying cause of inflammation. In the last few decades, mortality has significantly declined, and there has been a progress in functional outcome due to earlier diagnosis and more effective treatment.^{1,2} Therefore, we report the case focusing on diagnostic and management approach.

Case Report

A 4-year-old female patient presented with erythema of nasal bridge, cheeks, upper and lower eyelids lasted for four months. The complaint did not diminish with topical anti-allergy treatment. Two months later, she developed confined erythematous papular lesions of metacarpophalangeal, proximal part of interphalangeal, and distal part of interphalangeal joints. Simultaneously she suffered from weakness and difficulty to get up from the bed and run. No fever was observed. Neurological examination showed the weakness of proximal muscle strength.

No sign of arthritis and calcinosis Skin changes typically involved erythematous rash with purplish discolorisation along the nasal bridge, the cheeks as well as periorbital regions (heliotrope rash) (Table 1). There were papular, erythematous and scaly lesions over the knuckles (Gottron's sign) (Fig 1). CPK level was 354 IU/mL. ANA test, anti-ds-DNA, CRP and LE cell phenomenon were negative. Muscle biopsy revealed perivascular infiltration of inflammatory cells and perivascular atrophy (Fig3). Methylprednisolone 18mg in three divided doses was administered.

Within two weeks of treatment, the patient showed remarkable improvement (fig 2). A few skin lesions manifested as generalised erythema and mild oedema of skin were persisted. Addition to methotrexate as steroid-sparing agent weekly started at 7.5 mg and then increased 2.5 mg weekly to a maximal dose of 25 mg.

On four weeks follow-up of treatment, the patient showed an excellent response. The muscle strength gradually improved as well as the cutaneous manifestations were moderate disappear. The methotrexate was well tolerated. No side effect was significantly observed. No mood changes, weight gain and recurrent infections developed. The treatment remained to be instituted.

1. Prastiya Indra Gunawan,
2. Darto Saharso, MD

Pediatric Neurology, Department Of Pediatrics, Airlangga University, College of Medicine Dr Soetomo Hospital, Surabaya, Indonesia

Correspondence to: Prastiya Indra Gunawan, Airlangga University College of Medicine Jl. Prof Dr Moestopo 6-8 Surabaya Indonesia 60286, Email: prastiya_ig@yahoo.co.id

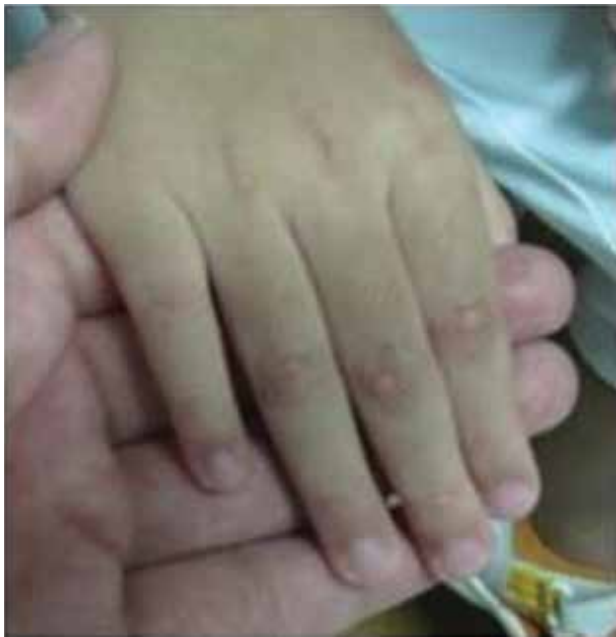

Figure 1. Gottron sign before treatment

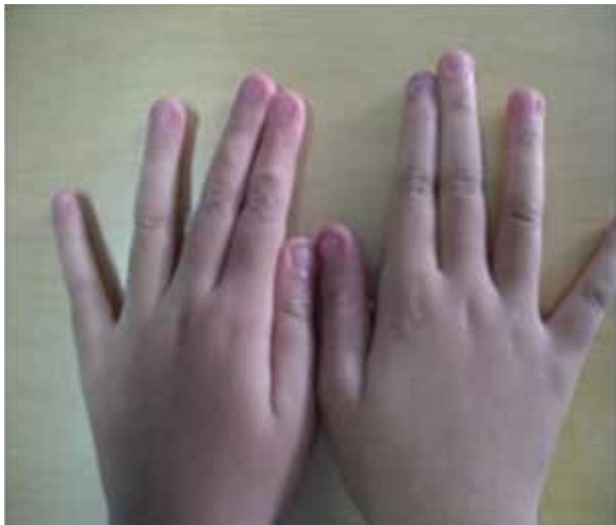

Figure 2. Gottron sign after treatment

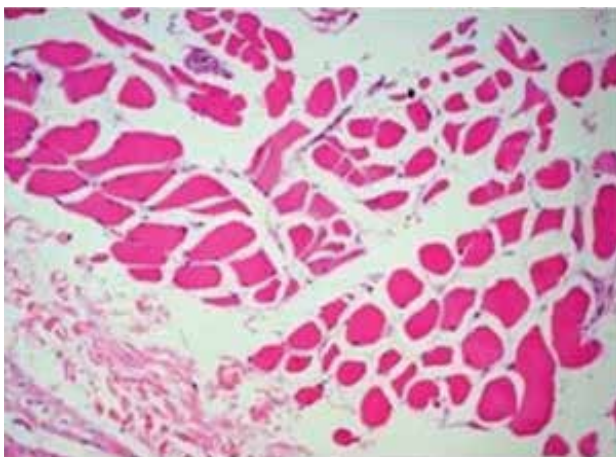


Figure 3. Muscle biopsy showing perivascular infiltration of inflammatory cells and perivascular atrophy

Table 1. Clinical manifestation of the patient

	The case
Heliotrope sign	+
Gottron's sign	+
Shawl sign	-
V-sign	-
Poikiloderma vasculare atrophicans	-

Discussion

The rash in JDM may precede or follow the onset of proximal muscle weakness. The characteristic rash is heliotropic or violaceous, occurring most prominently on the eyelids. Erythema can occur over the upper fragments of the body (shawl sign) and extensor surfaces of arms and legs.³ In this patient, the characteristic of rashes compared with clinical presentation by Sunkureddi et al could be showed in table 1.^{1,4}

Bohan and Peter set forth criteria for the diagnosis of JDM. These criteria assumed that the child has the characteristic rash, after which three of the four criteria must be fulfilled for the definite disease, two of four for probable diseases and one of four for possible diseases. The patient met all the criteria and appropriated as the definite disease.

As dermatomyositis are not common disease, there have been few randomized controlled trials, and those that have been completed enrolled small numbers of patients. Subsequently, optimum therapy has not been defined adequately. Corticosteroids are the mainstay of therapy for JDM.⁵ In this patient; methylprednisolone treatment showed a good response. Although controlled studies have not been published, initial treatment with high dose of corticosteroid is recommended. Approximately 90% of patients shows partially improvement with corticosteroid therapy, and 50-75% of patients would achieve complete remission.⁴ There is controversy surrounding the best route of administration, dosing regimen, duration and parameters to monitor the treatment.²

Throughout the corticosteroid tapering, the other immunosuppressive agents, such as azathioprine, methotrexate, cyclophosphamide, and cyclosporine be able to be used to monitor disease activities or facilitate steroid tapering.^{4,5,6} Januar reported 3

cases at KKH presented classically with skin and muscle involvement and were treated with high doses of prednisolone. Upon weaning the dose of prednisolone, they had a recurrence of symptoms and were started on subcutaneous methotrexate. All patients responded well to the treatment.⁷ The pediatric rheumatology group in Toronto compares outcomes in 31 children with JDM, who were received methotrexate as first line treatment and 22 similar children treated earlier who had not (control). All patients received 2 mg/kg/day of prednisone administered in three doses for the first six weeks, then in one daily dose. If the disease was under control, the dose was tapered by roughly 10% every second week. Patients received methotrexate at 10–20 mg/

m² body surface area/week. The duration, cumulative dose, and toxicity of corticosteroid treatment were significantly reduced in the methotrexate group.⁸ In this patient, methotrexate-steroid sparing agent for symptom relief was instituted after two weeks steroid treatment and it successfully reduced the symptoms. The overall prognosis for survival is improved with the use of corticosteroids. The prognosis is good for most patients with dermatomyositis without associated malignancy.⁴

Conclusion

Corticosteroids are still the mainstay of medication for juvenile dermatomyositis. Combination steroid and methotrexate treatment have a remarkable response in this patient.

References

1. Brown VE, Pilkington CA, Feldman BM et al. An international consensus survey of the diagnostic criteria for JDM. *Rheumatology* 2006;**45**:990-3.
2. Amato AA, Kissel JT. Inflammatory myopathies. In Swaiman KF, Ashwal S, Ferriero DM eds. *Pediatric neurology principles and practice*. Philadelphia, Mosby elsevier 2006. p 2075-83.
3. Chari G, Laude TA. Juvenile dermatomyositis: A Review. *Int Pediatr* 2000;**15**:21-25.
4. Sunkureddi P, Nguyen-Oghalai TU, Jarvis JL, Karnath BM. Signs of dermatomyositis. *Hospital physician* 2005;**4**:41-5.
5. Choy EHS, Isenberg DA. Treatment of dermatomyositis and polymyositis. *Rheumatology* 2002;**41**:7–13.
6. Riley P, Maillard SM, Wedderburn LR, et al. Intravenous cyclophosphamide pulse therapy in juvenile dermatomyositis. A review of efficacy and safety. *Rheumatology* 2004;**43**:491-6.
7. Jamuar SS, Shek LPC, Goh AEN. Successful use of methotrexate for juvenile dermatomyositis: KK Hospital experience. *Archives of Disease in Childhood* 2008;**93**:141.
8. Ramanan AV, Webster C, Ota S, et al. The effectiveness of treating juvenile dermatomyositis with methotrexate and aggressively tapered corticosteroid. *Arthritis Rheum* 2005;**52**:3570-8.