

Carbonate Hydroxyapatite- Hyaluronic Acid as Bone Healing Accelerator: in-vitro and in-vivo Studies on the Alveolar Bone of Wistar Rats

by Prihartini Widiyanti

Submission date: 29-Nov-2020 09:53PM (UTC+0800)

Submission ID: 1459140122

File name: C05._Fulltext_JIDMR_Carbonate_Hydroxyapatite_2142019.pdf (355.96K)

Word count: 5003

Character count: 28205

Carbonate Hydroxyapatite-Hyaluronic Acid as Bone Healing Accelerator: *in-vitro* and *in-vivo* Studies on the Alveolar Bone of Wistar Rats

Ernie Maduratna Setiawatie^{1*}, Prihartini Widiyanti^{2,3*}, Muhammad Ryan¹, Muhammad Rubianto¹

1. Department of Periodontics, Faculty of Dentistry, Universitas Airlangga, Surabaya, Indonesia.

2. Biomedical Engineering Study Program, Department of Physics, Faculty of Science and Technology, Universitas Airlangga, Surabaya, Indonesia.

3. Institute of Tropical Disease, Universitas Airlangga, Surabaya, Indonesia.

Abstract

Bone graft materials have been used extensively in periodontics support the success of the periodontal tissue treatment. By merely applying *Carbonate hydroxyapatite* for the treatment of bone is not the top way to form new bones. Hence, the utilization of regenerative materials such as *hyaluronic acid*, which is utilized in conjunction with *Carbonate hydroxyapatite* was expected to increase the success of periodontal treatment. To examine the effect of *Carbonate Hydroxyapatite* addition to hyaluronic acid 0.02%, post-tooth extraction on the number of osteoblasts and amount of Osteoprotegerin (OPG) and TGF Beta 1 in the Wistar rats' bone defect treatment. This study is constituted laboratory-based experimental research with a posttest-only control group. 27 rats (*Rattus norvegicus*) represented the animal study model in this research. The sample population was divided into 3 treatment groups; K0: the untreated control group; K1: socket filled with CHA Graft. K2: socket filled with CHA and hyaluronic acid. The K2 group had the highest number of osteoblasts when compared with the control group (\pm ; $P < 0.001$) and the strongest OPG and TGF- β 1 expression of K2 groups (\pm ; $P < 0.01$). The differences in each group were tested by one way ANOVA test ($\alpha = 0.05$). The carbonate hydroxyapatite combined with Hyaluronic Acid significantly increased the number of osteoblasts, OPG and TGF- β 1 in the new bone formations. It is a potential treatment for tissue engineering-based periodontal defect.

Experimental article (J Int Dent Med Res 2019; 12(4): 1280-1286)

Keywords: Carbonate hydroxyapatite, Hyaluronic acid, Osteoblast, OPG, TGF- β 1.

Received date: 06 November 2018

Accept date: 21 April 2019

Introduction

Indonesia is known as a country that is rich with bioresources and mineral sedimentation, including gypsum, calcium carbonate, and calcium hydroxide. Nevertheless, the research related to the use of polymer resources, local therapeutics agents and mineral sedimentation for medical applications is insufficient. To contribute to the development of the country, our research group has been being successful to scale up the technology in developing and fabricating carbonate hydroxyapatite (CHA) composite from indigenous bioresources as a bone substitute.

Carbonate hydroxyapatite (CHA) are calcium phosphate biomaterials for a bone substitute which are biocompatible, bioactive, and osteoconductive. It can be self-setting and forming of well-defined geometry in variable sizes and shapes to the mineralized bone. It could fill the bone defects or voids of irregular and patient-specific shape platforms.¹ However, although a carbonate substitution in CHA has increased bone formation, its performance depends on the presence and conditioning of functional osteoclasts.² Also, CHA tends to induce spontaneous differentiation of bone formation.³ Additionally, the CHA has been found to have poor mechanical properties, resulting in strong compression, weak in tension, and structural instability.^{4,5} granules

Nowadays, the use of regenerative materials, such as Hyaluronic Acid (HA), has been growing tremendously in various biomedical applications. Hyaluronic acid, a biodegradable, biocompatible, and linear non-sulfated polysaccharide component from N-acetyl-D-

*Corresponding author:

Ernie Maduratna Setiawatie and Prihartini Widiyanti
Department of Periodontics,
Faculty of Dentistry, Universitas Airlangga,
Surabaya, Indonesia.
E-mail: erniemaduratna@gmail.com; pwidiyanti@fst.unair.ac.id

glucosamine and glucuronic acid, which can be found in almost all biological fluids and tissues, serves an accelerating regeneration process through chemotaxis, proliferation, and differentiation of mesenchymal cells. With its critical role as signaling molecule in cell motility⁶, cell differentiation⁷ and wound healing.⁸ Physico-chemically, HA has interesting viscoelastic properties influenced by its polymeric and polyelectrolyte characteristics, making it suitable as lubricant, water absorption and retention.⁹⁻¹¹ HA also shares the role as bone induction with osteogenic substance, such as Bone Morphogenetic Protein-2 and osteopontin. However, the poor mechanical properties and rapid degradation of HA require a careful implementation.¹¹

As important biomaterials in bone healing, studies on CHA and HA have been widely performed in many ways, from observing in various forms for observing their capacities, to mixing with other materials for obtaining combined properties. The studies on the combination of hydroxyapatite and hyaluronic acid have been conducted in the dermatology for dermal fillers¹² and bone defect filler.¹³ The combination of hydroxyapatite, hyaluronic acid, and calcium sulfate for alveolar bone regeneration has been made by¹⁴. However, according to the authors' knowledge, there is no study of applying a combination of CHA and Hyaluronic acid for bone healing accelerator in the periodontal tissue treatment. We are performed an *in-vivo* study to determine the bone healing acceleration by observing bone marker such as OPG and TGF- β 1 and alveolar bone of Wistar rats' molar tooth extraction socket.

Materials and Methods

This study was laboratory-based experimental research with a post test-only control group on Wistar rats. In this study, a CHA powder was obtained from capsules made by Kimia Farma (Indonesia). Carbonated apatite Gama-CHA used in this study was a long research product of Tissue Engineering Research Group of Universitas Gadjah Mada with patent ID number P 0036890. Gama-CHA is a bone graft (substitute material) produced biomimetically (suitable for the human physiological condition) and identical with natural human bone. Gama-CHA contains carbonate

apatite and polymer such as denaturalized collagen that has a function to accelerating bone tissue regeneration process, has osteoconductive properties, osteoinduction, and osteogenesis. The carbonate apatite is the main component in the human bone that produced synthetically but identical (similar and uniform) so that it could avoid the immunological reaction that often occurs if using an allograft or xenograft. The fabrication process of Gama-CHA was performed at biomimetic temperature and condition (suitable with the physiological condition of the human body) to produce carbonate apatite that has low crystallinity that is identical with apatite in human and has the same Ca/P level as human bone. Gama-CHA was registered officially at Ministry of Health of the Republic of Indonesia with Distribution License Certificate Number of Indonesian Ministry of Health No.AKd 20602410125. The safety of Gama-CHA is guaranteed because it has met the requirements to get the distribution license.

This study received approval through an ethical clearance letter from the Faculty of Dental Medicine, Universitas Airlangga number 042/HRECC.FODM/IV/2017. 27 adult male Wistar strain rats with a weight of 300-350 grams were randomly assigned to one of three study groups. The first group consisted of Wistar strain treated with Carbonate Hydroxyapatite on the extraction socket of the mandibular incision. The second group was Wistar strain rats treated with carbonate hydroxyapatite mixed with hyaluronic acid on the extraction socket of the mandibular incision. The third group was Wistar strain rats with the extraction socket of mandibular incision filled with blood (control). OPG expression, and TGF β 1 was observed after 14 days.

The sample was divided into three groups; K0: the control group without treatment; K1: sockets filled with CHA graft. K2: sockets filled with CHA and HA. The study of an alveolar bone defect in the animal model was affected by extracting the first molar of the mandible using sterile needle holder clamps. Before tooth extraction was performed, the animal models were injected with 0.05- 0.1ml/10g body Intra-muscular (IM) rodent anesthesia (ketamine, xylazine, acepromazine and sterile isotonic saline). Following tooth extraction, all wounds were stitched with silk 3.0 and a period of 21 days elapsed before the animal study models

were sacrificed. OPG marker kit (Sigma Aldrich™, Germany) was then used to conduct Hematoxylin-Eosin (HE) and Immunohistochemistry (IHC) examinations. Statistical analysis was performed using Statistical Package for the Social Sciences (SPSS) 20.0 software for windows 8.1 (SPSSTM, Chicago, United States). Data obtained from the OPG expression then subjected to ANOVA analysis and, in cases of any difference between the treatment groups, a subsequent Tukey test was used.

Results

Microscopic observation and histological study

At 14 days post-operation, the rats in the respective groups were sacrificed by putting them into a container of diethyl ether 97%. The rat jaw was removed and fixed in 10% buffered formalin for two weeks. After fixation was completed, the mandibular jaw was cut at 5 mm above and under the surgery site including the surrounding tissue. Those parts containing the hard tissue (bone) need to be decalcified for block preparation and sectioning. This step was performed by placing the samples in nitric acid 10% for 24 hours. The presence of water in the tissue prevents the penetration of the preparing material (paraffin) into the tissue. So, to dehydrate the tissue, samples were placed in alcohol 50%, 70%, and 90% and absolute alcohol and then were placed in xylol to substitute for alcohol (dehydration process). In the infiltration step, samples were placed in molten paraffin (50 °C). From the samples embedded in paraffin, serial microscopic sections of 3-4 µm thick were prepared using a Leica microtome (Leica Microsystems, Wetzlar, Germany). Then the slices from the repaired bone cavity were stained with hematoxylin and eosin for microscopic examination.

Number of osteoblast cell counting using HE staining

The K2 group histopathological features confirmed a higher osteoblasts cell count compared with that of the K0, K1 groups (Figure 1). The use of this study of a statistical Analysis of Variance (ANOVA) test produced significant results 0.000 ($p < 0.05$). Tukey test was subsequently employed to analyse the relative significance of the number of osteoblasts within

each group. The K2 group recorded the highest number of osteoblasts when compared with its K0, K1 and K2 counterparts (Table 1). The Tukey test results revealed a very significant difference between the negative control group and all treatment groups ($p < 0.05$), as was also the case with the positive control group ($p < 0.05$). Observation under the microscope showed the histological image as in Figure 1.

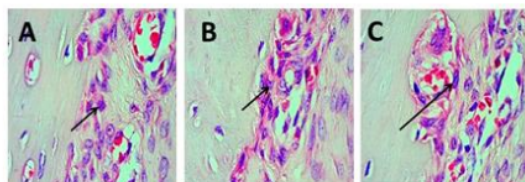


Figure 1. Alveolar bone tissue preparations showing the existence of osteoblast quantity on K0 control group. K1. Carbonate hydroxyapatite Group, K3 Carbonate hydroxyapatite combined with Hyaluronic acid Group.

No	Treatment Group	N	HE average results	Std. Deviation
1.	Carbonate hydroxyapatite	9	10.78	1.394
2.	Carbonate hydroxyapatite+ Hyaluronic acid	9	19.00	1.500
3.	Control	9	3.56	1.236

Table 1. The Mean and Standard Deviation of the Number of Osteoblasts.

Qualitative histopathological scoring

The slices were studied using an Olympus microscope (Olympus Optical Co., Ltd, Tokyo, Japan) in a high-power field ($\times 400$). Two slices from each defect were examined and graded by an expert pathologist for bone regeneration. OPG expression was characterized by brown coloration in osteoblasts due to antigenic binding and the presence of OPG antibodies. The K2 group experienced high OPG expression characterized by a stronger brown colour than the other three K groups. Group K0 contained fewer OPG expressions than K1 and K2 (Figure 2). The ANOVA test result confirmed significant OPG expression in all groups ($p < 0.05$), while that of the subsequent Tukey test revealed strong ANOVA Expression across them ($p < 0.05$). The mean results confirmed the K2 group as having the highest average expression of OPG. Based on the statistical analysis, the K2

group achieved the most significant result compared to the others (Table 2). Comparison of each treatment group with the control group revealed a marked difference ($p < 0.05$). This finding paralleled the outcome of a comparison between the K1 element within the positive control group and the K2 group ($p < 0.05$).

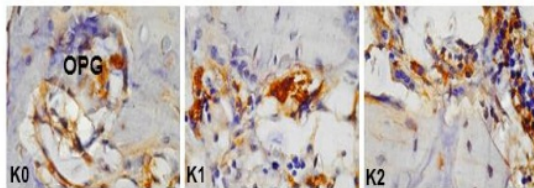


Figure 2. Alveolar bone tissue preparations showing the existence of OPG expression on K0 control group. K1. Carbonate hydroxyapatite Group, K2 Carbonate hydroxyapatite combined with Hyaluronic acid Group.

No	Time of treatment	Treatment Group	N	$\bar{x} \pm SD$	Sig.
1.		CHA	9	7.1±1.020	0.22
2.	14 days	CHA+HA	9	15.22±1.035	0.22
3.		C	9	3.12±1.014	0.22

Table 2. OPG Calculation Result in 14 Day Group.

Transforming growth factor (TGF-β1) expression with immunohistochemistry (IHC) examination

Based on Figure 3, the highest TGF β1 expression was on the group with carbonate hydroxyapatite and hyaluronic acid with an average of 10.67 and the lowest one was on the control group with an average of 2.33, while the treatment using carbonate hydroxyapatite was 5.11 (Table 3).

No.	Duration of Treatment	Treatment Group	N	$\bar{x} \pm SD$	Sig.
1.		CHA	9	5.11±1.269	0,78
2.	7 days	CHA+HA	9	10.67±2.449	0,78
3.		Control	9	2.33±1.225	0,78
4.		CHA	9	11.33±1.500	0,22
5.	14 days	CHA+HA	9	15.78±2.635	0,22
6.		Control	9	5.22±1.394	0,22

CHA = Carbonate hydroxyapatite, HA = Hyaluronic acid, C = control

Table 3. The Mean of TGF-β1 Expression on 7 and 14 days

The highest TGF β1 expression on the 14th day was on the carbonate hydroxyapatite and hyaluronic acid with an average of 15.78 and the lowest one was on the control group with an average of 5.22, while the treatment using carbonate hydroxyapatite was 11.33.

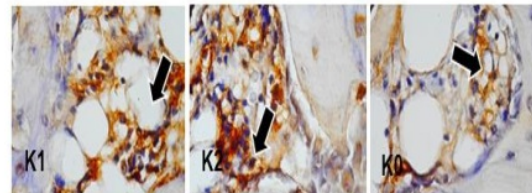


Figure 3. Preparation of Alveolar Bone tissue showing 14-day TGF-β1 expression at 400X magnification, arrows indicate positive expression of TGF β1 in osteoblast cells (Expression of TGF-β1 day 14 (K1) Carbonate hydroxyapatite group, (K2) Carbonate hydroxyapatite group mixed Hyaluronic acid and (K0) Control Group).

Discussion

Bone defects might develop in various clinical situations such as periodontal disease, tooth extraction or orthopedic surgeries. The conventional methods of bone repair which commonly were used, including autografts and allografts. Autografts are limited regarding the availability of materials and may result in donor site morbidity. Using allografts may be more desirable in some cases, but the possible immune reaction and infection transmission limit their application.¹⁵ To overcome these limitations, various synthetic bone substitutes made of metal, ceramics, polymers, etc., have been introduced to accelerate and improve the process of bone regeneration, though their safety, effectiveness, and efficacy remain uncertain. The new materials which are used should help us to reduce the operation time, scar size, post-operation pain, and also improve patient recovery. An ideal material for bone regeneration, as indicated by prior studies, should be biocompatible, biodegradable, easy to apply, and effective on bone repair.¹⁶ It is important for bone replacement materials to be highly adaptable to the bone defects. Our study is different from the others regarding using pure hyaluronic acid 0.02% and also applying with CHA in a powder form to achieve good adaptation to bone defects. Chevrier et al. showed in their study that HA

increases vascularization and induces granulation tissue generation. It has been observed that HA, a natural biopolymer, may act as wound healing accelerators, bone substitutes, antimicrobial agents, and may show hemostatic activities. It was documented that these substances are biodegradable and nontoxic.

The bone substitution with bone graft material has an important role on the regenerative dentistry therapy. The bone graft material plays a role as a scaffold or framework so that the bone cell could proliferate. The carbonate hydroxyapatite is a synthetic ceramic bone graft that is similar to the mineral structure of natural bone. The carbonate hydroxyapatite was absorbed by the osteoclast faster and then replaced by the new bone cells that are better than hydroxyapatite. It caused carbonate hydroxyapatite preferable to be used in the bone tissue repair.² The carbonate hydroxyapatite is also osteoconductive and bioresorbable.^{17,18}

Hyaluronic acid also called hyaluronan or hyaluronate is a carbohydrate polymer with high molecular weight consisted of a repetition of D-linear glucuronic acid and D N-acetylglucosamine disaccharide units. The hyaluronic acid is one of the primary polysaccharides from an extracellular matrix component available in the embryonic mesenchyme, vitreous humor, skin, and the other organ and tissue.²⁰ Most of the body cells could synthesize the hyaluronic acid. The synthesis occurs in the cell membrane. The hyaluronic acid is a natural hygroscopic molecule that is safe to use intrinsically and non-toxic.¹⁹⁻²¹ In the early stage of inflammation, the tissue contains hyaluronic acid that has a function as an antimicrobial agent. The hyaluronic acid could accelerate the tissue regeneration by using chemotaxis, proliferation, mesenchymal cell differentiation, inducing the osteogenic agent, such as bone morphogenetic protein-2 (BMP-2) and osteopontin.²²

Some growth factors were needed in the bone fracture healing. The growth factor such as Transforming Growth Factor-Beta 1 (TGF- β 1), Fibroblast Growth Factor 2 (FGF-2), Platelet-Derived Growth Factor-B (PDGF-B), and insulin-like growth factor 1 (IGF-1) are not only has a role as cartilage regulator and bone formation, but also crucial in controlling the bone fracture repair. The growth factors are produced by mesenchymal cells, chondrocytes, and osteoblast in the inflammation sites.²⁴ TGF- β

organizes several biological processes, including cell proliferation, cell viability, cell differentiation, cell migration, and production of extracellular matrix (ECM). The combination of cellular response in mediating the TGF- β effect to body immune response, angiogenesis, wound healing, and bone formation. TGF- β is expressed starting in the early stage as a potential chemotaxis factor from mesenchymal progenitor cell and macrophage to the wound healing, proliferation induction, and stimulate the production of extracellular collagen matrix by osteoblast.²

This study was aimed to observe OPG expression and TGF- β 1 around the osteoblast cells in the tooth socket of male Wistar strand rats with the treatment of carbonate hydroxyapatite and hyaluronic acid. These materials were used in the socket preservation procedure and periodontal flap surgery and were expected to help the new bone formation process through osteoinduction and osteoconduction process. This study used 9 male Wistar strand rats in every group with a total of 54 rats.

The osteoblast originated from mesenchymal stem cell (progenitor cells) of bone marrow stromal cells and responsible in the bone matrix synthesis and the next mineralization process. The osteoblast is responsible for controlling the osteoclast and bone matrix decomposition.²⁴ The osteoblast contains alkaline phosphatase, organic phosphate-breaking enzyme, parathyroid and estrogen hormone receptors, growth factor, physical activities, and acting as the other stimuli that go through osteoblast as effect carrier in the bone.²⁵

TGF- β 1 is a superfamily protein that is abundant in the bone tissue. TGF- β 1 is latent present in the bone matrix and active while the osteoclastic resorption occurs. TGF- β 1 as a potential stimulator in the bone formation promotes the osteoblast differentiation and the synthesis of the osteoid matrix and inhibit the synthesis of protease from matrix metalloproteinase (MMP). TGF- β 1 inhibits the bone resorption by reducing the formation and differentiation of osteoclast and stimulate the apoptosis of osteoclast.²⁴⁻²⁶ TGF- β 1 is present in the hematoma after wound takes place, is expressed at the osteoblast proliferation in the intramembranous ossification and chondrocyte proliferation while the chondrogenesis and endochondral ossification process occur.²⁷ TGF- β 1 is produced from platelet towards hematoma

in the fracture, then synthesized by the osteoblast and chondrocyte during the healing process, so that the TGF- β 1 expression increase in the second week after fracture. The chemotaxis effect of TGF- β 1 stimulates the bone formation by inducing the mesenchymal cell differentiation process to be osteoblast.²⁸

Based on the study of Zhou et al.²⁹ the osteogenic response occurred in the seventh day until 25th day, while the modeling and bone maturation occurred on the 14th day until the 35th day. In this study, it was shown that the OPG and TGF- β 1 expression on the control group increased at the 14th day. The increase of TGF- β 1 expression was suitable with Joyce's analysis. The result showed that the presence of TGF- β 1 in the soft callus increased gradually from the 7th day until the 14th day after fracture and decreased from 14th day until the 17th day.^{30,31} Meyer Jr. stated that the highest TGF- β RNA level was on the 7th day until 14th day from the fracture.³¹ The increase of TGF- β 1 expression started on the 7th day until the 14th day. It is showed that the TGF- β 1 had a role in the early stage of differentiation. In line with the statement of Kasagi³², TGF- β 1 had a role in increasing the protein production of bone extracellular matrix in the early stage of osteoblast differentiation, which was in the process of pre-osteoblast an immature osteoblast formation.

In the treatment group of carbonate hydroxyapatite, an average of OPG and TGF- β 1 expression on the 4th day increased on the addition of hyaluronic acid significantly. It was concluded that the treatment of carbonate hydroxyapatite and hyaluronic acid could accelerate the new bone formation, because of its osteoconductive property. According to the statement of Calasans-Maia³³ after 7 days of carbonate hydroxyapatite treatment on the tooth socket of the rats, the osteoid deposition around the granule of carbonate hydroxyapatite could be seen, compared to the group of the tooth socket of the rats that treated with a blood clot. It was caused by the osteoconductive property of carbonate hydroxyapatite.

The in vitro study, the hyaluronic acid has a role in increasing the formation of osteoblast from the bone with increasing the mesenchymal cell differentiation and migration.³⁴ The hyaluronic acid with the correct molecular weight and dose could improve the osteogenic and

osteoconductive properties from the bone graft and provide the stimulating effect on the osteoblast. The synthesis of hyaluronic acid related to the expression of the number of anabolic hormone and growth factor.³⁵

The group with the treatment of carbonate hydroxyapatite and hyaluronic acid had the highest osteoblast average number, OPG, and TGF- β 1 expression on the 14th day compared to the other group. The application of hyaluronic acid could increase the biomechanics and biochemistry ability of the neocartilage and also accelerate the TGF- β 1 signals and extracellular matrix receptors.³⁶ The use of bone graft materials combined with the biological mediator, such as hyaluronic acid could enhance the mechanical strength and reduce the bone resorption.³⁵ The application of hyaluronic acid with metronidazole combined with hydroxyapatite after tooth retraction could increase the number of osteoblast in the bone defect treatment in the rats.³⁷ CHA + HA composite improves the mechanical strength of the scaffold material. Usui et al., in their study found that HA has favorable compatibility with the bone tissue and promote bone regeneration and may accelerate bone formation stimulated by recombinant human bone morphogenetic protein-2 (BMP-2).³⁸

Conclusion

In conclusion, the treatment using Carbonate hydroxyapatite and Hyaluronic Acid was proved to be used to increase the number of osteoblast on the bone defect treatment.

It is possible that a combination of CHA and HA work on the proliferation of osteoblast cell lineage as well as induction of angiogenesis, and promotion of osteoblast differentiation.

In this study, a good response was seen in the use of a combination of Hyaluronic Acid and Carbonate hydroxyapatite compared with merely using Carbonate hydroxyapatite. It was seen from OPG and TGF- β 1 in the healing process of the male Wistar rats' sockets. The combination of Hyaluronic Acid and Carbonate hydroxyapatite was proven to increase the number of osteoblasts in the treatment of bone defects.

Acknowledgements

The authors would like to thank to Faculty of Dental Medicine Universitas Airlangga for all support.

Conflict of Interest

The authors declare that there is no conflict of interest regarding the publication of this article.

References

1. Tang PF, Li Gang, et al. Development, Characterization, and Validation of Porous Carbonated Hydroxyapatite Bone Cement. *J Biomed Mater Res Part B: Appl Biomater* 2009;886-93.
2. Spence G, Philips S, et al. Bone formation in a carbonate-substituted hydroxyapatite implant is inhibited by zoledronate. *J Bone Joint Sur* 2008;90-B(12):1635-40.
3. Ripamonti U, Crooks J, et al. The induction of bone formation by coral-derived calcium carbonate/hydroxyapatite constructs. *Biomater* 2009;30(7):1428-39.
4. Pisarcik M, Bakos D, et al. Non-Newtonian properties of hyaluronic acid aqueous solution. *Colloids Surfaces A: Physicochemical Eng Aspects* 1995;97(3):197-202.
5. Jebahil S, Saoudi M. Biologic Response to Carbonated Hydroxyapatite Associated with Orthopedic Device: Experimental Study in a Rabbit Model. *Korean J Pathol* 2012;46(1):48-54.
6. Hall CL, Turley EA. Hyaluronan: RHAMM mediated cell locomotion and signaling in tumorigenesis. *J Neuro-Oncol* 1995;26(3):221-9.
7. Huang L, Cheng YY, et al. The effect of hyaluronan on osteoblast proliferation and differentiation in rat calvarial-derived cell cultures. *J Biomed Mater Res A* 2003;66(4):880-4.
8. Sasaki T, Watanabe C. Stimulation of osteoinduction in bone wound healing by high-molecular hyaluronic acid. *Bone* 1995;16(1):9-15.
9. Goa KL, Benfield P. Hyaluronic Acid: A Review of its Pharmacology and Use as a Surgical Aid in Ophthalmology, and its Therapeutic Potential in Joint Disease and Wound Healing. *Drugs* 1994;47(3):536-66.
10. Hahn MS, Kobler JB, et al. Quantitative and comparative studies of the vocal fold extracellular matrix. I: Elastic fibers and hyaluronic acid. *Ann Otol Rhinol Laryngol* 2006;115(2):156-64.
11. Jeon O, Song SJ, et al. Mechanical properties and degradation behaviors of hyaluronic acid hydrogels cross-linked at various cross-linking densities. *Carbohydr Polym* 2007;70(3):251-7.
12. Jeong SH, Fan YF, et al. Long-lasting and bioactive hyaluronic acid-hydroxyapatite composite hydrogels for injectable dermal fillers: Physical properties and in vivo durability. *J Biomater Appl* 2016;31(3):464-74.
13. Dennis SC, Whitlow J, et al. Hyaluronic-Acid-Hydroxyapatite Colloidal Gels Combined with Micronized Native ECM as Potential Bone Defect Fillers. *Langmuir* 2017;33(1):206-18.
14. Subramaniam S, Fang YH, et al. Hydroxyapatite-calcium sulfate-hyaluronic acid composite encapsulated with collagenase as bone substitute for alveolar bone regeneration. *Biomater* 2016;74:99-108.
15. Newman MG, Takei N, Klovkevold. *Clinical Periodontology* 11th ed. Elsevier Saunders, Missori 2012;41-43,204-205,572-588.
16. Nandya. Status Kesehatan Jaringan Periodonsium Pada Pasien Diabetes Mellitus Tipe 2 Dibandingkan Dengan Pasien Non Diabetes Mellitus Berdasarkan Gpi. *Jurnal e-GiGi (eG)* 2010;3(1).
17. Bang LT, Long BD, Othman R. Carbonate Hydroxyapatite and Silicon-Substituted Carbonate Hydroxyapatite: Synthesis, Mechanical Properties, and Solubility Evaluations. *Sci World J* 2014;1-9. DOI: <http://dx.doi.org/10.1155/2014/969876>.
18. Aufan MR, Daulay AH, Indriani D, Nuruddin A, Purwasasmita BS. Sintesis Scaffold alginat-Kitosan-Karbonat Apatit sebagai bone graft menggunakan metode freeze drying. *Jurnal Biofisika* 2012;8(1):16-24.
19. Bogaerde L. Treatment of Infrabony Periodontal Defects with Esterified Hyaluronic Acid: Clinical Report of 19 Consecutive Lesions. *Int J Periodontics Restor Dent* 2009;29(3):315-23.
20. Dahiya P, Kamal R. Hyaluronic acid: A boon in periodontal therapy. *North Am J Med Sci* 2013;5(5):309-15.
21. Aguado E, Pascaretti-Grizon F. β -TCP granules mixed with reticulated hyaluronic acid induce an increase in bone apposition. *J Biomed Mater* 2014;9(1):1-10.
22. Mendes RM, Silva GA, et al. Sodium hyaluronate accelerates the healing process in tooth sockets of rats. *Arch Oral Biol* 2008;53(12):1155-62.
23. Radhi IH, Al-Ghaban NM. Evaluation the effect of hyaluronic acid on bone healing process in rabbits (Immunohistochemical study for TGF- β). *J Bagh Coll Dent* 2015;27(1):111-6.
24. Kini, Usha ZN. Physiology of Bone Formation, Remodeling, and Metabolism. *Radionuclide and Hybrid Bone Imaging*. Fogeman, et al. (eds). Springer-Verlag Berlin Heidelberg 2012;XIV(1046):29-63.
25. Harada S, Rodan GA. Control of osteoblast function and regulation of bone mass. *Nature* 2003;423(6937):349-55.
26. Baylink DJ, Finkelmann RD, Mohan S. Growth factors to stimulate bone formation. *J Bone Miner Res* 1993;8(Suppl 2):S565-S572.
27. Liu Z, Luyten FP, et al. Molecular signaling in bone fracture healing and distraction osteogenesis. *Histol Histopathol* 1999;14(2):587-95. DOI: 10.14670/HH-14.587.
28. Sarahudi K, Thomas A, et al. Elevated transforming growth factor-beta 1 (TGF- β 1) levels in human fracture healing. *Injury* 2011;42(8):833-7.
29. Zhou FH, Foster BK, et al. Expression of proinflammatory cytokines and growth factors at the injured growth plate cartilage in young rats. *Bone* 2004;35(6):1307-15.
30. Joyce ME, Terek RM, et al. Role of Transforming Growth Factor - β in Fracture Repair. *Trans Growth Factors: Chem, Biol, and Ther* 1990;593(1):107-23.
31. Poniatowski AA, Wójdasiewicz P, et al. Transforming Growth Factor Beta Family: Insight into the Role of Growth Factors in Regulation of Fracture Healing Biology and Potential Clinical Applications. *Mediators Inflamm* 2015;137823. DOI: 10.1155/2015/137823.
32. Kasagi S, Chen W. TGF-beta1 on osteoimmunology and the bone component cells. *Cell Bioscience* 2013;3:4.
33. Calasans-Maia M, Melo B. Cytocompatibility and biocompatibility of nanostructured carbonated hydroxyapatite spheres for bone repair. *J Appl oral Sci* 2015;23(6):599-608.
34. Aslan M, Simsek G, Dayi E. The Effect of Hyaluronic Acid-supplemented Bone Graft in Bone Healing: Experimental Study in Rabbits. *J Biomater Appl* 2006;20(3):209-20.
35. Elkarary A. Alveolar Sockets Preservation Using Hydroxyapatite/Beta tricalcium Phosphate with Hyaluronic Acid (Histomorphometric study). *J Am Sci* 2013;9(1):556-63.
36. Responde DJ, Natoli RM, Athanasiou KA. Identification of potential biophysical and molecular signalling mechanisms underlying hyaluronic acid enhancement of cartilage formation. *J R Soc Interface* 2012;9(77):3564-73.
37. Setiawati EM. Hydroxyapatite combined with hyaluronic acid metronidazole gel increased the quantity of osteoblasts in the alveolar bone wistar rat. *Dent J (Majalah Kedokteran Gigi)* 2015;48(4):204-8.
38. Usui Y, Aoki K, et al. Carbon Nanotubes with High Bone-Tissue Compatibility and Bone-Formation Acceleration Effects. *Small* 2008;4(2):240-6.

Carbonate Hydroxyapatite-Hyaluronic Acid as Bone Healing Accelerator: in-vitro and in-vivo Studies on the Alveolar Bone of Wistar Rats

ORIGINALITY REPORT

23%

SIMILARITY INDEX

19%

INTERNET SOURCES

12%

PUBLICATIONS

3%

STUDENT PAPERS

PRIMARY SOURCES

1

www.ncbi.nlm.nih.gov

Internet Source

9%

2

Submitted to Universitas Airlangga

Student Paper

3%

3

Radhi , Ibtihal H. | Al-Ghaban , Nada M..

"Evaluation the Effect of Hyaluronic Acid on Bone Healing Process in Rabbits (

Immunohistochemical Study for TGF - β)",

Journal of Baghdad College of Dentistry, 2015

Publication

1%

4

Zhou, F.H.. "Expression of proinflammatory cytokines and growth factors at the injured growth plate cartilage in young rats", Bone,

200412

Publication

1%

5

www.mdpi.com

Internet Source

1%

www.jidmr.com

6	Internet Source	1%
7	worldwidescience.org Internet Source	1%
8	fkg.ugm.ac.id Internet Source	1%
9	mafiadoc.com Internet Source	1%
10	Pei-Fu Tang. "Development, characterization, and validation of porous carbonated hydroxyapatite bone cement", Journal of Biomedical Materials Research Part B Applied Biomaterials, 2009 Publication	1%
11	medcraveonline.com Internet Source	1%
12	Chiquita Prahasanti, Alexander Patera Nugraha, Tania Saskianti, Ketut Suardita, Wibi Riawan, Diah Savitri Ernawati. " Exfoliated Human Deciduous Tooth Stem Cells Incorporating Carbonate Apatite Scaffold Enhance BMP-2, BMP-7 and Attenuate MMP-8 Expression During Initial Alveolar Bone Remodeling in Wistar Rats (<i>Rattus norvegicus</i>)	<1%

", Clinical, Cosmetic and Investigational Dentistry, 2020

Publication

13

repository-tnmgrmu.ac.in

Internet Source

<1%

14

www.lawinsport.com

Internet Source

<1%

15

www.hindawi.com

Internet Source

<1%

16

www.jofamericanscience.org

Internet Source

<1%

17

P Widiyanti, N D W Rini, M N Kirana, T Astutik.
"Synthesis and Characterization of Collagen-Chitosan-Sodium Hyaluronates as Artificial Cornea", Journal of Physics: Conference Series, 2019

Publication

<1%

18

Camilo Zamora-Ledezma, Lionel Buisson, Simon E. Moulton, Gordon Wallace et al.
"Carbon Nanotubes Induced Gelation of Unmodified Hyaluronic Acid", Langmuir, 2013

Publication

<1%

19

kinampark.com

Internet Source

<1%

20

iapc-obp.com

Internet Source

<1%

21 www.liebertpub.com <1%
Internet Source

22 www.researchgate.net <1%
Internet Source

23 Yuhua Sun, Jing Tan, Xianzhen Yin, Baohua Wu, Bo Feng. "Regulation of Osteoblast Differentiation by Affinity Peptides of TGF- β 1 Identified via Phage Display Technology", ACS Biomaterials Science & Engineering, 2018 <1%
Publication

24 Nike Hendrijantini, Tuti Kusumaningsih, Rostiny Rostiny, Pungky Mulawardhana, Coen Pramono Danudiningrat, Fedik Abdul Rantam. "A potential therapy of human umbilical cord mesenchymal stem cells for bone regeneration on osteoporotic mandibular bone", European Journal of Dentistry, 2019 <1%
Publication

25 Cory J. Xian. "Folinic acid attenuates methotrexate chemotherapy-induced damages on bone growth mechanisms and pools of bone marrow stromal cells", Journal of Cellular Physiology, 03/2008 <1%
Publication

26 journals.plos.org <1%
Internet Source

27 Jeon, O.. "Mechanical properties and degradation behaviors of hyaluronic acid hydrogels cross-linked at various cross-linking densities", Carbohydrate Polymers, 20071001
Publication <1%

28 J. C. Antunes. "Novel poly(L-lactic acid)/hyaluronic acid macroporous hybrid scaffolds: Characterization and assessment of cytotoxicity", Journal of Biomedical Materials Research Part A, 2010
Publication <1%

29 Förster, Yvonne, Ricardo Bernhardt, Vera Hintze, Stephanie Möller, Matthias Schnabelrauch, Dieter Scharnweber, and Stefan Rammelt. "Collagen/glycosaminoglycan coatings enhance new bone formation in a critical size bone defect — A pilot study in rats", Materials Science and Engineering C, 2017.
Publication <1%

Exclude quotes

Off

Exclude matches

< 7 words

Exclude bibliography

On

Carbonate Hydroxyapatite-Hyaluronic Acid as Bone Healing Accelerator: in-vitro and in-vivo Studies on the Alveolar Bone of Wistar Rats

GRADEMARK REPORT

FINAL GRADE

/0

GENERAL COMMENTS

Instructor

PAGE 1

PAGE 2

PAGE 3

PAGE 4

PAGE 5

PAGE 6

PAGE 7
