

# Application of Artificial Neural Network for Type 2 Diabetes Mellitus Detection Using Buccal Cell Images

*by* Prihartini Widiyanti

---

**Submission date:** 13-May-2019 04:10PM (UTC+0800)

**Submission ID:** 1129598170

**File name:** C10\_JIDMR\_Buccal\_Cell\_Images\_Vol\_10\_No\_2\_20\_Mei\_2017.pdf (471.65K)

**Word count:** 3965

**Character count:** 21321

## Application of Artificial Neural Network for Type 2 Diabetes Mellitus Detection Using Buccal Cell Images

Priyanka Kusuma Wardhani<sup>1</sup>, Prihartini Widiyanti<sup>1,2\*</sup>, Franky Chandra Satria Arisgraha<sup>1</sup>

1. Biomedical Engineering Study Program, Faculty of Science and Technology, Universitas Airlangga, Indonesia.  
2. Institute of Tropical Disease, Universitas Airlangga, Indonesia.

### Abstract

Diabetes mellitus (DM) is metabolic disease causing hyperglycemia due to insulin action anomaly. DM can cause cellular changes, including buccal cell. Blood tests are used to diagnosis diabetes, so non-invasive test is required for diagnosis of diabetes.

Accordingly, this research aims to design non-invasive system based on artificial neural network for type 2 DM detection using buccal cell images. Buccal cells smears were obtained from 30 subjects suffering from type 2 DM and 30 normal subjects. The smears were stained by using Papanicolaou method. Each slide were observed under digital microscope and were evaluated. The system was designed by using MATLAB with image processing and Probabilistic Neural Network (PNN) algorithm to classify features. Buccal cell images were segmented to get features. The features used in this study were nucleus area, nucleus perimeter and nucleus circularity.

Nucleus areas and perimeters in type 2 DM group were higher than those in control group with similar nucleus roundness in both groups. Forty nucleus feature datasets were used for training process, while 20 nucleus feature datasets were used for testing process.

The optimal PNN value was 0.4 g constant. The optimal accuracy of training was 92.5%, while the optimal accuracy of testing was 90%.

*Clinical article (J Int Dent Med Res 2017; 10(2): pp. 253-259)*

**Keywords:** Type 2 diabetes mellitus, buccal cell images, artificial neural network.

**Received date:** 05 April 2017

**Accept date:** 20 May 2017

### Introduction

Diabetes prevalence is high and tends to increase sharply. In 2013, International Diabetes Federation (IDF) noted that there were 382 million people with diabetes and predicted to increase 55% in 2035<sup>1</sup>. According IDF (2013), Indonesia had 8.5 million people with diabetes. Diabetes Mellitus (DM) is an endocrine disorder in the metabolism of carbohydrates, lipids, and proteins due to deficiency of insulin in the body, the target tissue resistance to insulin, or both. Until now, there has been no therapy that can cure diabetes completely, but DM can still be controlled<sup>2</sup>. DM is divided into two conditions, type 1 DM and type 2 DM. The number of patients with type 2 DM is

growing faster as obesity rate is increasing, while human physical activity is decreasing.<sup>3</sup>

Long-term high blood glucose causes diabetes patients prone to complications. A number of complications often occur in patients with DM, such as, microvascular abnormalities, coronary heart disease, and macrovascular disorders, such as stroke, heart disease systemic, and gangrene.<sup>2</sup> Soft tissue abnormalities have been reported to be associated with diabetes mellitus in the oral cavity such periodontal diseases (periodontitis and gingivitis); salivary dysfunction leading to a reduction in salivary flow and changes in saliva composition, and taste dysfunction. Oral fungal and bacterial infections have also been reported in patients with diabetes. There are also reports of oral mucosa lesions in the form of stomatitis, geographic tongue, benign migratory glossitis, fissured tongue, traumatic ulcer, lichen planus, lichenoid reaction and angular cheilitis.<sup>4-8</sup> In addition, delayed mucosal wound healing, mucosal neuro-sensory disorders, dental carries and tooth loss has been reported in patients with diabetes.<sup>9</sup> The prevalence and

#### \*Corresponding author:

Prihartini Widiyanti  
Biomedical Engineering Study Program,  
Faculty of Science and Technology, Universitas Airlangga,  
Indonesia.  
E-mail: [pwidiyanti@fst.unair.ac.id](mailto:pwidiyanti@fst.unair.ac.id)

the chance of developing oral mucosal lesions were found to be higher in patients with diabetes compared to healthy controls.<sup>10</sup> Diabetic patients have more severe periodontitis and Diabetes Mellitus negatively affects oral health as reflected by the higher decay, missing, filling, total score (DMFT) scores in diabetic patients.<sup>11</sup>

Early diagnosis for DM is one of the important aspects to reduce the possibility of complications.<sup>4</sup> Diagnosis of DM using blood tests is the most widely used and accurate. However, this method gives a psychological effect on patients, such as fear or discomfort due to blood sampling. In addition, this method also requires considerable time in blood analysis, so it will be useful to find a new tool that can replace, complement, or compare the results obtained, yet still provides patient with greater comfort.<sup>5</sup>

Several soft tissue abnormalities have been reported to be associated with diabetes mellitus in the oral cavity. These complications include periodontal diseases (periodontitis and gingivitis); salivary dysfunction leading to a reduction in salivary flow and changes in saliva composition, and taste dysfunction. Oral fungal and bacterial infections have also been reported in patients with diabetes. There are also reports of oral mucosa lesions in the form of stomatitis, geographic tongue, benign migratory glossitis, fissured tongue, traumatic ulcer, lichen planus, lichenoid reaction and angular cheilitis.<sup>6-10,21-25</sup>

In addition, delayed mucosal wound healing, mucosal neuro-sensory disorders, dental caries and tooth loss has been reported in patients with diabetes.<sup>12</sup> The prevalence and the chance of developing oral mucosal lesions were found to be higher in patients with diabetes compared to healthy controls.<sup>13</sup>

Several clinical and paraclinical techniques are available for evaluation of oral mucosa changes. Oral cytology is one of exfoliative cytology method, the study of cells taken or smeared on the surface epithelium of organ.<sup>5</sup> Previously, exfoliative cytology method was very limited because of observer's subjectivity, so the possibility of wrong diagnosis was very large. But now, it can be overcome with quantitative methods, such as cytomorphometric analysis.<sup>14</sup>

Cytomorphometric is a quantitative measurement of cell using graphic interface.<sup>15</sup> Cytomorphological features include nucleus (nucleus size, shape, or membrane) and

cytoplasmic qualities. Some characteristics are unique to certain disease processes, aiding greatly in diagnosis. Oral cytology has been used for early detection of premalignant and malignant oral lesion, microbial disease, Fe-deficiency, and cell proliferation in smoker.<sup>16</sup>

Some of exfoliative cytology studies show there are changes in buccal mucosa cells and epithelial cells in mouth in the case of type 2 DM and it can be detected by cytomorphometric analysis.<sup>14,17</sup>

According to Sonawane et al<sup>4</sup> exfoliative cytology has potencies to be developed into a diagnostic method in type 2 DM. However, the previous studies by Sonawane et al<sup>4</sup>, Rivera and Nunez-de-Mendoza,<sup>5</sup> Suvarna et al,<sup>14</sup> Ahmed and Garib<sup>16</sup> and Jajarm et al<sup>17</sup> provide quantitative value on nucleus, cytoplasm wide, and nucleus-cytoplasm ratio. Based on the previous studies, we conducted a study to classify buccal epithelial cells for non-invasive diagnosis of type 2 DM. This study is expected to build an application that is able to detect type 2 DM through buccal cell image and artificial neural network (ANN).

## Materials and methods

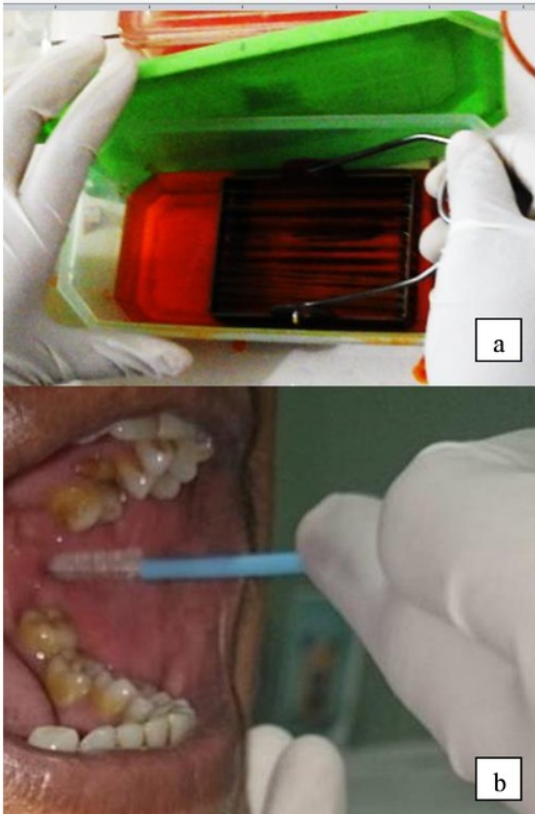
Subjects were randomly selected from adult patients at the Department of Diabetes, Dr. Ramelan Marine Hospital. The subjects were divided into two groups, consisting of 30 subjects with type 2 DM and 30 non-diabetic subjects as the control group.

The subjects with smoking and tobacco chewing habits, habitual alcohol consumption, oral sepsis presence, other systemics disease presences, and non-diabetic medication consumption were excluded from this study.

Previous studies have demonstrated that cellular and nuclear size are influenced by these factors [Rivera].

The subject was rinsed with NaCL 0.9% to sterilize the buccal cavity. The surface of buccal mucosa was smeared with cytobrush and transferred to a clean and dry glass slide.

The slide was immediately fixed in 96% alcohol for 30 minutes and stained by using Papanicolaou technique. Each slide was observed under microscope (Olympus CX21) at 400× magnification.



**Figure 1.** (a) Swabs from the buccal mucosa (b) Samples stained by using Papanicolaou technique.

Next, three clearly defined cells with good staining on each slide were selected from different location to avoid repetition of the cells. The images were captured by digital camera which was attached to the microscope and saved in computer as a bitmap (\*.bmp). Each image was cropped to the size of 180×180 pixels to reduce noise and computation time. The buccal cell images should be converted to grayscale intensity image<sup>18</sup>:

$$G_s = (0.2989 \times R) + (0.5870 \times G) + (0.1141 \times B) \quad (1)$$

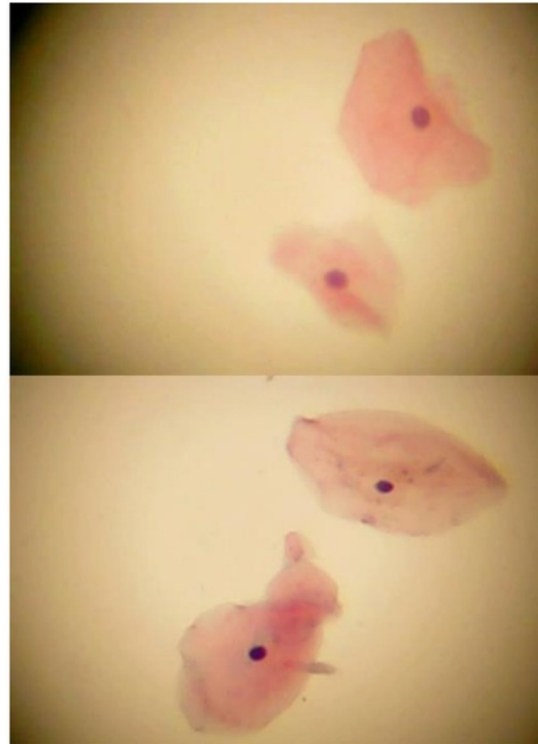$G_s$  is grayscale weighted average, and  $R$ ,  $G$ , and  $B$  are weighted averages of the red, green, and blue values.

The grayscale image should be enhanced by using contrast stretching, brightness, and filtering process. The filter used in this study is

Gaussian Low Pass Filter. The transfer function of GLPF is given as follow<sup>19</sup>:

$$H(u, v) = e^{-D^2(u, v) / 2D_o^2} \quad (2)$$

$D_o$  is specified non-negative number. In this study,  $D_o$  is down to 0.7. Then, the image is segmented to get nucleus region.



**Figure 2.** (a) Pap stained cytological smear representative of diabetic group (b) Pap stained cytological smear representative of normal group.

Identification buccal cell of type 2 DM or is actually based on the nucleus's geometric shape features. The features used in this study were nucleus area, perimeter, and circularity. The nucleus area can be calculated by adding the amount of the nucleus pixels, while the nucleus perimeter can be determined by adding the amount of the edge of nucleus pixels. Hence, the nucleus circularity can be defined as below<sup>19</sup>:

$$circularity (R) = 4\pi \frac{A(R)}{P^2(R)} \quad (3)$$

After the nucleus features of all those three cells on each slide were measured, the averages were derived from each individual, so there were three features in a feature dataset of each individual. The features were then used as an input of classification. The classification step used supervised classification algorithm, namely, Probabilistic Neural Network (PNN).

It was divided into two steps, namely training and testing. In this study, 20 feature datasets of each group were used for training process; 10 feature data sets of each group were used for testing process. A parameter that would be varied is  $g$ . The performance of the algorithm can be evaluated by computing the percentages of Accuracy, the respective definitions are as follow<sup>20</sup>:

$$Accuracy = \frac{\sum(TP+TN)}{n} \times 100\%$$

(4)  
 $TP$  is the number of true positives,  $TN$  is the number of true negatives, and  $n$  is the number of data.

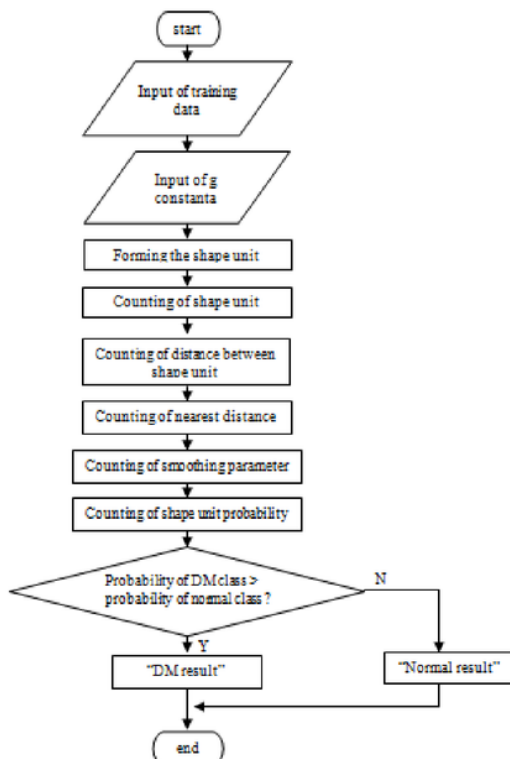


Figure 3. PNN Algorithm.

## Results

### Image Processing

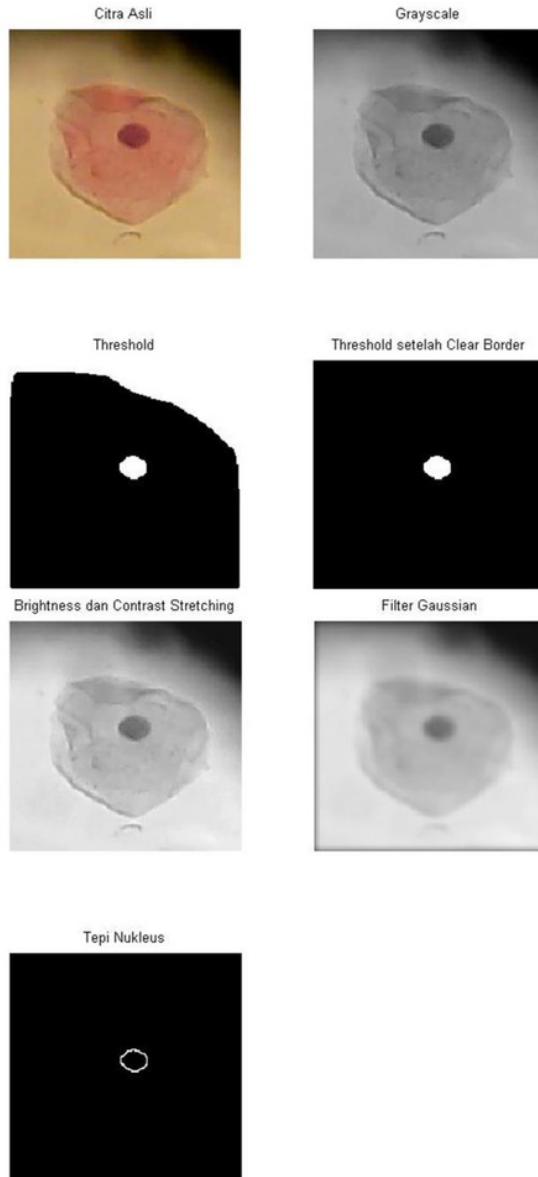
Before buccal cells of patients were classified as with type 2 diabetes or normal, the buccal cell image had been conducted first by using digital image processing to obtain features. Next, the image of the buccal cell obtained from buccal cell slide were observed by using a digital microscope on the computer. Consequently, three cells on each slide were evaluated from three different points. Thus, according to Rivera and Nunez de Mendoza<sup>5</sup>, it takes at least more than one cell to be able to make a diagnosis of a disease. Since the number of the subjects in this study was 60 subjects consisting of 30 DM and 30 normal subjects, and each subject was represented by three cells, the total image of the buccal cells used was 180.

Next, each image was cropped to the size of 180x180 pixels. Each image consisted of single buccal cell. There were three stages of digital image processing conducted to obtain features, such as grayscaling, image preprocessing, and segmentation. Figure 4. shows the stage depicting how a segmentation occurred in the nucleus. The first stage was the process of converting RGB images into gray-scale image through grayscaling process. RGB images often need to be converted into a grayscale image because many image processing operations work in gray scale.<sup>21</sup>

Moreover, there were several processes performed in image preprocessing, ie contrast stretching, brightness, and filtering. Contrast stretching and brightness aim to make images brighter and more contrast to facilitate the segmentation stage further. However, there were some visible noises on cells with certain intensity almost equal to the nucleus intensity. This could disrupt the segmentation process, so filtering process was needed to remove the noise. Filter used in this study was Gaussian Low Pass Filter (GLPF). GLPF has a constant variable as  $D_0$ . Thus, the smaller the value  $D_0$  is, the more blurred image is obtained.<sup>22</sup> In this study, the proper value of  $D_0$  was 0.07. At this value, noise found in the cell could be obscured, but did not affect the nucleus.

Furthermore, segmentation stage is the first step in the acquisition of features and image classification. Segmentation was performed to obtain nucleus region. The segmentation process

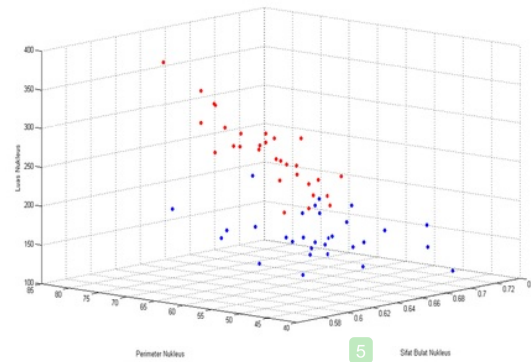
conducted was thresholding and nucleus edge detection. Thresholding was conducted with a limit of 140. The nucleus region was segmented into a white color. Edge detection was conducted to obtain nucleus edge.



**Figure 4.** Image Processing.

The third image of the cells representing each subject was calculated and averaged. Each group consisted of nucleus features, perimeter,

and circularity. It was used as training dataset and testing dataset for classification. Figure 5 is a distribution graph of subjects with type 2 DM and Normal for each nucleus feature area, perimeter, and circularity.



**Figure 5.** Distribution graph of subjects with type 2 DM and Normal for each nucleus feature area, perimeter, and circularity.

## Discussion

### Analysis Cytomorphometric

There were different nucleus features between the type 2 DM group and the normal group. Table 1 shows data of each group. The average nucleus area of the type 2 DM group was  $252.23 \pm 41.03$ , while the average nucleus area of the normal group was  $165.54 \pm 24.96$ . The average nucleus perimeter of the type 2 DM group was  $68.59 \pm 5.84$ , while the average nucleus perimeter of the normal group was  $56.4 \pm 4.76$ . The average nucleus circularity of the type 2 DM group was  $0.67 \pm 0.01$ , while the average nucleus circularity of normal group was  $0.66 \pm 0.03$ .

Nucleus Features	Group	Mean $\pm$ DE
Area	Type 2 DM	$252.23 \pm 41.03$
	Normal	$165.54 \pm 24.96$
Perimeter	Type 2 DM	$68.59 \pm 5.84$
	Normal	$56.4 \pm 4.76$
Circularity	Type 2 DM	$0.67 \pm 0.01$
	Normal	$0.66 \pm 0.03$

**Table 1.** Cytomorphometrical analysis of the type 2 DM group and the normal group.

Nucleus areas and perimeters in the type 2 DM group were higher than those in the control group. But, nucleus roundness in both group were similar. According to Jajarm<sup>17</sup>, one of factors causing the increasing of buccal cell

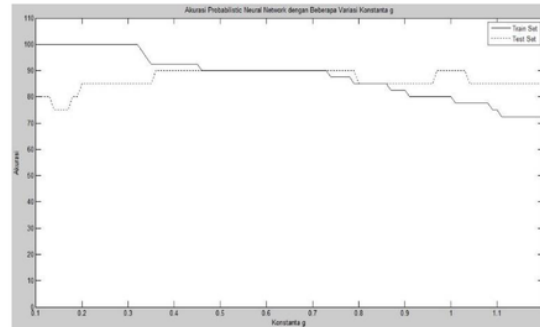
nucleus of type 2 DM is inflammatory. High glucose levels creates the extracellular matrix in the body with a higher concentration. These conditions then can lead the extracellular liquid into the cell and provide a response in the nucleus, causing inflammation.

### Classification

PNN algorithm was made in accordance with the flowchart in Figure 3. The advantage of PNN is that testing time needed is faster than Backpropagation ANN. PNN has various parameters of constant  $g$  value. The constant  $g$  will affect the value of smoothing parameter ( $\sigma$ ). Smoothing parameter then affects the width of Gaussian curve and influences probability function at each sample point. If the value of  $\sigma$  is too small, information on the classes will be lost, but if the value of  $\sigma$  is too wide, the data can become blurry and detailed density will be biased. Selection of the value of  $\sigma$  is usually conducted by trial and error of the variation of the constant  $g$ .<sup>23</sup>

PNN testing process in this study used 10 feature datasets of the type 2 diabetes group and 10 feature datasets of the normal group that were not used in the training process. Those feature datasets would be classified as type 2 diabetes if the value of DM probability was greater than the value of normal probability and vice versa. The accuracy level of the classification results of network PNN then was determined by comparing to the results of the doctor's diagnosis.

Figure 6 is a graph showing the comparison of the training data to the test data. The best accuracy of the testing dataset was 90%, while the best accuracy of the training dataset was 92.5% with the constant  $g$  value from 0.36 to 0.45. Accuracy does not reach 100% because the value of  $\sigma$  can not provide the appropriate grade estimation. Another possibility obtained by Gaussian curve was too wide so that the sample data information became blurred causing some sample points not classified correctly. In addition, an error in the training could also be caused due to the less number of the training data. This is based on research Anggraeny and Hatta<sup>18</sup> that the number of training data affects the accuracy of the system.



**Figure 6.** Graph of the training data accuracy compared to the testing data accuracy with the value of  $g$  constant from 0.1 to 1.2.

The testing results show that PNN failed to classify two test data. Misclassification was estimated as the value of the variable data features classifying approaches for the features in other groups. The value of these features affected the probability of the groups. This classification error then is expected to be corrected in future studies by increasing the number of training data and exploring other features. A large number of training data can affect the ability of network to classify. In addition, it should be added with feature values that are more spread out. The more various training data and the more scattered feature values of sample points are, the better probability value will be at describing a problem.<sup>18</sup>

### Conclusions

1. Cell detection program of type 2 diabetes mellitus using buccal image was created based on digital image processing and Artificial Neural Network (ANN). Identification buccal cell of type 2 DM or normal was based on the nucleus's geometric shape features. The features used in this study were nucleus area, perimeter, and circularity. A feature vector is a set of average features from buccal cell nucleus that was used as an input of classification. The algorithm used is JST Probabilistic Neural Network (PNN).
2. The classification used supervised classification algorithm, namely Probabilistic Neural Network (PNN). From the results of the training of PNN, the value of the constant  $g$  is located at the most optimal range up to 0.36 0.45. Konstanta  $g$ , which is used for the classification is 0.40 because those values are in the middle range is optimal.

3. Optimal accuracy of the resulting program using 20 test data with the value of the constant  $g = 0.40$  by 90%.

### Acknowledgements

The author would like to thank Diabetic Clinic and Pathology Anatomy Laboratory Navy Hospital Dr Ramelan Surabaya for permission and technical assistance. We are also grateful to our patients for the participation in this study.

### Declaration of Interest

The authors report no conflict of interest.

### References

- Hirst M. Diabetes in 2013. The new figures. *Diabetes Res Clin Pract.* 2013;102:265.
- Milchovich, Sue K. and Dunn-Long, Barbara, *Diabetes Mellitus: A Practical Handbook*, 10<sup>th</sup> Edition, Bull Publishing Company, Colorado. 2011.
- Kasper, Dennis L., Braunwald, Eugene, Fauci, Anthony S., Hauser, Stephen L., Longo, Dan L., and Jameson, J. Larry, *Harrison's Principles of Internal Medicine*, 16<sup>th</sup> edition, McGraw Hill: New York. 2005.
- Sonawane, Kishore, Jain, Sandeep, Gupta, Indra, B.V., Karthik, Singaraju, Sasiidhar, and Singaraju, Medhini, *Cytomorphometric Analysis of Oral Mucosa in Diabetic Patients in Bhopal Region an In-Situ Study*, *International Journal of Clinical Dental Science.* 2011; 2(4): 12-15.
- Rivera, Cesar and Nunez-de-Mendoza, Camila, *Exfoliative Cytology of Oral Epithelial Cells From Patients With Type 2 Diabetes: Cytomorphometric Analysis*, *International Journal of Clinical and Experimental Medicine.* 2013; 6(8):667-676.
- Sandberg GE, Sundberg HE, Fjellstrom CA, Wikblad KF. Type 2 diabetes and oral health: A comparison between diabetic and non-diabetic subjects. *Diabetes Res Clin Pract.* 2000; 50:27–34.
- Chomkhakhai U, Thnakun S, Khovidhunkit S-P, Khovidhunkit W, Thweboon S. Oral health in Thai patients with metabolic syndrome. *Diabetes Metab Syndr.* 2009; 3:192–7.
- Collin HL, Niskanen L, Uusitupa M, Töyry J, Collin P, Koivisto A-M, et al. Oral symptoms and signs in elderly patients with type 2 diabetes mellitus. *Oral Surg Oral Med Oral Pathol Oral Radiol Endod.* 2000; 90:299–305.
- Guggenheimer J, Moore PA, Rossie K, Myers D, Mongelluzzo MB, Block HM, et al. Insulindependent diabetes mellitus and oral soft tissue pathologies: I. Prevalence and characteristics of noncandidal lesions. *Oral Surg Oral Med Oral Pathol Oral Radiol Endod.* 2000; 89:563–9.
- Guggenheimer J, Moore PA, Rossie K, Myers D, Mongelluzzo MB, Block HM, et al. Insulindependent diabetes mellitus and oral soft tissue pathologies. II. Prevalence and characteristics of Candida and candidal lesions. *Oral Surg Oral Med Oral Pathol Oral Radiol Endod.* 2000; 89:570–6.
- Nur Izzati Najwa Ramli, Syarifah Nur Izzati Alkaff Syed Mohamad Nadzir Alkaff, Ghasak Ghazi Faisal, Lina Hilal Al Bayati, 2016. *Diabetes Mellitus; Its Impact on Periodontal Health and Dental Caries.* *Journal of International Dental and Medical Research* 2016; 9(3) : 164-168
- Lamster IB, Lalla E, Borgnakke WS, Taylor GW. The relationship between oral health and diabetes mellitus. *J Am Dent Assoc.* 2008; 139:19–24.
- Saini R, Al-Maweri SA, Saini D, Ismail NM, Ismail AR. Oral mucosal lesions in non oral habit diabetic patients and association of diabetes mellitus with oral precancerous lesions. *Diabetes Res Clin Pract.* 2010; 89:320–6.
- Suvarna, M., Anuradha, C., Kumar, K. Kiran, Sekhar, P. Chandra, Chandra, K. Lalith Prakash, and Reddy, BV ramana, *Cytomorphometric Analysis of Exfoliative Buccal Cells in Type II Diabetic Patients*, *Journal of Dr. NTR University of Health Science.* 2012;1: 33-37.
- Kumaresan; Gayathri Devi and Jagannathan, Nithya, *Exfoliative Cytology – A Predictive Diagnostic Tool*, *International Journal of Pharmacy and Pharmaceutical Sciences.* 2014; 6(5).
- Ahmed, Mohammad T., and Garib, Balkees T., *Cytological Features of Oral Cytobrush Smears in Type II Diabetes Mellitus Patients*, *Tikrit Journal for Dental Sciences.* 2012; Vol. 1: 6-12.
- Jajarm, Hasan Hosseinpour, Mohtasam, Nooshin, and Rangiani, Afsaneh, *Evaluation of Oral Mucosa Epithelium in Type II Diabetic Patients by an Exfoliative Cytology Method*, *Journal of Oral Science.* 2008;50(3): 335-340.
- Anggraeny, Fetty Tri and Hatta, Heliza Rahmania, *Probabilistic Fuzzy Neural Network untuk Deteksi Dini Penyakit Jantung Koroner*, *Jurnal Informatika Mulawarman.* 2011; 6(2): 75-79.
- Kadir, Abdul, *Dasar Pengolahan Citra dengan Delphi*, Penerbit Andi, Yogyakarta. 2013.
- Al-Timemy, Ali H., Al-Naima, Fawzi M., Qaeab, Nebras H., *Probabilistic Neural Network for Breast Biopsy Classification*, *IEEE Computer Society.* 2009;2(1), 101-106.
- Kadir, Abdul, and Susanto, Adhi, *Teori dan Aplikasi Pengolahan Citra*, Penerbit ANDI, Yogyakarta. 2013.
- Hermawati, Fajar Astuti, *Pengolahan Citra Digital: Konsep dan Teori*, Penerbit ANDI, Yogyakarta. 2013.
- Saputri, Eka Endah, Wahono, Rono Satria, and Suhartono, Vincent, *Pemilihan Parameter Smoothing pada Probabilistic Neural Network dengan Menggunakan Particle Swarm Optimization untuk Pendeteksian Teks pada Citra*, *Journal of Intelligent Systems.* 2015;1(1):22-26.



# Application of Artificial Neural Network for Type 2 Diabetes Mellitus Detection Using Buccal Cell Images

---

## ORIGINALITY REPORT

---

14%

SIMILARITY INDEX

10%

INTERNET SOURCES

10%

PUBLICATIONS

1%

STUDENT PAPERS

---

## PRIMARY SOURCES

---

1

[www.ncbi.nlm.nih.gov](http://www.ncbi.nlm.nih.gov)

Internet Source

6%

2

[ijcem.com](http://ijcem.com)

Internet Source

1%

3

Hala El-Mesallamy, Salwa Suwailem, Nadia Hamdy. "Evaluation of C-Reactive Protein, Endothelin-1, Adhesion Molecule(s), and Lipids as Inflammatory Markers in Type 2 Diabetes Mellitus Patients", Mediators of Inflammation, 2007

Publication

1%

4

Adanti Wido Paramadini, Prihartini Widiyanti, Djoni Izak Rudyardjo. "Effects of Collagen Concentration Variation toward Characteristics of Bacterial Cellulose-Collagen Biocomposites as Candidate of Artificial Dura Mater", Journal of Biomimetics, Biomaterials and Biomedical Engineering, 2017

Publication

1%

---

5	<p>"Principles of Diabetes Mellitus", Springer Nature, 2017  Publication</p>	1%
6	<p>Baban , Mohammad T.   Garib , Balkees T.. "Oral Signs and Symptoms and Hyperglycemic Status of Type II Diabetic Patients in Relation to Cytomorphometric Findings of Gingival and Buccal Cytobrush Smears", Journal of Baghdad College of Dentistry, 2013  Publication</p>	1%
7	<p>Akash Khandelwal, Matthew D. Krasowski, Erica J. Reschly, Michael W. Sinz, Peter W. Swaan, Sean Ekins. "Machine Learning Methods and Docking for Predicting Human Pregnane X Receptor Activation", Chemical Research in Toxicology, 2008  Publication</p>	<1%
8	<p><a href="http://www.tandfonline.com">www.tandfonline.com</a>  Internet Source</p>	<1%
9	<p>M. Keles, F. Caglayan, U. Tozoglu, A. Kara, E. Cankaya, H. Dogan, G.E. Dogan, A. Uyanik, B. Aydinli. "Changes in Exfoliative Cell of Oral Mucosa in Kidney Transplant Patients", Transplantation Proceedings, 2015  Publication</p>	<1%
10	<p>Sun, J.. "Application of an artificial neural network for simultaneous measurement of</p>	<1%

bending curvature and temperature with long period fiber gratings", Sensors & Actuators: A. Physical, 20070704

Publication

---

11

[irep.iium.edu.my](http://irep.iium.edu.my)

Internet Source

<1%

---

12

I Putu Gede Abdi Sudiarmika. "Segmentation of crack area on road image using Lacunarity method", 2017 5th International Conference on Cyber and IT Service Management (CITSM), 2017

Publication

<1%

---

13

[edentj.com](http://edentj.com)

Internet Source

<1%

---

14

[www.science.gov](http://www.science.gov)

Internet Source

<1%

---

15

Mardina, Zahrina, N. Fitriana, R. Siswanto, O. Oktavina, N. Zahra, Prihartini Widiyanti, D. Rudyarjo, E. Indarto, and R. Langenati. "The Influence of Braiding Angle Variation in Braided-Twisted Fiber Scaffold Based Poly L-Lactic Acid for Anterior Cruciate Ligament Reconstruction Application", Advanced Materials Research, 2013.

Publication

<1%

---

16

[ptjournal.apta.org](http://ptjournal.apta.org)

Internet Source

<1%

---

17

[www.ido.org.tr](http://www.ido.org.tr)

Internet Source

<1%

---

18

Meral Ünür. "The relationship of oral disturbances of diabetes mellitus patients with paraoxonase gene polymorphisms", Cell Biochemistry and Function, 12/2008

Publication

<1%

---

19

"Abstracts of the 37th Annual Meeting of the EASD Glasgow, United Kingdom, 9–13 September 2001", Diabetologia, 08/2001

Publication

<1%

---

20

"Abstracts of Papers", Journal of Dental Research, 2016

Publication

<1%

---

21

Sabah E. Abd-Elraheem, Amany mohammed EL saeed, Hayam Hamza Mansour. "Salivary changes in type 2 diabetic patients", Diabetes & Metabolic Syndrome: Clinical Research & Reviews, 2017

Publication

<1%

---

Exclude quotes Off

Exclude matches

< 7 words

Exclude bibliography On

# Application of Artificial Neural Network for Type 2 Diabetes Mellitus Detection Using Buccal Cell Images

---

GRADEMARK REPORT

---

FINAL GRADE

**/0**

GENERAL COMMENTS

**Instructor**

---

PAGE 1

---

PAGE 2

---

PAGE 3

---

PAGE 4

---

PAGE 5

---

PAGE 6

---

PAGE 7

---