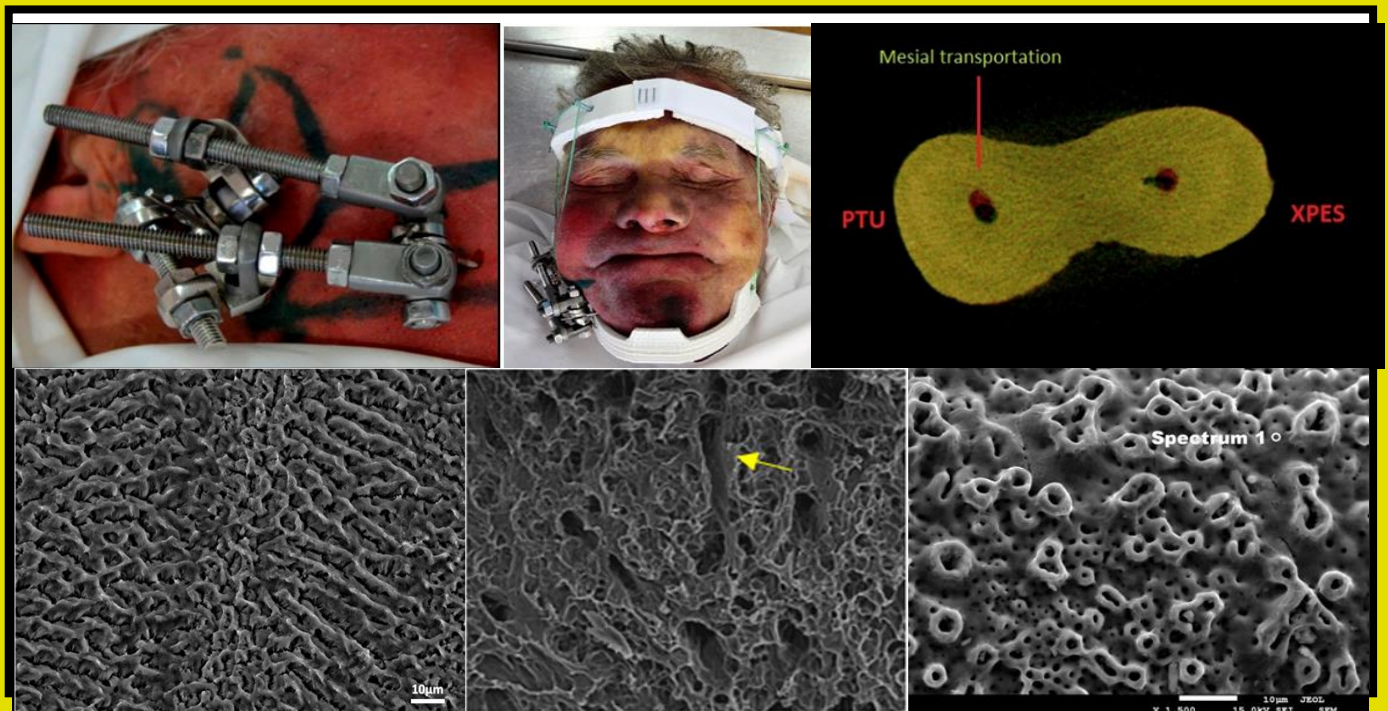


Journal of

International

Dental and Medical

Research



2020 - Vol. 13 – No. 2

<http://www.jidmr.com>

Editorial Board of JIDMR

Prof. Dr. Izzet YAVUZ
Editor-in-Chief and General Director
Prof. Dr. Ozkan ADIGUZEL
Associate Editor

Advisory Board

Prof. Dr. Refik ULKU Associate Editor for Medicine
Prof. Dr. Zulkuf AKDAG Associate Editor for Biomedical Research

Gajanan Kiran KULKARNI (CANADA)	Ferranti WONG (UK)	Lindawati S
Betul KARGUL (TURKEY)	Zeki AKKUS (TURKEY)	KUSDHANY (INDONESIA)
Diah Ayu MAHARANI (INDONESIA)	Michele CALLEA (ROME, ITALY)	Yasemin YAVUZ (TURKEY)
Francisco Cammarata-Scalisi (Venezuela) Myroslav	Zelal ULKU (TURKEY)	Yuliya
Goncharuk-Khomyn (UKRAINE)	Moschos A.	MAKEDONOVA (RUSSIA)
	PAPADOPOULOS (GREECE)	Nik Noriah Nik
		HUSSEIN (MALAYSIA)

Editorial Board

Abdel Fattah BADAWI (EGYPT)	Guvenc BASARAN (TURKEY)	Nezahat AKPOLAT (TURKEY)
Abdurrahman ONEN (TURKEY)	Guven ERBIL (TURKEY)	Nihal HAMAMCI (TURKEY)
Ahmet YALINKAYA (TURKEY)	Halimah AWANG (MALAYSIA)	Nik Noriah Nik HUSSEIN (MALAYSIA)
Ahmet DAG (TURKEY)	Halit AKBAS (TURKEY)	Nicola Pranno (ROME)
Ali Al-ZAAG (IRAQ)	Heloisa Fonseca MARAO (BRAZIL)	Nurten AKDENIZ (TURKEY)
Ali BUMIN (TURKEY)	Hilal TURKER (TURKEY)	Nurten ERDAL (TURKEY)
Ali FADEL (EGYPT)	Huseyin ASLAN (TURKEY)	Orhan TACAR (TURKEY)
Ali GUR (TURKEY)	Igor BELYAEV (SWEDEN)	Ozant ONCAG (TURKEY)
Ali Kemal KADIROGLU (TURKEY)	Ilhan INCI (ZURICH)	Ozgun UZUN (TURKEY)
Ali Riza ALPOZ (TURKEY)	Ilker ETIKAN (TURKEY)	Ozkan ADIGUZEL (TURKEY)
Ali Riza Tunçdemir (TURKEY)	Isil TEKMEK (TURKEY)	Rafat Ali SIDDIQUI (PAKISTAN)
Allah Bakhsh HAAFIZ (USA)	Isin ULUKAPI (TURKEY)	Refik ULKU (TURKEY)
Alpaslan TUZCU (TURKEY)	Jalen DEVECIOGLU KAMA (TURKEY)	Sabiha Zelal ULKU (TURKEY)
Alpen ORTUG (TURKEY)	Kemal CIGDEM (TURKEY)	Sabri BATUN (TURKEY)
Armelia Sari WIDYARMAN (INDONESIA)	Kemal NAS (TURKEY)	Sadullah KAYA (TURKEY)
Ashish AGGARWAL (INDIA)	Kewal KRISHAN (INDIA)	Saul Martins PAIVA (BRAZIL)
Ayşe GUNAY (TURKEY)	King Nigel MARTYN (HONG KONG, CHINA)	Sedat AKDENIZ (TURKEY)
Aziz YASAN (TURKEY)	Kursat ER (TURKEY)	Seher GUNDUZ ARSLAN (TURKEY)
Balasubramanian MADHAN (INDIA)	Levent ERDINC (TURKEY)	Selahattin ATMACA (TURKEY)
Benik HARUTUNYAN (ARMENIA)	Luca TESTARELLI (ROME)	Selahattin TEKES (TURKEY)
Betul KARGUL (TURKEY)	Lucianne Cople MAIA (BRAZIL)	Serdar ERDINE (TURKEY)
Betul URREHMAN (UAE)	Luciane Rezende COSTA (BRAZIL)	Serdar ONAT (TURKEY)
Bugra OZEN (TURKEY)	Marri Sai ARCHANA (INDIA)	Sergio Adriane Bezerra DE MOURA (BRAZIL)
Carlos Menezes AGUIAR (BRAZIL)	Manoj KUMAR (INDIA)	Serhan AKMAN (TURKEY)
Cemil SERT (TURKEY)	Marcelo Rodrigues AZENHA (BRAZIL)	Sertac PEKER (TURKEY)
Chiramana SANDEEP (INDIA)	Marcia Cancado FIGUEIREDO (BRAZIL)	Seyed Amir Danesh Sani (USA)
Christine Bettina STAUDT (SWITZERLAND)	Marco MONTANARI (ITALY)	Seyit Burhaneddin ZİNCİRCİOĞLU (TURKEY)
Cihan AKGUL (TURKEY)	Margaret TZAPHLIDOU (GREECE)	Shailesh LELE (INDIA)
Claudia DELLAVIA (ITALY)	Maria Elisa Oliveira dos SANTOS (BRAZIL)	Sinerik N. AYRAPETYAN (ARMENIA)
Diah Ayu MAHARANI (INDONESIA)	Medi GANIBEGOVIC (BOSNIA and HERZEGOVINA)	Smaragda KAVADIA (GREECE)
Dinesh Rokaya (NEPAL)	Mehmet DOGRU (TURKEY)	Sossani SIDIROPOULOU (GREECE)
Edoardo BAUNER (ROMA)	Mehmet Emin ERDAL (TURKEY)	Stefano Di CARLO (ROME)
Emmanuel Joao N. Leal da SILVA (BRAZIL)	Mehmet Sinan DOGAN (TURKEY)	Sunit Kr. JUREL (INDIA)
Emin Caner TUMEN (TURKEY)	Mehmet Ünal (TURKEY)	Stephen D. SMITH (USA)
Emrullah BAHSI (TURKEY)	Mehmet Zulkuf AKDAG (TURKEY)	Susumu TEREKAWA (JAPAN)
Ertunc Dayı (TURKEY)	Meral ERDİNC (TURKEY)	Suha TURKASLAN (TURKEY)
Fadel M. ALI (EGYPT)	Michele CALLEA (ITALY)	Suleyman DAsDAG (TURKEY)
Fahinur ERTUGRUL (TURKEY)	Mohamed TREBAK (USA)	Taskin GURBUZ (TURKEY)
Feral OZTURK (TURKEY)	Mohammad Khursheed Alam (KSA)	Ufuk ALUCLU (TURKEY)
Feridun BASAK (TURKEY)	Mohammed Mustahsen URREHMAN (UAE)	Ugur KEKLIKCI (TURKEY)
Ferranti WONG (UNITED KINGDOM)	Moschos A. PAPADOPOULOS (GREECE)	Xiong-Li YANG (CHINA)
Feyzi Çelik (TURKEY)	Mostaphazadeh AMROLLAH (IRAN)	Vatan KAVAK (TURKEY)
Feyzullah Uçmak (TURKEY)	M.S. Rami REDDY (INDIA)	Yasar YILDIRIM (TURKEY)
Figen SEYMEN (TURKEY)	Muhammad FAHIM (INDIA)	Yasemin YAVUZ (TURKEY)
Filippo BATTCELLI (ITALY)	Mukadder ATMACA (TURKEY)	Yavuz SANISOGLU (TURKEY)
Filiz Acun KAYA (TURKEY)	Murat AKKUS (TURKEY)	Yu LEI (USA)
Flavio Domingues Das NEVES (BRAZIL)	Murat SOKER (TURKEY)	Yuri LIMANSKI (UKRAINE)
Folakemi OREDUGBA (NIGERIA)	Mustafa KELLE (TURKEY)	Zafer C. CEHRELI (TURKEY)
Francesca De Angelis (ITALY)	Mustafa ZORTUK (TURKEY)	Zeki AKKUS (TURKEY)
Gajanan Kiran KULKARNI (CANADA)	Muzeyyen YILDIRIM (TURKEY)	Zeynep AYTEPE (TURKEY)
Gamze AREN (TURKEY)	Neval Berrin ARSERIM (TURKEY)	Zuhal KIRZIOGLU (TURKEY)
Gauri LELE (INDIA)		Zurab KOMETIANI (GEORGIA)
Gonul OLMEZ (TURKEY)		
Gulsen YILMAZ (TURKEY)		
Gulten UNLU (TURKEY)		

DENTISTRY

EXPERIMENTAL ARTICLE

1. **Mandible Exoskeleton - First Results of Development and Implementation**
Alexandr A. Vorobyev, Denis Yu. Dyachenko, Yuliya A. Makedonova, Dmitriy V. Mikhailchenko,
Evgeniy V. Fomichev, Karen A. Sargsyan
Pages 400-406
2. **Evaluation of the Shaping Ability of XP Endo Shaper: A Micro-Computed Tomography Study**
Sarah Mubarak Alkahtany, Sara Suliman Alrumaih, Mona Abdullah Alhassan, Basmah Ahmad Alnashmi,
Ebtissam M. Al-Madi
Pages 407-411
3. **Viability Test of Fish Scales Collagen from Oshphronemus Gouramy on Osteoblast Cell Culture**
Agung Krismariono, Novia Wiyono, Chiquita Prah santi
Pages 412-416
4. **Isolation and Antimicrobial Activity of Lactic Acid Bacteria against Streptococcus Mutans**
Nor Zaihana Abdul Rahman, Rohazila Mohamad Hanafiah, Siti Aisyah Abd Ghafar, Norafiqah Abdullah,
Nur Nabilah Azman
Pages 417-421
5. **Clinical Control of Denture Base Acrylics Polymerization for the Quality Assurance: Pilot Study of Spectroscopic Approach**
Yuriy Lokota, Ivan Paliichuk, Volodymyr Paliichuk, Myroslav Goncharuk-Khomyn
Pages 422-429
6. **The Mangiferin (Mangifera Indica Linn) Effect Against the Calcium Degradation, Bones Resorption and Ossification of Rattus novergicus of Post-orthodontic treatment**
Yenita Alamsyah, Nazruddin, Syafruddin Ilyas, Deddi Prima Putra
Pages 430-435
7. **The Effect of Cranberry, Strawberry and Blueberry Juices on the Viability of Cariogenic Bacteria: An in Vitro Study**
Md. Sofiqul Islam, Zainab Riaz, Anam Waqar, Mohannad Nassar, Ashfaque Hossain,
Muhammed Mustahsen Rahman
Pages 436-441
8. **Effects of Different Aging Methods on Color Change of Bulk-Fill and Anterior Resin Composites**
Effects of Aging Methods on Color Change of Composites
Makbule Tugba Tuncdemir, Kubra T. Kahraman
Pages 442-447
9. **Efficiency of Cleaning the Various Types of Dental Implants' Surfaces (Tiu-Nite, Sla, Rbm) Using the Air-Flow Erythritol Method**
Furtsev T.V., Zeer G.M.
Pages 448-452
10. **Effect of Eucalyptus and Chloroform on Mineral Content of Radicular Dentin: an in vitro Study**
Nexhmije Ajeti, Violeta Vula, Miranda Stavileci, Merita Barani, Agran Halimi, Lindihana Emiri
Pages 453-458

- EXPERIMENTAL ARTICLE
- 11. Time Consumptions by Four Polishing Methods for in Vitro Removals of Orthodontic Adhesive Remnants**
Kiatanan Sugsompian, Thosapol Piyapattamin
Pages 459-462
- EXPERIMENTAL ARTICLE
- 12. The Microarchitecture and Atomic Mineral Composition of the Rats' Mandibular Condyle Varying Masticatory Functional Loads**
Nur Masita Silviana, Sri Andarini, Diana Lyrawati, Mohammad Hidayat
Pages 463-468
- EXPERIMENTAL ARTICLE
- 13. Scanning Electron Microscopic Evaluation for the Ability of Endovac and EnoActivator in Cleaning Root Canal Space Using EDTA and QMix™**
Manal M. Abdelhafeez
Pages 469-474
- EXPERIMENTAL ARTICLE
- 14. Radioprotective Effect of Spirulina Platensis on Head and Neck Radiation-Induced Xerostomia**
Sarianoferni, Dian Mulawarmanti, Indeswati Diyatri, Eha Renwi Astuti, Soetjipto
Pages 475-479
- EXPERIMENTAL ARTICLE
- 15. In vitro Analysis of Minimal Inhibitory Concentrations of NaOCl, CHX, MTAD, and EDTA against Enterococcus faecalis**
Donika Bajrami, Miranda Stavileci, Agime Dragidella, Blerim Kamberi, Nora Aliu
Pages 480-485
- EXPERIMENTAL ARTICLE
- 16. Influence of Root Canal Preparation with Different Tapers on Apical Leakage**
Remy Barazy, George Eshoa
Pages 486-490
- EXPERIMENTAL ARTICLE
- 17. RT-qPCR Gene Expression Analysis on the Irf6 Intron Polymorphism in Oral Epithelium of Non-Syndromic Oral Cleft Risk of Deutero-Malay Sub-Race Indonesian**
Saskia L. Nasroen, Ani Melani Maskoen, Hardisiswo Soedjana, Dany Hilmanto
Pages 491-496
- EXPERIMENTAL ARTICLE
- 18. Anti-Inflammatory Effect of Okra (Abelmoschus esculentus) Fruit Extract during Wound Healing Process after Tooth Extraction of Diabetic Wistar Rat**
Muhammad Luthfi, Tuti Kusumaningsih, Agung Sosiawan, Hasna Shabrina
Pages 497-502
- EXPERIMENTAL ARTICLE
- 19. Expression of Non-Metastatic Protein-23 And Metastatic Associated Protein-1 as a Molecular Target Therapy of an Oral Malignant Burkitt's Lymphoma Induced by Oligonucleotide P27 Sense**
Supriatno, Ana Medawati, Sartari Entin Yuletnawati
Pages 503-507
- EXPERIMENTAL ARTICLE
- 20. Enhancement of Osteogenesis Using a Combination of Hydroxyapatite and Stem Cells from Exfoliated Deciduous Teeth**
Chiquita Prahasanti, Agung Krismariono, Rifiana Takanamita, I Komang Evan Wijaksana, Ketut Suardita, Tania Saskianti, Diah Savitri Ernawati
Pages 508-512

EXPERIMENTAL ARTICLE**21. Pulpitis Induced Carotid Atherosclerosis**

Nadie Fatimatuzzahro, Rendra Chriestedy, IDA Susilawati, Wulandari Fajrin
Pages 513-518

EXPERIMENTAL ARTICLE**22. Potency of Okra Fruit Extract (*Abelmoschus esculentus*) Against *Porphyromonas Gingivalis* as the Cause of Chronic Periodontitis**

Yuliati, Muhammad Luthfi, Priyawan Rachmadi, Bella Primordio Cida, Elvina Hasna Wijayanti
Pages 519-524

EXPERIMENTAL ARTICLE**23. Combination of Anadara Granosa Shell-Stichopus Hermanni Gel on Osteoblast-Osteoclast and Blood Vessels in Femur Healing**

Rima Parwati Sari, Isnainy Nurlaily, Rizky Putri Heryana, Wahyu Fatmawati, Meinur Nur Ashrin
Pages 525-532

EXPERIMENTAL ARTICLE**24. Enamel Remineralization Effect using Dewaxed Shellac Varnishes with Added Carbonate Apatite and Tricalcium Phosphate**

Arief Cahyanto, Dena Fadhilah Marwa, Kesya Saragih, Veni Takarini, Zulia Hasratiningsih
Pages 533-538

EXPERIMENTAL ARTICLE**25. The Inhibitory Effect of Kaffir Lime Extract towards *Staphylococcus Aureus* Bacteria**

Sartika Puspita, Ovin Lutfialifta P
Pages 539-542

EXPERIMENTAL ARTICLE**26. Effectivity of Insulin Leaf Extract (*Tithonia Diversivolia*) on Mice Malondialdehyde (MDA) Levels**

Tuti Kusumaningsih, Mohammed Aljunaid, Abdul Hafid Fauzi Barmen, Tantiana, Retno Palupi, Yuliati
Pages 543-546

EXPERIMENTAL ARTICLE**27. The Expressions of Some Growth Factors as the Progressive Indicators of Pulmonary Arterial Hypertension**

Mahrus A. Rahman, I Ketut Alit Utamayasa, Agus Sunandar
Pages 547-552

EXPERIMENTAL ARTICLE**28. Corticosteroid Effects and Administration Time Difference on Mice Model of Biliary Atresia**

Bagus Setyoboedi, Anang Endaryanto, Sjamsul Arief
Pages 553-560

CLINICAL ARTICLE**29. The Role of Prooxidant-Antioxidant System in the Development of Alveolitis after Teeth Extraction**

Hutor N.S., Pidruchna S.R., Melnyk N.A., Avdeev O.V., Boykiv A.B., Kovtun N.Ya., Skochylo O.V., Tverdokhlib N.O., Goncharuk-Khomyn M.Y.
Pages 561-565

CLINICAL ARTICLE**30. The Infraorbital Ethmoid (Haller's) Cells in a Group of Thai Patients: Panoramic Radiographic Study**

Chutamas Deepho, Sirilawan Tohnak, Ruchadaporn Kaomongkolgit, Ronnayut Chansamat, Weeraya Tantanapornkul
Pages 566-570

CLINICAL ARTICLE

- 31. Comparative Evaluation of Treatment Efficiency of Inflammatory Complications after Orthopedic Treatment with Up-To-Date Methods of Pharmacotherapy**

Yuliya A. Makedonova, Dmitriy V. Mikhilchenko, Alexandr V. Zhidovinov, Denis Yu. Dyachenko,
Sergej A. Veremeenko
Pages 571-576

CLINICAL ARTICLE

- 32. Stress-Related Oral Manifestations Disorders in A Population Sample of Patients Attending Ajman University Dental Clinics**

Ebtesam Khalil, Nihal A.Ibrahim, Maher Al Shayeb, Syed Kuduruthullah, Mawada Hassan
Pages 577-586

CLINICAL ARTICLE

- 33. Prevalence and Periodontal Treatment Needs of Aggressive Periodontitis, in Students of Specific part of Iran**

Hossein Assarzadeh, Zahra Baghani, Rahil Mahmoodi
Pages 587-594

CLINICAL ARTICLE

- 34. Retrospective Study of the Prevalence of Type 2 Diabetes Mellitus and Severity of Periodontal Disease in Chronic Periodontitis Patients**

Waleed Ahmed Ismail, Siti Lailatul Akmar Zainuddin, Romaisa Arshad Khokhar, Haslina Taib,
Basaruddin Ahmad, Azlina Ahmad
Pages 595-600

CLINICAL ARTICLE

- 35. Social and Clinical Risk Determinants of Oral Lichen Planus – a Case Control Study**

Jolanta Aleksejuniene, Arunas Rimkevicius, Alina Puriene, Ruta Rasteniene
Pages 601-607

CLINICAL ARTICLE

- 36. Relationship between the Nasopharyngeal Width and Hyoid Bone Position in Skeletal Malocclusion**

Hilda Fitria Lubis, Lydia Irani Nainggolan, Alfrina Marwan
Pages 608-613

CLINICAL ARTICLE

- 37. Relapse in Modified Vacuum-Formed and Hawley Retainers for Transverse Expansion A Multicenter Randomized Control Trial**

Lew Xian, Asma Ashari, Alizae Marny Fadzlin Syed Mohamed, Rohaya Megat Abdul Wahab,
Elavarasi a/p Kuppusamy, Malathi Deva Tata, Yeoh Chiew Kit, Sindhu Sinnasamy
Pages 614-621

CLINICAL ARTICLE

- 38. Evaluation of Masticatory Efficiency among subjects with Removable Partial Dentures: A Comparative Study**

Linda J Dula, Kujtim Sh. Shala, Arlinda Tmava-Dragusha, Zana Lila-Krasniqi, Teuta Pustina-Krasniqi,
Teuta Bicaj
Pages 622-627

CLINICAL ARTICLE

- 39. Depression, Anxiety and Stress Among Pharmacy Students in Malaysia**

Ali Sabri Radeef, Ghasak Ghazi Faisal
Pages 628-632

- CLINICAL ARTICLE
- 40. Increased Hsp-72 Expression in Oral Mucormycosis after treatment with Hyperbaric Oxygen (HBO)**
Fanny Margaretha Laihah, I Ketut Sudiana, M. Guritno S, Sumarno, Sunarjo, Retno Indrawati, Theresia Indah Budhy, Herjunianto, Titut Harnanik, Noengki Prameswari, Arya Brahmanta, Eddy Hermanto
Pages 633-638
- CLINICAL ARTICLE
- 41. Miswak (Salvadora Persica) As an Alternative Oral Aid to Reduce Denture Induce Stomatitis on Edentulous Patients**
Nusima Mohamed, Norlela Yacob, Wan Nor Syariza Wan Ali, Aida Ali, Nor Azlina Ismail, Nasadila Nadhira Nasser
Pages 639-645
- CLINICAL ARTICLE
- 42. Diagnostic Value of Panoramic Radiography in Completely Edentulous Patients**
Amaweya Abdulrahman Al-Sammarraie, Ayyam Khalid Abdulkareem
Pages 646-650
- CLINICAL ARTICLE
- 43. Electromyography Activity of the Chewing Muscles During Adaptation among Complete Denture Wearers**
Kujtim Sh. Shala, Linda J Dula, Venera Bimbashi
Pages 651-658
- CLINICAL ARTICLE
- 44. Increasing Salivary Flow Rate and Salivary Ph after Consuming Secang Drink (Caesalpinia Sappan L.) Related to Body Mass Index**
Winy Yohana, Sri Tjahajawati, Irna Sufiawati, Intan Safitri Kartika, Muhammad Iqbal Izdaulfikri
Pages 659-662
- CLINICAL ARTICLE
- 45. Serum nitric oxide levels in smokers with chronic periodontitis**
Hytham N Fageeh, Wael I Ibraheem, Abdullah A Meshni, Reghunathan S Preethanath
Pages 663-668
- CLINICAL ARTICLE
- 46. The Relationship between Sex and Age on Dental Arch Change after Treatment with the Reverse Pull Face Mask Appliance of Class III Malocclusion: a Randomized Clinical Trial**
Osama Bahaa Albajalan, Nawres Oraibi Alazzawi, Nor Ashikeen Mukti, A. R. Samsudin
Pages 669-673
- CLINICAL ARTICLE
- 47. Sports-Related Dental Injury from the Perspective of Malaysian Athletes**
Aiemeeza Rajali, Nik Rahayyu Nik Zulkifeli, Ahmad Safwan Mohd Elias, Nur Al Huda Mansur, Nik Haziman Wan Hamat, Syamsul Rizal Abu Amin
Pages 674-681
- CLINICAL ARTICLE
- 48. Influence of Smoking upon the Ki67 Expressions in Asymptomatic Fully Impacted Lower Third Molar Follicles**
Mhd Amer Alassfar, Mumdouh Almohareb, Haytham Bahhah
Pages 682-688
- CLINICAL ARTICLE
- 49. Teeth and Soft Tissue Injuries as Well as Wound Healing Quality Patterns Among Primary School Students of Prishtina Region**
Naim Haliti, Ragip Shabani, Shefqet Mrasori, Fatmir Dragidella, Hrvoje Juric, Nora Shabani Behrami, Dafina Doberdoli, Fehim Haliti
Pages 689-696

- CLINICAL ARTICLE
- 50. The Practice, Perception, and Awareness of Self-Medication for Dental Pain in Malaysian Dental Students**
Mahyunah Masud, Zaty Ainaa Mohamed, Nur Farhaanah Azman, Mohd Aizat Abdul Rahim
Pages 697-703
- CLINICAL ARTICLE
- 51. The Comparison between Acetaminophen and Ibuprofen Effectiveness for Ductus Arteriosus Closure Therapy in Premature Infants**
Mahrus A. Rahman, I Ketut Alit Utamayasa, Agus Cahyono
Pages 704-707
- CLINICAL ARTICLE
- 52. Effectiveness of Treatment with Reverse Twin-Block and Reverse Pull Face Mask on Dental Arches of Class III Malocclusion: A Randomized Clinical Trial**
Osama Bahaa Albajalan, Nawres Oraibi Alazzawi, Nor Ashikeen Mukti, A.R. Samsudin
Pages 708-713
- CLINICAL ARTICLE
- 53. Characteristics of Dental Health, Dentomaxillar Growth and Body Mass Index in 3-6 years old Children in Yahya Kindergarten Bandung**
Winnie Yohana, Rosiliwati Wihardja
Pages 714-718
- CASE REPORT
- 54. Dilemma of Orthodontic Treatment in Fluorosed / Hypomineralised Enamel Teeth: A Case Report**
Noor Ayuni Ahmad Shafiai, Alizae Marny Mohamed
Pages 719-726
- CASE REPORT
- 55. Neutral Zone Impression Technique in Atrophic Mandibular Ridge using a Modified Design of Lower Base Plate**
Ayman Al Oulabi, Zuryati Ab-Ghani, Noor Huda Ismail, Nafij Jamayet
Pages 727-730
- REVIEW
- 56. The Advantage and Basic Approach of Infrared Thermography in Dentistry**
Abdillah Imron Nasution, Mikhail Nikolaevich Pankov
Pages 731-737
- REVIEW
- 57. Intrinsic Dental Erosion: Review of Dental Management**
Mohammed Sulaiman Alruthea
Pages 738-744
- REVIEW
- 58. Patient Satisfaction Measuring Instrument—A Scoping Review**
Krisnawati Erry Tarman, Diah Ayu Maharani, Miesje K. Purwanegara
Pages 745-751
- REVIEW
- 59. Recent Updates of the Oral Benefits of Mangosteen Plant Extracts: Review**
Mohammed Aljunaid, Ninuk Hariyani, Retno Indrawati Roestamadji, Rini Devijanti Ridwan, Tuti Kusumaningsih, Huda Rashad Qaid
Pages 752-757

MEDICINE

- 60. The Effect of the Neurotransmitter Dopamine, Lead Acetate, L-NAME, and Verapamil on the Metabolic Pathway in the Longitudinal Smooth Muscle**
Rahman Ferizi, Nora Shabani, Ragip Shabani, Naim Haliti
Pages 758-768
EXPERIMENTAL ARTICLE
- 61. In Vitro Assay of Cornea Artificial Properties**
Prihartini Widiyanti, Reni Prastyani
Pages 769-773
EXPERIMENTAL ARTICLE
- 62. Smoke Effects of Disturbances Folliculogenesis (Mda, Gnrh, Hsp70, Apoptosis, and Follicles) in Ovarian on Mice Balb / C**
Eny Susanti, I Ketut Sudiana, Hendy Hendarto
Pages 774-777
EXPERIMENTAL ARTICLE
- 63. Lung Dendritic Cells Express Higher Stress Proteins on Higher Allergen Dose Exposure and Contribute to Allergen Tolerance Induction**
Gatot Soegiarto, Agustina Tri Endharti, Wibi Riawan, Anang Endaryanto, Subijanto Marto Sudarmo
Pages 778-784
EXPERIMENTAL ARTICLE
- 64. The Increasing Inflammatory Cells, Degeneration and Duodenal Necrosis on Infant Mice from Carbofuran Exposed Mothers**
E. Z. Yanti, H. A. Hermadi, P. S. Rejeki, Y. Dhamayanti, Widjiati, E. M. Luqman
Pages 785-790
EXPERIMENTAL ARTICLE
- 65. The Effect of Serum and Follicular Fluid Vitamin D on Intracytoplasmic Sperm Injection Outcome**
Israa Majeed, Mohammad Oda Selman, Ban J. Qasim, Ghasak Ghazi faisal
Pages 791-795
CLINICAL ARTICLE
- 66. Predictors of Time Delay in Commencing Primary Coronary Intervention in STEMI Kosova Case-Pilot Study**
Hajdin Çitaku, Ramë Miftari, Fatmir Ferati, Xhevdet Krasniqi
Pages 796-800
CLINICAL ARTICLE
- 67. Profile of Predictive Factors of Response to Therapy in Patients with Diffuse Large B-cell Lymphoma in dr Soetomo General Teaching Hospital Surabaya**
Mochammad Dilliawan, Siprianus Ugroseno Yudho Bintoro, Putu Niken Ayu Amrita
Pages 801-807
CLINICAL ARTICLE
- 68. Evaluating the Treatment of Patients with Appendicitis, Perspectives on Challenges Professional Work**
Kadir Hysein, Valon Morina, Zeqir Hashani, Qenan Maxhuni, Rahman Ferizi
Pages 808-815
CLINICAL ARTICLE
- 69. Comparison Study between Angio CT and USG Doppler for Early Detection of Arterial Stenosis of Lower Extremities in University Clinical Center of Kosovo**
Lavdim H. Ymeri, Vjosa A. Zejnullahu, Serbeze Kabashi Muqaj, Muharrem Sadiku, Valon A. Zejnullahu
Pages 816-823
CLINICAL ARTICLE

70. Curcumin as Adjuvant Therapy in COVID-19: Friend or Foe?

Jeanne Adiwinata Pawitan

Pages 824-829

The Increasing Inflammatory Cells, Degeneration and Duodenal Necrosis on Infant Mice from Carbofuran Exposed Mothers

E. Z. Yanti¹, H. A. Hermadi², P. S. Rejeki³, Y. Dhamayanti⁴, Widjiati⁴, E. M. Luqman^{4*}

1. Faculty of Veterinary Medicine, Universitas Airlangga, Surabaya, East Java, Indonesia
2. Department of Veterinary Reproduction, Faculty of Veterinary Medicine, Universitas Airlangga Surabaya, East Java, Indonesia.
3. Department of Physiology, Faculty of Medicine Universitas Airlangga Surabaya, East Java, Indonesia.
4. Department of Veterinary Anatomy, Faculty of Veterinary Medicine, Universitas Airlangga, Surabaya, East Java, Indonesia.

Abstract

This study was designed to observe the effect of carbofuran induction as a trigger for ROS on duodenal histopathology in infant mice exposed to transmammary.

This study aimed to evaluate any inflammation, degeneration and duodenal necrosis in the infant mice from the carbofuran exposed mothers during the lactation periods. There were 20 strain Balb/C mice were divided into four groups, each group contained five mice. Control Group induced with 0.1 ml/kg Body Weight (BW) of aquades, Carbofuran Group 1/16 LD₅₀ with the dose of 0.3125 mg/kg BW, carbofuran Group 1/8 LD₅₀ with the dose of 0.625 mg/kg BW, and Carbofuran Group 1/4 LD₅₀ with the dose of 1.25 mg/kg BW. Mice mothers were exposed to carbofuran orally from Day 1 to 9 after giving birth. On Day 10, infant mice were sacrificed, one from each parent. Next, the infant mice duodenum were stained using hematoxylin-eosin.

The results show that carbofuran exposure causes an increase in inflammation ($p = 0.001$), degeneration ($p = 0.001$) and necrosis ($p = 0.002$). Carbofuran leads to oxidative duodenal stress in infant mice which triggers the increase in inflammation, degeneration and necrosis in infant mice's duodenum along with the increasing doses.

Experimental article (J Int Dent Med Res 2020; 13(2): 785-790)

Keywords: Carbofuran, lactation, inflammation, degeneration, necrosis, duodenum.

Received date: 24 February 2020

Accept date: 03 May 2020

Introduction

Carbofuran is an insecticide that is often used in the agricultures to avoid pests or diseases in the agricultural crops and plantations. Improper use can cause various side effects for the environment.¹ In the city of Batu, Malang, East Java, Indonesia, 95% of vegetable and fruit farmers got poisoned by insecticide due to insecticide residues in their drinking water² and their agricultural products as an effect of intensive insecticide use.³ This carbamate insecticide is easily decomposed in the wild and in the food chain but is highly toxic in the non-target animals.³ Carbofuran has been proven to accumulate in fat and has a negative impact on the brain, liver, ribbed muscles, non-target

mammalian heart, maternal plasma, umbilical cord, and new-borns.^{1,4}

Lactation is a critical period of development of postpartum individuals because the organ functions and systems are still developing, thus, so that they are more susceptible to functional disorders.⁵ Metabolic material in the milk due to insecticide exposure in the lactating mothers allows the transmission of toxic substances to children.⁶ The intestine is an organ that plays an important role in the process of food absorption. The intestine can also be the main channel or portal for the entry of unwanted substances in the body such as the toxic insecticides and drugs.^{5,7} According to Indraningsih,³ the orally induced insecticides can result in the hypermotility and malabsorption in digestive tract. Hypermotility and malabsorption are caused by a decrease in enterocyte cell's number due to the increased necrosis.

The effects of carbofuran create free radicals in the form of reactive oxygen species (ROS) that can trigger the death of body cells.⁸ High free radicals are dangerous for living

*Corresponding author:

E. M. Luqman
Department of Veterinary Anatomy,
Faculty of Veterinary Medicine,
Universitas Airlangga Surabaya, East Java, Indonesia
E-mail: epy-m-l@fkh.unair.ac.id

creatures.⁹ Free radicals form the membrane lipid peroxidation, thus, the fatty acid chains in cell membranes break down and provoke injury to the cells.¹⁰ Research conducted by ¹¹ showed an increase in MDA levels in the brains of mice exposed to carbofuran from their mother's milk for four days. The increased levels of MDA indicate a rise in the damaged cell membranes which leads to a decline in the cell function in the form of cell degeneration (reversible) and necrosis (irreversible).⁸ In addition, free radicals are known for increasing the permeability of intestinal mucosa so that inflammatory cell's infiltration can occur in the intestinal mucosa.^{12,13}

Research on the effect of transmammary carbofuran administration is needed to find out the effects that can be caused on the infants during breastfeeding. The duodenum of small intestine is an important organ in digesting various substances that enter through the digestive system, also an important organ in the metabolism of xenobiotic substances including pollutants, drugs, and toxic components in food.¹⁴ Observation of inflammatory cells, degeneration and necrosis is one way to determine the effect of carbofuran exposure in the mice mothers during the lactation periods against the duodenum of infant mice (*Mus musculus*).

Materials and methods

The research was carried out in the Department of Veterinary Anatomy, In vitro Fertilization Laboratory and Veterinary Pathology Department of the Faculty of Veterinary Medicine, Airlangga University, Surabaya in August - October 2019.

This study used 20 pregnant strain Balb/C female mice with the body weights around 25-30 grams. It also employed Carbofuran 98% (Sigma Aldrich, Bellstain Registry number 1428746, Product of USA), distilled water, 70% alcohol, 10% formalin, experimental cage, drinking pot, feeding tube syringe, 3 ml syringe, minor surgical instrument, petri dish, and microscope Olympus® CX-41. This study applied the approach of Carbofuran LD₅₀ fraction given to mice mothers, they were 1/16 LD₅₀ with 0.3125 mg/kg BW, 1/8 LD₅₀ with 0.625 mg/kg BW, 1/4 LD₅₀ with 1.25 mg/kg BW.

The pregnant mice mothers were adapted and divided randomly into 4 groups, each group consisting of five mice. Carbofuran exposure is

given in the lactation period of Day 1 to Day 9 orally. The control group was given with 0.5 ml of aquadest per day each, while the treatment groups were induced with carbofuran solution with a dose of 1/16 LD₅₀ (0.3125 mg/kg BW), 1/8 LD₅₀ (0.625 mg/kg BW), and 1/4 LD₅₀ (1.25 mg/kg BW). On Day 10 infant mice were sacrificed and its duodenum was taken, then the histopathological preparations were made.

Observations were made using a 400x magnification microscope at five different fields of view, then assessed using Wiadnyana's scoring system (2015) as follows: inflammatory cell's infiltration (0) there was no inflammatory cell's infiltration, (1) local or focal inflammatory cell's infiltration, (2) multifocal inflammatory cell's infiltration, (3) even or diffuse inflammatory cell's infiltration. While for cell degeneration, it applied the scoring as follow: cell degeneration (0) there is no cell degeneration, (1) local or focal cell degeneration, (2) multifocal cell degeneration, (3) uniform or diffuse cell degeneration. Furthermore, for necrosis, it used this following scoring: necrosis (0) no necrosis, (1) local or focal necrosis, (2) multifocal necrosis, (3) even or diffuse necrosis.

Observation data were analysed using the Kruskal-Wallis test, if there were significant differences it would be followed by the Mann-Whitney test. It calculated using Statistical Program for Social Scientific (SPSS) version 21.

Results

The duodenum of the small intestine is a digestive organ that plays an important role in digesting various xenobiotic substances including pollutants, drugs, and toxic components in food.¹⁴ The observation of the duodenum in infant mice from mothers with carbofuran exposure for nine days shows that there are microscopic changes in the form of inflammatory cell's infiltration, degeneration and necrosis. While, data from the Kruskal-Wallis test reveals that the results are significantly different ($p < 0.05$) in inflammatory cell's infiltration, degeneration and necrosis variables (see Table 1). The results present the infiltration of inflammatory cells increases with the increasing doses (see Table 1). The increased visible cell's inflammation in the duodenal lamina propria displays a body response to injury from carbofuran exposure (see Figure 1). In this study, it is also found that an

increase in degeneration along with the increasing doses of exposure. Duodenal fattening degeneration in infant mice is indicated by an incline in fat vacuoles in the cell cytoplasm (see Table 1 and Figure 2).

Treatments	Inflammatory Cell's Infiltration (Mean±SD)	Degeneration (Mean±SD)	Necrosis (Mean±SD)
Control Group	0.04±0.06 ^a	0.23±0.32 ^a	0.00±0.00 ^a
1/16 LD ₅₀ (0.3125 mg/kg BW)	0.12±0.03 ^b	0.85±0.24 ^b	0.08±0.03 ^b
1/8 LD ₅₀ (0.625 mg/kg BW)	0.21±0.11 ^c	1.80±0.09 ^c	0.24±0.10 ^c
1/4 LD ₅₀ (1.25 mg/kg BW)	0.43±0.06 ^d	2.13±0.29 ^d	0.36±0.28 ^c

Table 1. Scoring of inflammatory cell's infiltration, duodenal degeneration and necrosis of infant mice from mothers with carbofuran exposure during lactation periods.

Remarks: Different superscripts in the same column show significant differences (p <0.05).

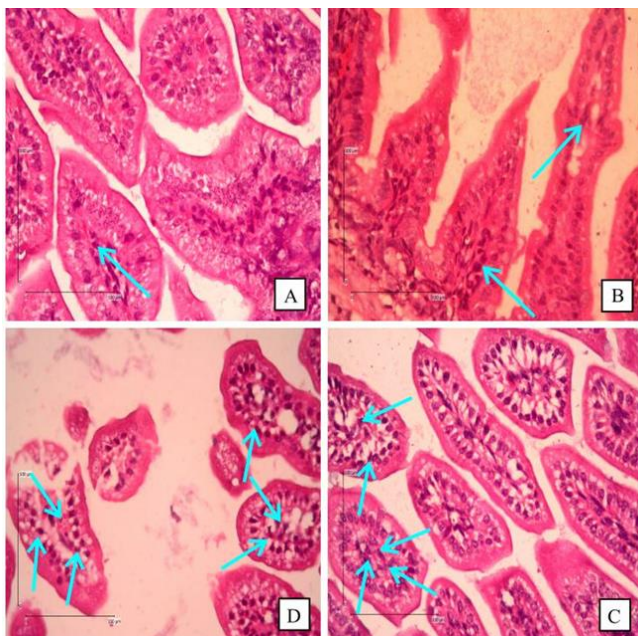


Figure 1. Infiltration of inflammatory cells in the duodenum of infant mice shown in blue arrows. A = control, B = 1/16 LD₅₀ (0.3125 mg/kg BW), C = 1/8 LD₅₀ (0.625 mg/kg BW), and D = 1/4 LD₅₀ (1.25 mg/kg BW). 400x magnification.

Moreover, the results also indicate a growth in necrosis along with an upgrade in carbofuran doses, although there are no any significant differences between groups 1/8 LD₅₀ (0.625 mg/kg BW) and 1/4 LD₅₀ (1.25 mg/kg BW). Necrosis is characterized by the presence of duodenal epithelial cell nucleus that experiences karyopyknotic, karyorrhexis and karyolysis (see Table 1 and Figure 3).

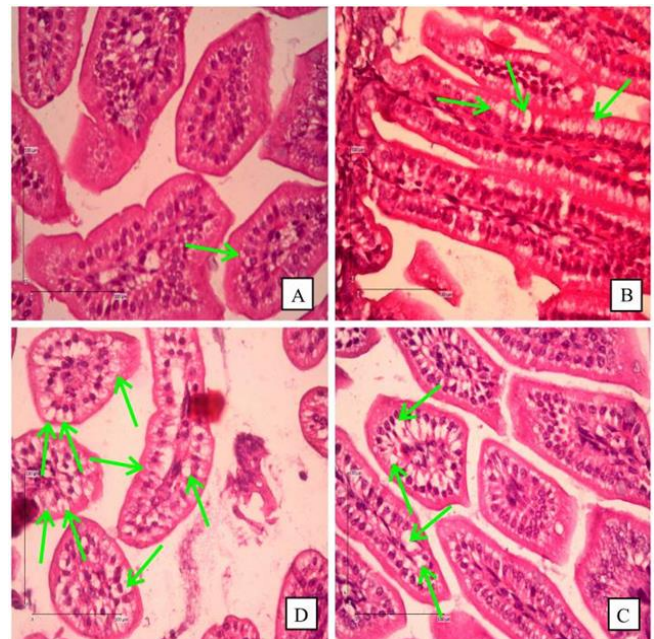


Figure 2. Duodenal fattening Degeneration in infant mice shown in green arrows (Characteristic of degeneration: there are fat vacuoles in the cell cytoplasm). A = control, B = 1/16 LD₅₀ (0.3125 mg/kg BW), C = 11/8 LD₅₀ (0.625 mg/kg BW), and D = 1/4 LD₅₀ (1.25 mg/kg BW). 400x magnification.

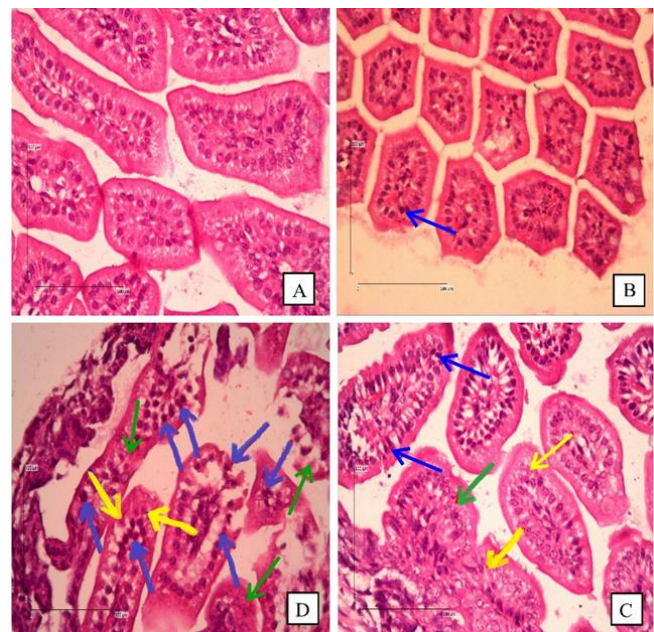


Figure 3. Duodenal necrosis of infant mice. Necrosis is characterized by karyopyknotic (blue arrow), karyorrhexis (yellow arrow), and karyolysis (green arrow). A = control, B = 1/16 LD₅₀ (0.3125 mg/kg BW), C = 1/8 LD₅₀ (0.625 mg/kg BW), and D = 1/4 LD₅₀ (1.25 mg/kg BW). 400x magnification.

Discussion

Carbofuran leaves residues in the environment and is easily absorbed by the body through skin, inhalation and oral, which is then absorbed by the intestine.³ Toxic manifestations of carbamate metabolites associated with the formation of free radicals (ROS).¹ Carbofuran metabolites can reach the brain, muscles, heart, liver, placenta, foetus, umbilicus, fat tissue, blood and milk.^{3,6,11} Carbofuran has lipophilic properties so that it can enter the mother's milk through the mother's blood plasma passively.^{9,15} Carbofuran metabolites in the milk allow the transmission of harmful substances from mother to child. The concentration of metabolites in milk can be higher than in the blood plasma because blood flow to the mother is faster than the secretion, allowing for accumulation.¹⁵

Carbofuran stimulates reactive oxygen species (ROS) and causes the death of body cells including intestinal epithelial cells.^{8,16} From this study, it is found an increase in MDA levels in the brain of infant mice exposed to transmammary carbofuran for four days.¹¹ The findings support this study that carbofuran exposure to mothers during the lactation periods inclines the free radicals in breast-fed infant mice. According to previous study, free radicals can cause membrane lipid peroxidation, thus, the fatty acid chains in cell membranes break down and trigger injury to cells.¹⁰ This reaction produces MDA on the network. The increased levels of MDA indicate the level of cell membrane damage that causes tissue damage.⁸

Inflammatory cells are one of the body's defence systems against toxic substances that attack the body and respond to injuries.⁸ Inflammatory cell activity occurs because of the body being exposed to toxic antigens such as carbofuran. Non-specific immune responses will work against these antigens at the site of damage.¹⁰ The presence of inflammatory cells in the duodenal lamina propria shows the body's response to injury from the carbofuran exposure (see Figure 1). The presence of inflammatory cells in tissues is a tissue response to injury.¹⁷ The results present that inflammatory cell's infiltration increases along with the increasing doses (Table 1). This indicates that carbofuran metabolites in the milk increase along with the increasing ROS activity. In line with the previous research conducted,¹¹ there is an increase in

ROS activity by measuring the MDA levels of the brain in four-days-old mice along with the increase in carbofuran doses given to the mothers. In its activity, ROS causes lipid peroxidation which accelerates intestinal cell damage.¹⁶ According to the previous study,¹⁸ lipid peroxidation triggers cells secreting the inflammatory cytokines that activate the response of inflammatory cells. Based on the previous study,¹⁶ ROS that occurs causes the accumulation of inflammatory cells in the intestinal mucosa. Moreover, inflammatory cells such as neutrophils and macrophages in the intestinal mucosa produce more ROS which can damage the cytoskeleton protein and epithelial permeability which leads to the damage of intestinal barrier.

The mechanism of carbofuran in causing the toxic effects in the form of increasing ROS activity has been investigated.^{1,8,11,19} The presence of excessive amounts of ROS triggers the formation of hydroxyl radicals that are highly reactive and harmful to the body. Hydroxyl radicals interfere with the normal function of cells by producing membrane lipid peroxidation. Lipid peroxidation then causes reversible lesions in the form of degeneration. In line with previous research that changes in membrane lipids can lead cells to be unable to maintain ionic homeostasis and fluids thus exposure to carbofuran can cause cell degeneration.^{17,20,22}

Degeneration due to the damaged cell membranes provoke the accumulation of lipids and other particles in cells.¹⁰ Duodenal degeneration is a form of fatty degeneration characterized by the enlarged size in cytoplasm of duodenal epithelial cells due to the presence of fat vacuoles, while in the staining of HE, cytoplasm containing fat appears empty and the nucleus is pushed to the edge (see Figure 2). In this study, it is found an incline in degeneration along with the increasing exposure doses (see Table 1). This is due to the presence of increased ROS which is then followed by the increasing lipid peroxidation which lead to the increased degeneration. In line with the research previously,^{1,11} the administration of carbofuran in mice causes a significant increase in MDA levels based on the length of exposure and the dose of carbofuran. Degeneration and continuous damage to cell membranes can affect the state of the cell. Membrane damage from cell organelles can affect cell balance and metabolism so that it

can cause cell death (necrosis). Groups of 1/16 LD₅₀, 1/8 LD₅₀, and 1/4 LD₅₀ experience an increase in necrosis proportionally to the carbofuran dose given to the mothers during lactation periods (see Table 1). Carbofuran metabolites in mice mother's milk can trigger the duodenal necrosis of mice. Free radicals lead to ATP depletion and stimulate the release of proteolytic enzymes resulting in necrosis. Changes to the irreversible injury are associated with the increased cell swelling, ruptured lysosomes, swollen mitochondria, and an increased calcium in the cytoplasm leading to a growth in several enzymes including phospholipase and proteases which make the cell membranes rupture. Membrane damage has passed the point of no return and irreversible damage can occur because of the cell fails to maintain its balance.¹⁰

Necrosis is characterized by the presence of duodenal epithelial cell nucleus that experience karyopyknotic, karyorrhexis and karyolysis (see Figure 3). The results of this study show necrosis grows along with the increase in carbofuran doses, although there were no significant differences between groups 1/8 LD₅₀ (0.625 mg/kg BW) and 1/4 LD₅₀ (1.25 mg/kg BW) (see Table 1). This is because ROS causes other types of death through DNA fragmentation and causes apoptosis.¹⁰ Apoptosis and necrosis are the two main modes of cell death requiring the balanced molecular interactions between these two cellular death modes. Several death initiators, effector molecules and signalling pathways have been identified as primary mediators and as switches to decide which route of cell death to be taken depending on the specific situation.²¹ The results of this study indicate the effects of carbofuran on organ histopathological changes depending on the dose given. Previous researches^{20,22} show a linear relationship that high doses cause high level of damage and compensation efforts.

Conclusions

Carbofuran exposure in the mice mothers during lactation periods can cause an increase in inflammatory cell infiltration, degeneration and necrosis in the duodenum of infant mice along with the increasing doses.

Acknowledgments

The authors express sincere thanks to the Ministry of Research, Technology and Higher Education of the Republic of Indonesia for funding research and Dean Faculty of Veterinary Medicine for providing all necessary facilities and fund for conducting research work.

Declaration of Interest

The authors declare that there is no conflict of interest regarding the publication of this paper.

References

- Otieno P, Lalah J, Virani MZ, et al. Soil and Water Contamination with Carbofuran Residues in Agricultural Farmlands in Kenya Following the Application of the Technical Formulation Furadan. *J Environ Sci Heal B* 2019; 45(2):137-44.
- Mariyono J, Dewi HA, Putu B, Daroini PB, et al. Farming Practices of Vegetables: A Comparative Study in Four Regions of East Java and Bali Provinces. *J Agr Rural Dev Res* 2018; 4(2):81-91.
- Indraningsih. Effect of Carbamate Insecticide on The Health of Livestock and its Products. *Jurnal Wartazoa* 2008; 18(2): 101-14.
- Rai DK, Sharma B. Carbofuran-Induced Oxidative Stress in Mammalian Brain. *Mol Biotechnol* 2007; 37(1):66-71.
- Gross SM, Resnik AK, Nanda JP, et al. Early Postpartum: A Critical Period in Setting the Path for Breastfeeding Success. *Breastfeed Med* 2011; 6(6):407-12.
- Keegan J, Michelle W, Martin D, et al. Benzimidazole Carbamate Metabolites in Milk: Detection by Surface Plasmon Resonance-biosensor, Using a Modified QuEChERS (Quick, Easy, Cheap, Effective, Rugged and Safe) Method for Extraction. *Anal Chim Acta*. 2009; 654(2):111-9.
- Lin JH, Chiba M, Baillie TA. Is the Role of the Small Intestine in First-pass Metabolism overemphasized? *Pharmacol Rev* 1999; 51(2):135-58.
- Luqman EM, Sudiana IK, Darmanto W, et al. Mouse (*Mus Musculus*) Embryonic Cerebral Cortex Cell Death Caused by Carbofuran Insecticide Exposure. *J Vet Res*. 2019; 63(3): 413–21.
- Sharma RK, Sharma B. In-vitro Carbofuran Induced Genotoxicity in Human Lymphocyte and its Mitigation by Vitamin C and E. *Dis Markers*. 2012; 32(3):153-63.
- Horton JW. Free Radicals and Lipid Peroxidation Mediated Injury in Burn Trauma: The Role of Antioxidant Therapy. *Toxicol* 2003;189(1):75-88.
- Luqman EM, Widjiati, Yustinasari LR. Brain Cells Death on Infant Mice (*Mus musculus*) Caused by Carbofuran Exposure During the Lactation Period. *Kafkas University Veteriner Fakultesi Dergisi* 2018; 24(6):845-852.
- Vliet AV, Aalt B. Role of Reactive Oxygen Species in Intestinal Disease. *Free Radic. Biol. Med* 1992; 12(6): 499-513.
- Bhattacharyya A, Chattopadhyay R, Mitra S, et al. Oxidative Stress: An Essential Factor in the Pathogenesis of Gastrointestinal Mucosal Diseases. *Physiol Rev* 2014; 94(2): 329–54.
- Koppel N, Rekdal VM, Balskus EP. Chemical Transformation of Xenobiotics by the Human Gut Microbiota. *Science* 2018; 356(6344):1-11.
- Mansour SA, Mossa AH. Adverse Effect of Lactation Exposure to Chlorpyrifos in Suckling Rats. *Hum Exp Toxicol* 2010; 29(2):77-92.

16. Zhao M, Tang S, Xin J, et al. Reactive Oxygen Species Induce Injury of the Intestinal Epithelium During Hyperoxia. *Int J Mol Med* 2018; 41(1): 322–30.
17. Chen L, Deng H, Cui H, et al. Inflammatory Responses and Inflammation-Associated Diseases in Organs. *Oncotarget* 2018; 9(6): 7204–18.
18. Tayal D, Goswami B, Patra SK, et al. Association of Inflammatory Cytokines, Lipid Peroxidation End Products and Nitric Oxide with the Clinical Severity and Fetal Outcome in Preeclampsia in Indian Women. *Indian J Clin Biochem* 2014; 29(2): 139–44.
19. Rai DK, Rai PK, Rizvi SI, et al. Carbofuran-induced Toxicity in Rats: Protective Role of Vitamin C. *Toxikologische Pathologie* 61(6):531-5.
20. Sharma RK, Jaiswal S, Siddiqi N, et al. Effect of Carbofuran on Some Biochemical Indices of Human Erythrocytes in Vitro. *Cell Mol Biol* 2012;58(1):103-09.
21. Nikolettou V, Markaki M, Palikaras K, et al. Crosstalk Between Apoptosis, Necrosis and Autophagy. *Biochim Biophys Acta* 2013; 1833(12): 3448–59.
22. Ozden S, Catagol B, Gezginci-oktayoglu, et al. Acute Effect of Methiocarb on Oxidative Damage and the Protective Effect of Vitamin E and Taurin in the Liver and Kidney of Wistar Rats. *Toxicol Ind Health* 2013; 29(1): 60-71.