

# The Increasing Inflammatory Cells, Degeneration and Duodenal Necrosis on Infant Mice from Carbofuran Exposed Mothers

*by Epy M. luqman*

---

**Submission date:** 20-Dec-2022 11:12AM (UTC+0800)

**Submission ID:** 1984824730

**File name:** The\_Increasing\_Inflammatory\_Cells,\_Degeneration\_and\_Duodenal.pdf (601.91K)

**Word count:** 3583

**Character count:** 19034

## The Increasing Inflammatory Cells, Degeneration and Duodenal Necrosis on Infant Mice from Carbofuran Exposed Mothers

E. Z. Yanti<sup>1</sup>, H. A. Hermadi<sup>2</sup>, P. S. Rejeki<sup>3</sup>, Y. Dhamayanti<sup>4</sup>, Widjiati<sup>4</sup>, E. M. Luqman<sup>4\*</sup>

1. Faculty of Veterinary Medicine, Universitas Airlangga, Surabaya, East Java, Indonesia
2. Department of Veterinary Reproduction, Faculty of Veterinary Medicine, Universitas Airlangga Surabaya, East Java, Indonesia.
3. Department of Physiology, Faculty of Medicine Universitas Airlangga Surabaya, East Java, Indonesia.
4. Department of Veterinary Anatomy, Faculty of Veterinary Medicine, Universitas Airlangga, Surabaya, East Java, Indonesia.

12

### Abstract

This study was designed to observe the effect of carbofuran induction as a trigger for ROS on duodenal histopathology in infant mice exposed to transmammary.

This study aimed to evaluate any inflammation, degeneration and duodenal necrosis in the infant mice from the carbofuran exposed mothers during the lactation periods. There were 20 strain 10 lb/C mice were divided into four groups, each group contained five mice. Control group induced with 0.1 ml/kg Body Weight (BW) of aquadeg, Carbofuran Group 1/16 LD<sub>50</sub> with the dose of 0.3125 mg/kg BW, carbofuran Group 1/8 LD<sub>50</sub> with the dose of 0.625 mg/kg BW, and Carbofuran Group 1/4 LD<sub>50</sub> with the dose of 1.25 mg/kg BW. Mice mothers were exposed to carbofuran orally from Day 1 to 9 after giving birth. On Day 10, infant mice were sacrificed, one from each parent. Next, the infant mice duodenums were stained using hematoxylin-eosin.

The results show that carbofuran exposure causes an increase in inflammation ( $p = 0.001$ ), degeneration ( $p = 0.001$ ) and necrosis ( $p = 0.002$ ). Carbofuran leads to oxidative duodenal stress in infant mice which triggers the increase in inflammation, degeneration and necrosis in infant mice's duodenum along with the increasing doses.

Experimental article (J Int Dent Med Res 2020; 13(2): 785-790)

**Keywords:** Carbofuran, lactation, inflammation, degeneration, necrosis, duodenum.

**Received date:** 24 February 2020

**Accept date:** 03 May 2020

### Introduction

Carbofuran is an insecticide that is often used in the agricultures to avoid pests or diseases in the agricultural crops and plantations. Improper use can cause various side effects for the environment.<sup>1</sup> In the city of Batu, Malang, East Java, Indonesia, 95% of vegetable and fruit farmers got poisoned by insecticide due to insecticide residues in their drinking water<sup>2</sup> and their agricultural products as an effect of intensive insecticide use.<sup>3</sup> This carbamate insecticide is easily decomposed in the wild and in the food chain but is highly toxic in the non-target animals.<sup>3</sup> Carbofuran has been proven to accumulate in fat and has a negative impact on the brain, liver, ribbed muscles, non-target

mammalian heart, maternal plasma, umbilical cord, and new-borns.<sup>1,4</sup>

Lactation is a critical period of development of postpartum individuals because the organ functions and systems are still developing, thus, so that they are more susceptible to functional disorders.<sup>5</sup> Metabolic material in the milk due to insecticide exposure in the lactating mothers allows the transmission of toxic substances to children.<sup>6</sup> The intestine is an organ that plays an important role in the process of food absorption. The intestine can also be the main channel or portal for the entry of unwanted substances in the body such as the toxic insecticides and drugs.<sup>5,7</sup> According to Indraningsih,<sup>3</sup> the orally induced insecticides can result in the hypermotility and malabsorption in digestive tract. Hypermotility and malabsorption are caused by a decrease in enterocyte cell's number due to the increased necrosis.

The effects of carbofuran create free radicals in the form of reactive oxygen species (ROS) that can trigger the death of body cells.<sup>8</sup> High free radicals are dangerous for living

#### \*Corresponding author:

E. M. Luqman

Department of Veterinary Anatomy,  
Faculty of Veterinary Medicine,  
Universitas Airlangga Surabaya, East Java, Indonesia  
E-mail: epy-m-l@fkh.unair.ac.id

creatures.<sup>9</sup> Free radicals form the membrane lipid peroxidation, thus, the fatty acid chains in cell membranes break down and provoke injury<sup>2</sup> the cells.<sup>10</sup> Research conducted by<sup>11</sup> showed an increase in MDA levels in the brains of mice exposed to carbofuran from their mother's milk for four days. The increased levels of MDA indicate a rise in the damaged cell membranes which leads to a decline in the cell function in the form of cell degeneration (reversible) and necrosis (irreversible).<sup>8</sup> In addition, free radicals are known for increasing the permeability of intestinal mucosa so that inflammatory cell's infiltration can occur in the intestinal mucosa.<sup>12,13</sup>

Research on the effect of transmammary carbofuran administration is needed to find out the effects that can be caused on the infants during breastfeeding. The duodenum of small intestine is an important organ in digesting various substances that enter through the digestive system, also an important organ in the metabolism of xenobiotic substances including pollutants, drugs, and toxic components in food.<sup>14</sup> Observation of inflammatory cells, degeneration and necrosis is one way to determine the effect of carbofuran exposure in the mice mothers during the lactation periods against the duodenum of infant mice (*Mus musculus*).

### Materials and methods

The research was carried out in the Department of Veterinary Anatomy, In vitro Fertilization Laboratory and Veterinary Pathology Department of the Faculty of Veterinary Medicine, Airlangga University, Surabaya in August - October 2019.

This study used 20 pregnant strain Balb/C female mice with the body weights around 25-30 grams. It also employed Carbofuran 98% (Sigma Aldrich, Bellstain Registry number 1428746, Product of USA), distilled water, 70% alcohol, 10% formalin, experimental cage, drinking pot, feeding tube syringe, 3 ml syringe, minor surgical instrument, petri dish, and microscope Olympus® CX-41. This study applied the approach of Carbofuran LD<sub>50</sub> fraction given to mice mothers, they were 1/16 LD<sub>50</sub> with 0.3125 mg/kg BW, 1/8 LD<sub>50</sub> with 0.625 mg/kg BW, 1/4 LD<sub>50</sub> with 1.25 mg/kg BW.

The pregnant mice mothers were adapted and divided randomly into 4 groups, each group consisting of five mice. Carbofuran exposure is

given in the lactation period of Day 1 to Day 9 orally. The control group was given with 0.5 ml of aquadest per day each, while the treatment groups were induced with carbofuran solution with a dose of 1/16 LD<sub>50</sub> (0.3125 mg/kg BW), 1/8 LD<sub>50</sub> (0.625 mg/kg BW), and 1/4 LD<sub>50</sub> (1.25 mg/kg BW). On Day 10 infant mice were sacrificed and its duodenum was taken, then the histopathological preparations were made.

Observations were made using a 400x magnification microscope at five different fields of view, then assessed using Vadhnyana's scoring system (2015) as follows: inflammatory cell's infiltration (0) there was no inflammatory cell's infiltration, (1) local or focal inflammatory cell's infiltration, (2) multifocal inflammatory cell's infiltration, (3) even or diffuse inflammatory cell's infiltration. While for cell degeneration, it applied the scoring as follow: cell degeneration (0) there is no cell degeneration, (1) local or focal cell degeneration, (2) multifocal cell degeneration, (3) uniform or diffuse cell degeneration. Furthermore, for necrosis, it used this following scoring: necrosis (0) no necrosis, (1) local or focal necrosis, (2) multifocal necrosis, (3) even or diffuse necrosis.

Observation data were analysed using the Kruskal-Wallis test, if there were significant differences it would be followed by the Mann-Whitney test. It calculated using Statistical Program for Social Scientific (SPSS) version 21.

### Results

The duodenum of the small intestine is a digestive organ that plays an important role in digesting various xenobiotic substances including pollutants, drugs, and toxic components in food.<sup>14</sup> The observation of the duodenum in infant mice from mothers with carbofuran exposure for nine days shows that there are microscopic changes in the form of inflammatory cell's infiltration, degeneration and necrosis. While, data from the Kruskal-Wallis test reveals that the results are significantly different ( $p < 0.05$ ) in inflammatory cell's infiltration, degeneration and necrosis variables (see Table 1). The results present the infiltration of inflammatory cells increases with the increasing doses (see Table 1). The increased visible cell's inflammation in the duodenal lamina propria displays a body response to injury from carbofuran exposure (see Figure 1). In this study, it is also found that an

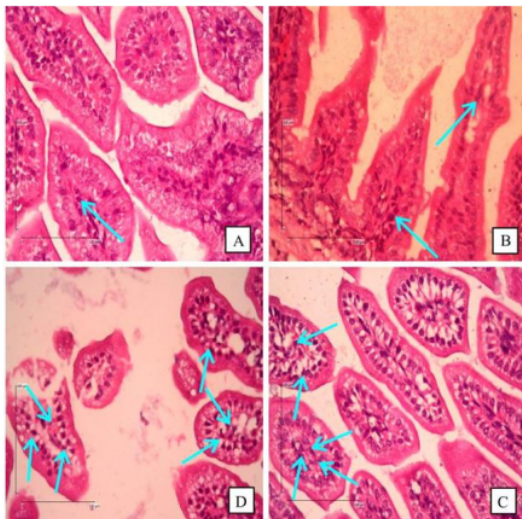


increase in degeneration along with the increasing doses of exposure. Duodenal fattening degeneration in infant mice is indicated by an incline in fat vacuoles in the cell cytoplasm (see Table 1 and Figure 2).

Treatments	Inflammatory Cell's Infiltration (Mean±SD)	Degeneration (Mean±SD)	Necrosis (Mean±SD)
Control Group	0.04±0.06 <sup>a</sup>	0.23±0.32 <sup>a</sup>	0.00±0.00 <sup>a</sup>
1/16 LD <sub>50</sub> (0.3125 mg/kg BW)	0.12±0.03 <sup>b</sup>	0.85±0.24 <sup>b</sup>	0.08±0.03 <sup>b</sup>
1/8 LD <sub>50</sub> (0.625 mg/kg BW)	0.21±0.11 <sup>c</sup>	1.80±0.09 <sup>c</sup>	0.24±0.10 <sup>c</sup>
1/4 LD <sub>50</sub> (1.25 mg/kg BW)	0.43±0.06 <sup>d</sup>	2.13±0.29 <sup>d</sup>	0.36±0.28 <sup>c</sup>

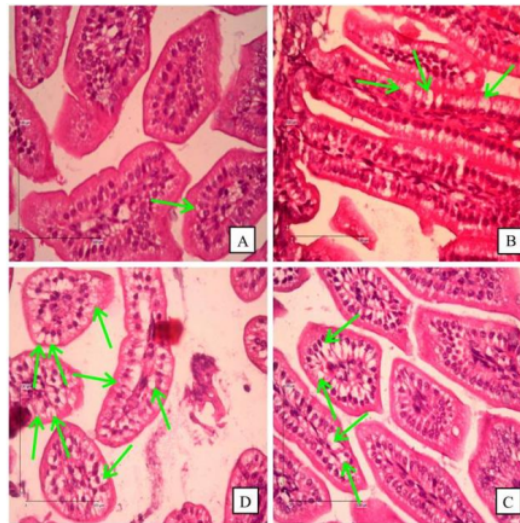
**Table 1.** Scoring of inflammatory cell's infiltration, duodenal degeneration and necrosis of infant mice from mothers with carbofuran exposure during lactation periods.

Remarks: Different superscripts in the same column show significant differences ( $p < 0.05$ ).

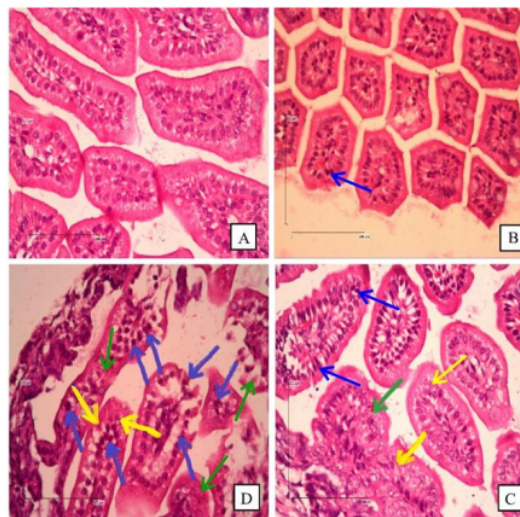


**Figure 1.** Infiltration of inflammatory cells in the duodenum of infant mice shown in blue arrows. A = control, B = 1/16 LD<sub>50</sub> (0.3125 mg/kg BW), C = 1/8 LD<sub>50</sub> (0.625 mg/kg BW), and D = 1/4 LD<sub>50</sub> (1.25 mg/kg BW). 400x magnification.

Moreover, the results also indicate a growth in necrosis along with an upgrade in carbofuran doses, although there are no any significant differences between groups 1/8 LD<sub>50</sub> (0.625 mg/kg BW) and 1/4 LD<sub>50</sub> (1.25 mg/kg BW). Necrosis is characterized by the presence of duodenal epithelial cell nucleus that experiences karyopyknotic, karyorrhexis and karyolysis (see Table 1 and Figure 3).



**Figure 2.** Duodenal fattening Degeneration in infant mice shown in green arrows (Characteristic of degeneration: there are fat vacuoles in the cell cytoplasm). A = control, B = 1/16 LD<sub>50</sub> (0.3125 mg/kg BW), C = 1/8 LD<sub>50</sub> (0.625 mg/kg BW), and D = 1/4 LD<sub>50</sub> (1.25 mg/kg BW). 400x magnification.



**Figure 3.** Duodenal necrosis of infant mice. Necrosis is characterized by karyopyknotic (blue arrow), karyorrhexis (yellow arrow), and karyolysis (green arrow). A = control, B = 1/16 LD<sub>50</sub> (0.3125 mg/kg BW), C = 1/8 LD<sub>50</sub> (0.625 mg/kg BW), and D = 1/4 LD<sub>50</sub> (1.25 mg/kg BW). 400x magnification.

## Discussion

Carbofuran leaves residues in the environment and is easily absorbed by the body through skin, inhalation and oral, which is then absorbed by the intestine.<sup>3</sup> Toxic manifestations of carbamate metabolites associated with the formation of free radicals (ROS).<sup>1</sup> Carbofuran metabolites can reach the brain, muscles, heart, liver, placenta, foetus, umbilicus, fat tissue, blood and milk.<sup>3,6,11</sup> Carbofuran has lipophilic properties so that it can enter the mother's milk through the mother's blood plasma passively.<sup>9,15</sup> Carbofuran metabolites in the milk allow the transmission of harmful substances from mother to child. The concentration of metabolites in milk can be higher than in the blood plasma because blood flow to the mother is faster than the secretion, allowing for accumulation.<sup>15</sup>

Carbofuran stimulates reactive oxygen species (ROS) and causes the death of body cells including intestinal epithelial cells.<sup>8,16</sup> From this study, it is found an increase in MDA levels in the brain of infant mice exposed to transmammary carbofuran for four days.<sup>11</sup> The findings support this study that carbofuran exposure to mothers during the lactation periods inclines the free radicals in breast-fed infant mice. According to previous study, free radicals can cause membrane lipid peroxidation, thus, the fatty acid chains in cell membranes break down and trigger injury to cells.<sup>10</sup> This reaction produces MDA on the network. The increased levels of MDA indicate the level of cell membrane damage that causes tissue damage.<sup>8</sup>

Inflammatory cells are one of the body's defence systems against toxic substances that attack the body and respond to injuries.<sup>8</sup> Inflammatory cell activity occurs because of the body being exposed to toxic antigens such as carbofuran. Non-specific immune responses will work against these antigens at the site of damage.<sup>10</sup> The presence of inflammatory cells in the duodenal lamina propria shows the body's response to injury from the carbofuran exposure (see Figure 1). The presence of inflammatory cells in tissues is a tissue response to injury.<sup>17</sup> The results present that inflammatory cell's infiltration increases along with the increasing doses (Table 1). This indicates that carbofuran metabolites in the milk increase along with the increasing ROS activity. In line with the previous research conducted,<sup>11</sup> there is an increase in

ROS activity by measuring the MDA levels of the brain in four-days-old mice along with the increase in carbofuran doses given to the mothers. In its activity, ROS causes lipid peroxidation which accelerates intestinal cell damage.<sup>16</sup> According to the previous study,<sup>18</sup> lipid peroxidation triggers cells secreting the inflammatory cytokines that activate the response of inflammatory cells. Based on the previous study,<sup>16</sup> ROS that occurs causes the accumulation of inflammatory cells in the intestinal mucosa. Moreover, inflammatory cells such as neutrophils and macrophages in the intestinal mucosa produce more ROS which can damage the cytoskeleton protein and epithelial permeability which leads to the damage of intestinal barrier.

The mechanism of carbofuran in causing the toxic effects in the form of increasing ROS activity has been investigated.<sup>1,8,11,19</sup> The presence of excessive amounts of ROS triggers the formation of hydroxyl radicals that are highly reactive and harmful to the body. Hydroxyl radicals interfere with the normal function of cells by producing membrane lipid peroxidation. Lipid peroxidation then causes reversible lesions in the form of degeneration. In line with previous research that changes in membrane lipids can lead cells to be unable to maintain ionic homeostasis and fluids thus exposure to carbofuran can cause cell degeneration.<sup>17,20,22</sup>

Degeneration due to the damaged cell membranes provoke the accumulation of lipids and other particles in cells.<sup>10</sup> Duodenal degeneration is a form of fatty degeneration characterized by the enlarged size in cytoplasm of duodenal epithelial cells due to the presence of fat vacuoles, while in the staining of HE, cytoplasm containing fat appears empty and the nucleus is pushed to the edge (see Figure 2). In this study, it is found an incline in degeneration along with the increasing exposure doses (see Table 1). This is due to the presence of increased ROS which is then followed by the increasing lipid peroxidation which lead to the increased degeneration. In line with the research previously,<sup>1,11</sup> the administration of carbofuran in mice causes a significant increase in MDA levels based on the length of exposure and the dose of carbofuran. Degeneration and continuous damage to cell membranes can affect the state of the cell. Membrane damage from cell organelles can affect cell balance and metabolism so that it



can cause cell death (necrosis). Groups of 1/16 LD<sub>50</sub>, 1/8 LD<sub>50</sub>, and 1/4 LD<sub>50</sub> experience an increase in necrosis proportionally to the carbofuran dose given to the mothers during lactation periods (see Table 1). Carbofuran metabolites in mice mother's milk can trigger the duodenal necrosis of mice. Free radicals lead to ATP depletion and stimulate the release of proteolytic enzymes resulting in necrosis. Changes to the irreversible injury are associated with the increased cell swelling, ruptured lysosomes, swollen mitochondria, and an increased calcium in the cytoplasm leading to a growth in several enzymes including phospholipase and proteases which make the cell membranes rupture. Membrane damage has passed the point of no return and irreversible damage can occur because of the cell fails to maintain its balance.<sup>10</sup>

Necrosis is characterized by the presence of duodenal epithelial cell nucleus that experience karyopyknotic, karyorrhexis and karyolysis (see Figure 3). The results of this study show necrosis grows along with the increase in carbofuran doses, although there were no significant differences between groups 1/8 LD<sub>50</sub> (0.625 mg/kg BW) and 1/4 LD<sub>50</sub> (1.25 mg/kg BW) (see Table 1). This is because ROS causes other types of death through DNA fragmentation and causes apoptosis.<sup>10</sup> Apoptosis and necrosis are the two main modes of cell death requiring the balanced molecular interactions between these two cellular death modes. Several death initiators, effector molecules and signalling pathways have been identified as primary mediators and as switches to decide which route of cell death to be taken depending on the specific situation.<sup>21</sup> The results of this study indicate the effects of carbofuran on organ histopathological changes depending on the dose given. Previous researches<sup>20,22</sup> show a linear relationship that high doses cause high level of damage and compensation efforts.

## Conclusions

Carbofuran exposure in the mice mothers during lactation periods can cause an increase in inflammatory cell infiltration, degeneration and necrosis in the duodenum of infant mice along with the increasing doses.

## 2

## Acknowledgments

The authors express sincere thanks to the Ministry of Research, Technology and Higher Education of the Republic of Indonesia for funding research and Dean Faculty of Veterinary Medicine for providing all necessary facilities and fund for conducting research work.

## Declaration of Interest

The authors declare that there is no conflict of interest regarding the publication of this paper.

## References

- Otieno P, Lalah J, Virani MZ, et al. Soil and Water Contamination with Carbofuran Residues in Agricultural Farmlands in Kenya Following the Application of the Technical Formulation Furadan. *J Environ Sci Heal B* 2019; 45(2):137-44.
- Mariyono J, Dewi HA, Putu B, Daroini PB, et al. Farming Practices of Vegetables: A Comparative Study in Four Regions of East Java and Bali Provinces. *J Agr Rural Dev Res* 2018; 4(2):81-91.
- Indraningsih. Effect of Carbamate Insecticide on The Health of Livestock and its Products. *Jurnal Wartazoa* 2008; 18(2): 101-14.
- Rai DK, Sharma B. Carbofuran-Induced Oxidative Stress in Mammalian Brain. *Mol Biotechnol* 2007; 37(1):66-71.
- Gross SM, Resnik AK, Nanda JP, et al. Early Postpartum: A Critical Period in Setting the Path for Breastfeeding Success. *Breastfeed Med* 2011; 6(6):407-12.
- Keegan J, Michelle W, Martin D, et al. Benzimidazole Carbamate Metabolites in Milk: Detection by Surface Plasmon Resonance-biosensor, Using a Modified QuEChERS (Quick, Easy, Cheap, Effective, Rugged and Safe) Method for Extraction. *Anal Chim Acta*. 2009; 654(2):111-9.
- Lin JH, Chiba M, Baillie TA. Is the Role of the Small Intestine in First-pass Metabolism overemphasized? *Pharmacol Rev* 1999; 51(2):135-58.
- Luqman EM, Sudiana IK, Darmanto W, et al. Mouse (*Mus Musculus*) Embryonic Cerebral Cortex Cell Death Caused by Carbofuran Insecticide Exposure. *J Vet Res*. 2019; 63(3): 413–21.
- Sharma RK, Sharma B. In-vitro Carbofuran Induced Genotoxicity in Human Lymphocyte and its Mitigation by Vitamin C and E. *Dis Markers*. 2012; 32(3):153-63.
- Horton JW. Free Radicals and Lipid Peroxidation Mediated Injury in Burn Trauma: The Role of Antioxidant Therapy. *Toxicol* 2003;189(1):75-88.
- Luqman EM, Widjati, Yustinasari LR. Brain Cells Death on Infant Mice (*Mus musculus*) Caused by Carbofuran Exposure During the Lactation Period. *Kafkas University Veteriner Fakultesi Dergisi* 2018; 24(6):845-852.
- Vliet AV, Aalt B. Role of Reactive Oxygen Species in Intestinal Disease. *Free Radic. Biol. Med* 1992; 12(6): 499-513.
- Bhattacharyya A, Chattopadhyay R, Mitra S, et al. Oxidative Stress: An Essential Factor in the Pathogenesis of Gastrointestinal Mucosal Diseases. *Physiol Rev* 2014; 94(2): 329–54.
- Koppel N, Rekdal VM, Balskus EP. Chemical Transformation of Xenobiotics by the Human Gut Microbiota. *Science* 2018; 356(6344):1-11.
- Mansour SA, Mossa AH. Adverse Effect of Lactation Exposure to Chlorpyrifos in Suckling Rats. *Hum Exp Toxicol* 2010; 29(2):77-92.

16. Zhao M, Tang S, Xin J, et al. Reactive Oxygen Species Induce Injury of the Intestinal Epithelium During Hyperoxia. *Int J Mol Med* 2018; 41(1): 322–30.
17. Chen L, Deng H, Cui H, et al. Inflammatory Responses and Inflammation-Associated Diseases in Organs. *Oncotarget* 2018; 9(6): 7204–18.
18. Tayal D, Goswami B, Patra SK, et al. Association of Inflammatory Cytokines, Lipid Peroxidation End Products and Nitric Oxide with the Clinical Severity and Fetal Outcome in Preeclampsia in Indian Women. *Indian J Clin Biochem* 2014; 29(2): 139–44.
19. Rai DK, Rai PK, Rizvi SI, et al. Carbofuran-induced Toxicity in Rats: Protective Role of Vitamin C. *Toxikologische Pathologie* 61(6):531-5.
20. Sharma RK, Jaiswal S, Siddiqi N, et al. Effect of Carbofuran on Some Biochemical Indices of Human Erythrocytes in Vitro. *Cell Mol Biol* 2012;58(1):103-09.
21. Nikolettou V, Markaki M, Palikaras K, et al. Crosstalk Between Apoptosis, Necrosis and Autophagy. *Biochim Biophys Acta* 2013; 1833(12): 3448–59.
22. Ozden S, Catagol B, Gezinci-oktayoglu, et al. Acute Effect of Methiocarb on Oxidative Damage and the Protective Effect of Vitamin E and Taurin in the Liver and Kidney of Wistar Rats. *Toxicol Ind Health* 2013; 29(1): 60-71.

# The Increasing Inflammatory Cells, Degeneration and Duodenal Necrosis on Infant Mice from Carbofuran Exposed Mothers

## ORIGINALITY REPORT

18%

SIMILARITY INDEX

16%

INTERNET SOURCES

6%

PUBLICATIONS

2%

STUDENT PAPERS

## PRIMARY SOURCES

1 [cybercampus.unair.ac.id](http://cybercampus.unair.ac.id) 5%  
Internet Source

2 [www.vetmedmosul.com](http://www.vetmedmosul.com) 5%  
Internet Source

3 [www.ektodermaldisplazi.com](http://www.ektodermaldisplazi.com) 2%  
Internet Source

4 [repo.stikesicme-jbg.ac.id](http://repo.stikesicme-jbg.ac.id) 1%  
Internet Source

5 [www.thejaps.org.pk](http://www.thejaps.org.pk) 1%  
Internet Source

6 Epy Muhammad Luqman, I Ketut Suidiana, Win Darmanto, Agung Budianto Achmad, Widjiati. " Mouse embryonic cerebral cortex cell death caused by carbofuran insecticide exposure ", Journal of Veterinary Research, 2019  
Publication <1%



7	Internet Source	<1 %
8	nexusacademicpublishers.com Internet Source	<1 %
9	jwpr.science-line.com Internet Source	<1 %
10	nopr.niscair.res.in Internet Source	<1 %
11	www.wvj.science-line.com Internet Source	<1 %
12	Yilmaz-Ozden, T., A. Can, A. Karatug, Z. Pala-Kara, A. Okyar, and S. Bolkent. "Carbon tetrachloride-induced kidney damage and protective effect of Amaranthus lividus L. in rats", Toxicology and Industrial Health, 2014. Publication	<1 %
13	brother-quiet.xyz Internet Source	<1 %
14	Amer J. Al-Malahmeh, Abdelmajeed Al-Ajlouni, Sebastiaan Wesseling, Ans E. M. F. Soffers et al. "Physiologically based kinetic modeling of the bioactivation of myristicin", Archives of Toxicology, 2016 Publication	<1 %
15	journal.um-surabaya.ac.id Internet Source	<1 %

16 [progressinorthodontics.springeropen.com](https://progressinorthodontics.springeropen.com) <1 %  
Internet Source

---

17 B. A. Magnuson, G. A. Burdock, J. Doull, R. M. Kroes et al. "Aspartame: A Safety Evaluation Based on Current Use Levels, Regulations, and Toxicological and Epidemiological Studies", *Critical Reviews in Toxicology*, 2008 <1 %  
Publication

---

18 Muhammad Thohawi Elziyad Purnama, Dodit Hendrawan, Arya Pradana Wicaksono, Faisal Fikri, Agus Purnomo, Shekhar Chhetri. "Risk factors, hematological and biochemical profile associated with colic in Delman horses in Gresik, Indonesia", *F1000Research*, 2022 <1 %  
Publication

---

19 Erica L. Liebelt. "NTP-CERHR Expert Panel Report on the reproductive and developmental toxicity of hydroxyurea", *Birth Defects Research Part B Developmental and Reproductive Toxicology*, 08/2007 <1 %  
Publication

---

Exclude quotes  Off

Exclude matches  Off

Exclude bibliography  On

# The Increasing Inflammatory Cells, Degeneration and Duodenal Necrosis on Infant Mice from Carbofuran Exposed Mothers

---

GRADEMARK REPORT

---

FINAL GRADE

**/0**

GENERAL COMMENTS

**Instructor**

---

PAGE 1

---

PAGE 2

---

PAGE 3

---

PAGE 4

---

PAGE 5

---

PAGE 6

---