

Inhibition of Type I Collagen Expression in Fibrosis Prevention after Trabeculectomy: *Oryctolagus cuniculus*

Nurwasis^{1*}, Shinta Arta Wiguna¹, Evelyn Komaratih¹, Heryawati²

¹Department of Ophthalmology, Faculty of Medicine-Dr. Soetomo Teaching Hospital, Universitas Airlangga, Surabaya 60131, Indonesia

²Department of Anatomical Pathology, Faculty of Medicine-Dr. Soetomo Teaching Hospital, Universitas Airlangga, Surabaya 60131, Indonesia

ABSTRACT

The administration of postoperative bevacizumab injection in subconjunctival trabeculectomy will reduce bleb fibrosis. This study aimed to investigate the effect of bevacizumab as an antifibrotic agent on collagen density, collagen thickness and type I collagen expression after trabeculectomy in rabbits. Sixteen males New Zealand white rabbits were divided into two groups, control and treatment group. Masson's trichrome was performed to evaluate collagen density and thickness. Immunohistochemistry examination using a monoclonal antibody to type I collagen was performed to evaluate collagen expression. Among the sixteen samples, postoperative bleb conditions obtained diffuse bleb, and there were no differences in bleb characteristics between the control and treatment groups. Anterior chamber was deep, and cornea was clear in all animals. This study showed that the density of collagen fibers and type 1 collagen expression significantly decreased in the treatment group compared to control group ($p = 0.0075$; $p = 0.006$, respectively). However, there was no significant difference in the thickness of collagen fibers in both groups ($p = 0.323$). Bevacizumab reduces bleb fibrosis by inhibition of angiogenesis and accumulation of extracellular matrix. Postoperative subconjunctival injection of bevacizumab may limit scar tissue formation at the site of trabeculectomy by blocking collagen synthesis.

Keywords: bevacizumab, trabeculectomy, fibrosis, collagen type I

Correspondence:

Nurwasis, MD

Department of Ophthalmology, Faculty of Medicine-Dr. Soetomo Teaching Hospital, Universitas Airlangga, Surabaya 60131, Indonesia
Tel: +6231-502-0251; Fax: +6231-502-2472

E-mail: nurwasispm@yahoo.com

INTRODUCTION

Glaucoma can cause blindness similar to other diseases, such as ocular trauma (1,2). Glaucoma is also related to other infections due to VacA toxin (3,4). The glaucoma treatment is to preserve visual function by lowering intraocular pressure (IOP) (5). Trabeculectomy is the most widely used surgical filtration procedure to treat IOP that cannot be controlled by drugs or lasers. IOP is defined by the rate of the formation of aqueous humor and the amount of resistance to its flowing out of the eye (6). Elevating IOP can cause axonal damage to the optic nerve head and subsequent retinal ganglion cell death and also lead to complication, such as aqueous misdirection, which is rare (7,8). Trabeculectomy aims to reduce the IOP by making an artificial pathway for aqueous humor from the anterior chamber to the subconjunctival area. The success rate of trabeculectomy is quite low at around 24% to 74% because of the formation of fibrosis tissue occurring postoperatively in the filtration area and causing the failure of bleb formation. This bleb failure is the result of fibroblast proliferation and inflammatory cell migration in the wound healing process, thus forming excessive subconjunctival scar tissue and inhibiting the new pathway of the aqueous humor (9–11).

The modulation strategy of the healing process after the trabeculectomy process has been developed. The use of antimetabolites such as Mitomycin-C (MMC) and 5-fluorouracil (5-FU) to prevent episcleral fibrosis has been

widely used for three decades. The use of antimetabolites is the main standard used in trabeculectomy surgery. The success of using MMC in trabeculectomy surgery is about 29% to 67% of cases a year. The disadvantages of using antimetabolites is the emergence of a number of complications, such as hypotony, bleb leaks, endophthalmitis, and epithelial toxicity. Amnion membrane transplantation in trabeculectomy surgery can also be applied and has an antifibrotic effect to minimize bleb failure. Amnion membrane transplantation does not cause side effects as in the use of antimetabolites (10,12,13).

Angiogenesis is key element of the wound healing process and very important for the final formation of granulation tissue. Vascular endothelial growth factor (VEGF) is a potent cytokine promoting angiogenesis, increasing vascular permeability, migration of inflammatory cells and fibroblasts, with an effect on extracellular matrix formation. Bevacizumab (Avastin®; Genentech Inc., San Francisco, USA) is a non-selective monoclonal antibody to VEGF (14). Previous study showed that the administration of bevacizumab can reduce fibroblast proliferation and collagen deposition. It can improve the outcome of trabeculectomy (15). The administration of postoperative bevacizumab injection in subconjunctival trabeculectomy will reduce bleb fibrosis (16). Recent study also examined subconjunctival bevacizumab administration and showed good results in reducing blood vessel counts and bleb fibrosis (17). The purpose of this study was to determine the effect of bevacizumab on the density and

thickness of collagen fibers and the expression of type I collagen after trabeculectomy in rabbits.

MATERIALS DAN METHODS

This was a true experimental study on experimental animals with a randomized post-test only control group design. The study was conducted at the Universitas Airlangga Stem Cell Research and Development Center, Surabaya Indonesia from August to September 2018, after obtaining an ethical clearance from the Research Ethics Committee of the Faculty of Veterinary Medicine, Universitas Airlangga, Surabaya. The experimental animal of this study was male New Zealand white rabbit (*Oryctolagus cuniculus*) with the age of 4-6 months, weighing 2.5-3.5 kg with healthy eyes and body condition. The study used 16 rabbit eyes divided into 2 groups. Each group consisted of 8 rabbit eyes for the control group and treatment group. The drop-out criteria in this study were rabbits in sick condition, dead, and having complications of trabeculectomy surgery, such as infection, scleral perforation, vitreous prolapse, and bleeding during and after trabeculectomy.

The trabeculectomy surgery procedure was performed in the right eye of the rabbit. General anesthesia in rabbits was carried out by administering ketamine 100 mg/50 mL and xylazine 20 mg/50 mL intramuscularly as much as 0.4 cc. Partial-thickness corneal traction in the superior part was done using vicryl 8.0. The fornix-based conjunctival flap was performed in the superior quadrant, after that 3x3mm a trapezoidal sclera flap and paracentesis of the anterior chamber were performed. Then keratectomy and iridectomy were also performed. Sclera flap was closed using nylon 10.0 and conjunctiva closed using vicryl 8.0.

In the control group, trabeculectomy was performed, and an injection of subconjunctival balanced salt solution (BSS) was administered. In the treatment group, trabeculectomy and subconjunctival injection of bevacizumab in the outer area of bleb (1.25 mg in 0.05 mL BSS) were performed. Bevacizumab injection was given in single dose after trabeculectomy using 1 cc syringe and 30G needle at $\pm 3-4$ mm superior to the trabeculectomy area.

Experimental animals were sacrificed on day 14 and then enucleated in the eye. The eyeball was inserted into the formalin buffer. Conjunctival tissue in the bleb area was cut, and a histopathologic examination was performed at the Anatomical Pathology Laboratory of the Regional General Hospital Dr. Soetomo/Faculty of Medicine, Universitas Airlangga, Surabaya. Masson's trichrome examination was performed to observe the density and thickness of collagen. Collagen density results were counted using criteria according to Ekinci's research: score 1 if the collagen fibers was loose, score 2 if the collagen fibers was medium, and score 3 if the collagen fibers was dense (18). Immunohistochemical examination was carried out using monoclonal antibodies

against the expression of type I collagen. The results were counted based on the modified Remmele method with the Immunoreactive Score (IRS) (19).

Statistical analysis

The density of collagen fibers and expression of type I collagen were tested statically using Wilcoxon-Mann Whitney U test with a significance level (α) < 0.05 , whereas the thickness of collagen fibers was tested using independent t-test with a significance level (α) < 0.05 .

RESULTS

The animals were evaluated before and after trabeculectomy surgery. The examination was carried out using a slit lamp handheld to determine the anterior segment. Postoperative bleb conditions obtained diffuse bleb, and there were no differences in bleb characteristics between the control and treatment group. The anterior chamber was deep, and the cornea was clear in all animals. Figure 1 shows an overview of experimental animals on days 1, 7, and 14, postoperatively.

Table 1 shows that the density of collagen fibers significantly decrease in the treatment group ($p = 0.0075$). While Table 2 displays no significant difference in the thickness of collagen fibers in both groups ($p = 0.323$, $p > 0.05$).

Table 1: Distribution of collagen fiber density in rabbit conjunctiva

Collagen density	Groups		p
	Control	Treatment	
N	8	8	0.0075*
Median	3	2	
IQD	0.5	0.0	
Minimum	2	2	
Maximum	3	3	

IQD : interquartile deviation

* Significant at 0.05 ($p < 0.05$)

Table 2: Distribution of thickness of collagen fibers in rabbit conjunctiva

Collagen thickness	Groups (micrometers)		p
	Control	Treatment	
N	8	8	0.323*
Mean	491.36	543.15	
SD	243.03	195.13	
Minimum	114.3	303.3	
Maximum	954.0	831.6	

SD : standard deviation

* Significant at 0.05 ($p < 0.05$)

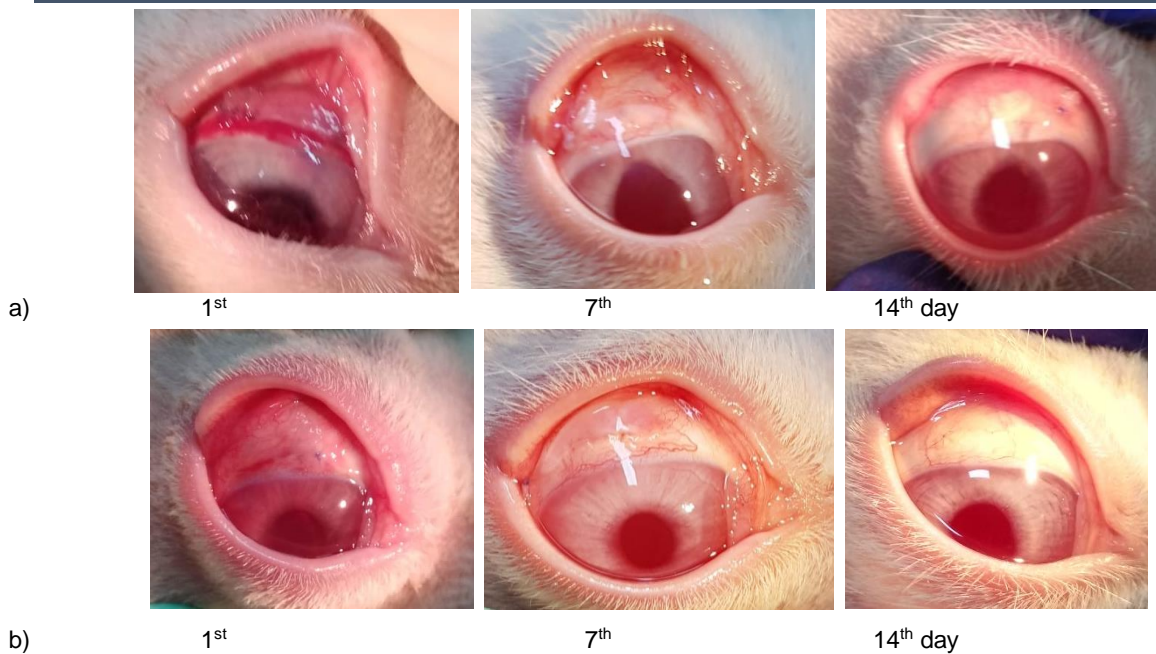


Figure 1: Examination on the Postoperative 1st, 7th, and 14th day, a. Control group, b. Treatment group

The examination of collagen density and thickness using Masson's trichrome staining is shown in Figure 2. The measurement of collagen thickness was calculated from the

overall thickness and reduced by the vacuole formed (DP2SW Olympus).

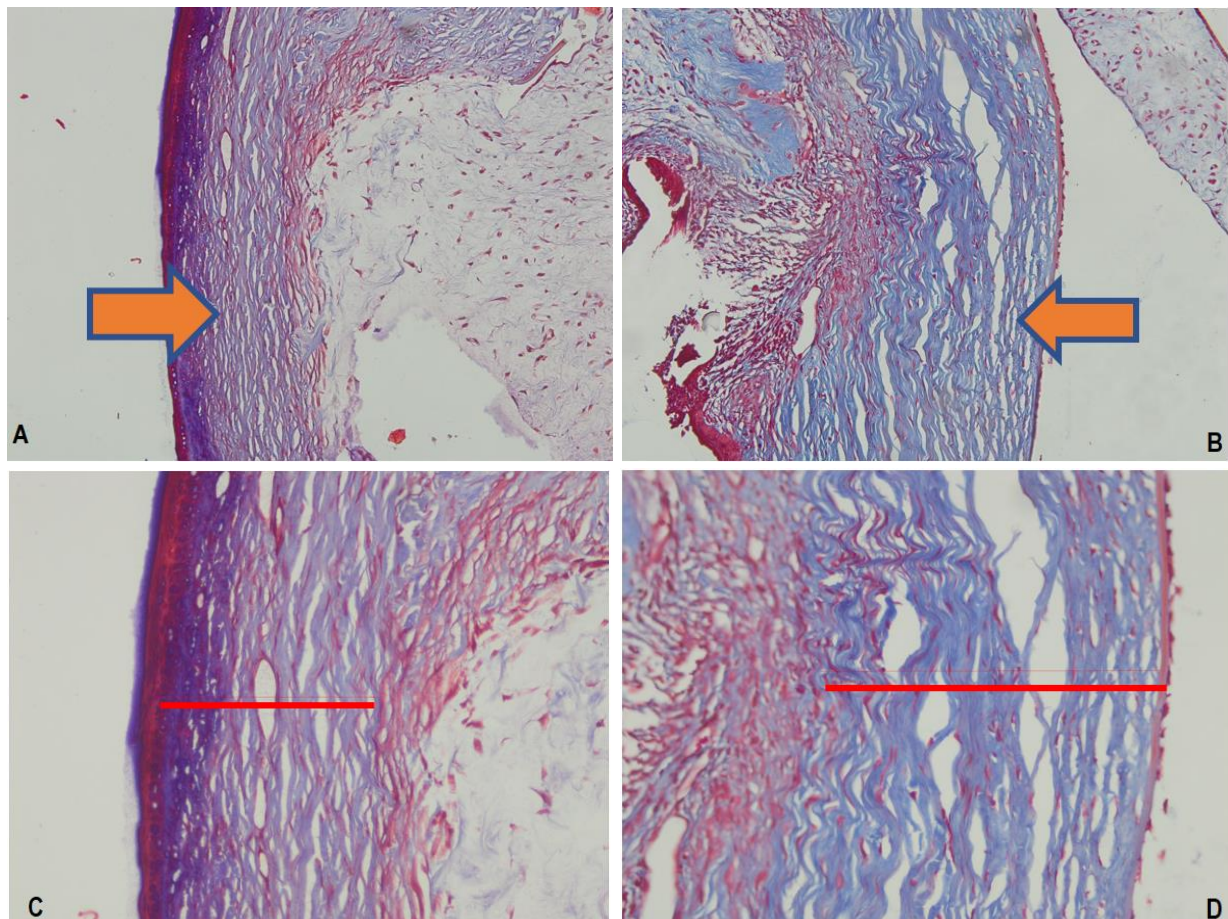


Figure 2: Collagen (blue) is shown with arrows. The density of conjunctival collagen fibers with Masson's trichrome staining is seen with 200x magnification (a. Control group, b. Treatment group). The thickness of conjunctival collagen fibers is seen with 400x magnification (c. Control group, d. Treatment group)

The expression of type I collagen was carried out by immunohistochemistry examination using Collagen I Alpha 2 Antibody in each group. Histological features of type I

collagen expression can be seen in Figure 3. The results of examination of type I collagen expression according to IRS scores obtained are presented in Table 3.

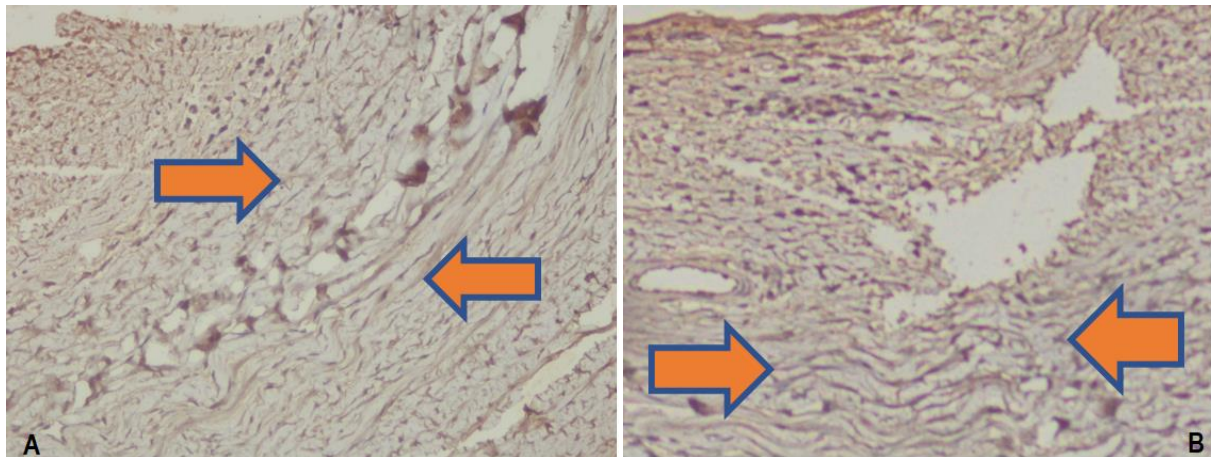


Figure 3: Expression of type I collagen with immunohistochemical staining is seen with 400x magnification. The direction of the arrow shows the expression of collagen brownish in fiber, a. Control group, b. Treatment group

There was a significant decrease in type I collagen expression in the treatment group compared to control group ($p = 0.006$, $p < 0.05$) as seen in Table 3.

Analysis of differences between collagen density, thickness, and type I collagen expression can be seen in Figures 4, 5, and 6.

Table 3: Distribution of type I collagen expression in rabbit conjunctiva

Type I Collagen Expression (IRS)	Groups		p
	Control	Treatment	
N	8	8	0.006*
Mean	5.50	2.88	
IQD	0.75	1.50	
Minimum	4	1	
Maximum	6	6	

IQD: interquartile deviation

* Significant at 0.05 ($p < 0.05$)

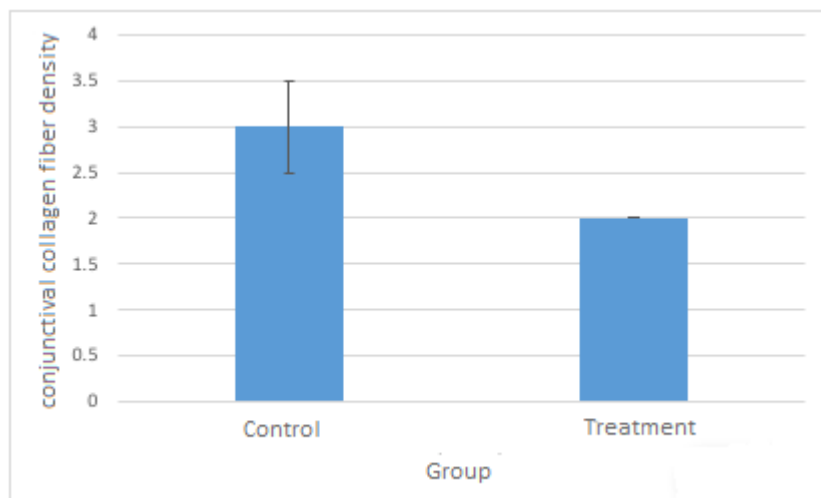


Figure 4: Diagram of conjunctival collagen fiber density in the treatment and control groups

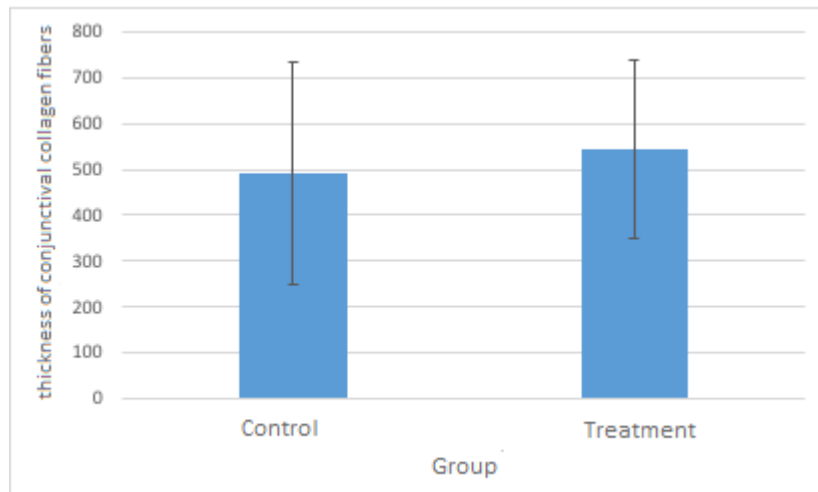


Figure 5: Diagram of the thickness of conjunctival collagen fibers in the control group and treatment group

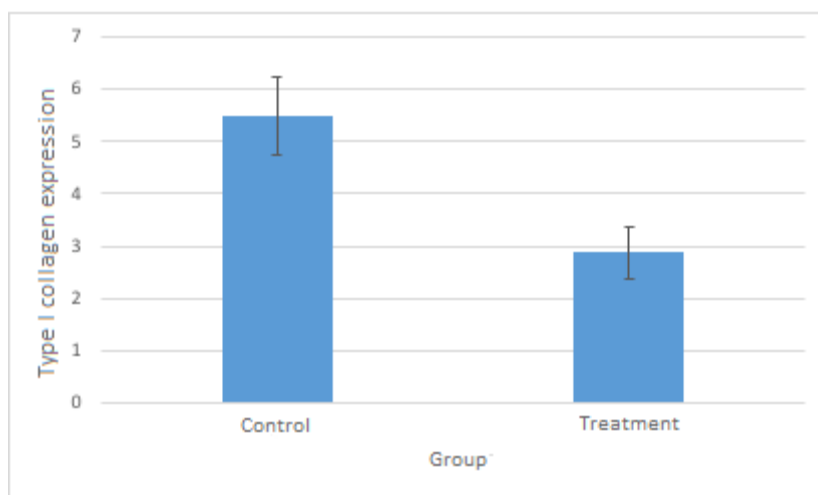


Figure 6: Type I collagen expression bar diagram in the control group and treatment group

DISCUSSION

Failure in glaucoma filtration surgery is caused by fibrosis tissue formation on the excessive bleb formation of sub conjunctival fibrosis tissue in the filtration area, inhibiting new pathways from the aqueous humor (10,20,21). Modulation of wound healing in trabeculectomy surgery aims to prevent and suppress the formation of episcleral scar tissue in the bleb filtration area, but at the same time allows optimal healing of the conjunctival injury. The use of antimetabolites such as Mitomycin-C (MMC) and 5-fluorouracil (5-FU) to prevent episcleral fibrosis has been widely used in recent years, but it can cause many complications (22–24).

Vascular endothelial growth factor (VEGF) is a potent cytokine promoting angiogenesis, increasing vascular permeability, migration of inflammatory cells, and fibroblasts, and having an effect on fibroblast activity. VEGF also plays a role in the formation and modulation of the extracellular matrix. Bevacizumab is an anti-VEGF agent functioning directly to inhibit all VEGF-A molecular isoforms by binding to VEGF receptors, resulting in full inhibition of proangiogenic signals (15,16,22).

The density and thickness of collagen fibers in this study were observed using Masson's Trichrome staining. The density of collagen fibers in the treatment group was lower than that of the control group. The examination of collagen thickness showed that there was no difference between treatment group and control group. This may be due to variation of conjunctival thickness in animal eye preoperatively, where in this study there was no examination of the conjunctival thickness before surgery, especially compared to non-operated fellow eyes. Quantitative histology examination in this study was difficult because the size is very thin (micrometers). Cutting on histological preparations will affect the thickness of the conjunctiva. Different cutting techniques, such as perpendicular or diagonal, can make a difference in the preparation. Thus, the deduction must be done carefully. The results of this study are similar to previous study comparing the use of bevacizumab, MMC 0.02%, and BSS in trabeculectomy surgery. This study showed that the effect of bevacizumab injection on collagen deposition was not significant compared to the control group. The combination of bevacizumab and MMC is proven effective in improving the results of surgery (22).

Another study found a significant difference in collagen deposition between the control group and the group administered with bevacizumab injection. Masson's trichrome staining showed a decrease collagen deposition in group injected by bevacizumab at the filtration area as much as 11% on the 14th day ($p = 0.003$) and 13% on the 30th day ($p = 0.001$). Fibroblasts in tenon capsules appearing during the healing process of trabeculectomy surgery can stimulate the production of collagen, elastin, and mediators, which are important in fibrosis tissue formation (15). Another study revealed the influence of bevacizumab on collagen deposition after trabeculectomy surgery. The study consisted of 4 treatment groups with subconjunctival injection: 5-FU group combined with bevacizumab, 5-FU group (monotherapy), bevacizumab group (monotherapy), and phosphate buffered saline (PBS) group. The histologic examination found the effect of bevacizumab inhibitor on the process of subconjunctival scar tissue formation. The control group or 5-FU monotherapy group showed denser collagen deposition. Meanwhile, the bevacizumab monotherapy group and bevacizumab-5FU combination showed a more loose collagen structure in the subconjunctival area ($p < 0.005$) (25).

Another study reported the effects of bevacizumab on several eye diseases, one of which was to observe the effect of bevacizumab in trabeculectomy surgery. The control group was given with injection of NaCl (0.9%) and the treatment with bevacizumab injection (1, 25 g). The evaluation of collagen was performed using Sirius Red staining. There was a decrease collagen deposition in group given with bevacizumab injection ($n = 31$, 1.2%) compared to the control group ($n = 10$, $p < 0.001$) (26). The present study showed a significant decrease in collagen type I expression in the treatment group compared to the control group. The results of the study are consistent with previous study observing the effect of bevacizumab in expression of type I collagen using real time PCR. This experimental study revealed a significant decrease in type I collagen expression in bevacizumab monotherapy group or bevacizumab-5FU combination compared to the control group or 5-FU monotherapy group ($p < 0.005$) (25). The administration of bevacizumab after trabeculectomy clinically improved bleb survival and reduced conjunctival blood vessels and fibrosis response. VEGF-A is the main mediator responsible in the process of conjunctival fibrosis. Giving bevacizumab as an anti-VEGF agent can reduce the process of angiogenesis and bleb fibrosis after trabeculectomy (26).

The limitations of this study are: 1) Use of Schiötz tonometer to measure IOP before and after surgery, 2) Experimental animals are not animal models of glaucoma, 3) This study did not evaluate bleb morphology completely during study periods, 4) This study did not compare collagen density and thickness as well as type I collagen expression in the proliferation and maturation phases (> 21 days), 5) Difficulties in making histological preparations because of the thinness of the conjunctival tissue; thus, quantitative histology examination must be done carefully, 6) This study did not check VEGF levels in the area of trabeculectomy before or after trabeculectomy surgery, 7) This study also did not compare the effectiveness of bevacizumab combined with antimetabolites, such as Mitomycin-C or 5-FU.

CONCLUSION

This study showed a decrease in collagen density, although it was not significant in collagen thickness. Meanwhile, the expression of type I collagen will show more specific conditions of collagen fibrosis because type I collagen mostly found in conjunctival tissue and type III collagen, which is widely produced in the proliferation phase of the healing

process, will be degraded and replaced by type I collagen. Decreased expression of type I collagen in experimental animals given with bevacizumab injection shows the effect of bevacizumab, indicating a good effect as an antifibrotic agent.

REFERENCES

- Lubis R, Wulandari C. The characteristic of ocular trauma in adulthood patients at adam malik hospital period 2011-2012: A hospital based study. *Int J PharmTech Res.* 2015;8(2):200–3.
- Lubis RR, Limanto V, Putri R, Lubis AN, Arrasyid NK. Epidemiological characteristics of work-related ocular trauma among the carpenters in Medan, Indonesia. *Open Access Maced J Med Sci.* 2018;6(11):2119–22.
- Matsunari O, Miftahussurur M, Shiota S, Suzuki R, Vilaichone R, Uchida T, et al. Rare *Helicobacter pylori* virulence genotypes in Bhutan. *Sci Rep.* 2016;6(1):1–11.
- Miftahussurur M, Sharma RP, Shrestha PK, Suzuki R, Uchida T, Yamaoka Y. Molecular epidemiology of *Helicobacter pylori* infection in Nepal: specific ancestor root. *PLoS One.* 2015;10(7).
- Sari MD, Sihotang AD, Lelo A. Ginkgo biloba extract effect on oxidative stress marker malondialdehyde, redox enzyme glutathione peroxidase, visual field damage, and retinal nerve fiber layer thickness in primary open angle glaucoma. *Int J PharmTech Res.* 2016;9(3):158–66.
- Rayungsista A. Characteristics of Primary Glaucoma in Eye Outpatient Clinic of RA Basoeni Hospital, Mojokerto, Indonesia. *Folia Medica Indones.* 2018;54(3):172–8.
- Kamaruddin MI, Nakamura-Shibasaki M, Mizuno Y, Kiuchi Y. Ocular hypotensive effects of a rho-associated protein kinase inhibitor in rabbits. *Clin Ophthalmol.* 2017;11:591–7.
- Faisal AA, Kamaruddin MI, Toda R, Kiuchi Y. Successful recovery from misdirection syndrome in nanophthalmic eyes by performing an anterior vitrectomy through the anterior chamber. *Int Ophthalmol.* 2019;39(2):347–57.
- Radcliffe NM. Trabeculectomy revision as a treatment for failed trabeculectomy. *Glaucoma Today.* 2010;(Fall):25–8.
- Rumelt HSE-S. Update on Modulating Wound Healing in Trabeculectomy. In *Rijeka: IntechOpen*; 2011. p. Ch. 19. Available from: <https://doi.org/10.5772/23062>
- Cheng J, Cheng S, Wei R, Lu G. Anti-vascular endothelial growth factor for control of wound healing in glaucoma surgery. *Cochrane Database Syst Rev.* 2016;(1).
- Hyung SM, Kim SK. Mid-term effects of trabeculectomy with mitomycin C in neovascular glaucoma patients. *Korean J Ophthalmol.* 2001;15(2):98–106.
- Masoumpour MB, Nowroozzadeh MH, Razeghinejad MR. Current and Future Techniques in Wound Healing Modulation after Glaucoma Filtering Surgeries. *Open Ophthalmol J [Internet].* 2016 Feb 29;10:68–85. Available from: <https://pubmed.ncbi.nlm.nih.gov/27014389>
- Nurwasis N, Yuliawati D, Komaratih E, Heriyawati H. The Effect of Subconjunctival Bevacizumab on Angiogenesis in Rabbit Model. *Folia Medica Indones.* 2019;55(4):290–4.
- Li Z, Van Bergen T, Van de Veire S, Van de Vel I, Moreau H, Dewerchin M, et al. Inhibition of vascular

- endothelial growth factor reduces scar formation after glaucoma filtration surgery. *Invest Ophthalmol Vis Sci*. 2009 Nov;50(11):5217–25.
16. Ozgonul C, Mumcuoglu T, Gunal A. The effect of bevacizumab on wound healing modulation in an experimental trabeculectomy model. *Curr Eye Res*. 2014 May;39(5):451–9.
 17. Martorana GM, Schaefer JL, Levine MA, Lukowski ZL, Min J, Meyers CA, et al. Sequential Therapy with Saratin, Bevacizumab and Ilomastat to Prolong Bleb Function following Glaucoma Filtration Surgery in a Rabbit Model. *PLoS One*. 2015;10(9):e0138054.
 18. Ekinci M, Cagatay HH, Ceylan E, Keles S, Koban Y, Gokce G, et al. Reduction of conjunctival fibrosis after trabeculectomy using topical α -lipoic acid in rabbit eyes. *J Glaucoma*. 2014 Aug;23(6):372–9.
 19. Nowak M, Madej J, Dziegiel P. Intensity of COX2 expression in cells of soft tissue fibrosarcomas in dogs as related to grade of tumour malignancy. *Bull Vet Inst Pulawy*. 2007 Jan 1;51:275–9.
 20. Savino PJ, Danesh-Meyer H V. *Color Atlas and Synopsis of Clinical Ophthalmology--Wills Eye Institute--Neuro-Ophthalmology*. Lippincott Williams & Wilkins; 2012.
 21. Freitas ML, Lisboa JE, Marinho Q, Grieshaber MC. *Adult Glaucoma Surgery*. New Delhi: Jaypee Brothers Medical Publishers (P) Ltd; 2013. 1–7 p.
 22. Liu X, Du L, Li N. The Effects of Bevacizumab in Augmenting Trabeculectomy for Glaucoma: A Systematic Review and Meta-Analysis of Randomized Controlled Trials. *Medicine (Baltimore)*. 2016 Apr;95(15):e3223.
 23. Slabaugh M, Salim S. Use of anti-VEGF agents in glaucoma surgery. *J Ophthalmol*. 2017;2017.
 24. Van Bergen T, Vandewalle E, Moons L, Stalmans I. Complementary effects of bevacizumab and MMC in the improvement of surgical outcome after glaucoma filtration surgery. *Acta Ophthalmol*. 2015 Nov;93(7):667–78.
 25. How A, Chua JLL, Charlton A, Su R, Lim M, Kumar RS, et al. Combined treatment with bevacizumab and 5-fluorouracil attenuates the postoperative scarring response after experimental glaucoma filtration surgery. *Invest Ophthalmol Vis Sci*. 2010;51(2):928–32.
 26. Hollanders K, Van Bergen T, Van de Velde S, Sijnave D, Vandewalle E, Moons L, et al. Bevacizumab revisited: its use in different mouse models of ocular pathologies. *Curr Eye Res*. 2015 May;40(6):611–21.