

THE INDIAN VETERINARY JOURNAL

SINCE - 1924

Journal of
THE INDIAN VETERINARY ASSOCIATION
ESTD - 1922 Regd. No. Sl. No. 96/1967 (CHENNAI)



No. 11, Pasumpon Muthuramalinga Thevar Salai (Chamiers Road),
Nandanam, Chennai - 600 035, Tamil Nadu, India
Tel. : +91 44 2435 1006
Email : ivj83@yahoo.com
ONLINE : www.ivj.org.in

Editorial Committee

Executive Editor	Dr. L. Chandrasekaran M.V.Sc. (LPM) <i>[Vice President, The Indian Veterinary Association; Former Joint Director AHD, Tamil Nadu, India]</i>
Chief Editor	Dr. A.V.Krishnan M.V.Sc. (Path.) <i>[Former Additional Director of AHD, Tamil Nadu, India]</i>
Managing Editor	Dr. S. Sukumar M.V.Sc. (Vet. Micro.), Ph.D. (Animal Biotech) <i>[Former Professor of Biotechnology, TANUVAS, Tamil Nadu, India]</i>
Editor	Dr. I. Ponnu Pandian B.V.Sc. , PGDAEM.
Editor	Dr. A. B. Peter M.V.Sc. (Vet. Micro.), Ph.D. (Animal Biotech) <i>[Former Senior Research Officer, AHD, Tamil Nadu, India]</i>
Editor	Dr. M. Raman M.V.Sc. (Parasitology), Ph.D., Post Doc (UK) <i>[Former Project Director, TRPVB, TANUVAS, Tamil Nadu, India]</i>

Editorial Board

Chairman	Dr. Chirantan Kadian B.V.Sc. & A.H. <i>[President, The Indian Veterinary Association]</i>
Board Member	Dr. K. N. Selvakumar Ph.D. <i>[Vice Chancellor, Tamil Nadu Veterinary and Animal Sciences University (TANUVAS), Tamil Nadu, India]</i>
Board Member	Dr. Praveen Malik M.V.Sc. <i>[Commissioner, Department of Animal Husbandry, Ministry of Fisheries, Dairying & Animal Husbandry (GOI), India]</i>
Board Member	Dr. P. K. Panwar M.V.Sc. <i>[Department of Animal Husbandry, Uttar Pradesh, India]</i>
Board Member	Dr. Subhash Chander Ahlawat B.V.Sc. & A.H. <i>[Department of Animal Husbandry, Haryana, India]</i>

Indian Veterinary Association

To know more about the Indian Veterinary Association, please visit www.indianveterinaryassociation.in

Table Of Contents: *April 2020: 97 (4)*

Clinical and Haemato-Biochemical Characterization of Calf Diarrhoea

S.K.Sharma and Monika Joshi

Evaluation of efficacy of Azithromycin and Neostigmine in the Management of Ileus in Goats

P.A. Ammu, G.Vijayakumar, S.Sivaraman, and S.Kathirvel

Biochemical Parameters of Goats Fed with Wet Distillers Grains with Solubles Replacing Cottonseed Cake

A. B. Waghmare, S. M. Bhalerao, A. V. Khanvilkar, V. R. Patodkar, A. Y. Doiphode and A. K. Barate

Gross Anatomical Studies on the Pelvic Girdle of African Grey Parrot (*Psittacus erithacus*)

O.R.Sathyamoorthy, K.Nagarajan, G.V.Sudhakar Rao and T. Shiarjit Singh

Energy and Protein Requirements of Namakkal Chicken-1

P.Parthipan, M.Moorthy, K.Mani and A.Natrajan

Comparative Study of Feeding Jowar Kadabi and Groundnut Haulms on Nutrient Digestibility of Growing Goats

A.B. Darade, S.M. Bhalerao, A.V. Khanvilkar, V.R. Patodkar, A.Y. Doiphode and A.K. Barate

Long Term Outcome of Perineal Herniorrhaphy in Dogs

Ramandeep Singh, Vandana Sangwan, Ashwani Kumar, Arun Anand, Shashi Kant Mahajan and Navdeep Singh

Drinking Thyme Extract on Growth Performance and Immune Response of Broiler Chickens

Hayder Abd AL-Emier Almremdhy and Muna A. Al-khafaji

Beneficial Effect of Grinting Grass (*Cynodon dactylon*) on the Streptozotocin Induced Diabetes Mellitus in the Mice

Martia Rani Tacharina, Arif Nur Muhammad Ansori, Hani Plumeriastuti, Kusnoto, Rochmah Kurnijasanti and Eka Pramytha Hestianah

Protective Immunity of *Eimeriaacervulina* Oocysts Protein against Intestinal Coccidiosis

Muchammad Yunus, EndangSuprihati and AgusWijaya

Effect of Fructose on Fertility in Fowl Semen

Tatik Hernawati and Erma Safitri

Performance of Commercial Broiler Chicken Fed With Soya Oil Cake

N.S.Sonale, K. Rajendran, M. Moorthy and C. Kathirvelan

Pathology of *Muellerius Capillaris* Infection in Free-Ranging Spotted Deer

K. Gopal, T.Mohanapriya, V.Kumar, R.Thangathurai and N.Pazhanivel

Surgical Management of Cutaneous Compound Melanocytoma in a Pulikulam Bull

R. Uma Rani and N. Pazhanivel

chicks from 7 to 28 days of age. *British Poultry Sci.* **48**:496-504.

Davis, P. H., (1982) Flora of Turkey and the east aegean islands. **7**: 320- 354 pp, Univer-Sity Press, Edinburgh.

Foroughi, A. R., H. M. Torghabeh and H. Salen, (2011) The effect of essential oil of thyme (thyme vulgaris) on performance and humoral immune response broiler chicken. *Agri. J.* **6** (6): 299 – 302.

Hagmuller, W., M. Jugl-Chizzola, K. Zitterl-Eglseer, C. Gabler, J. Spersger, R. Chizzola, and C. Franz, (2006) The use of thyme herbal as feed additive (0.1%, 0.5%, 1.0%) in weanling piglets with assessment of the shedding of haemolysing e. Coli and the detection of thymol in the blood plasma. *Bulgarian J. of Vet. Med.* **119**: 50-54.

Heckert R A, Estevez I, Russek-Cohen E, Pettit- Moraes, R, Salle, C T P Padilha, A P and Riley, V P. (2002) Effects of density and perch availability on the immune status of broilers. *Poult. Sci.* **81**: 451-457.

Hoffman-Pennesi, D. and C. Wu, (2010). The effect of thymol and thyme oil feed supplementation on growth performance, serum antioxidant levels and cecal salmonella population in broilers. *The J. of Applied Poul. Res.* **19** (4): 432 – 443.

Juven BJ, Kanner J, and Schved F.(1994) Factors that interact with the antibacterial action of thyme essential oil and its active constituents. *J. Appl Bacteriol.* **76**:626-631.

Kshash, B. and Oda, H.(2019) Constraints Facing Poultry Producers in Iraq. *J. of Agri. Exten.* **23** (2), 90-100.

Manach F. Regeat F and Texier O. (1996) Bioavailability, metabolism and physiological impact of 4-oxo-flavonoids. *Nutrition Res.* **16**: 517-544.

Masada Y., (1976) Analysis of oils by gas chromatography and mass spectrometry. Johan Wiley and Sons. pp:334.

Rahimi S, Teymouri Zadeh Z, and Karimi Torshizi M.A. (2011) Effect of the three herbal extracts on growth performance, immune system, blood factors and intestinal selected bacterial population in broiler chickens. *J. Agri Sci Tech.* **13**:527-39.

Talazadeh F, and Mayahi M. (2017) Immune response of broiler chickens supplemented with pediatric cough syrup including thyme extract in drinking water against influenza vaccine. *J Herbmec Pharmacol.* **6**(1):33-36.

Teymouri Zadeh Z, Rahimi SH, Karimi Torshizi MA. and Omid-baigi R. (2009) The effects of *Thymus vulgaris* L., *Echinacea purpurea* (L.) Moench, *Allium sativum* L. extracts and virginiamycin antibiotic on intestinal microflora population and immune system in broilers. *Iranian J. of Medicinal and Aromatic Plants.* **25**(1):39-48.

Toghyani, M., M. Tohidi, A. A. Gheisari and S. A. Tabeidian, (2010) Performance, immunity, serum biochemical and hematological parameters in broiler chicks fed dietary thyme as alternative for an antibiotic growth promoter. *Afr. J. Biotech.* **9** (40): 6819-6825.

Indian Vet. J., April 2020, 97 (04) : 35 - 38

Beneficial Effect of Grinting Grass (*Cynodon dactylon*) on the Streptozotocin Induced Diabetes Mellitus in the Mice

Martia Rani Tacharina¹, Arif Nur Muhammad Ansori, Hani Plumeriastuti, Kusnoto, Rochmah Kurnijasanti and Eka Pramyrtha Hestianah

Laboratory of Virology and Immunology, Department of Veterinary Microbiology, Faculty of Veterinary Medicine, Universitas Airlangga, Surabaya, 60115, Indonesia.

(Received : September, 2019 329/19 Accepted : October, 2019)

Abstract

The aim of this study was to investigate antidiabetic activity of the non-polisaccharide fraction of the aqueous extract of grinting grass (NPF-GG) in streptozotocin induced diabetes in mice. Thirty male BALB/C mice of two months age were divided into five groups: placebo control,

metformin control, NPF-GG treated groups (250 mg/kgBW, 500 mg/kgBW, and 1000 mg/kgBW, respectively). Hypoglycemic effect and histopathological features of the pancreatic islet showed that NPF-GG have high antidiabetic effect. It induced hypoglycemic effect and increased the cell quantity in Langerhans cells in the pancreas.

Keyword: antihyperglycemic activity, *Cynodon dactylon*, diabetes mellitus, pancreatic islet.

¹Corresponding author : Email : martia.rt@fkh.unair.ac.id

Table I. Fasting Blood Glucose Level in Diabetic Mice

	Day 6			Day 14
	1h	3h	5h	
Placebo control	260.5 ^b ± 37.26	240.3 ^b ± 40.83	184.2 ^b ± 23.79	150.2 ^c ± 6,57
Metformin control	169.5 ^a ± 36.37	144.3 ^a ± 46.17	109.17 ^a ± 39.51	158 ^{bc} ± 34,37
NPF-GG 250 mg/kg	129.5 ^a ± 26.18	119.17 ^a ± 24.46	85 ^a ± 34,87	100 ^a ± 30,17
NPF-GG 500 mg/kg	116.3 ^a ± 7.71	94.5 ^a ± 19.26	91.5 ^a ± 20,11	115 ^{ab} ± 13,61
NPF-GG 1000 mg/kg	129.2 ^a ± 17.71	115.5 ^a ± 15.61	96.7 ^a ± 6,07	123 ^{ab} ± 16,47

Indonesia has a high level of biodiversity and has many natural potentials that can be utilized for the treatment of various diseases (Wahyuni *et al.*, 2017; Fadholly *et al.*, 2019). Grinting grass (*Cynodon dactylon*) is a stoloniferous grass widely distributed in the tropical and subtropical regions of the world. Currently, grinting grass is listed as invasive in many countries including Indonesia. Grinting grass traditionally used as medication in diabetes but there are not many study to demonstrate the antidiabetic activity of this grass. The aim of this study was to analyze the antidiabetic activity of the NPF-GG in streptozotocin induced diabetes in the mice.

Materials and Methods

This study was approved by the Committee of Animal Care and Use, Faculty of Veterinary Medicine, Universitas Airlangga, Surabaya, Indonesia. Dried powder of grinting grass was heated in the water (25g in 200mL) at 90 °C for 15 minutes. When it was filtrated and ethanol was added to induce precipitation, the sediments (polysaccharide fraction) was removed to obtain non-polysaccharide fraction (NPF) (Jarald *et al.*, 2008). The NPF was evaporated using rotary evaporator then dried using freeze dryer over night. The dried NPF-GG was suspended in 1% Tween 80 just before the administration to mice.

Thirty male BALB/C mice of two months age were used in this study. 40mg/kgBW of streptozotocin were administered intraperitoneally each day for five consecutive days. The mice were divided into five groups: placebo control, metformin control, NPF-GG treated groups (250 mg/kgBW, 500 mg/kgBW, and 1000 mg/kgBW, respectively). The test was conducted for 14 days. Hypoglycemic effect of NPF-GG was deter-

mined on day 6 at the 1st, 3rd, and 5th hours after NPF-GG administration and at day 14. At the end of the experiment, all mice were euthanized by cervical dislocation and the pancreas was collected by abdominal section for analysis of quantity cells in Langerhans islets in the pancreas. Langerhans islet cells were all normal cells in each pale form (Langerhans islets) in the pancreas. Normal cell was described as cell which has no sign of necrosis (pycnosis, karyorrhexis, and karyolysis) and also has no sign for cell degeneration. There were three histopathological sections of pancreas on a slide of each sample. The cells counted in all Langerhans islets and the total number of Langerhans islet cells was the average of the total cells in one Langerhans islet. The data were analyzed using one-way ANOVA and followed by Duncan post hoc test.

Results and Discussion

Streptozotocin enters the pancreatic beta cells through glucose transporter-2 (GLUT-2) and cause DNA alkylation. DNA alkylation or the entry of methyl groups from streptozotocin into the DNA molecules caused damage that lead to DNA fragmentation. Streptozotocin acts directly on the pancreatic beta cells by cytotoxic action mediated by reactive oxygen species (ROS). Nitric oxide (NO) donor binds to superoxide (O⁻) to produce peroxynitrite radicals that can be used as diabetes mellitus induction material (Szkudelski, 2001). The diabetic mice were found to have fasting blood glucose level higher than 160 mg/dL on the day 5 after the last injection of streptozotocin.

In the diabetic mice after several hours evaluation we found that NPF-GG has antihyperglycemic effect at all dose levels 250 mg/

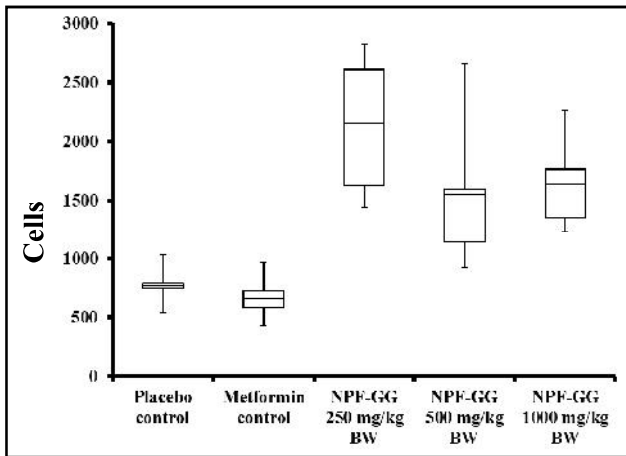


Fig 1. Total number of pancreatic islet cells in the diabetic mice

kg BW, 500 mg/kg BW, and 1000 mg/kg BW, respectively. It was found to be more effective than both placebo control group and metformin control group (Table I).

The data from Langerhans pancreatic islet in the Figure 1 and 2 showed that the cell quantity of each group is 776.17 ± 156.68 cells for placebo control group and 671.17 ± 184.34 cells for metformin control group, 2133.33 ± 598.04 cells, 1551 ± 622.63 cells, and 1643.33 ± 377.59 cells for NPF-GG 250, 500, 1000 mg/kg BW, respectively. The results indicated that NPF-GG increased the total number of Langerhans pancreatic islets also.

NPF-GG contains several chemical constituents such as flavonoids, saponins, tannins, and glycosides. In the previous study, the isoliquiritigenin, protocatechualdehyde, and butein in flavonoid components are effective to preserve the integrity of the beta cells from streptozotocin exposure (Lukačínová *et al.*, 2008). Quercetin of flavonoid compounds acts as an antioxidant that prevent the cells in the pancreatic islet from oxidative stress. This theory might explain the protective activity of NPF-GG that inhibits the binding of streptozotocin NO donor to O₂. Quercetin might increase insulin secretion by the pancreas and might also increase the glucokinase activity causing increase in the uptake of glucose in a liver. Furthermore, quercetin was found to inhibit maltase enzyme that lowers glucose absorption in the intestines (Husen *et al.*, 2019). Other flavonoid compounds

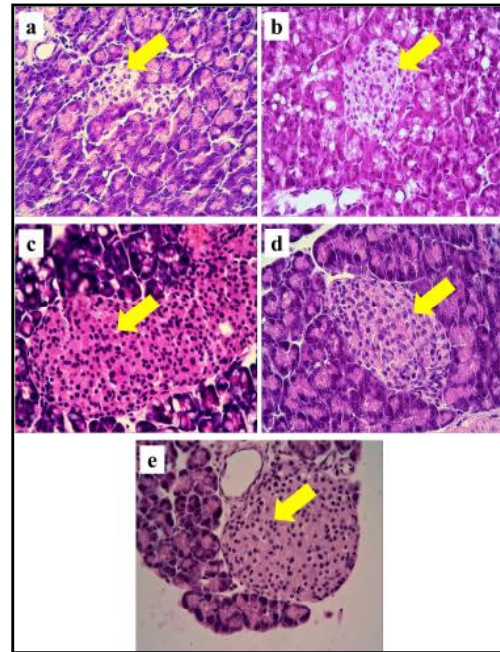


Fig 2. Histopathological features of pancreatic islets in the diabetic mice. a) A group of placebo control, b) A group of metformin control, c) A group of NPF-GG 250 mg/kg BW, d) A group of NPF-GG 500 mg/kg BW, and e) A group of NPF-GG 1000 mg/kg BW. Hematoxylin-eosin staining, 400x magnification

have an acarbose like-effect and inhibits the glucose absorption in the intestines (Giordani *et al.*, 2015).

Summary

The NPF-GG has high antidiabetic effect and hypoglycemic effect and increases the number of Langerhans pancreatic islet. NPF-GG was found to be more effective than metformin which is a standard antidiabetic drug.

Acknowledgment

This work was supported by the Ministry of Research, Technology, and Higher Education of the Republic of Indonesia.

References

- Fadholly, A., Ansori, A.N.M., Jayanti, S., Proboningrat, A., Kusala, M.K.J., Putri, N., Rantam, F.A., Sudjarwo, S.A. (2019) Cytotoxic effect of *Allium cepa* L. extract on human colon cancer (WiDr) cells: *in vitro* study. *Research J Pharm and Tech*. **12(7)**: 3483-3486.
- Giordani, M.A., Collicchio, T.C.M., Ascêncio, S.D., De Oliveira Martins, D.T., Balogun, S.O., Bieski, I.G.C., Da Silva, L.A., Colodel, E.M., De Souza, R.L., De Souza, D.L.P., De França,

S.A., Andrade, C.M.B., Kawashita, N.H. (2015) Hydroethanolic extract of the inner stem bark of *Cedrela odorata* has low toxicity and reduces hyperglycemia induced by an overload of sucrose and glucose. *J Ethnopharmacol.* **162**: 352–361.

Husen, S.A., Wahyuningsih, S.P.A., Ansori, A.N.M., Hayaza, S., Susilo, R.J.K., Winarni, D., Punnapayak, H., Darmanto, W. (2019) Therapeutic effect of okra (*Abelmoschus esculentus* Moench) pods extract on streptozotocin-induced type-2 diabetic mice. *Research J Pharm and Tech.* **12(8)**: 3703-3708.

Jarald, E.E., Joshi, S.B., Jain, D.C. (2008) Antidiabetic activity of aqueous extract and non polysaccharide fraction of *Cynodon dactylon* Pers. *Indian J Exp Biol.* **46**: 660-667.

Luka ínová, A., Mojžiš, J., Be a ka, R., Keller, J., Maguth, T., Kurila, P., Vaško, L. (2008) Preventive effects of flavonoids on alloxan-induced diabetes mellitus in rats. *Acta Vet Brno.* **77**: 175-182.

Szkudelski, T. (2001) The mechanism of alloxan and streptozotocin action in B cells of the rat pancreas. *Physiol Res.* **50(6)**: 537-546.

Wahyuni, D.K., Ansori, A.N.M., Vidiyanti, F. (2017) GC-MS analysis of phytochemicals in methanolic extracts of leaf-derived callus of *Justicia gendarussa* Burm.f. *Biosci Res.* **14(3)**: 668-677.

Indian Vet. J., April 2020, 97 (04) : 38 - 40

Antibacterial Activity of *Annona muricata* Linn ethanolic Extraction Against *Pseudomonas aeruginosa* in vitro

Faisal Fikri¹, Imas Hapsari Rahmaningtyas and Muhammad Thohawi Elziyad Purnama

Department of Veterinary Physiology, Pharmacology and Anatomy, Faculty of Veterinary Medicine, Universitas Airlangga, Surabaya 60115, Indonesia.

(Received : October, 2019 358/19 Accepted : January, 2020)

Abstract

This study aimed to measure antibacterial activity of *Annona muricata* Linn ethanolic extract on inhibition of *Pseudomonas aeruginosa* by diffuse disc method. The result of the inhibition zone was analyzed using contrast orthogonal Anova ($p < 0.01$). The inhibition number of negative control (C-) was $0.00^e \pm 0.00$ and the positive control (C+) was $31.31^a \pm 0.57$. The result of treatment groups (T1; T2; T3; T4; T5; T6; T7; T8; T9; T10 and T11) were ($14.49^b \pm 4.96$; $8.98^c \pm 1.29$; $5.84^{cd} \pm 1.85$; $5.56^{cd} \pm 1.58$; $2.85^{de} \pm 0.28$; $2.98^{de} \pm 0.53$; $2.82^{de} \pm 1.59$; $2.41^{de} \pm 1.10$; $2.20^{de} \pm 0.34$; $1.10^e \pm 0.19$ and $0.00^e \pm 0.00$). It was concluded that *A. muricata* Linn ethanolic extract inhibits *P. aeruginosa* with Minimal Inhibitory Concentration (MIC) of 125 ppm.

Key words: Antibacterial activity, *Annona muricata* Linn, *Pseudomonas aeruginosa*

Pseudomonas sp. infections were found in 4 out of 20 horses with pneumonia (Yuriadi, 2003). *P. aeruginosa* is also one of the causes

of respiratory tract infections in dogs with a percentage of 27.7% (Warastri, 2007). *Annona muricata* Linn extract can inhibit the growth of Gram-negative bacteria. In addition, it contains wide variety of secondary metabolites including alkaloids, saponins, flavonoids, steroids and tannins (Solomon-Wisdom *et al.*, 2014; Ningsih *et al.*, 2016). The study was designed to assess the anti bacterial properties and also as a herbal medicine for animals.

Materials and Methods

About 800 grams of the dried *A. muricata* Linn leaves powder were added into 2500 mL of ethanol and kept for three days. The final extraction process was concentrating ethanol extract using a rotary evaporator at a temperature at 89°C. The concentration of extracts at various dilutions of 1000, 500, 250, 125, 65, 30, 15, 10, 5, 1, and 0.5 ppm were prepared with CMC 0.5%. Furthermore, the paper disks were soaked for 30 minutes until it became saturated (Ningsih *et al.*, *loc cit*). The isolate *P. aeruginosa* turbidity was similar to the 0.5 McFarland standard

¹Corresponding author : Email : faisalfikriunair@gmail.com