

# Anti-Inflammatory Effect of Okra (*Abelmoschus esculentus*) Fruit Extract during Wound Healing Process after Tooth Extraction of Diabetic Wistar Rat

*by Agung Sosiawan*

---

**Submission date:** 15-Feb-2021 10:48AM (UTC+0800)

**Submission ID:** 1509606991

**File name:** 10\_18-D20\_1030\_Muhammad\_Luthfi\_Indonesia.pdf (386.33K)

**Word count:** 4289

**Character count:** 23244

## Anti-Inflammatory Effect of Okra (*Abelmoschus esculentus*) Fruit Extract during Wound Healing Process after Tooth Extraction of Diabetic Wistar Rat

Muhammad Luthfi<sup>1\*</sup>, Tuti Kusumaningsih<sup>1</sup>, Agung Sosiawan<sup>2</sup>, Hasna Sabrina<sup>2</sup>

1. Department of Oral Biology, Faculty of Dental Medicine, Universitas Airlangga, Surabaya, Indonesia.
2. Department of Public Health, Faculty of Dental Medicine, Universitas Airlangga, Surabaya, Indonesia.
3. Undergraduate Student, Faculty of Dental Medicine, Universitas Airlangga, Surabaya, Indonesia.

### Abstract

To analyze the anti-inflammatory properties of okra fruit extract and its effect toward wound healing process in diabetic mellitus rats.

27 Wistar rats were divided into three groups: (1) negative control (K-), (2) positive control (K+) and (3) streptozotocin induction and 250 mg/kg body weight okra fruit extract (P). Three rats from each group were sacrificed on the 1st, 4th, and 7th days after extraction of their left lower incisor and excised for histologic examination by Hematoxylin Eosin (HE) staining to enable evaluation of the neutrophil expressions.

The administration of okra extract to the tooth extraction wounds significantly reduced neutrophil expression compared to that in the untreated group. There was a significant difference on day 1 between the following groups: (1) K- and K+ and (2) K+ and P. On day 4, the most significant difference was between K- and P. On day 7, the most significant difference was between K- and K+ group, K+ and P group.

Okra fruit extract exhibits anti-inflammatory activity and is, therefore, an effective agent for healing process of tooth extraction wounds in diabetic mellitus rats.

**Experimental article (J Int Dent Med Res 2020; 13(2): 497-502)**

**Keywords:** *Abelmoschus esculentus*, diabetes mellitus neutrophils, wound healing.

**Received date:** 18 October 2019

**Accept date:** 26 January 2020

### Introduction

Diabetes Mellitus (DM) is a condition characterized by chronic hyperglycemia due to impaired metabolism of carbohydrates, fats and proteins. DM can occur due to various (multifactorial) reasons or to the pathophysiology process.<sup>1</sup> Chronic hyperglycemia in DM can be associated with long-term damage to body tissues, including blood vessels. Long-term damage to these can result in slower wound healin.<sup>2</sup>

Wound healing, in fact, constitutes a complex and dynamic series of processes whose purpose is to replace damaged cell structures and tissues.<sup>3</sup> Effective healing occurs if the regeneration and integrity of functional tissue is achieved through the activation and infiltration of

inflammatory cells such as neutrophils and macrophages which produce pro-inflammatory cytokines including: tumor necrosis factor-alpha (TNF- $\alpha$ ) and interleukin-1 (IL-1).<sup>4</sup> The acute inflammatory phase occurs between the first 24 hours and the third day, a period marked by the presence of cellular activity, namely; the movement of neutrophils from blood vessels to the wound site, their increase between 24 and 48 hours and subsequent decrease after the third day.<sup>5</sup>

The inflammatory response begins when leukocyte infiltrates tissues, especially if neutrophils present in the blood vessels penetrate the wound area. Neutrophils constitute the most abundant cells there for the first two days after injury.<sup>6</sup> The chemokines function mainly to attract neutrophils and lymphocytes and participate in regulating the initial wound healing phase. After neutrophils have migrated to the injured area, monocytes will follow suit. Monocytes will differentiate into macrophages that play a significant role in the inflammatory, proliferation and rehabilitation phases of the wound healing process.<sup>7</sup>

#### \*Corresponding author:

Muhammad Luthfi,  
Department of Oral Biology,  
Faculty of Dental Medicine, Universitas Airlangga, Jl. Mayjen  
Professor Doktor Moestopo No. 47, Surabaya, Indonesia.  
E-mail: m.luthfi@fkg.unair.ac.id

Neutrophils are inflammatory cells released immediately after injury which provoke an immune response by producing proteolytic enzymes to digest foreign particles and destroy bacteria. Although neutrophils have a role in preventing infection, the presence of persistent neutrophils in the wound will result in impaired healing and the development of chronic wounds.<sup>8</sup>

At present, alternative medicine using natural ingredients is widely resorted to because it is more economical with limited undesirable side effects. One plant suitable as an alternative treatment is okra fruit extract (*Abelmoschus esculentus*) due to its numerous beneficial characteristics including: antidiabetic, antioxidant, antibacterial and anti-inflammatory.<sup>9</sup> According to Shah and Seth, a dose of 250 mg / kg body weight okra fruit extract produces an encouraging anti-inflammatory effect.<sup>10</sup> Okra fruit extract inhibits alpha-glucosidase enzyme which impedes glucose absorption in the intestine and lowers blood glucose levels.<sup>11</sup> The active ingredients contained in okra extract include: saponins, tannins, flavonoids and alkaloids.<sup>12</sup> In previous research conducted by Sathish et al., flavonoids were shown to produce anti-inflammatory effects<sup>13</sup> by inhibiting cyclooxygenase and lipooxygenase enzymes in arachidonic acid metabolism.<sup>14</sup> Flavonoids can modulate oxidative bursts in neutrophils resulting in a decrease in ROS, thereby accelerating wound healing.<sup>15</sup> saponins, tannins, alkaloids, triterpenoids, flavonoids, phenolics, steroids, and glycosides from herbal plants is potentially effective as a wound healing agent that stimulates fibroblast cell proliferation.<sup>16</sup> Based on these facts, researchers resolved to analyze the anti-inflammatory effect of okra fruit extract on the healing of tooth extraction wounds of diabetic mellitus rats.

## Materials and methods

### Preparation of wistar rats

Samples of 27 2-3 month-old, male, Wistar rats, weighing 100-150 grams were provided with *ad libitum* standard pellets and distilled water for one week. These subjects were divided into three groups, namely: a negative control group (K-), a positive control group (K+) and a treatment group (n = 9). The K- group was neither *Streptozotocin*-induced nor administered with okra fruit extract, the K+ group was

*Streptozotocin*-induced, but not given okra fruit extract, while the P group was induced with *Streptozotocin* and okra fruit extract.

### Plant material and preparation of extract

Fresh okra fruit was identified at the Integrated Service Unit of Materia Medica, Batu, East Java before being cleaned and mashed using a blender. 70% ethanol solvent was subsequently introduced into the jar which was tightly sealed for 24 hours and agitated in a digital shaker (Orbital Shaker OS-100, Guangdong, China) at a speed of 50 rpm. The liquid extract was then passed through a filter before being stored in an erlenmeyer flask. The results of the liquid extraction process were evaporated using a rotary evaporator (Rotavapor® R-100, Banten, Indonesia) for 90 minutes. The resulting extract was evaporated in a waterbath (WNB14, German) for two hours. Thereafter, the liquid extract produced was stored in a container. The basic use of ethanol solvents is due to the results of the study showed that the ethanolic extract of Moringa leaves helps to accelerate the wound healing on the rat's palate.<sup>17</sup>

### *Streptozotocin* preparation

*Streptozotocin* (STZ) (Bioworld, Batam, Indonesia) was administered at a dose of 50 mg / kg BW to rats by dissolving STZ powder in a 0.05 M citrate buffer solution of 4.3-4.5 pH which had been made with STZ concentration of 22.5 mg / ml in citrate.<sup>18</sup>

### Experimental treatment

In both the positive control and treatment groups, STZ was induced by means of one intraperitoneal injection. On the fourth day after STZ induction, the blood glucose levels of the Wistar rats were calculated by extracting blood from their lateral veins and measuring it by glucometer (Accu-Chek, Basel, Switzerland). Wistar rats are considered to be diabetic when their blood glucose level reach  $\geq 200$  mg / dl.<sup>18</sup>

All groups were then given anesthesia by means of peritoneal injection of 0.1 ml of ketamine per subject. After 1-1.5 hours, the lower left incisor of each subject was extracted, and the tooth socket irrigated using saline solution.<sup>19</sup> After extraction, the K- and K+ groups were denied okra fruit extract, while the P group was given a 250 mg / kg dose of the extract orally using a gastric tube as much as 1 ml once a day until all subjects had been sacrificed.

Three Wistar rats from each group were sacrificed on the 1st, 4th and 7th day after tooth extraction by intraperitoneal ketamine injection of a lethal dose (at least four times the anesthetic dose or approximately 0.4 ml / kg body weight). The gingival around the incisor tooth socket was subsequently excised and placed in fixation solution.<sup>20</sup> The sacrificed rats were then buried.

Two millimeters of gingival mucosa around the socket was excised for histologic examination by Hematoxylin Eosin (HE) staining. Histopathological observation was performed by counting the number of neutrophil cells under a light microscope at 400x magnification.

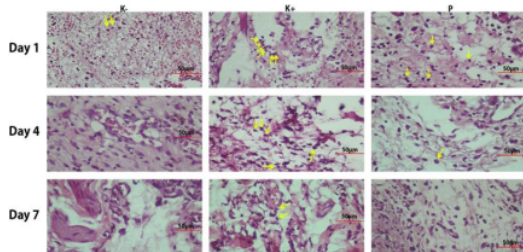
#### Statistical analysis

A statistical analysis was performed on the data obtained by means of Kolmogorov-Smirnov and Levene tests. Data normally distributed, although not homogeneous, was identified by means of a Kruskal-Wallis test. For that data containing significant differences, the analysis was further conducted by a Mann-Whitney test.

#### Results

It was found that neutrophil expression on the gingival mucosal surface identified by Hematoxylin eosin (HE) staining was as follows:

The results from observation of neutrophil cells using a light microscope at 400x magnification can be seen in Figure 1., Table 1 Day 4 shows a decrease in the number of neutrophil cells in the treatment group compared to the positive control group.



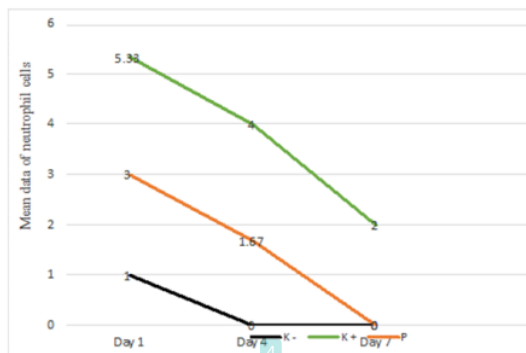
**Figure 1.** Neutrophil cells in the mandibular left incisor socket wound on day 1, 4, and 7. (a) K-group. (b) K+ group. (c) P group. The yellow arrow indicates the neutrophil cells. Day 1 shows a decrease in the number of neutrophil cells in the treatment group compared to the positive control group, although it was not less than the negative control group.

K+ group				P group			
Time	Day 1	Day 4	Day 7	Time	Day 1	Day 4	Day 7
Day 1		0.105	0.046*	Day 1		0.178	0.037*
Day 2			0.077	Day 2			0.034*
Day 3				Day 3			

**Table 1.** Results of Mann-Whitney Test: K + and P group.

\* = significant differences ( $p < 0,05$ )

In contrast, neutrophil cells were absent from the negative control group. Day 7 shows a decrease in the number of neutrophil cells in the treatment group compared to the positive control group. Neutrophil cells were not found in the treatment group; neither were they present in the negative control group. Those results showed fewer neutrophil cells in the treatment group than the positive control group, but not fewer than the negative control group. A diagram of the average number of neutrophil cells can be seen in Figure 2.



**Figure 2.** The diagram of the average number of neutrophil cells in groups K-, K+, and P.

The normality test was conducted in the form of a Kolmogorov-Smirnov test. In this study, all groups showed normal data distribution except for the K- group day 4, K- group day 7, and P group day 7. Those results did not show normal data distribution since the mean data was 0 (zero). A Kruskal-Wallis test was carried out to compare the mean value of cell numbers between groups. If there were significant differences (indicated by  $p < \alpha = 0.05$ ), a Mann-Whitney test was executed. The results of the Kruskal-Wallis statistical test confirmed that the K- group did not show significant differences between days 1, 4 and 7 ( $p = 0.105$ ), whereas the K + group ( $p = 0.042$ ) and P ( $p = 0.038$ ) showed a significant difference.

The results showed the lack of significant difference between days 1, 4 and 7 in the negative control group ( $p = 0.105$ ). The positive control group showed significant differences ( $p = 0.042$ ), while the most significant difference ( $p = 0.038$ ) was that of the treatment group. The most significant difference in the positive control group was between day 1 and day 7, while in the treatment group the most significant differences occurred between day 4 and day 7.

## Discussion

The aim of this study was to analyze the anti-inflammatory effect of okra fruit extract on the wound healing process of post extraction socket in subjects with DM through the expression of neutrophil cells. The results of this study indicate that the administration of okra fruit extract can reduce the number of neutrophil cells within the healing process of extraction wound sockets in diabetic mellitus rats. The number of neutrophil cells in the P group was less than that in the K+ group, although greater than in the K-group. Neutrophil cells were not found in the K-group on the 4th and 7th days. This is in accordance with the short life span of neutrophils, namely, the first 24-48 hours after injury before decreasing after the 3rd day.<sup>5</sup>

The average number of neutrophils in the K + group was the highest because STZ-induced DM rats experienced an interrupted wound healing process. STZ induction is intended to induce DM in the animal model, characterized by hyperglycemia. STZ is a diabetogenic material widely used in research.<sup>21</sup> Damage of pancreatic beta cells caused by STZ induction depends on the dose and type of treatment provided to the subject. In this study, a low, non-toxic (to Wistar rats) dose of 50 mg / kg body weight was injected intraperitoneally and STZ was able to affect blood glucose through three mechanisms, including: 1) absence of the first stage of insulin response. Insulin secretion is delayed, failing to restore a surge of prandial blood sugar in normal time, 2) decreased insulin sensitivity in response to the amount of glucose causes hyperglycemia, and 3) failure to stimulate a realistic insulin response.<sup>22</sup>

The cytotoxicity of STZ causes the release of free radicals which trigger intracellular oxidative stress.<sup>21</sup> This is related to the inhibition of the wound healing process in Wistar rats with

DM. The obstruction of the wound healing process in DM is one of the conditions that can complicate the healing of lesions. The function of inflammatory cells changes under DM conditions, one of which is neutrophils. Under DM conditions, it is known that high blood sugar levels will induce protracted hyperglycemic conditions so that Advance Glycation End (AGE) product is formed. AGE affects the migration and phagocytosis of neutrophils so that they become persistent. Persistent neutrophils is capable of increasing pro-inflammatory cytokines, such as IL-1 $\beta$ , IL-8, and TNF- $\alpha$ . Excessive production of cytokines causes the number of neutrophils to remain high and result in inappropriate activation causing tissue damage.<sup>24,25</sup> Neutrophils experience an extended life span the duration of which is normally 2-3 days after injury. However, in this study with DM conditions, neutrophils persisted until the 7th day after injury. If neutrophil apoptosis is delayed, neutrophils will continue to secrete matrix metalloproteinase-8 (MMP-8) and reactive oxygen species (ROS) which triggers more protracted tissue damage.<sup>26,27</sup>

In P group, the mean number of neutrophil cells was lower than that of the K+ group because of the per oral okra fruit extract. Oral administration represents the most common method but takes longer to reach the wound site. The extract passes through the digestive tract, thereby not directly reaching the target receptor. In the study conducted by Tamara et al. regarding differences between oral and topical drug administration in cases of Wistar tooth extraction wounds, it can be concluded that oral administration of an effective dose is more supportive of the extract reaching the target receptor.<sup>28</sup> This is related to the theory that the effectiveness of the drug is influenced by the dose, the method of administration and half-life, the time that the body requires to eliminate drugs until there is an effective dose remaining.<sup>29</sup> The current dose being used in this study (250 mg/kg body weight) can effectively reduce the number of neutrophil cells so that the wound healing process can be accelerated. In addition, oral administration is also intended to stabilize the systemic state of Wistar rats, STZ-induced group (K + and P) experience decreased activity and weight loss. When given topically it only induces local effects, leading to concerns that the systemic conditions of the Wistar rats cannot be

managed effectively.

Efforts that can be made to accelerate wound healing in DM rats are blood glucose control.<sup>30</sup> Okra fruit extract can be used as an alternative treatment to control blood glucose with its potential as an anti-diabetic treatment. The isoquersetin and quersetin-3-O-glucopyranosyl-glucoside content in okra fruit extracts can reduce blood glucose levels by acting as an  $\alpha$ -glucosidase inhibitor. If the action of the  $\alpha$ -glucosidase enzyme is inhibited, the blood glucose level can be restored to normal limits thereby promoting the wound healing process.<sup>11</sup> The difference between the K + and P groups, due to the administration of okra fruit extract, function as an anti-inflammatory agent with the presence of flavonoids, those flavonoids can inhibit inflammation by inhibiting the cyclooxygenase enzyme and lipooxygenase enzyme in arachidonic acid metabolism. After the cyclooxygenase pathway is inhibited, prostaglandin and leukotrin in the lipooxygenase pathway, will also be inhibited. In the presence of inflammation, those prostaglandins with the most important role are: prostocycline (PGI<sub>2</sub>), PGD<sub>2</sub>, PGE<sub>2</sub> and PGF<sub>2</sub> which can act as a vasodilator. This vasodilation of veins and arteries results in increased blood flow and enhanced vascular permeability that will transports blood cells to areas of infection or trauma. White blood cells then attach to the endothelial wall of the blood vessels using adhesion molecules and migrate to the inflamed tissue.<sup>31,32</sup>

In this study, oxidative stress due to STZ administration can be neutralized by flavonoids contained in okra fruit extract which can act as antioxidants indirectly supporting their anti-inflammatory effects. Flavonoids can stabilize ROS by reacting with reactive compounds from radicals, therefore those radicals become inactive. Flavonoids can inhibit neutrophil degranulation, thereby directly reducing the release of arachidonic acid by neutrophils that decrease immunity response.<sup>33</sup>

Tooth extraction represents a minor surgical procedure involving both the hard and soft tissue of the oral cavity. The study sample was taken from the soft tissue (gingiva) of extraction wounds. After further histology examination, it was found that there was only a small number of neutrophils, indicating, in turn, mild inflammation of the gingiva. The possibility of mild gingival damage is related to the

expertise of the operator and his/her ability to perform tooth extraction effectively. This is in accordance with the findings of Rakhshan on factors that can affect the degree of trauma caused by tooth extraction, one of which is that of the operator.<sup>34</sup> Operators play an important role because they must have the appropriate techniques and predict the amount of power that should be used when extracting teeth to cause minimal trauma to the tissue.

## Conclusions

Okra fruit extract exhibits anti-inflammatory activity and is, therefore, an effective agent in the healing process in tooth extraction wounds of diabetic mellitus rats.

## Declaration of Interest

The authors declare that this study did not receive any financial support.

## Ethical Approval

This study was approved by the Health Research Ethical Clearance Commission (HRECC) with certificate number 176/HRECC.FODM/IX/2017.

## References

1. Zimmet P, Alberti KG, Magliano DJ, Bennett PH. Diabetes mellitus statistics on prevalence and mortality: facts and fallacies. *Nat Rev Endocrinol* 2016;12:616–22. doi:10.1038/nrendo.2016.105.
2. Ben-Chioma A, Tamuno-Emine D, Dan D. The Effect of *Abelmoschus esculentus* in Alloxan-Induced Diabetic Wistar Rat. *Int J Sci Res* 2013;4:540–3.
3. Yolanda M-M, Maria A-V, Amaia F-G, Marcos P-B, Silvia PL, Dolores E, et al. Adult Stem Cell Therapy in Chronic Wound Healing. *J Stem Cell Res Ther* 2014;4:162. doi:10.4172/2157-7633.1000162.
4. Portou MJ, Baker D, Abraham D, Tsui J. The innate immune system, toll-like receptors and dermal wound healing: A review. *Vascul Pharmacol* 2015;71:31–6. doi:10.1016/j.vph.2015.02.007.
5. Mantovani A, Cassatella MA, Costantini C, Jaillon S. Neutrophils in the activation and regulation of innate and adaptive immunity. *Nat Publ Gr* 2011;11. doi:10.1038/nri3024.
6. Eming SA, Martin P, Tomic-Canic M. Wound repair and regeneration: Mechanisms, signaling, and translation. *Sci Transl Med* 2014;6:265sr6. doi:10.1126/scitranslmed.3009337.
7. Wang N, Liang H, Zen K. Molecular Mechanisms That Influence the Macrophage M1-M2 Polarization Balance. *Front Immunol* 2014;5:614. doi:10.3389/fimmu.2014.00614.
8. Webster J, Scuffham P, Stankiewicz M, Chaboyer WP. Negative pressure wound therapy for skin grafts and surgical wounds healing by primary intention. *Cochrane Database Syst Rev* 2014. doi:10.1002/14651858.CD009261.pub3.

9. Xia F, Zhong Y, Li M, Chang Q, Liao Y, Liu X, et al. Antioxidant and Anti-Fatigue Constituents of Okra. *Nutrients* 2015;7:8846–58. doi:10.3390/nu7105435.
10. Shah BN, Seth AK. Anti-inflammatory activity of fruits of *Abelmoschus esculentus* Linn. *Pharmacol* 2010;1:208–12.
11. Thanakosai W, Phuwapraisirisan P. First identification of  $\alpha$ -glucosidase inhibitors from okra (*Abelmoschus esculentus*) seeds. *Nat Prod Commun* 2013;8:1085–8.
12. [Bello H, Mustapha A, Isa M, Rahila T. THE INVITRO ANTIBACTERIAL ACTIVITY OF OKRA (*Abelmoschus esculentus*) AGAINST SOME SELECTED BACTERIA FROM MAIDUGURI, NORTH EASTERN NIGERIA. *Int J Biosci Nanosci* 2015;2:84–8.
13. Sathish Kumar D, Eswar Tony D, Praveen Kumar A, Ashok Kumar K, Bramha Srinivasa Rao D, Nadendra R. A review on: *Abelmoschus esculentus* (okra). *Int Res J Pharm App Sci* 2013;3:129–32.
14. [Naim Z, Billah MM, Ibrahim M, Debnath D, Masud Rana S, Arefin P, et al. Anti-Inflammatory, Analgesic and Anti-Nociceptive Efficacy of Peel of *Abelmoschus esculentus* Fruits in Laboratory Animal. *Curr Drug Ther* 2015;10:113–21. doi:10.2174/15748851002151222161409.
15. Ciz M, Denev P, Kratchanova M, Vasicek O, Ambrozova G, Lojek A. Flavonoids inhibit the respiratory burst of neutrophils in mammals. *Oxid Med Cell Longev* 2012;2012:181295. doi:10.1155/2012/181295.
16. Sugiaman VK., Pranata N, Kintawati S., Maskoen AM, Rezano A. 2019. Oral Mucosa Wound Healing Activities of Aloe vera Extract: in vivo Study. *Journal of International Dental and Medical Research.*, 11;3; 878-83
17. Hanafiah OA, Abidin T, Ilyas S. 2018. Wound Healing Activity of Binahong (*Anredera cordifolia* (Ten.) Steenis) Leaves Extract towards NIH-3T3 Fibroblast Cells. *Journal of International Dental and Medical Research.* 12;(3):854-58
18. [Barbalho SM, Damasceno DC, Spada APM, Lima IE dos RN, Araújo AC, Guiguer EL, et al. Effects of *Passiflora edulis* on the Metabolic Profile of Diabetic Wistar Rat Offspring. *J Med Food* 2011;14:1490–5. doi:10.1089/jmf.2010.0318.
19. Azmi N F, Mulawarmanti D, Prameswari N. Efektifitas perbandingan kombinasi clindamycin dan ekstrak *Nannochloropsis oculata* terhadap peningkatan kepadatan kolagen pada osteomielitis mandibula. *Dent J Kedokt Gigi* 2015;9:64–73.
20. Dag A, Firat ET, Uysal E, Ketani S, Ketani MA. Histological investigation of the impact of streptozotocin-induced experimental diabetes on the healthy gingivae of rats. *Biotechnol Biotechnol Equip* 2014;28:710–5. doi:10.1080/13102818.2014.943558.
21. Li R, Qiu S, Tian H, Zhou S. [Diabetes induced by multiple low doses of STZ can be spontaneously recovered in adult mice]. *Dongwuxue Yanjiu* 2013;34:238–43.
22. Firdaus F, Rimbawan R, Marliyati SA, Roosita K. Model tikus diabetes yang diinduksi streptozotocin-sukrosa untuk pendekatan penelitian diabetes melitus gestasional. *Media Kesehat Masy Indones* 2016;12:29–34. doi:10.30597/MKMI.V12I1.550.
23. [Aboonabi A, Rahmat A, Othman F. Antioxidant effect of pomegranate against streptozotocin-nicotinamide generated oxidative stress induced diabetic rats. *Toxicol Reports* 2014;1:915–22. doi:10.1016/J.TOXREP.2014.10.022.
24. Hanses F, Park S, Rich J, Lee JC. Reduced Neutrophil Apoptosis in Diabetic Mice during Staphylococcal Infection Leads to Prolonged Tnf $\alpha$  Production and Reduced Neutrophil Clearance. *PLoS One* 2011;6:e23633. doi:10.1371/journal.pone.0023633.
25. Hatanaka E, Monteagudo PT, Marrocos MSM, Campa A. Neutrophils and monocytes as potentially important sources of proinflammatory cytokines in diabetes. *Clin Exp Immunol* 2006;146:443–7. doi:10.1111/j.1365-2249.2006.03229.x.
26. Preshaw PM, Alba AL, Herrera D, Jepsen S, Konstantinidis A, Makrilakis K, et al. Periodontitis and diabetes: a two-way relationship. *Diabetologia* 2012;55:21–31. doi:10.1007/s00125-011-2342-y.
27. Akhila S, Malaiappan S. Periodontitis and Diabetes-A Two Way Connection. *IOSR J Dent Med Sci Ver IV* 2014;13:58–61.
28. [26] Jannah Tamara AH, Rochmah YS, Mujayanto R. Pengaruh aplikasi virgin coconut oil terhadap peningkatan jumlah fibroblas pada luka pasca pencabutan gigi pada *Rattus norvegicus*. *ODONTO Dent J* 2015;1:29–34. doi:10.30659/odj.1.2.29-34.
29. Zaman-Joenoes N. *Ars Prescribendi: Resep yang rasional*. 3rd ed. 1994.
30. Kolluru GK, Bir SC, Kevil CG. Endothelial Dysfunction and Diabetes: Effects on Angiogenesis, Vascular Remodeling, and Wound Healing. *Int J Vasc Med* 2012;2012:1–30. doi:10.1155/2012/918267.
31. Wright HL, Moots RJ, Bucknall RC, Edwards SW. Neutrophil function in inflammation and inflammatory diseases. *Rheumatol* 2010;49:1618–31. doi:10.1093/rheumatology/keq045.
32. Ricciotti E, FitzGerald GA. Prostaglandins and inflammation. *Arterioscler Thromb Vasc Biol* 2011;31:986–1000. doi:10.1161/ATVBAHA.110.207449.
33. Hidayati NA, Listyawati S, Setyawan AD. Kandungan Kimia dan Uji Antiinflamasi Ekstrak Etanol *Lantana camara* L. pada Tikus Putih (*Rattus norvegicus* L.) Jantan. *Biotechnologi* 2008;5:10–7. doi:10.13057/biotek/c050102.
34. Rakhshan V. Common risk factors for postoperative pain following the extraction of wisdom teeth. *J Korean Assoc Oral Maxillofac Surg* 2015;41:59–65. doi:10.5125/jkaoms.2015.41.2.59.

# Anti-Inflammatory Effect of Okra (*Abelmoschus esculentus*) Fruit Extract during Wound Healing Process after Tooth Extraction of Diabetic Wistar Rat

## ORIGINALITY REPORT

**21** %  
SIMILARITY INDEX

**16** %  
INTERNET SOURCES

**15** %  
PUBLICATIONS

**6** %  
STUDENT PAPERS

## PRIMARY SOURCES

**1** repository.unair.ac.id  
Internet Source 4%

**2** Submitted to Universitas Airlangga  
Student Paper 4%

**3** worldwidescience.org  
Internet Source 2%

**4** Muhammad Luthfi, Wisnu Setyari Juliastuti, Yuniar Aliyah Risky, Elvina Hasna Wijayanti et al. "Expression of fibroblast cells after extraction of wistar rat teeth after topical application of okra fruit (*Abelmoschus esculentus*) gel", Infectious Disease Reports, 2020  
Publication 2%

**5** www.jidmr.com  
Internet Source 1%

**6** K I N Rahayu, I P S Suharto, A N Etika, S E Nurseskasatmata. "The Effect of Ginger



Extract (zingiber officinale roscoe) on the Number of Neutrophil Cells, Fibroblast and Epithelialization on Incision Wound", Journal of Physics: Conference Series, 2020

Publication

---

7	<a href="https://doi.org/">doaj.org</a> Internet Source	<1 %
8	<a href="https://www.mdpi.com">www.mdpi.com</a> Internet Source	<1 %
9	Taufan Bramantoro, Nafilah Karimah, Agung Sosiawan, R Darmawan Setijanto et al. "Miswak users' behavior model based on the theory of planned behavior in the country with the largest Muslim population", Clinical, Cosmetic and Investigational Dentistry, 2018 Publication	<1 %
10	<a href="https://www.foodandnutritionjournal.org">www.foodandnutritionjournal.org</a> Internet Source	<1 %
11	<a href="https://www.scielo.br">www.scielo.br</a> Internet Source	<1 %
12	<a href="https://insights.ovid.com">insights.ovid.com</a> Internet Source	<1 %
13	<a href="https://repository.usu.ac.id">repository.usu.ac.id</a> Internet Source	<1 %
14	Arman Saparov, Vyacheslav Ogay, Talgat Nurgozhin, William C. W. Chen, Nurlan	<1 %

Mansurov, Assel Issabekova, Jamilya Zhakupova. "Role of the immune system in cardiac tissue damage and repair following myocardial infarction", Inflammation Research, 2017

Publication

15

[translational-medicine.biomedcentral.com](https://translational-medicine.biomedcentral.com)

Internet Source

<1 %

16

Rooh Ullah, Shafiq Ahmed Tariq, Naeem Khan, Nawaz Sharif, Zia Ud Din, Khalid Mansoor. "Antihyperglycemic effect of methanol extract of Tamarix aphylla L. Karst (Saltcedar) in streptozocin–nicotinamide induced diabetic rats", Asian Pacific Journal of Tropical Biomedicine, 2017

Publication

<1 %

17

[ppsub.ub.ac.id](https://ppsub.ub.ac.id)

Internet Source

<1 %

18

[www.magonlinelibrary.com](http://www.magonlinelibrary.com)

Internet Source

<1 %

19

"Mechanism of Pancreatic Islet Number Improvement on Hyperglycemic Wistar Rats (Rattus norvegicus) After Golden Sea Cucumber (Stichopus hermannii) Extract Administration", International Journal of Innovative Technology and Exploring Engineering, 2020

Publication

<1 %

20

Heidi Sandoz. "Negative pressure wound therapy: clinical utility", Chronic Wound Care Management and Research, 2015

Publication

&lt;1 %

21

Tulio, Artemio Z., Claire Chang, Indika Edirisinghe, Kevin D. White, Joseph E. Jablonski, Katarzyna Banaszewski, Archana Kangath, Ravi K. Tadapaneni, Britt Burton-Freeman, and Lauren S. Jackson. "Berry Fruits Modulated Endothelial Cell Migration and Angiogenesis via Phosphoinositide-3 Kinase/Protein Kinase B Pathway in Vitro in Endothelial Cells", Journal of Agricultural and Food Chemistry, 2012.

Publication

&lt;1 %

22

[etheses.bham.ac.uk](http://etheses.bham.ac.uk)

Internet Source

&lt;1 %

23

Caroline Prajnaparamitha Anggraini, Kristanti Parisihni, Widyastuti W. "The Effect Of Sea Cucumber Powder And Hyperbaric Oxygen Therapy On The Expression Of Tumor Necrosis Factor Alfa In Rats With Diabetes Mellitus Induced By Porphyromonas gingivalis", DENTA, 2016

Publication

&lt;1 %

24

Hafsa Yasin, Farwa Tariq, Aysha Sameen, Nazir Ahmad et al. "Ethanollic extract of okra has a potential gastroprotective effect on

&lt;1 %

acute gastric lesions in Sprague Dawley rats",  
Food Science & Nutrition, 2020

Publication

---

25

K. Baert, L. Duchateau, S. De Boever, M. Cherlet, P. De Backer. " Antipyretic effect of oral sodium salicylate after an intravenous LPS injection in broiler chickens ", British Poultry Science, 2010

Publication

---

<1 %

26

Purabi Sarkar, Ananya Bhowmick, Mohan Chandra Kalita, Sofia Banu. " Effects of Resveratrol and Mangiferin on and Gene Expressions in Adipose Tissue of Streptozotocin-Nicotinamide-Induced Diabetes in Rats ", Journal of Dietary Supplements, 2018

Publication

---

<1 %

---

Exclude quotes Off

Exclude matches Off

Exclude bibliography On

# Anti-Inflammatory Effect of Okra (*Abelmoschus esculentus*) Fruit Extract during Wound Healing Process after Tooth Extraction of Diabetic Wistar Rat

---

## GRADEMARK REPORT

---

FINAL GRADE

**/0**

GENERAL COMMENTS

**Instructor**

---

PAGE 1

---

PAGE 2

---

PAGE 3

---

PAGE 4

---

PAGE 5

---

PAGE 6

---