

# The decreasing of NFκB level in gingival junctional epithelium of rat exposed to Porphyromonas gingivalis with application of 1% curcumin on gingival sulcus

*by Agung Krismariono*

---

**Submission date:** 17-Oct-2019 04:10PM (UTC+0800)

**Submission ID:** 1194631136

**File name:** 7\_705-1360-2-PB.pdf (279.58K)

**Word count:** 3134

**Character count:** 16868

Research Report

## The decreasing of NF $\kappa$ B level in gingival junctional epithelium of rat exposed to *Porphyromonas gingivalis* with application of 1% curcumin on gingival sulcus

Agung Krismariono  
Department of Periodontics  
Faculty of Dental Medicine, Universitas Airlangga  
Surabaya - Indonesia

### ABSTRACT

**Background:** Periodontal disease is a chronic, multi-factorial disease. Chronic periodontitis is one of the main causes of tooth loss. Chronic periodontitis is usually caused by *Porphyromonas gingivalis* (*P. gingivalis*). *P. gingivalis* can induce NF $\kappa$ B activation resulting in the increasing of periodontal extracellular matrix degradation. Curcumin can inhibit NF $\kappa$ B activation and reduce the severity of periodontal degradation. **Purpose:** This research was aimed to observe level of NF $\kappa$ B in gingival junctional epithelium of rat exposed to *Porphyromonas gingivalis* with local administration of curcumin. **Methods:** Sixteen Wistar rat were divided into two groups. Group 1 (treatment) consisted of eight rat given  $2 \times 10^6$  CFU/ml *P. gingivalis* and 1% curcumin. Meanwhile, group 2 (control) consisted of eight rat given  $2 \times 10^6$  CFU/ml *P. gingivalis* only. GCF samples were collected from gingival sulcus. The samples were biochemically analyzed with ELISA method. Data were then analyzed statistically by using independent t-test ( $\alpha=0.05$ ). **Results:** The examination of NF $\kappa$ B level showed that there was significant difference between treatment group and control group ( $p<0.05$ ). The level of NF $\kappa$ B in the treatment group was significantly lower than the control group. **Conclusion:** It can be concluded that 1% curcumin application can reduce NF $\kappa$ B level in gingival junctional epithelium of rat exposed to *P. gingivalis*.

**Keywords:** NF $\kappa$ B; junctional epithelium gingiva; curcumin

**Correspondence:** Agung Krismariono, c/o: Departemen Periodonsia, Fakultas Kedokteran Gigi Universitas Airlangga, Jl. Mayjend. Prof. Dr. Moestopo no. 47 Surabaya 60132, Indonesia. E-mail: agungkr@yahoo.com

### INTRODUCTION

Periodontal disease is irreversible so that if there is no optimal treatment, most patients will potentially have lifelong disorder. However, this disease is likely painful, so people are not aware, as a result, it is generally found in the advanced level.<sup>1</sup> Chronic periodontitis is one of the types of periodontal disease widely spread in community. *Porphyromonas gingivalis* (Pg) bacteria are a major cause of this disease.<sup>2</sup> In person with poor oral hygiene, the presence of Pg bacteria in the *gingival sulcus* can potentially damage junctional epithelium, causing periodontitis characterized by loss of attachment.

Loss of attachment to the *junctional epithelium* may be caused by the invasion of Pg bacteria. Pg bacteria causing chronic periodontitis can produce certain endotoxin, namely LPS and proteases, that can activate neutrophils and macrophages, which then will activate the transcription factor of nuclear factor-kappa B (NF $\kappa$ B). The activation of NF $\kappa$ B can trigger transcription and translation processes producing mediators that play a role in inflammation process.<sup>3</sup> A research in rat showed that LPS in 10 days can cause inflammation in periodontal tissue.<sup>4</sup> Inflammatory mediators in the optimal number actually can serve to neutralize antigen. If the number of inflammatory mediators produced are excessive, the extracellular matrix

will be damaged, so the periodontal tissues then can be damaged.<sup>5</sup>

Various attempts have been made to treat chronic periodontitis, such as by scaling and root planning as well as by giving antibiotics and anti-inflammatory either locally or systemically. Anti-inflammatory is required in the treatment of chronic periodontitis since it can neutralize the effects caused by the increasing of pro-inflammatory mediators. Anti-inflammatory commonly used in the treatment of chronic periodontitis is administered systemically. Systemic administration has few adverse side effects. Therefore, it needs proper efforts that are effective, efficient and safe for treating this disease. One of those is by using herbal ingredients, which have medicinal properties and can be administered locally, such as turmeric (*Curcuma longa*).<sup>6</sup>

The main active ingredient contained in turmeric is curcuminoid which main content is curcumin. Curcumin has useful properties, such as anti-inflammatory, antioxidant, antibacterial, antitumor and antihepatotoxic. Curcumin is also considered as a potent inhibitor of transcription factor NF $\kappa$ B.<sup>6,7</sup> Nevertheless, the role of curcumin against NF $\kappa$ B associated with periodontal disease, especially chronic periodontitis with indicators taken from GCF has never been proven.

Based on those facts, curcumin is expected to reduce the degree of inflammation in the gingival junctional epithelium caused by bacterial Pg invasion. Curcumin is also expected to inhibit the increasing of NF $\kappa$ B level so that pro-inflammatory mediators produced by NF $\kappa$ B that cause periodontitis can be decreased. The purpose of this research is to investigate NF $\kappa$ B level in gingival junctional epithelium of rat exposed to *Porphyromonas gingivalis* with local administration of curcumin.

## MATERIALS AND METHODS

This research can be considered as an in vivo experiment using male rat (*Rattus norvegicus*) Wistar aged 5-6 months old and weighed 250-300 grams. The choosing of the age was based on the fact that the size of the jaw and gingival of the rat in that age is big enough to be applied with the medicines. This research was conducted at Laboratory of Biology in Faculty of Natural Science and Mathematics, Laboratory of Microbiology, and Laboratory of Biochemistry in Universitas Brawijaya. The samples of this research were selected randomly with the sample size determined through trial. Based on a sample size formula the representative number of samples must be eight.<sup>7</sup>

Curcumin powder was prepared in solution by using corn oil solvent to achieve a concentration of 1%. The concentration of 1% was determined based on a previous research conducted by Suhag.<sup>9</sup> Meanwhile, to stimulate periodontitis disease in those rat, Pg bacteria (ATCC 33 277) were given and grown in a medium containing tryptic soy broth (TSB). They were incubated in an anaerobic atmosphere for 24 hours. They were grown in blood agar

containing 10% sheep blood, 0.4 mL/ml vitamin K1 and 5 mL/ml hemin and then put into an anaerobic incubator with a composition of 80% N<sub>2</sub>, 10% H<sub>2</sub> and 10% CO<sub>2</sub> for 24 hours at a temperature of 37<sup>0</sup> C. The largest colonies were transferred into liquid medium containing thioglicolat, and then incubated for 24 hours at 37<sup>0</sup> C in an anaerobic atmosphere. After PBS was given, spectrophotometry with 624 nm wavelength was used to make bacterial concentration as many as 1 x 10<sup>6</sup> CFU.<sup>10</sup>

Rat used as experimental animals were adapted for 1 week before the research, by conditioning them in a cage with feeding (certain concentrate) and beverages (distilled water) according to standards of animal care in Biological Laboratory, Faculty of Natural Science and Mathematics, Universitas Brawijaya. Those rat were then locally given 0.03 ml of live Pg ATCC 33 277 with the concentration of 2 x 10<sup>6</sup> CFU/ml in the *gingival sulcus* bottom of their left and right mesial incisor teeth. The same procedure was then repeated every three days for two weeks. This procedure was conducted to make the animals get periodontitis. In the treatment group, 1% curcumin in corn oil as much as 0.03 ml was administered locally in the same area as the provision of bacteria every day for two weeks to provide a therapeutic effect. Meanwhile, in the control group, only corn oil was administered every day for two weeks in the same area as the provision of bacteria.

NF $\kappa$ B level was measured on day 14 by using periopaper put into the gingival sulcus for 30 seconds to get gingival crevicular fluid (GCF).<sup>11</sup> The examination was conducted two weeks after the treatment. Periodontitis can be occurred in the past 10 days.<sup>4</sup> Samples derived from GCF (in periopaper) put into eppendorf tubes and stored at -80<sup>0</sup> C until all the samples were collected and ready for examination. After all the samples were collected from the GCF, then the preparation of ELISA examination was conducted. Each eppendorf tube containing periopaper was added with 0.5ml, 0.02M PBS with pH 7.0 to 7.2 as the solvent, and then centrifugation was conducted at 3000 rpm for 20 minutes. Finally, the supernatant of all of those samples was taken for examination in accordance with ELISA procedure using specific rat monoclonal antibody for NF $\kappa$ B.

## RESULTS

Table 1 and Figure 1 show that NF $\kappa$ B levels in both the control group (bacteria and corn oil) and the treatment group (bacteria and curcumin in corn oil) on day 14. The results of Kolmogorov-Smirnov Goodness of Fit Test showed the value of p was 0.954 (p>0.05). It indicates that the survey data were normally distributed.

Based on the analysis of independent t-test results between the treatment group and the control group, it is known that there were significant differences between the control group and the treatment group with p=0.000 (p<0.05). It is also showed that NF $\kappa$ B level in the treatment

group given 1% curcumin was lower than that in the control group.

**DISCUSSION**

This research was conducted to find an alternative solution for healing chronic periodontitis. The data from previous researches indicate that oral hygiene is the main cause of pathogen bacteria accumulation. This accumulation of bacteria causes periodontal tissue damage characterized by loss of attachment and migration of gingival junctional epithelium to apical. The results of this research showed that the group of rat not given curcumin had higher NFκB level than the group given curcumin. It means that curcumin has an effect in inhibiting NFκB activity in gingival junctional epithelium cells of those rat.

Curcumin can inhibit the phosphorylation of IκB kinase, so the translocation of NFκB into the nucleus of the cell is inhibited, resulting the decreasing of NFκB activity so that the expression of pro-inflammatory cytokines is also decreased.<sup>7</sup> The inhibition of the phosphorylation of the inhibitor factor of IκB kinase in the cytoplasm can occur because curcumin is lipophilic<sup>13</sup> so it could penetrate cell membranes and be located in either the cytoplasm or nucleus.<sup>14</sup>

Curcumin can inhibit NFκB activation prior to its translocation into the cell nucleus. NFκB activation in

patients with periodontitis has increased about 90%, while that in healthy tissue is only 30%. The expression of IκB as an NFκB inhibitor in patients with periodontitis is only 5%.<sup>15</sup>

Curcumin as an anti-inflammatory is a potential inhibitor of NFκB. NFκB determines the expression of genes encoding cytokines, chemokine, growth factors, cell adhesion molecules, some acute protein phases, such as iNOS and COX-2, and receptors on the cell membrane, such as TLR.<sup>16</sup> The activation of NFκB can be caused by a wide variety of triggers, such as bacteria, viruses, cytokines, free radicals and toxic environments. The activation of NFκB is associated with inflammatory process found in diseases, such as periodontitis, arthritis, atherosclerosis, and other degenerative diseases.<sup>17</sup> On the other hand, the complex and persistent inhibition of NFκB is also connected directly with apoptosis, impaired immune cell development, and cell growth inhibition.<sup>16</sup>

Chronic periodontitis disease is generally caused by Pg bacteria.<sup>2</sup> The increasing of NFκB is generally caused by products produced by Pg bacteria, such as protease, LPS, and fimbriae.<sup>18</sup> Protease produced by Pg bacteria can trigger a series of immune response. Arg-gingipain (RGP), protease produced by Pg bacteria, is a potential activator for protease-activated receptor-2 (PAR-2).<sup>19</sup> It means that protease is capable of breaking peptide in N-terminal of PAR-2 molecule, resulting in a new amino acid (neo-ligand) binding to the trans-membrane domain triggering PAR-2 activation. PAR-2 will further stimulate signals to NFκB, so NFκB is activated and trans-located into the nucleus.<sup>20</sup>

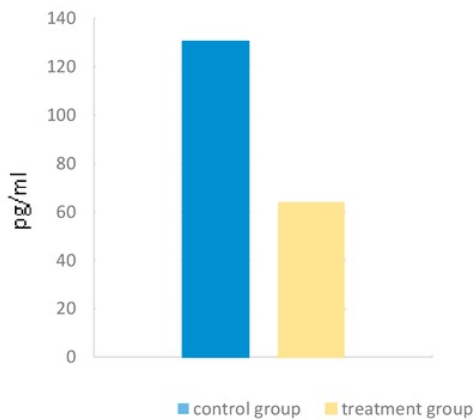
In addition to proteases, LPS produced by Pg bacteria is also a potent stimulator to produce pro-inflammatory cytokines. It means that in periodontal tissue exposed to LPS, monocytes will be activated, and pro-inflammatory cytokines will be secreted. LPS may also activate receptors on the cell membrane, such as TLR-2, TLR-4 and TLR-7. The activation of TLR causes intracellular signals passing through MyD88 pathway that induces p38 MAPK and subsequently activates NF-κB.<sup>21</sup>

Fimbriae contained on live Pg can also be considered as an effective inducer that can activate NFκB due to signals from TLR-2. TLR-2 can enhance the activity of NFκB due to fimbriae of Pg bacteria.<sup>21</sup> The fimbriae of Pg bacteria can stimulate TLR-2 which signals will further activate NFκB.<sup>22</sup> In other words, the activation of NFκB is stimulated by TLR-2 signals more dominantly activating cytokines induced by TNF in acute responses of osteoclastogenesis process.<sup>23</sup> The increasing of osteoclasts then will cause damage to the periodontal tissues.

In addition to extracellular signals, the increasing of NFκB level may also be caused by intracellular signals derived from virulence factor of the structure of Pg bacteria, ie peptidoglycan. Peptidoglycan, a bacterial cell wall, can be recognized by TLR-2 located on the cell membrane or by NOD1 and NOD2 located in the cytoplasm. This synergism between TLR and NOD-2 then can activate NFκB.<sup>24</sup>

**Table 1.** The mean and standard deviation levels of NFκB

NFκB	Treatment group X̄ ± SD	Control group X̄ ± SD
	63.79 ± 8.049 pg/ml	130.48 ± 22.378 pg/ml



**Figure 1.** NFκB levels in the control group and the treatment group.

The focus of this research is to analyze the activity of the transcription factor NF $\kappa$ B used as a strategy for the prevention and treatment of periodontal disease, especially chronic periodontitis. From the results of this research, it is known that the administration of 1% curcumin can make NF $\kappa$ B level in the treatment group lower than that in the control group. This means that inflammation is the problem of tissue damage in chronic periodontitis disease, but its severity can be reduced by administration of curcumin. It can be concluded that 1% curcumin locally given in gingival sulcus can reduce the degree of inflammation in the periodontal tissues, especially gingival junctional epithelium, by decreasing NF $\kappa$ B level.

#### REFERENCES

1. Deschner J, Eick S, Damanaki A, Nokhbehshaim M. The role of adipokines in periodontal infection and healing. *Mol Oral Microbiol* 2014; 29(6): 258-69.
2. Mysak J, Podzimek S, Sommerova P, Lyuya-Mi Y, Bartova J, Janatova T, Prochazkova J, Duskova J. *Porphyromonas gingivalis*: major periodontopathic pathogen overview. *J Immunology Res* 2014; 1-8.
3. Lisboa, Assis R, Andrade, Vinicius M, Melo C, Renan J. Toll-like receptor activation and mechanical force stimulation promote the secretion of matrix metalloproteinases 1, 3 and 10 of human periodontal fibroblasts via p38, JNK and NF- $\kappa$ B. *Archives of Oral Biology* 2013; 58 (6): 731-9.
4. Feng Z, Weinberg A. Role of bacteria in health and disease of periodontal tissues. *Periodontology* 2000, 2006; 40: 50-76.
5. Aggarwal BB, Bhatt ID, Ichikawa H, Ahn KS, Sethi G, Sandur SK, Natarajan C, Seeram N, Shishodia S. Curcumin: biological and medicinal properties. 2006; 297-340.
6. Jurenka JS. Anti-inflammatory properties of curcumin, a major constituent of curcuma longa: a review of preclinical and clinical research. *Altern Med Rev* 2009; 14(2): 141-53.
7. Kuntoro. Metode sampling dan penentuan besar sampel. Surabaya: Pustaka Melati; 2008. p. 211-20.
8. Suhag A, Dixit J, Dhan P. Role of curcumin as a subgingival Irrigant: a pilot study. *Quintessence J* 2007; 4(2): 115-21.
9. Polak D, Wilensky A, Shapira L, Halabi A, Goldstein D, Weiss EI, Haddad YH. Mouse model of experimental periodontitis induced by *Porphyromonas gingivalis*/Fusobacteriumnucleatum infection: bone loss and host response. *J Clin Periodontol* 2009; 36: 406-10.
10. Kaya FA, Arslan SG, Kaya CA, Arslan H, Hamam O. The gingival crevicular fluid levels of IL-1 $\beta$ , IL-6 and TNF- $\alpha$  in late adult rat. *Int Dent Res* 2011; 1: 7-12.
11. Chen D, Nie M, Fan MW, Bian Z. Anti-inflammatory activity of curcumin in macrophages stimulated by lipopolysaccharides from *Porphyromonas gingivalis*. *Pharmacology* 2008; 82(4): 264-9.
12. Minear S, O'Donnell AF, Ballew A, Giaever G, Nislow C, Stearns T, Cyert MS. Curcumin inhibits growth of *Saccharomyces cerevisiae* through iron chelation. *Eukaryotic Cell* 2011; 10(11): 1574-81.
13. Kunwar A, Barik A, Mishra B, Rathinasamy K, Pandey R, Priyadarsini KI. Quantitative cellular uptake, localization and cytotoxicity of curcumin in normal and tumor cells. *Biochim Biophys Acta* 2008; 1780(4): 673-9.
14. Ambili R, Santhi WS, Prasanthila J, Nandakumar K, Pillai R. Expression of activated transcription factor nuclear factor- $\kappa$ B in periodontally diseased tissues. *J Periodontol* 2005; 76(7): 1148-53.
15. Ballistreri CR, Candore G, Accardi G, Colonna-Romano G, Lio D. NF- $\kappa$ B pathway activators as potential ageing biomarkers: targets for new therapeutic strategies. *Immunity & Ageing* 2013; 10(24): 1-16.
16. Arabaci T, Cicek Y, Canakci V, Canakci CF, Ozgoz M, Albayrak M, Keles ON. Immunohistochemical and Stereologic Analysis of NF- $\kappa$ B Activation in Chronic Periodontitis. *Eur J Dent* 2010; 4(4): 454-61.
17. Yu WH, Hu H, Zhou Q, Xia Y, Amar S. Bioinformatics analysis of macrophages exposed to *Porphyromonas gingivalis*: Implications in acute vs. chronic infections. *PLoS One* 2010; 5(12): 1-7.
18. Holzhausen M, Spolidorio LC, Ellen RP, Jobin MC, Steinhoff M, Gordon PA, Vergnolle N. Protease-activated receptor-2 activation a major role in the pathogenesis of *Porphyromonas gingivalis* infection. *Am J Pathol* 2006; 168: 1189-99.
19. Rallabhandi P, Nhu QM, Toshchakov VY, Piao W, Medvedev AE, Hollenberg MD, Fasano A, Vogel SN. Analysis of proteinase-activated receptor 2 and TL4R4 signal transduction. A novel paradigm for receptor cooperativity *J Biol Chem* 2008; 283(36): 24314-25.
20. Zhou Q, Amar S. Identification of signaling pathways in macrophage exposed to *Porphyromonas gingivalis* or to its purified cell wall components. *J Immunol* 2007; 179(11): 7777-90.
21. Krachler AM, Woolery AR, Orth K. Manipulation of kinase signaling by bacterial pathogens. *J Cell Biol* 2011; 195(7):1083-92.
22. Kanaya S, Nemoto E, Ogawa T, Shimauchi H. *Porphyromonas gingivalis* fimbriae induce unique dendritic cell subsets via Toll-like receptor 2. *J Periodontal Res* 2009; 44(4): 543-9.
23. Sugawara Y, Uehara A, Fujimoto Y, Kusumoto S, Fukase K, Shibata K, Sugawara S, Sasano T, Takada H. Toll-like Receptors, NOD1, and NOD2 in oral epithelial cells. *J Dent Res* 2006; 85(6): 524-9.

# The decreasing of NFκB level in gingival junctional epithelium of rat exposed to Porphyromonas gingivalis with application of 1% curcumin on gingival sulcus

---

## ORIGINALITY REPORT

---

9%

SIMILARITY INDEX

8%

INTERNET SOURCES

5%

PUBLICATIONS

%

STUDENT PAPERS

---

## MATCH ALL SOURCES (ONLY SELECTED SOURCE PRINTED)

---

4%

★ zombiedoc.com

Internet Source

---

Exclude quotes Off

Exclude matches Off

Exclude bibliography On

The decreasing of NFκB level in gingival junctional epithelium of rat exposed to Porphyromonas gingivalis with application of 1% curcumin on gingival sulcus

---

GRADEMARK REPORT

---

FINAL GRADE

**/0**

GENERAL COMMENTS

**Instructor**

---

PAGE 1

---

PAGE 2

---

PAGE 3

---

PAGE 4

---