

# THE INDIAN VETERINARY JOURNAL

SINCE - 1924

**Journal of**  
**THE INDIAN VETERINARY ASSOCIATION**  
ESTD - 1922      Regd. No. Sl. No. 96/1967 (CHENNAI)



No. 11, Pasumpon Muthuramalinga Thevar Salai (Chamiers Road),  
Nandanam, Chennai - 600 035, Tamil Nadu, India  
Tel. : +91 44 2435 1006  
Email : [ivj83@yahoo.com](mailto:ivj83@yahoo.com)  
ONLINE : [www.ivj.org.in](http://www.ivj.org.in)

**THE INDIAN VETERINARY JOURNAL**  
(Official Organ of The Indian Veterinary Association)

**EDITORIAL COMMITTEE**

**Dr A.V. KRISHNAN, Chief Editor**

B.V.Sc., M.V.Sc (Path.)

Retd. Additional Director of A.H., TN

**Dr S. SUKUMAR, Managing Editor**

B.V.Sc., M.V.Sc (Vet. Micro), Ph.D. (Biotech)

Retd. Professor of Biotechnology, TANUVAS, TN

**Dr V. Titus George, Editor**

B.V.Sc., M.V.Sc., Ph.D. (Patho)

Retd. Prof. of Pathology, TANUVAS

**Dr I. Ponnu Pandian, Editor**

B.V.Sc., PGDAEM

**Dr K. Venukopalan, Editor**

B.V.Sc., M.V.Sc., Ph.D. (Poul.)

Retd. Prof. of Poultry Science, TANUVAS

**EDITORIAL BOARD**

**CHAIRMAN**

**Dr. Chirantan Kadian**

B.V.Sc & A.H.

**President, The Indian Veterinary Association**

**MEMBERS**

**Dr Praveen Malik**

B.V.Sc & A.H.; M.V.Sc; Ph.D; MBA

Commissioner

Department of Animal Husbandry

Ministry of Fisheries, Dairying and Animal Husbandry  
Government of India.

**Prof. Dr C. Balachandran**

M.V.Sc, Ph.D., PGDAJ, PGDEVP, DICVP

FAO Fellow, FIAVP, FNAVS, FASAW

Vice-Chancellor

Tamilnadu Veterinary and Animal Sciences University  
Madhavaram Milk Colony, Chennai - 600 051.

**Dr. P.K. Panwar**

BVSc & AH, MVSc,

Department of Animal Husbandry  
Uttar Pradesh

**Dr. Subhash Chander Ahlawat**

BVSc & AH.

Department of Animal Husbandry  
Haryana

**MANAGING COMMITTEE OF  
THE INDIAN VETERINARY ASSOCIATION**

**President :**

Dr. Chirantan Kadian

**Secretary General :**

Dr. R.S. Patel

**Treasurer :**

Dr. I. Ponnu Pandian

**Joint Secretary :**

Dr. M.K. Srikanth

**Vice Presidents :**

Dr. L. Chandrasekaran, HQ, Tamilnadu

Dr. Arun Sirkeck, Himachal Pradesh

Dr. S.G. Yalagod, Karnataka

Dr. Ilang, Nagaland

Dr. Ramji Lal Meena, Rajasthan

Dr. Sudhir Kumar, Uttar Pradesh

**Zonal Secretaries :**

Dr. Amit Nain, Punjab

Dr. R. Vasantha Rayalu, Andhra Pradesh

Dr. Bhuvan Ch. Sarmah, Assam

Dr. Umesh Balaji Sontakke, Maharashtra

Dr. Pankaj Kumar, Jharkhand

**Managing Editor, IVJ :**

Dr. S. Sukumar, Tamil Nadu

# THE INDIAN VETERINARY JOURNAL

(Official organ of the Indian Veterinary Association)

Vol. 97

February 2020

No. 02

## CONTENTS

### GENERAL ARTICLES :

- Surgical and Clinicopathological Features of Bovine Ocular Squamous Cell Carcinoma**  
R. Uma Rani and N. Pazhanivel ... 09
- Immune Stimulation by Electroacupuncture at High Frequency ST36 Acupoint through SP on Hyperglycemia**  
William Sayogo, Jusak Nugraha, Suhariningsih, I Ketut Sudiana, Sarmanu, Paulus Liben, Rahajoe Imam Santosa and Budi Utomo ... 12
- Retrospective Study on Medicinal Disorders in Breeding Bulls**  
S.H.Sontakke, V. H.Shende, V.V.Potdar, H.D.Kadam, J.R.Khadse and A.B.Pande ... 14
- Antiangiogenesis Activity of *Centella Asiatica* on the Macrophage Number and Matrix Metalloproteinase-9 in Blood Vessels of Chorioallantois Membrane Induced by Basic Fibroblast Growth Factor**  
Iwan Sahrial Hamid ... 17
- Gross Anatomical Studies on the Sternum of African Gray Parrot (*Psittacus erithacus*)**  
O.R.Sathyamoorthy, R.Mahaprabhu and S.Ushakumary ... 20
- Photodynamic Therapy with Ozone aids to *Staphylococcus aureus* Biofilm Reduction**  
Putri S. Puspita, Suryani D. Astuti, Aulia M.T. Nasution, Anak A.S. Pradhana and Amiliyatul Mawaddah ... 24
- An investigation on the *Euphoria longan* (Lour.) Steud Seeds in Wound Healing in *Rattus norvegicus***  
Amaq Fadholly, Arif N.M. Ansori, Annise Proboningrat, Muhammad K.J. Kusala, Naimah Putri, Vindo R. Pertiwi, Vivi H. Harun, Samirah U. Balbeid, Muhammad C. Ardiansyah and Suryo Kuncorojakti ... 26
- Aluminosilicates Decrease Cytochrome-C and Caspase-3 Expression in Mice Uterine Glands Model Zearalenone Intoxication**  
Amung Logam Saputro, Ragil Angga Prastya and Muhammad Thohawi Elziyad Purnama ... 30
- Adjuvant Therapy of *Syzygium cumini* Leaf and Fruit Extract Nanoparticles in Mice (*Mus musculus*) Infected by *Plasmodium berghei***  
Lilik Maslachah, Rahmi Sugihartuti, Retno Sri Wahjuni and Lita RakhmaYustinasari ... 33
- Encoding Gene for Methicillin Resistant *Staphylococcus aureus* (MRSA) Isolated from Nasal Swab of Dogs**  
Reina Puspita Rahmaniar, Maya Nurwartanti Yunita, Mustofa Helmi Effendi, and Sheila Marty Yanestria ... 37
- Substituting Chrome Tanner with Mangrove (*Rhizophorasp.*) Bark Extract Improves Tanning of Parrotfish (*Scarus sp.*) Leather**  
Ulifiah Adi Saputri, Laksmi Sulmartiwi and Annur Ahadi Abdillah ... 41

<b>Chemical Composition of Maggot, Fermented and Commercial Feed-fermented Maggot Meals</b>	
Muhammad Browijoyo Santanumurti, Syifania Hanifah Samara, Daruti Dinda Nindarwi, Lailatur Rubi'ah, Nur Wantika, Budiana, Rusdiatin, Yuli Tya Nila, Ekka Suryani, Nada Dzatalini, Mohammad Anam Al-Arif, Widya Paramita Lokapirnasari, Mochammad Amin Alamsjah, and Mirni Lamid	... 43
 <b>CLINICAL AND FIELD ARTICLES :</b>	
<b>Surgical Management of Immature Ocular Setariasis in a Kid</b>	
A.R.Ninu, S.Dharmaceelan, S.Kokila, K.Dhandapani and T.Anna	... 46
<b>Surgical Management of Large Chronic Penile Hematoma in a Bull – A Case Report</b>	
R. Uma Rani, A. Tamil Mahan and S. Senthilkumar	... 47
<b>Dystocia Due to Cranium Bifidum Occultum (Catlin Mark) in a Cross Bred Jersey Cow- A Case Report</b>	
A.Ganesan, P.Chandran and M.Murugan	... 49
<b>An Incidental Finding of Uterine Leiomyoma in <i>Panthera Pardus</i></b>	
P. D. Gadhawe, S.G. Pethe, V.S. Dhaygude, D.P. Kadam, B.R. Dash and P.V. Meshram	... 50
<b>Congenital Bilateral Cleft Lip - Jaw - Palate in a Male Holstein Friesian Crossbred Calf</b>	
R. Kalirajan and R. Uma Rani	... 52
<b>Surgical Management of Unilateral Endometrial Adenoma in a Queen Cat</b>	
R. Uma Rani and N. Pazhanivel	... 54
<b>Dystocia Due to Perosomus Elumbis Coupled with Cryptorchidism in a Pattanam Ewe</b>	
R. Valarmathi, R. Rajkumar, M. Palanisamy, S. Raja, V. Prabakaran and P. Tamilmahan	... 55
<b>Successful Management of Post-Partum Rectal and Crevico - Vaginal Prolapse in a Gir Cow - A Case Report</b>	
G. Shanmuga Priya and G. Prakash	... 57
<b>Congenital Phimosis in a Bhutia Pup and its Surgical Treatment</b>	
M. S. Abhishek, R. Prabhat and T. Jagadeesh	... 59
<b>Performances of Khaki Campbell Duck Under Intensive and Extensive System of Management</b>	
H. Hazarika, D. Hazarika and D. K. Borah	... 61
 <b>COMMUNICATION : FMD Control -The Last Mile Delivery</b>	... 63
 <b>Author and Subject Index</b>	<b>69 &amp; 70</b>

## Antiangiogenesis Activity of *Centella Asiatica* on the Macrophage Number and Matrix Metalloproteinase-9 in Blood Vessels of Chorioallantois Membrane Induced by Basic Fibroblast Growth Factor

Iwan Sahrial Hamid<sup>1</sup>

Department of Veterinary Pharmacology, Faculty of Veterinary Medicine, Universitas Airlangga, Surabaya 60115, Indonesia.

(Received : June, 2019 244/19 Accepted : September, 2019)

### Abstract

This study aimed to examine the potential of aqueous extract of *Centella asiatica* on the macrophage number and matrix metalloproteinase-9 (MMP-9) in blood vessels of chorioallantois membrane induced by basic Fibroblast Growth Factor (bFGF). This study used 20 embryonated chicken eggs (ECE) which were divided into five groups i.e. positive control (C+) given 60 ng of bFGF; negative control (C-) given DMSO 2%; treatment groups (T1; T2; T3) given 60 ng of bFGF and *Centella asiatica* extract (75; 90; 110) µg. It was concluded that *Centella asiatica* at a dose of 110 µg decreased the macrophage number and the expression of MMP-9.

**Key words:** *Centella asiatica*, Chorioallantois membrane, Macrophage, MMP-9

Angiogenesis is a phenomenon associated with the growth of new blood vessels (Murata *et al.*, 2008). Angiogenesis of cancer pathophysiology takes a role of supplying oxygen and metabolic products of cancer cells (Seavey *et al.*, 2009). Cancer incidence were unable to be separated from the contribution of angiogenesis. The inhibitory, *Centella asiatica* was assumed to have the role on the mechanisms that initiate cancer through angiogenesis.

### Materials and Methods

This study was approved by the Animal Care and Use Committee, Faculty of Veterinary Medicine, Universitas Airlangga. Induction of the new blood vessels in the Chorioallantois Membrane performed by induced basic Fibroblast Growth Factor (bFGF). *Centella asiatica* aqueous extract of 10 mg was dissolved in 2% DMSO in sterile

aqueous solution to obtain a solution with a concentration of 1 µg/µl. This study used 20 embryonated chicken eggs (ECE) which were divided into five groups i.e. positive control (C+) given 60 ng of bFGF; negative control (C-) given DMSO 2%; treatment groups (T1; T2; T3) given 60 ng of bFGF and *Centella asiatica* extract (75; 90; 110) µg, respectively. All samples were incubated at a temperature of 38°C and a relative humidity of 60% for 72 hours (Hamid *et al.*, 2018). Immunohistochemistry method was done to measure the macrophage number and expression of MMP-9. The data tested by one way Anova and followed Duncan test.

### Results and Discussion

There was a significant difference in the provision of aqueous extract of *Centella asiatica* at various doses to decrease the number of macrophages (Table I). The mean number of macrophages were the lowest in the T3 group. These results were not significantly different ( $p > 0.05$ ) with the C- group. It means that the administration of *Centella asiatica* aqueous extracts at 110 µg capable of inhibiting the development of macrophages. While the T1 group at the dose of 75 µg was not significantly different ( $p > 0.05$ ) from C+ group. However, the results of this study indicated that there was decreased number of macrophages ( $p < 0.05$ ) in all three treatment groups treated with *Centella asiatica* aqueous extract, compared to C+ group.

The result of the MMP-9 expression in endothelial cells of new blood vessels (Fig.2) indicated that the highest average number expression was obtained in the C+ group. These results were significantly different ( $p < 0.05$ ) compared to all other treatment groups (Table

<sup>1</sup>Corresponding author : Email : iwan-s-h@fkh.unair.ac.id

**Table I.** Mean and standard deviation of the amount of macrophage and MMP-9

Treatments	Mean±SD	
	Macrophage	MMP-9
C+	90.50 <sup>a</sup> ±56.80	310.75 <sup>d</sup> ±23.76
C-	35.00 <sup>c</sup> ±7.52	97.00 <sup>a</sup> ±11.40
T1	82.25 <sup>a</sup> ±9.17	276.75 <sup>c</sup> ±30.01
T2	51.00 <sup>b</sup> ±8.60	151.00 <sup>b</sup> ±24.61
T3	34.50 <sup>c</sup> ±5.19	130.50 <sup>b</sup> ±19.39

Different superscripts in the same column indicate significant differences among treatments (p<0.05).

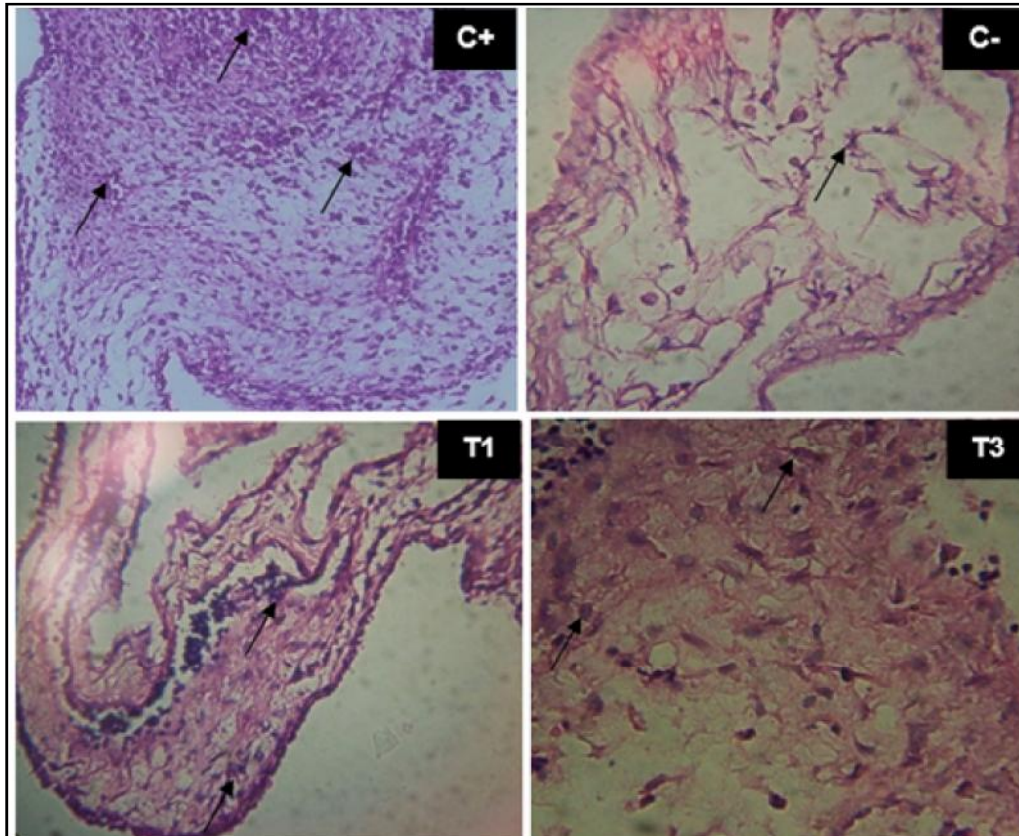
D). While the mean results of the MMP-9 expression the least were shown in the C- group. On comparison no significant differences (p>0.05) were noticed between by treatment groups with *Centella asiatica* extract at 90 µg and 110 µg.

*Centella asiatica* contains triterpenoid glycosides or asiaticoside which is used in leprosy wound healing. While compounds that function for anti-cancer properties are asiatic acids.

*Centella asiatica* is used as a tonic, antirheumatic, sedative, accelerates wound healing, and diuretics. The content of other compounds, namely: asiaticoside, thankuniside, medecassoside, brahmoside, brahminoside, madastic acid, vitamins B1, B2, and B6 (Sampson *et al.*, 2001).

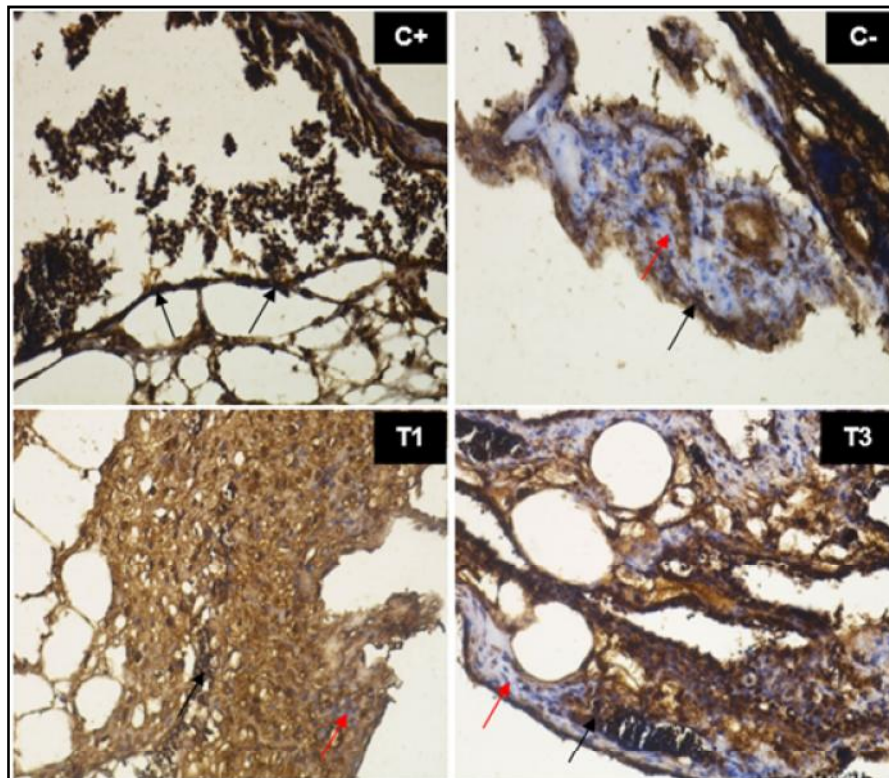
bFGF or FGF-2 is part of the Fibroblast Growth Factor group that affects most cellular activity. Interacting with no more than 23 ligands, four receptors and with various co-receptors that complexly spread into a sign of effects on various receptors (Coultas *et al.*, 2005). bFGF is generally identified as mitogen with prominent angiogenic, which is now better known as multifunctional growth factors (Przybylski, 2009). The ligand binding of the permissible and autophosphorylated receptors follows the binding and activation of cytoplasmic target proteins (Backhaus *et al.*, 2004).

Macrophages stimulate the body defense systems which functions as phagocytosis. Congenital body defense is a non-immunological



**Fig.1.** Histopathological features of chorioallantoic membrane of blood vessels after *Centella asiatica* and bFGF induction. The black arrows indicate macrophage ( ).





**Fig.2.** Expression of MMP-9 by Immunohistochemistry staining. The black arrows ( ) indicate the MMP-9 expression and red arrows ( ) indicate inactive MMP-9 in cells.

defense that has existed since the birth (Jetten *et al.*, 2014). Matrix metalloproteinase-9 and Matrix metalloproteinase-13 are families of MMP that play a role in angiogenesis. The role of MMP in angiogenesis was noticed when inflammatory cells or tumor cells secrete angiogenic factors such as VEGF and bFGF which then bind to their receptors on the endothelial cell surface (Iwasaki *et al.*, 2004). This will activate endothelial cells to secrete MMP and MMP that will degrade the extracellular matrix and assists their proliferation (Rosell *et al.*, 2008).

The observation of the overall number of macrophages in the treatment group *Centella asiatica* showed decreased significance (Fig.1). These results indicate that the higher the dose of *Centella asiatica* aqueous extract bigger the growth inhibition of new blood vessels. In addition, the growth of new blood vessels includes a complex process involving immunological processes, one of which is played by macrophages. Macrophages play a role in inflammatory processes and tumor angiogenesis (Jetten *et al.*, *loc. cit.*).

It is commonly known that MMP-9, often referred to as Chicken gelatinase B (chMMP-9), is a specific marker for heterophile, which is an analog of blood cells with neutrophils in mammals. It can be revealed by the development of angiogenesis induced by purified growth factors or by the Human HT-1080 cells fibrosarcoma which is linked to the presence of heterophile chMMP-9 (Rosell *et al.*, *loc. cit.*). The existence of heterophile followed by infiltration of monocytes or macrophages is sufficient to support the formation of new blood vessels. Disturbances or hindrance in cell inflammatory mechanism mediated by the presence of anti-inflammatory medications such as cortisone and ibuprofen showed significant differences in inhibiting angiogenesis. MMP-9 functionally contributes to angiogenesis triggered by inflammation and tumor growth (Zijlstra *et al.*, 2006).

### Summary

The aqueous extract of *Centella asiatica* at 110 µg decreased the macrophages number and the MMP-9 expression. It is advisable to observe

some function of factors that play a role in neoangiogenesises such as MMP-13, FGF and several cytokines involved are recommended.

### Acknowledgment

The authors acknowledge The Institute of Research and Innovation, Universitas Airlangga for providing fund support to carry out this study.

### References

Backhaus, R., Zehe, C., Wegehingel, S., Kehlenbach, A., Schwappach, B. and Nickel, W. (2004) Unconventional protein secretion: membrane translocation of FGF-2 does not require protein unfolding. *J. Cell. Sci.*, **117**(9): 1727-1736.

Coultas, L., Chawengsaksophak, K. and Rossant, J. (2005) Endothelial cells and VEGF in vascular development. *Nature*, **438**(7070): 937.

Hamid, I.S., Aksono, E.B., Sukmanadi, M., and Purnama, M.T.E. (2018) Antiangiogenesis activity test of tin leaf (*Ficus carica L.*) on the number of blood vessels and VEGF expression of chorioallantoic membrane of embryonated chicken eggs. *Eur. J. Oncol. Pharm.*, **1**(4): e00007.

Iwasaki, A., Kuwahara, M., Yoshinaga, Y. and Shirakusa, T. (2004) Basic fibroblast growth factor (bFGF) and vascular endothelial growth factor (VEGF) levels, as prognostic indicators in NSCLC. *Eur. J. Cardio-thoracic Surg.*, **25**(3): 443-448.

Jetten, N., Verbruggen, S., Gijbels, M.J., Post, M.J., De Winter, M.P. and Donners, M.M. (2014) Anti-inflammatory M2, but not pro-inflammatory M1 macrophages promote angio-

genesis in vivo. *Angiogen.*, **17**(1): 109-118.

Murata, M., Yudoh, K. and Masuko, K. (2008) The potential role of vascular endothelial growth factor (VEGF) in cartilage: how the angiogenic factor could be involved in the pathogenesis of osteoarthritis?. *Osteoarthritis and cartilage*, **16**(3): 279-286.

Przybylski, M. (2009) A review of the current research on the role of bFGF and VEGF in angiogenesis. *J. Wound Care*, **18**(12): 516-519.

Rosell, A., Cuadrado, E., Ortega-Aznar, A., Hernández-Guilamon, M., Lo, E.H. and Montaner, J. (2008) MMP-9-positive neutrophil infiltration is associated to blood-brain barrier breakdown and basal lamina type iv collagen degradation during hemorrhagic transformation after human ischemic stroke. *Stroke*, **39**(4): 1121-1126.

Sampson, J.H., Raman, A., Karlsen, G., Navsaria, H. and Leigh, I.M. (2001) In vitro keratinocyte antiproliferant effect of *Centella asiatica* extract and triterpenoid saponins. *Phytomed.*, **8**(3): 230-235.

Seavey, M.M., Maciag, P.C., Al-Rawi, N., Sewell, D. and Paterson, Y. (2009) An anti-vascular endothelial growth factor receptor 2/fetal liver kinase-1 Listeria monocytogenes anti-angiogenesis cancer vaccine for the treatment of primary and metastatic Her-2/neu+ breast tumors in a mouse model. *J. Immunol.*, **182**(9): 5537-5546.

Zijlstra, A., Seandel, M., Kupriyanova, T.A., Partridge, J.J., Madsen, M.A., Hahn-Dantona, E.A. and Deryugina, E.I. (2006) Proangiogenic role of neutrophil-like inflammatory heterophils during neovascularization induced by growth factors and human tumor cells. *Blood*, **107**(1): 317-327.

Indian Vet. J., February 2020, 97 (02) : 20 - 23

## Gross Anatomical Studies on the Sternum of African Gray Parrot (*Psittacus erithacus*)

O.R.Sathyamoorthy<sup>1</sup>, R.Mahaprabhu and S.Ushakumary

Department of Veterinary Anatomy, Madras Veterinary College, Chennai- 600 007, Tamil Nadu.

(Received : August, 2019 **296/19** Accepted : September, 2019)

### Abstract

The sternum of African gray parrot was comprised of a rostrum or manubrium sterni (sternal spine), a body or corpus sterni and a keel or sternal crest. The sternal spine was long, thick and bent, hook - like process. The corpus sterni was quadrilateral in shape. The cranio-

lateral processes were short and quadrilateral in shape. The sternal crest was well developed and triangular. The caudolateral processes were short and broad.

**Key words:** Sternal crest, sternal spine, cranio-lateral process, caudolateral process

The African gray parrot is Africa's largest parrot. The plumage of *Psittacus erithacus* is various shades of gray with very distinctive red

<sup>1</sup>Corresponding author : Email : drsathya1971@gmail.com