

# Diagnostic Accuracy of Recto-Sigmoid Index Evaluation on Barium Enema in Hirschsprung's Disease

Emma Ratna Fury<sup>1</sup>, Andy Darma<sup>2</sup>, Alpha Fardah Athiyyah<sup>3</sup>

<sup>1</sup>Resident, <sup>2</sup>Lecturer and Consultant, <sup>3</sup>Lecturer and Consultant in Paediatric Hepatology Division, Department of Child Health, Faculty of Medicine, Universitas Airlangga/Dr. Soetomo General Hospital, Surabaya, Indonesia

## Abstract

**Background:** Hirschsprung's disease is a congenital disease caused by the absence of ganglion cells in the bowel wall, which results in functional obstruction of the aganglionic segment due to failure of relaxation during peristalsis. The recto-sigmoid index on barium enema may constitute in the diagnosis of Hirschsprung's disease.

**Aim:** To evaluate the sensitivity, specificity, positive predictive value, and negative predictive value of recto-sigmoid index for the diagnosis of Hirschsprung's disease in patients who underwent barium enema examination.

**Methods:** This retrospective study was conducted in Dr Soetomo Hospital. Medical records of patients suspected of Hirschsprung's disease who underwent both barium enema examination and diagnostic full thickness biopsy were evaluated. Moreover, the sensitivity, specificity, positive predictive value (PPV), and negative predictive value (NPV) of recto-sigmoid index was calculated.

**Results:** A total of 37 patients were examined; 21 of them were male. The average age was 24.5 (SD 17.34, range 1 month-72 month). Biopsy revealed the absence of ganglion cells in 32 (91,8%) patients. The recto-sigmoid index agreed with the histopathologic diagnosis in 30 (81%) patients. The sensitivity, specificity, PPV, and NPV were 87.5%, 40%, 90.5% and 33% respectively.

**Conclusion:** Recto-sigmoid index evaluation in barium enema for the diagnosis of Hirschsprung's disease has poor diagnostic accuracy.

**Keywords** *Hirschsprung's disease; aganglionic; recto-sigmoid index; barium enema*

## Background

Hirschsprung's disease (HD) is a congenital disorder in the form of parasympathetic aganglionic segments in the submucosa or Auerbach's plexus of the colon,

from the internal anal sphincter to the proximal with varying lengths. The clinical symptoms are functional bowel disorders. This disease is caused by the cessation of the craniocaudal migration of the neural crest cells in the distal colon in the fifth week to the twelfth week of pregnancy that functions to form the intestinal nerve system.<sup>1</sup>

HD occurs in 1 out of 5,000 births and it is the most common cause of neonatal lower gastrointestinal obstruction.<sup>2</sup> This disease shows a predominance of men over women with a ratio of 4:1. The incidence of HD increases in familial cases to an average of about 6% (ranged between 2% and 18%).<sup>3</sup>

---

### Corresponding author:

**Andy Darma,**

Lecturer and Consultant in Department of Child Health, Faculty of Medicine, Universitas Airlangga/ Dr. Soetomo General Hospital. Jl. Mayjen Prof. Dr. Moestopo No. 47, Airlangga, Surabaya, East Java, Indonesia (+62 31) 5501681, e-mail: andarma@gmail.com

Specimen examination using full thickness biopsy is the gold standard in enforcing the HD method.<sup>4</sup> This examination must be carried out immediately on fresh specimens, so it is often difficult to carry out due to technical difficulties and a shortage of experts. In addition, this examination is invasive, requiring general anesthesia and sutures at the biopsy site.<sup>5</sup>

The border area between the ganglion and aganglionic segments is called the transition zone, which is usually found in the recto-sigmoid region. This zone can be detected using a radiological examination, namely barium enema. In barium enema examinations, the recto-sigmoid index (RSI), which is the ratio of the widest diameter of the rectum to the widest diameter of the sigmoid colon, is calculated.<sup>6</sup> However, the RSI often gives many false negative results in a certain age group, particularly under 1 month of age.<sup>7</sup>

This research aims to determine the accuracy of RSI in the diagnosis of Hirschsprung's disease using barium enema by calculating the sensitivity, specificity, positive predictive value, negative predictive value, and likelihood ratio of RSI.

## Methods and Materials

This research is a diagnostic test that applied the cross-sectional method. It was conducted from February 2017 to May 2017 at Dr. Soetomo General Hospital Surabaya. The research samples are infants and children suspected of Hirschsprung's disease who were treated in the neonatal ward, pediatric ward, and operating room of the hospital and underwent barium enema and histopathological examinations. Those

whose medical records contain incomplete patient characteristics were excluded. The data used in this research are secondary data collected from the medical records of inpatients with gastrointestinal conditions in the neonatal and paediatric wards of the hospital from February 2017 to May 2017.

The diagnostic accuracy of RSI was obtained by comparing it with the results of full thickness biopsy with calretinin staining, which was used as the gold standard. The RSI was calculated by a radiologist at Dr Soetomo Hospital. If the RSI is greater than 1, it does not support HD, but if the RSI smaller than 1, it supports HD. Unprepared barium enema examination was carried out using a tool from Canon manufactured in 2000. The accuracy is good if the sensitivity, specificity, positive predictive value (PPV), negative predictive value (NPV), and likelihood ratio (LH) have a high value.

Meanwhile, full thickness biopsy was performed by a pediatric surgeon at Dr Soetomo Hospital. The result is positive if ganglia and nerve fibers are not found in the submucosa and muscular layers and negative if ganglia and nerve fibers are found in those layers.

## Results

36 subjects between the age of 1 and 72 months with medical records containing a biopsy and barium enema evaluation met the inclusion criteria. Based on their sex, 20 subjects were male and 16 were female. 31 subjects were born at term, the mothers of 2 subjects experienced preeclampsia and eclampsia, and malnourishment was found in 21 subjects. The characteristics of the subjects are presented in Table 1.

**Table 1 Characteristics of Research Subjects**

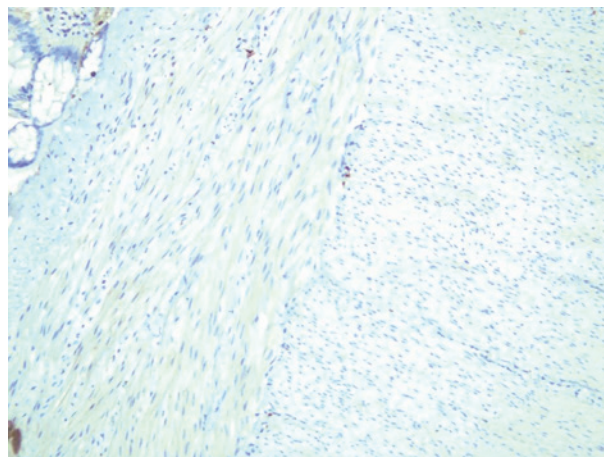
Characteristics		Quantity	Percentage (%)
Sex	Female	16	44.73
	Male	20	55.27
Age		Minimum: 1 month Maximum: 72 months Mean: 24.5 months	
Gestation	Term	32	88%
	Premature	4	11%
Nutritional Status	Well-nourished	3	8%
	At risk for malnutrition	21	58%
	Malnourished	5	14%

Table 2 shows the clinical illustration of the research subjects. Abdominal distension, which occurred to 33 research subjects, was the most frequent complaint. It was followed by delayed meconium passage or delayed first defecation that occurred to 32 patients; constipation, which was experienced by 30 patients; and another congenital disorder, which was down syndrome that occurred to 2 patients.

**Table 2 Clinical Illustration**

Characteristics	Quantity	%
Abdominal Distension	33	92
Delayed Meconium Passage	32	90
Fecal Incontinence after Rectal Examination	28	84
Constipation	30	88
Down Syndrome	2	5

32 (82%) subjects had positive biopsy results. If highlight is found on ganglia with or without nerve fibers, Hirschsprung’s disease is excluded. Conversely, if highlight is not found on ganglia in the microscope slide, it can be inferred that the patient suffers Hirschsprung’s disease. Table 5.3 shows the results of S100 staining on the full thickness biopsy specimen. The biopsy resulted in 32 positive and 3 negative cases.



**Figure 1. Microscopical Imaging of Immunohistochemistry Test Using Calretinin on Full Thickness Biopsy Specimen: Auerbach’s ganglion is not found between the muscularis propria layers (400X magnification).**

The RSI evaluation results of 30 (81%) subjects supported the diagnosis of HD.

**Table 3 Recto-sigmoid Index of Colon in Loop**

Result	Quantity	Percentage (%)
< 1	30	81
> 1	6	19
Total	36	100%

Table 5 presents the comparison of the recto-sigmoid index in barium enema examinations and the full thickness biopsy results.

**Table 4 Comparison of RSI and Biopsy Gold Standard**

Method	Biopsy		Quantity
	Positive	Negative	
RCI < 1	27	3	30
RCI > 1	4	2	6
Total	31	5	36

The diagnostic values of RSI evaluation can be seen in Table 6. The sensitivity and specificity were 87.5% and 40% respectively. The positive predictive value of anti-*H. pylori* IgG in urine was 90% and the negative predictive value was 33%. The negative and positive likelihood ratio of anti-*H. pylori* IgG was 0.32 and 1.45 respectively.

**Table 5 Diagnostic Accuracy of RSI examination in the diagnosis of Hirschsprung's Disease**

Variable	Value	95% Confidence Interval
Sensitivity	87.6	1.5-36.4
Specificity	40	61.6-98.4
Positive predictive value (PPV)	90	6.7-93.2
Negative predictive value (NPV)	33	29.5-67.4
Positive likelihood ratio	1.45	0.15-5.90
Negative likelihood ratio	0.32	0.78-1.3

## Discussion

The research subjects were dominantly male, which constituted 55.27% (20 patients), whereas the female patients were 44.73% (16 patients). 32 (88%) patients were born at term and only 4 patients (12%) were born preterm with gestational age under 37 weeks. Abdominal distension was experienced by 33 (91%) patients, delayed meconium passage by 30 (88%) patients, and chronic constipation by 30 (90%) patients. These characteristics

are in line with the results of previous research, which revealed that most HD patients are male,<sup>8,9,10,11,12,13</sup> were born at term,<sup>14,15</sup> as well as experienced abdominal distension (Chirdan, 2000; Nasir *et al* , 2007), delayed meconium passage,<sup>16</sup> and chronic constipation that usually persists despite therapy using laxatives.<sup>17</sup>

Down syndrome was included in the research subject characteristics because the syndrome is a genetic disorder that often accompanies HD.<sup>18</sup> Out of 36

patients, 2 (13%) of them have Down syndrome. This is in accordance with the previous research, which found that the prevalence of Down syndrome in HD patients ranges from 10% to 13%.<sup>19,20</sup>

In this research, four samples that were examined using full thickness biopsy with calretinin staining showed a positive imaging, indicated with blackish-brown color on the ganglia in the submucosa, muscularis propria, and/or lamina propria with or without nerve fibers. Calretinin reagent makes cells or tissues containing calretinin protein into brown, including tissues of the brain, heart, intestines, etc. The colored cells are not only ganglion and neuron cells, but also the morphology unique to ganglia and fibers that are easily recognized in specimens stained with calretinin.<sup>21</sup>

A diagnostic test has a high value if the sensitivity and specificity is  $\geq 90\%$ .<sup>22</sup> The sensitivity, specificity, PPV, and NPV were 87.5%, 40%, 90%, and 42% respectively. Other results of anti-*H. pylori* IgG in urine in other countries can be found in Table 7.

The sensitivity of the RSI in this research was 87.5%, which is considered adequate for the initial screening of a disorder or a disease. In general, previous research that assessed the accuracy of RSI resulted in adequate sensitivity, but some argued that the sensitivity is better as the patient ages because the older the patient, the more visible the transition zone. The research based on age groups conducted by Garcia *et al.*<sup>7</sup> showed that the highest sensitivity value was found in the group of above 1-month old patients. However, transition zones that indicate HD are not always present in HD cases. Rosenfield *et al.*<sup>23</sup> discovered that the transition zone is not found in the radiology imaging in HD-positive cases, RSI shows positive results in 32 of 42 patients (72%), and positive cases are more frequently found in children than neonatal subjects.

This research has low specificity, which was only 40%. It suggests that the RSI in the barium enema examination is not good enough to be used to diagnose HD, which may lead to inaccurate management and unwanted outcome, such as discomfort and disappointment of patients, the need of further tests, and the use of unnecessary resources and additional costs.<sup>24</sup>

The PPV and NPV in the RSI evaluation were 90%

and 33% respectively. It means that the subject has 90% probability to suffer from *H. pylori* infection if the test result is positive. Conversely, the subject has 33% probability to not suffer from the disease if the test result is negative.

Likelihood ratio is also a determining value of a diagnostic test. The higher the LR (positive), the more accurate the test in diagnosing which subject is ill and which is not.<sup>22</sup> This research resulted in the LR (positive) value of 1.45. Although it is greater than 1, the LR value is insignificant. LR value is significant if the difference is 10 or higher.<sup>22</sup>

The evaluation of RSI in barium enema examinations can show false negative and false positive results. False negative results in this research may have been caused by the failure to visualize the transition zone in the barium enema examinations due to various factors, such as the inaccurate procedure during rectal washout and inaccuracy in reading or interpreting the imaging results. In certain cases, the causes can be the unclear visualization of the total aganglionic and long HD segments, as well as transition zones. In fact, transition zones are not found at all. Some research emphasized that the transition zone is more visible as the patient ages. In infants under 1-month old with delayed meconium passage of over 24 hours and several cases, the transition zone does not appear (Garcia *et al.*, 2013).

On the other hand, false positive results in this research may have been caused by other factors that resulted in the imaging of transition zones in the reading of barium enema examination. Some of them are meconium plug, microcolon, and colonic atresia and stenosis.<sup>25</sup>

## Conclusion

It can be concluded that the evaluation of RSI in the barium enema examinations had adequate sensitivity, but it had low specificity, so it cannot be used as the sole diagnostic tool in the diagnosis of HD. The high positive predictive value indicates that if the test result is positive, it can be used as the basis of a more specific examination, namely rectal biopsy. Further prospective research involving more subjects of certain age groups is necessary to obtain results with good accuracy.



**Conflict of Interest :** None declared.

**Source of Funding :** The authors received no specific grants from any funding agency in the public, commercial, or not-for-profit sectors.

**Ethical Clearance :** Approved by researched ethical committee Dr. Soetomo General Hospital Surabaya No: 1787/KEPK/I/2020.

### References

1. Klein MD, Coran AG, Drongowski RA. Hirschsprung's disease in the newborn. *J Pediatr Surg.* 1984;19(370).
2. Best KE, Addor M-C, Arriola L, et al. Hirschsprung's disease prevalence in Europe: a register based study. *Birth Defects Res Part A Clin Mol Teratol.* 2014;100(695).
3. Emison ES, McCallion AS, Kashuk CS, et al. A common sex-dependent mutation in a RET enhancer underlies Hirschsprung disease risk. *Nature.* 2005;434(857).
4. Moore SW, Zaahl M. Clinical and genetic differences in total colonic aganglionosis in Hirschsprung's disease. *J Pediatr Surg.* 2009;44(1899).
5. Yaddav T, Usha K, Kanishka D, Mohanty S, Puttegowda D. Calretinin immunohistochemistry versus rapid improvised acetylcholinesterase histochemistry in the evaluation of colorectal biopsies for Hirschsprung Disease. *West Indian Med J.* 2014;17:2171-2178.
6. Taxman TL, Yulish BS, Rothstein FC. How useful is the barium enema in the diagnosis of infantile Hirschsprung's disease? *Am J Dis Child.* 1986;9140:9881-9884.
7. Garcia R, Arcement C, Hormaza L, et al. Use of the recto-sigmoid index to diagnose Hirschsprung's disease. *Clin Pediatr Philadelphia.* 2007;46:59-65.
8. Chirdan LB, Uba AF. Hirschsprung's disease presenting in the neonatal period in Jos, Nigeria. *Niger J Surg Res.* 2006;8(1):55-59.
9. Izadi M, Mansour-ghanaei F, Jafarshad R, Farahnaz J, Bagherzadeh AH, Tareh F. Clinical manifestations of Hirschsprung's disease: A 6-year course review on admitted patients in Guilan, north Province of Iran. *Middle East J Dig Dis.* 2009;1(2):68-73.
10. Mabula JB, Kayange NM, Manyama M, Chandika AB, Rambau PF, Chalya PL. Hirschsprung's disease in children: a five year experience at a University teaching hospital in northwestern Tanzania. *BMC Res Notes.* 2014;7(410).
11. Rahman Z, Hannan J, Islam S. Hirschsprung's disease: Role of rectal suction biopsy. *J Indian Assoc Pediatr Surg.* 2010;15(2):56-58.
12. Vincent M, Jackson S. Hirschsprung disease in Barbados a 16 years review. *West Indian Med J.* 2009;58:347-351.
13. Ziad F, Katchy KC, Ramadan S Al, Alexander S, Kumar S. Clinicopathological features in 102 cases of Hirschsprung disease. *Ann Saudi Med.* 2006;26(3):200-204.
14. Baxter J, Bathia M. Hirschsprung disease in preterm infant : implication for diagnosis and outcome. *Am J Surg.* 2013;79(7):734-738.
15. Anbardar MH, Geramizadeh B, Foroutan HR. Evaluation of Calretinin as a New Marker in the Diagnosis of Hirschsprung Disease. *Iran J Pediatr.* 2015;25(2):367.
16. Granéli C, Dahlin E, Börjesson A, Arnbjörnsson E, Stenström P. Diagnosis, Symptoms, and Outcomes of Hirschsprung's Disease from the Perspective of Gender. *Surg Res Pract.* 2017;208:34-38.
17. Khan AR, Vujanic GM, Huddart S, Drongowesky RA. The constipated child: how likely is Hirschsprung's disease? *Pediatr Surg Int.* 2003;19(6):439-442.
18. Puri P. *Hirschsprung's Disease and Variants in: Pediatric Surgery.* London: Springer; 2009.
19. Yin H, Boyd T, Pacheco MC, Schonfeld D, Bove KE. Rectal biopsy in children with Down syndrome and chronic constipation: Hirschsprung disease vs non-hirschsprung disease. *Pediatr Dev Pathol.* 2012;15(2):87-95.
20. Kessmann J. Hirschsprung's disease: diagnosis and management. *Am Fam Physician.* 2006;74(8):1319-1322.
21. Hiradfar M, Sharifi N, Khajedaluee M, Zabolnejad N, Taraz S, Al. E. Calretinin Immunohistochemistry: Aid in the Diagnosis of Hirschsprung's Disease. *Iran J Basic Med Sci.* 2012;15:1053-1059.
22. Puspongoro HD, Wirya IGN, Pudjiadi AH, Al. E. Uji diagnostik. In: *Dasar-Dasar Metodologi Penelitian Klinis.* 4th ed. Jakarta: CV Sagung Seto; 2011:219-244.

23. Rosenfield NS, Ablow RC, Markowitz RI. Hirschsprung disease: Accuracy of the barium enema examination. *Radiology*. 1984;9150:9393-9400.
24. Sastroasmoro S, Ismael S. *Dasar-Dasar Metodologi Penelitian Klinis*. 4th ed. Jakarta: CV Sagung Seto; 2011.
25. Carroll AG, Kavanagh RG, Leidhin CN, Cullinan NM, Lavelle LP, Malone DE. Comparative Effectiveness of Imaging Modalities for the Diagnosis of Intestinal Obstruction in Neonates and Infants: A Critically Appraised Topic. *Acad Radiol*. 2016;23(5):559-568.