

Treatment Evaluation of Odontogenic Keratocyst by Using CBCT and Fractal Dimension Analysis on Panoramic Radiograph

Eha Renwi Astuti, Ni Putu Mira Sumarta¹, Ramadhan Hardani Putra, Berty Pramatika

Departement of Dentomaxillofacial Radiology and ¹Oral and Maxillofacial Surgery, Faculty of Dental Medicine, Universitas Airlangga, Surabaya, Indonesia

Abstract

The odontogenic keratocyst (OKC) is a benign intraosseous lesion that derives from remnants of the dental lamina. General practitioners usually use panoramic radiograph and cone-beam computed tomography (CBCT) as radiography examination of a suspected OKC lesion in the mandible or maxilla. Evaluation of post marsupialization could be assessed by using fractal dimension (FD) analysis of trabecular bone in panoramic radiograph and CBCT. In the present case, we use panoramic radiograph and CBCT for the treatment evaluation of OKC. The aim of this case report is to describe a case of OKC and evaluation of treatment progress by using FD analysis on panoramic radiograph and CBCT. A 40-year-old female patient came with a complaint of slowly enlarged swelling on the left mandible for 10 years. Low-grade pain occasionally happened to that women. Panoramic radiographs revealed multi-locular radiolucency extending from anterior of the mandible body to ascending ramus. Coronoid and condyloid process, and inferior border of the mandible were intact. OKC was confirmed based on biopsy of the lesion from extraction site of left lower third molar tooth. We did marsupialization from tooth extraction socket and let it open as a window to apply obturator. The researchers did a serial panoramic radiograph to evaluate treatment, showing reduction of radiolucency size and increasing of FD in lesion peripheral, it means that there was an osseous healing process. One year after marsupialization, the researchers did CBCT examination to evaluate bone regeneration and density. The result of CBCT showed the size reduction of the lesion in sagittal, coronal, and axial planes. CBCT also revealed bone formation from the periphery of the lesion. CBCT assessment and FD analysis of trabecular bone on panoramic radiograph is a reliable imaging method for the treatment evaluation of OKC and determination of ossification as well.

Keywords: Cone-beam computed tomography, marsupialization, odontogenic keratocyst, panoramic radiograph

INTRODUCTION

Odontogenic keratocyst (OKC) is an odontogenic lesion derived from remnant of dental lamina, traumatic implantation, or down growth of the basal cell layer of the surface epithelium, reduced enamel epithelium of the dental follicle.^[1,2] OKC has clinical and histopathology characteristic that is different from other cystic lesions because of its aggressive behavior and high recurrence rate.^[1,3] Philipsen used the term OKC in 1956.^[4] Pindborg and Hansen first described OKC characteristic in 1963.^[5] In 1971, WHO classified OKC into developmental odontogenic cyst groups. In 2005, World Health Organization (WHO) classified these lesions as keratocystic odontogenic tumors (KCOT) because of its neoplastic nature. Recently, in 2017, WHO reclassified KCOT to the original terminology OKC.^[6]

The prevalence of OKC was about 11% of all mandibular cysts and it had predominance in male (55.7%) than female.^[7,8]

OKC occurred mainly in the second and fourth decade of life and it was more common in mandible than that of in maxilla at an approximately 2:1 ratio.^[7,9] Clinically, OKC did not show a specific characteristic. Some studies reported that 37.2% of patients presented with symptoms and 62.8% were asymptomatic.^[10] The asymptomatic OKC was usually found accidentally in routine radiography examination. Radiographically, the OKC was characterized as well-defined,

Address for correspondence: Dr. Eha Renwi Astuti,
Department of Dentomaxillofacial Radiology, Faculty of Dental
Medicine, Universitas Airlangga, Prof. Dr. Moestopo Street No. 47,
Surabaya - 60132, Indonesia.
E-mail: eha-r-a@fkg.unair.ac.id

This is an open access journal, and articles are distributed under the terms of the Creative Commons Attribution-NonCommercial-ShareAlike 4.0 License, which allows others to remix, tweak, and build upon the work non-commercially, as long as appropriate credit is given and the new creations are licensed under the identical terms.

For reprints contact: reprints@medknow.com

How to cite this article: Astuti ER, Mira Sumarta NP, Putra RH, Pramatika B. Treatment evaluation of odontogenic keratocyst by using CBCT and fractal dimension analysis on panoramic radiograph. *J Indian Acad Oral Med Radiol* 2019;31:391-6.

Received: 23-07-2019 **Revised:** 31-08-2019

Accepted: 18-11-2019 **Published:** 03-03-2020

Access this article online

Quick Response Code:



Website:
www.jiaomr.in

DOI:
10.4103/jiaomr.jiaomr_138_19

uni-locular or multi-locular, radiolucent lesion with smooth and sclerotic margins.^[11]

The treatment choice of OKC depended on the lesion size, location, continuity border of the mandible, and its relation to vital structure. General practitioners preferred doing enucleation if the lesion was close to the vital structure and the lining cyst could be easily separated from its bone attachment. They preferred doing marsupialization if the large cyst involved vital structure and apices of many adjacent teeth. Marsupialization was performed to reduce the cyst size and preserved the adjacent structures.^[12-14]

Radiography examination had an important role to make a diagnosis, treatment planning, and post-treatment evaluation. We usually use conventional radiography (i.e., panoramic radiograph), Ct-scan, MRI, and cone-beam computed tomography (CBCT)-scan for radiography examination of a suspected OKC lesion in the mandible or maxilla.^[1,15] Panoramic radiograph was the most frequently used to examine jaw lesion. It was usually adequate for initial assessment of the OKC, treatment planning, and widely used to evaluate treatment progress.^[15] Panoramic radiograph could be used to identify trabecular bone complexity and local bone quality. Some research studies showed that fractal dimension (FD) analysis was an assessment method that reflected trabecular bone micro-architecture, and it was a noninvasive method to detect and quantify changes in alveolar process bone mineral content.^[16,17]

Nowadays, cone beam computed tomography (CBCT) is a medical imaging technique that is popular in treatment planning and diagnosing in oral and maxillofacial diseases.^[15] A major advantage of CBCT that has been reported is the three-dimensional geometric accuracy compared with conventional radiographs. Besides, the advantages of this technique are relatively high isotropic spatial resolution of osseous structures with a reduced radiation dose and low cost compared to conventional computed tomography (CT) scans.^[15,18]

The aim of this case report is to describe a case of OKC and evaluation of treatment progress by using FD analysis on panoramic radiograph and CBCT.

CASE REPORT

A 40-year-old female patient came with a chief complaint of slowly enlarged swelling on the left mandible for 10 years. Low-grade pain occasionally happened to the women and pus drained from marginal gingiva of left third molar tooth appeared. There was no numbness on the lower lip. Extraoral examination revealed a hard mass with diffuse border in the left mandible, extending to lingual border of mandible and nontender. Intraoral examination revealed a hard mass in the extending position from anterior to posterior region, in lingual region. Left lower third molar tooth was mobile and pus was coming out from marginal gingiva. Panoramic

radiographs revealed multi-locular radiolucency extending from anterior portion of the mandible body to ascending ramus. The lesion size was about 36.38 mm × 110.67 mm. The lesion caused depression on the mandibular canal, first molar apical resorption and depletion of the mandibular inferior border. The radiograph showed an expansion mandibular body and mandibular ramus. Coronoid process, condyloid process, and inferior border of mandible were intact, as shown in Figure 1.

We reconfirmed OKC based on biopsy of the lesion from extraction site of left lower third molar tooth. We did marsupialization from tooth extraction socket and let it open as a window to apply obturator. We used serial panoramic radiograph to evaluate treatment progress [Figures 2-4] and fractal analysis was used to evaluate the osseous healing process in a serial panoramic radiograph. We obtained panoramic radiograph by using a panoramic X-ray unit Villa Rotograph Evo at 70 Kvp, 12 mA. All procedures for calculation of the FD were performed by using Image J software. We selected ROI as 60 × 60 pixel-sized squares located between canine and first premolar teeth, and mandibular ramus of the right-left mandibular segment. We chose the ROI location based on the theory that the new bone formation was started in the cyst periphery.^[19] Assessment of FD in the right side was to describe normal FD value of the mandibular. The result of FD measurement showed that there was an increasing FD from 3 months after marsupialization until 11 months after marsupialization and it means that there was an osseous healing process [Table 1]. The FD values in 11-month post marsupialization were close to the normal FD values on the right side.

One year after marsupialization, the researcher did CBCT to evaluate bone regeneration and density. CBCT images with 6 × 8 cm dimension of Field of View (FOV) were acquired

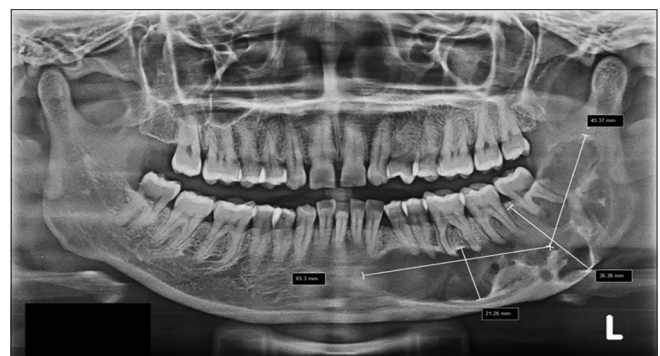


Figure 1: Preoperative panoramic radiograph

Table 1: Result of FD calculation

	Right side	Preoperative	3 months	8 months	11 months
FD mandibular ramus	1.4616	1.2692	1.2017	1.2674	1.316
FD P1 region	1.3292	1.2338	1.0610	1.2660	1.3023

with Instrumentarium OP300 with exposure settings of 90 kVp, 10 mA, and 13.8 s. CBCT showed irregular shape and size reduction of the radiolucency that extended from premolar region to the third molar region. CBCT result showed a ground-glass appearance in cyst periphery. The dimension of the lesion was measured from largest diameter in sagittal, axial, and coronal planes. Anteroposterior (sagittal planes), superoinferior (coronal planes), and bucco-lingual (axial planes) dimensions of the lesions were 54,20 × 23,79 × 7,90 mm as shown in Figure 5. CBCT also revealed bone formation from the periphery of the lesion. Bone profile measurement was performed in the anterior site of the lesion, which bone formation could be seen clearly. The result of the bone profile measurement in sagittal plane was 631.3-pixel values as shown in Figure 6. Cross-sectional image analysis was also performed to see the bucco-lingual bone formation of the lesion as shown in Figure 7. The average of bone profile measurement in axial plane was 769.7 pixel value as shown in Figure 8. The patient was suggested to return periodically in order to follow-up the treatment with clinical and radiographic examinations.

DISCUSSION

OKC was from the remnant of the dental lamina. Some research studies showed that OKC was caused by mutation of suppressor tumor gene such as p16 (75%), p53 (66%), PTCH (60%), and MCC (60%).^[20] OKC developed along the

cancellous bone. Hence, it caused minimal expansion on buccal cortical bone. This phenomenon was caused by intraluminal hyperosmolality, active epithelial proliferation, collagenolytic activity of the cyst wall, and synthesis of interleukin 1 and 6 by keratinocytes.^[21-23]

Based on Jankowski and Sumer research, KCOT clinical appearance showed differences among ethnic group. Swelling and pain happened to East Asians more frequently than those of other races, whereas OKC discovered as an incidental finding happened more frequently to Western community.^[24,25] In the present case, the OKC causes an unusual clinical sign of buccal cortical expansion in the lingual region despite its small size.

The treatment decisions were based on the age and health of the patients, lesion sizes, location of the lesion, involvement of the cortical bones, and the presence of important anatomical structures in close proximity to the lesion. Surgical treatment of OKC was resection, curettage, and marsupialization to reduce the size of the lesion. General practitioners suggested that the patients do a follow-up therapy once in 6 months to monitor the patients for any signs of recurrence which could develop

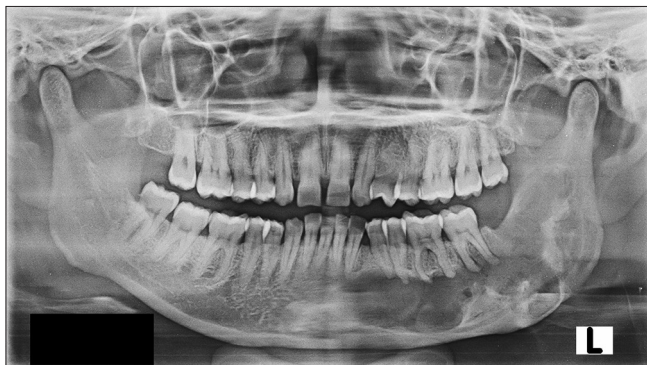

Figure 2: 3-month postoperative panoramic radiograph, showed increasing radiopacity within the lesion, especially in the ascending ramus

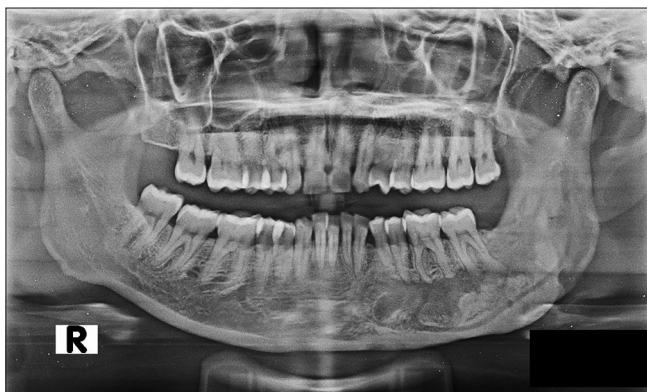

Figure 4: 11-month postoperative panoramic radiograph

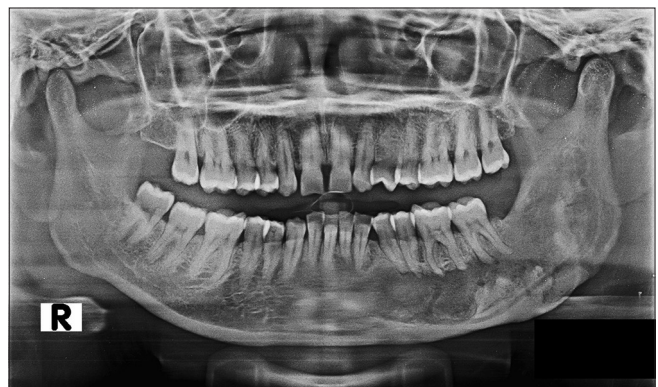

Figure 3: 8-month postoperative panoramic radiograph, showed increasing radiopacity within the lesion

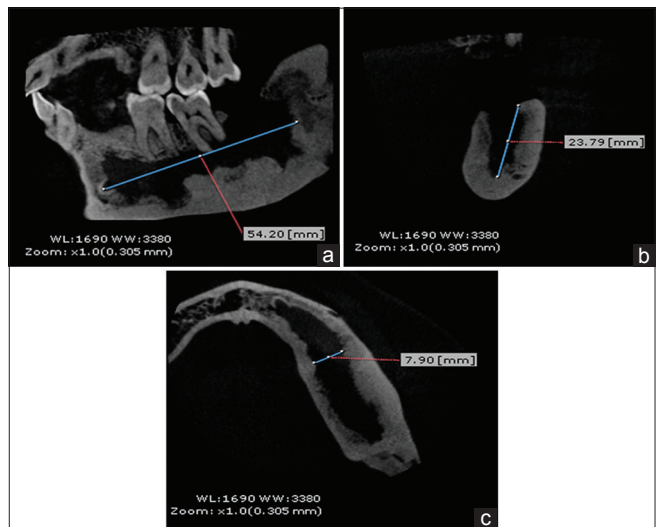


Figure 5: Measurement of the lesion size in (a) sagittal, (b) coronal, and (c) axial planes

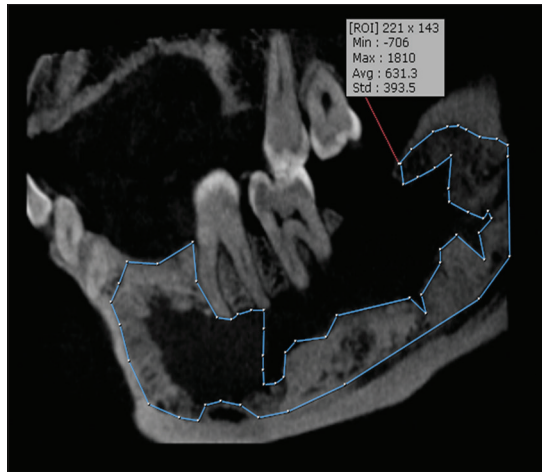


Figure 6: Sagittal view, bone formation analysis in the anterior site of the lesion

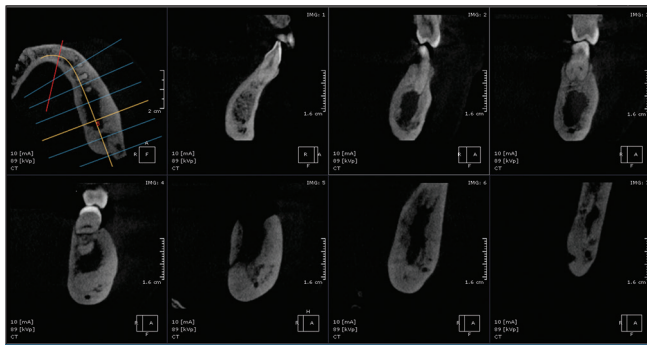


Figure 7: CBCT coronal view cross-sectional images

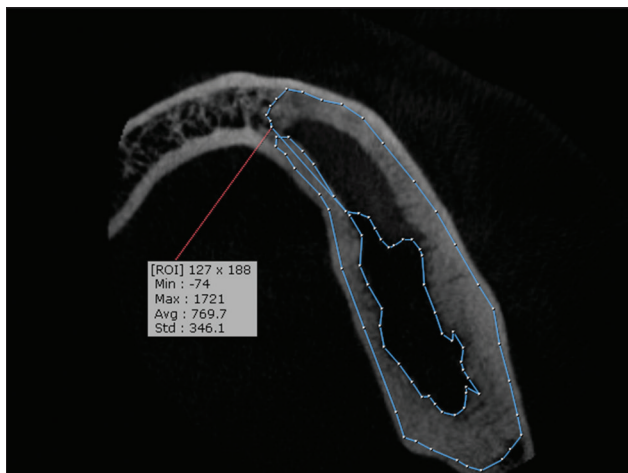


Figure 8: Axial slice of the lesion 1 year after marsupialization

within the first 5 years or delayed to 10 years. Marsupialization was a surgical technique by creating a window in cyst wall that was connected to the cyst and the oral cavity. Marsupialization treatment of OKC remained controversial; some researchers did not recommend marsupialization as an OKC treatment, because the recurrence was high. However, some researchers recommended this therapy to handle big size OKC because this technique could reduce the lesion size; therefore, the

surrounding vital structure (i.e., teeth, mandibular canal) did not have destruction.^[6,13,26] When OKC was open and connected to oral cavity, there were changes happened to wall cyst. Some research results showed that after marsupialization, the cyst wall became thicker, and we could do enucleation easily. Histologically, cyst walls were changed into normal oral mucous tissues.^[27]

The radiography examination is important to determine OKC diagnose, treatment planning, and evaluation post-surgery. OKC is characteristic radiographic features such as a radiolucent lesion with corticated and scalloped border, minimal expansion, especially toward medial side, and growth along the internal aspect of the mandibular or maxilla bone. Usually, the lesion causes displacement of the adjacent teeth, resorption of the adjacent teeth roots, extrusion of erupted teeth, and it has an association with the impacted teeth.^[11] This radiograph characteristic was shown in this case. In the present case, the lesion causes malposition of 35 teeth, 36 apical root resorption, but it does not have any relationship with impacted tooth.

Radiography modality that could be used to evaluate lesion was conventional radiography (i.e., panoramic radiograph, periapical radiograph) and 3D imaging (i.e., CT scan, CBCT, and MRI). Panoramic radiography was useful imaging method which is widely used in the practice of dentistry offering low cost and low dose of radiation. Radiographic examination was non-surgery examination to detect ossification post-surgery.^[28,29] Radiographically, OKC post-surgery ossification showed an increasing radiopacity of the lesion and there was a size reduction of the lesion. Our present case showed that there was an increasing radiopacity on panoramic radiograph of a 3-month post-surgery until 11-month post-surgery.

Fractal analysis was a method to quantify a complex bone structure based on variation pixel intensity an image. We use FD in dentistry to evaluate and quantify trabecular bone changes, i.e., periapical lesion evaluation, periodontitis healing evaluation, post bone surgery evaluation, and systemic disease evaluation. FD measurement described bone architecture change and bone density, and the big FD value describes complex bone architecture with dense bone trabecular and a few porous.^[30,31]

Some researchers suggested that panoramic radiographic images be useful to assess trabecular bone characteristics. Heo *et al.* stated that fractal analysis could be used as a reliable and effective method for the quantitative evaluation of the osseous healing process on the radiographs.^[32-35] FD measurement, in this case, showed an increasing FD value in 3-month post-surgery until 11-month post-surgery; it showed that there were bone architecture changes and ossification post-surgery.

In addition to evaluate the efficiency of marsupialization, we used 3D-CBCT. CBCT was a better imaging modality which could be used for an assessment to evaluate cysts and benign tumors. It offered a real-size data set with multi-planar cross-sectional and 3D reconstructions, which were based

on a single scan. We could investigate the internal structures of the pathologic lesions by using low-radiation doses.^[36] Multi-planar sections (axial, coronal, and sagittal planes) were required when cysts and tumors were located deeply in the tissues. CBCT was also helpful in post-surgical follow-ups of lesions that may have high recurrences, because it offered accuracy in measurement, absence of image distortion, and accuracy the border of the lesion.^[36,37]

We could see the bone regeneration post-marsupialization on the cyst outline that showed volume partial reduction and mandibular canal recovery. The new bones formed in cyst periphery showed a ground-glass appearance and radial bone spiculae.^[19,29] Based on the previous case above, CBCT was used to evaluate OKC one year after marsupialization. CBCT showed a ground-glass appearance in cyst periphery, and it means that there was a new bone formation in cyst. Furthermore, CBCT showed reducing size of the lesion, after 1 year of post-surgery with the lesion size as big as 54.2 mm × 23.79 mm × 7.90 mm. Because of our CBCT machine had limited FOV, it was about 6 × 8 cm dimension of FOV, we could not measure the lesion size in mandibular ramus. Based on the result of panoramic radiograph and CBCT, we believed that marsupialization was an effective treatment method for the large OKC lesion and the OKC that involved vital structure (i.e., mandibular canal).

CONCLUSION

Marsupialization is an effective treatment for the large OKC lesion, particularly for the lesion that involves the vital structure. Radiography examination has an important role to evaluate the treatment progress of OKC. In our present case, panoramic radiograph by using FD analysis and CBCT is a reliable imaging method for the treatment evaluation of OKC and determination of ossification as well.

Declaration of patient consent

The authors certify that they have obtained all appropriate patient consent forms. In the form the patient(s) has/have given his/her/their consent for his/her/their images and other clinical information to be reported in the journal. The patients understand that their names and initials will not be published and due efforts will be made to conceal their identity, but anonymity cannot be guaranteed.

Financial support and sponsorship

Nil.

Conflicts of interest

There are no conflicts of interest.

REFERENCES

- Eryilmaz T, Ozmen S, Findikioglu K, Kandal S, Aral M. Odontogenic keratocyst: An unusual location and review of the literature. *Ann Plast Surg.* 2009 Feb; 62(2):210-2.
- Hyun HK, Hong SD, Kim JW. Recurrent keratocyst odontogenic tumor in the mandible: A case report and literature review. *Oral Surg Oral Med Oral Pathol Oral Radiol Endod* 2009;108:e7-10.
- Gumusok M, Alkurt MT, Museyibov F, Ucok O. Evaluation of keratocyst odontogenic tumors using cone beam computed tomography. *J Istanbul Univ Fac Dent* 2016;50:32-7.
- Pindborg JJ, Philipsen HP, Henriksen J. Studies on odontogenic cyst epithelium. In: Sognnaes RF, editor. *Fundamentals of Keratinization.* Washington, DC: American Association of the Advancement of Science; 1962. p. 151-60.
- Pindborg JJ, Hansen J. Studies on odontogenic cyst epithelium. 2. Clinical and roentgenologic aspects of odontogenic keratocysts. *Acta Pathol Microbiol Scand* 1963;58:293-94.
- Passi D, Singhal D, Singh M, Mishra V, Panwar Y, Sahni A. Odontogenic keratocyst (OKC) or keratocyst odontogenic tumor (KCOT) – Journey of OKC from cyst to tumor to cyst again: Comprehensive review with recent updates on WHO classification (2017). *Int J Curr Res* 2017;9:54080-6.
- Sharif FN, Oliver R, Sweet C, Sharif MO. Intervention for the treatment of keratocyst odontogenic tumours (KCOT, odontogenic keratocyst (OKC)). *Cochrane Database Syst Rev* 2010;8:CD008464.
- Ramachandra S, Shekar PC, Prasad S, Kumar KK, Reddy GS, Prakash KL, *et al.* Prevalence of odontogenic cyst and tumors: A retrospective clinic pathological study of 204 cases. *SRM J Res Dent Sci* 2014;5:170-7.
- Chirapathomsakul D, sastravaha P, Jansisyantont P. A review of odontogenic keratocyst and the behavior of recurrences. *Oral Surg Oral Med Oral Pathol Oral Radiol Endod* 2006;101: 5-9; discussion 10.
- Boffano P, Ruga E, Gallesio C. Keratocystic odontogenic tumor (odontogenic keratocyst): Preliminary retrospective review of epidemiologic, clinical, and radiologic features of 261 lesions from University of Turin. *J Oral Maxillofac Surg* 2010;68:2994-9.
- White SC, Pharoah MJ. *Oral Radiology: Principles and Interpretation.* 7th ed. Missouri: Mosby; 2014. p. 343-5.
- Soliman MM, Hassan MA, Elgazaerly H, Sweedan TO. Marsupialization as a treatment modality of large jaw cysts. *World Appl Sci JWorld* 2013;21:1752-9.
- Zhao Y, Liu B, Cheng G, Wang SP, Wang YN. Recurrent keratocyst odontogenic tumours: Report of 19 cases. *Dentomaxillofac Radiol* 2012;41:96-102.
- Ecker J, Horst RT, Koslovsky D. Current role of Carnoy's solution in treating keratocystic odontogenic tumors. *J Oral Maxillofac Surg* 2016;74:278-82.
- Banik S, Samir B, Shaikh MH, Sadat SM, Mallick PC. Keratocystic odontogenic tumor and its radiological diagnosis by 3 dimensional Cone beam computed tomography (CBCT). *Update Dent Coll J* 2011;1:10-3.
- Watanabe PC, De Faria LM, Issa JP, Monteiro SA, Tioffi R. Morphodigital evaluation of the trabecular pattern in the mandible using digitized panoramic and periapical radiograph. *Minerva Stomatol* 2009;58:73-80.
- Demirbaş AK, Ergün S, Güneri P, Aktener BO, Boyacıoğlu H. Mandibular bone changes in sickle cell anemia: Fractal analysis. *Oral Surg Oral Med Oral Pathol Oral Radiol Endod* 2008;106:e41-8.
- Berberoğlu HK, Sirmahan Ç, Amila B, Banu GK, Barış AA, Cengizhan K. Three-dimensional cone-beam computed tomography for diagnosis of keratocystic odontogenic tumours; Evaluation of four cases. *Med Oral Patol Oral Cir Bucal* 2012;17:1000-5.
- Bodner L, Bar-Ziv J. Characteristic of bone formation following marsupialization of jaw cysts. *Dentomaxillofac Radiol* 1998;27:166-73.
- Agaram NP, Collins BM, Barnes L, Lomago D, Aldeeb D, Swalsky P, *et al.* Molecular analysis to demonstrate that odontogenic keratocysts are neoplastic. *Arch Pathol Lab Med* 2004; 128:313-7.
- Menon S. Keratocystic odontogenic tumours: Etiology, pathogenesis and treatment revisited. *Arch Pathol Lab Med* 2015;14:541-7.
- Barnes L, Eveson JW, Reichart P, Sidransky D. editors. *Pathology and Genetics of Head and Neck Tumours.* WHO Classification of Tumour Series. Lyon: IARC Press; 2005.
- Cohen MM Jr. Nevoid basal cell carcinoma syndrome: Molecular biology and new hypotheses. *Int J Oral Maxillofac Surg* 1999;28:216-23.
- MacDonald-Jankowsky DS. Keratocyst odontogenic tumour: Systematic review. *Dentomaxillofac Radiol* 2011;40:1-23.
- Sumer AP, Sumer M, Celenk P, Danaci M, Gunhan O. Keratocystic

- odontogenic tumor: Case report with CT and ultrasonography findings. *Imaging Sci Dent* 2012;42:61-4.
26. Abdullah WA. Surgical treatment of keratocystic odontogenic tumour: A review article. *Saudi Dent J* 2011;23:61-5.
 27. Pogrel MA. Treatment of keratocyst: The case for decompression and marsupialization. *J Oral Maxillofacial Surg* 2005;63:1667-73.
 28. Zhao Y, Liu B, Han QB, Wang SP, Wang YN. Changes in bone density and cyst volume after marsupialization of mandibular odontogenic keratocysts (keratocyst odontogenic tumors). *J Oral maxillofacial Surg* 2011;69:1361-6.
 29. Soltan A. Volume reduction of maxillary and mandibular cystic lesions after marsupialization: A computerized three-dimensional computed tomographic evaluation. *Proceeding of 54th ISERD International Conference, Singapore, 2016.* p. 19-25.
 30. Kavitha MS, An SY, An CH, Huh KH, Yi WJ, Heo MS, *et al.* Texture analysis of mandibular cortical bone on digital dental panoramic radiographs for the diagnosis of osteoporosis in Korean women. *Oral Surg Oral Med Oral Pathol Oral Radiol* 2015;119:346-56.
 31. Arsan B, Köse TE, Çene E, Özcan I. Assessment of the trabecular structure of mandibular condyles in patients with temporomandibular disorders using fractal analysis. *Oral Surg Oral Med Oral Pathol Oral Radiol* 2017;123:382-91.
 32. Lee DH, Ku Y, Rhyu IC, Hong JU, Lee CW, Heo MS, *et al.* A clinical study of alveolar bone quality using fractal dimension and the implant stability quotient. *J Periodontal Implant Sci* 2010;40:19-24.
 33. Alman AC, Johnson LR, Calverley DC, Grunwald GK, Lezotte DC, Hokanson JE. Diagnostic capabilities of fractal dimension and mandibular cortical width to identify men and women with decreased bone mineral density. *Osteoporos Int* 2012;23:1631-6.
 34. Sogur E, Baksi G, Grondahl HG, Sen BH. Pixel intensity and fractal dimension of periapical lesions visually indiscernible in radiographs. *J Endod* 2013;39:16-9.
 35. Heo MS, Park KS, Lee SS, Choi SC, Koak JY, Heo SJ, *et al.* Fractal analysis of mandibular bony healing after orthognatic surgery. *Oral Surg Oral Med Oral Pathl Oral Radiol Endodontic* 2002;94:763-7.
 36. Prabhusankar K, Yuvaraj A, Prakash CA, Parthiban J, Praveen B. CBCT cyst leasions diagnosis imaging mandible maxilla. *J Clin Diagn Res* 2014;8:ZD03-5.
 37. Macdonald-Jankowski DS. Focal cemento-osseous dysplasia: A systematic review. *Dentomaxillofac Radiol* 2008;37:350-60.