

The quality of the lollipops use in the making of the anterior upper teeth periapical radiography of in paediatric patients

by Eha Astuti

Submission date: 03-Nov-2020 02:44PM (UTC+0800)

Submission ID: 1434778354

File name: g-of-the-anterior-upper-teeth-periapical-radiography-of-8047.pdf (394.74K)

Word count: 3348

Character count: 19530



The quality of the lollipops use in the making of the anterior upper teeth periapical radiography of in paediatric patients

A P W Monika ¹, Eha Renwi Astuti ^{1*}, Sri Wigati Mardi Mulyani ¹

¹ Department of Radiology, Faculty of Dental Medicine, Universitas Airlangga, Surabaya, INDONESIA

*Corresponding author: eha-r-a@fkg.unair.ac.id

Abstract

Background: Periapical radiography is a technique that is routinely used in the field of dental radiology. Deficiencies in this procedure require patient cooperation, especially paediatric patients and during the procedure of making radiographs of intraoral film placement. Poor co-operability of paediatric patients has great potential to cause periapical radiographic failure. Vomiting reflexes are the most commonly reported complaints in children where one of the triggers for vomiting reflexes is in the palate which can affect the taking of periapical radiographs of the maxilla. The use of lollipop aids is one of the desensitization methods to overcome the problem of child cooperation during periapical radiography. **Objective:** To determine the quality of periapical radiographs of maxillary anterior teeth in paediatric patients using lollipops. **Methods:** This study used an experimental analytic study by taking periapical radiographs using lollipops and without assistive devices for paediatric patients. The lollipop used is made from tamarind candy (licensed by the Republic of Indonesia Food and Drug Supervisory Agency) which is melted and packaged into lollipops. This study has 52 samples and for each sample periapical radiography was taken by using a lollipop tool or not using a device, hence 26 radiographs were obtained for each technique. Periapical radiography was observed visually by three observers and then the observer filled the radiographic quality evaluation indicator table to obtain a score of quality evaluation results for each periapical radiography. **Results:** There were significant differences in quality evaluation results between periapical radiographs taken by using lollipops and without assistive devices (p-value 0.008). **Conclusion:** The quality of the maxillary anterior periapical radiographs of paediatric patients made using lollipops is better than without using aids.

Keywords: periapical radiography; cooperative children; radiographic quality evaluation; lollipop

Monika APW, Astuti ER, Mulyani SM (2020) The quality of the lollipops use in the making of the anterior upper teeth periapical radiography of in paediatric patients. Eurasia J Biosci 14: 4049-4053.

© 2020 Monika et al.

This is an open-access article distributed under the terms of the Creative Commons Attribution License.

INTRODUCTION

Radiographic examination is one of the supporting examinations that has a very important role in the field of dentistry. The role of dental radiography includes assisting dentists to conduct examinations, establish diagnoses, and arrange appropriate care management. Almost all dental and oral care requires radiographic examination support data thus the treatment performed achieves optimal results. This is because a radiographic examination can see abnormalities and tissue conditions that cannot be seen clinically. In order to fulfil radiographic data, good radiographic results are needed and can be interpreted. Poor radiographic results have the potential to lead to incorrect interpretations and have an impact on diagnosis and treatment plans that are also less precise, therefore it is necessary to make radiographs with the right techniques thus the results are good.

Periapical radiography technique is a technique that is routinely used in the field of dental radiology. Periapical radiography provides a picture of the teeth and surrounding alveolar bone thus it can be important information in helping diagnose various dental abnormalities such as caries, periapical abscesses and periodontal bone loss (Gupta, et al. 2017) Even so, the practice of using periapical techniques in a clinical setting has deficiencies. Many people cannot tolerate intraoral film placement during periapical radiographic procedures (Reddy, et al. 2015) In order for radiograph results to be interpreted optimally and support diagnosis, operators need to know ways to influence patient cooperation during radiographic procedures, especially paediatric patients. According to the American Academy

Received: November 2019

Accepted: March 2020

Printed: October 2020

7 of Paediatric Dentistry (American Academy Of Pediatric Dentistry 2017), children are more potentially uncooperative so dental radiographs may fail. Paediatric patients who often undergo dental care are children of primary school age. According to the WHO (World Health Organization) definition of elementary school children, that is, the group of children aged between 7-15 years. Whereas in Indonesia usually elementary school children aged 7-12 years (Kantja, 2017). As already mentioned, periapical radiographic technique is an important technique in the radio-diagnose process of dental abnormalities. Previous studies explained that periapical radiography taking in children, 44% of radiographs failed, of which 32% could not be interpreted and the rest could still be interpreted (Salami et al. 2017). A large percentage of failures has an impact on suboptimal radiographic results or even fails to fulfil its function as a diagnostic support and treatment plan, so it needs to be reproduced. Radiographic remodelling causes the patient to receive more exposure. In fact, x-ray radiation exposure to the patient's body must be minimized and performed in conditions that are needed, especially for paediatric patients because children are more radiosensitive than adults (Looe, et al. 2006).

Failure in making a child intraoral radiography is difficult to be completely eliminated due to the child's cooperation during the manufacturing procedure. (Salami et al. 2017). Some things that can affect the child's low cooperative on dental radiographic procedures include jaws that are too small so uncomfortable during the procedure, fear of swallowing radiograph films, fear of the taking of the radiograph itself, and the gag reflex (Schwartz 2015). The gag reflex is the most commonly reported complaint in children. This is because children have a higher tendency to vomit than adults due to the progressive setback of the vomiting reflex as they age (Ardelean, Bortun, dan Motoc 2003). Five main regions that trigger vomiting reflexes are the base of the tongue, faucum, palate, uvula, and posterior pharyngeal wall (Prashanti et al. 2015).

Some modifications that can be conducted during the procedure for taking radiographs to minimize and overcome problems related to child cooperation, one of them is the use of lollipops for intraoral radiography (Schwartz 2015). This method uses lollipop as a desensitizing medium by gradually stimulating intraoral film contact in the oral environment. It is hoped that paediatric patients will be more comfortable and cooperative in the procedure. The principle of desensitization is to provide stimuli in stages from low to high intensity. The advantages of using this lollipop tool apart from the fact that children love sweets, candy is known to overcome nausea, especially sour taste candy (Kementrian Kesehatan Republik Indonesia (Kemenkes RI) dan World Food Programme (WPF) (2017). American Cancer Society (2017). The method of making

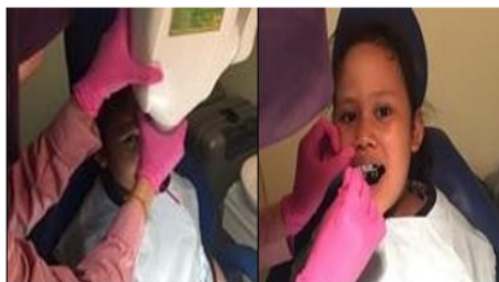

Fig. 1. Making periapical radiography using a lollipop tool

periapical radiographs of paediatric patients using a lollipop tool has never been studied at the Radiology Polyclinic of the Dental and Oral Hospital of Universitas Airlangga. Based on the background, it is necessary to conduct research to determine the quality of lollipop in the making of periapical radiographs of anterior teeth in children aged 7-12 years.

MATERIALS AND METHODS

The type of this study was experimental analytics. The samples studied were 52 samples, consisting of boys and girls aged 7 to 12 years with 26 children photographed periapical using a lollipop tool and 26 children photographed periapical without using tools. The experiment was conducted at the Dental and Oral Hospital of Universitas Airlangga, Surabaya. Before exposure, the researcher gave an oral and written explanation of the study procedure to the child's parents / guardians followed by the child's patient's guardian signing the consent form.

Furthermore, exposure was performed on each sample using lollipops or without tools. Lollipops serve as a tool for laying film / film holder by attaching periapical film using elastic ortho with a diameter of 1/4 inch in diameter. The lollipops in this study were made from sour taste candies (licensed by the Republic of Indonesia Food and Drug Supervisory Agency) which were melted and packed into lollipops. Both techniques with or without tools use the principle of bisecting angle.

RESULTS

The results of making anterior maxillary periapical radiography in paediatric patients obtained a radiographic percentage of 0 for both techniques with lollipop or without aids that was 0%. The percentage score of 1 for techniques without tools is 3.80% and for techniques using lollipop tools 0%. The percentage score of 2 for techniques without tools was 0% and for techniques using lollipop tools was 3.80%. The percentage score of 3 for techniques without tools was 42.30% and for techniques using a lollipop tool is 19.20%. The percentage score of 4 for techniques

Table 1. Table of Periapical Radiography Quality Evaluation Indicator

Quality Standard of Periapical Radiography	Score	Fulfilled (v) / Not fulfill (x)
The tooth picture has no foreshortening or elongation	1	
There is no horizontal overlap. If present, do not block the pulp / root canal	1	
All crowns and roots of teeth are covered	1	
2-3 mm Periapical bone is covered and can be observed to assess the anatomy of the apical area	1	
Total Score		

Note
 Fulfilled: Score 1 (one); Not fulfilled: Score 0 (null)
 Source: Andrew dan Eaton¹⁵
 *) The quality standards shown in this table have been selected and selected according to study needs.

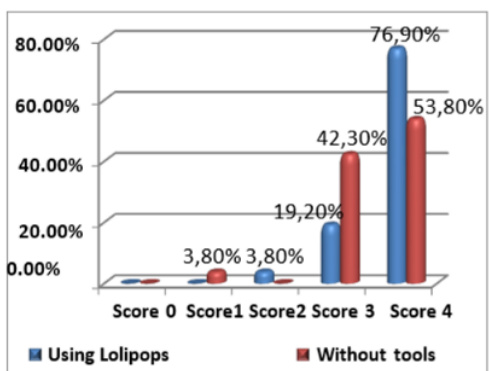
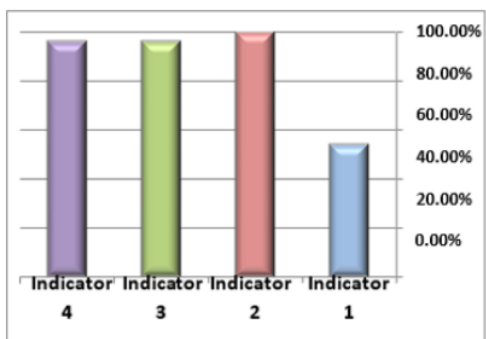


Fig. 2. Percentage score of the results of periapical radiographic quality evaluation using lollipops and without tools



Note
 Indicator 1 = The tooth picture has no foreshortening or elongation
 Indicator 2 = There is no horizontal overlap. If present, do not block the pulp / root canal
 Indicator 3 = All crowns and roots of teeth are covered
 Indicator 4 = 2-3 mm Periapical bone is covered and can be observed to assess the anatomy of the apical area

Fig. 3. Percentage of distribution of quality indicators of periapical radiographs by manufacturing without tools

without assistive devices was 53.80% and for techniques using lollipop tools was 76.90% (Fig. 2).

The results of periapical radiography were observed by three observers namely the researcher and two supervisors. Observation was accompanied by filling in the radiographic quality evaluation indicator table related to positioning when making periapical radiography in which there were 4 indicators (Table 1). Each indicator that was not met gives a score of 0 and if it was met gives a score of 1, so the range of quality evaluation scores for each radiographic result is 0-4. Then, the results of the periapical radiographic quality evaluation results from the three observers in Friedman's test to see the homogeneity of data between observers. After knowing the data from homogeneous observers, data from one observer can be used to test normality, and comparison. The normality test was conducted by using the Saphiro Wilk test.

After the normality test results were obtained, the comparison test was conducted by using the free sample t2 test if the data was normally distributed and using the Mann-Whitney test if the data were not normally distributed.

The results of making radiography without assistive devices, found that 54% radiographs did not undergo elongation or foreshortening. All radiographs do not experience horizontal overlap that covers the pulp / root canal. It was also found that 96% of radiographs included all crowns and roots of teeth and gave an observable 2-3 mm periapical bone picture (Fig. 3).

The results of radiography by making use of lollipops, found that 81% of radiographs did not experience elongation or foreshortening. In addition, all radiographs did not experience horizontal overlap that covers the pulp / root canal. It was also found that 96% of radiographs included all crowns and roots of teeth and gave observations of 2-3 mm periapical bone.

The results of comparative statistical tests showed that there was a significant difference between the results of periapical radiographic quality evaluation using lollipops and without assistive devices (p-value 0.008).

DISCUSSION

The role of dental radiography includes assisting dentists to conduct examinations, establish diagnoses, and arrange appropriate care management (Chiri et al. 2013). Periapical radiographic techniques are routinely used in the field of dental radiology. Periapical

radiography provides an overview of the teeth and surrounding alveolar bone thus it can be important information in helping diagnose various dental abnormalities such as caries, periapical abscesses and periodontal bone loss (Gupta, et al. 2017). However, many people cannot tolerate the placement of intraoral film during periapical radiographic procedures (Reddy, et al. 2015). This study is concerned about alternative methods for obtaining patient cooperation during periapical radiographic procedures, especially paediatric patients because according to the American Academy of Paediatric Dentistry (American Academy of Pediatric Dentistry (2017), children have lower levels of cooperativeness than adults. The alternative method uses a lollipop tool as a film holder.

The results of the evaluation of periapical radiographic quality evaluation found that in both methods, the most commonly produced radiography was radiography that met the four periapical radiographic quality standards (score 4). This shows that both techniques generally produce radiographs that are good for interpretation. But, the percentage of the radiographs number that meet the four radiographic quality standards is higher in the method of using a lollipop tool. This may be related to the better cooperation of children due to the use of lollipops as a desensitization method. As research in the United States shows that with desensitization, paediatric patients are more cooperative and show fewer negative behaviours towards dentistry (Machen, dan Johnson 2017, Piero et al. 2008). Better child cooperation will support better radiographic results with fewer failures. This is consistent with studies in Brazil which show that in children with good cooperation, fewer failures are found on the results of intraoral radiography device. Besides that, better child cooperation and fewer failures are also factors that in the comparative statistical tests,

there are significant differences between the scores of periapical radiographic quality evaluations made using lollipops and without assistive devices.

Observation of periapical radiography results in this study also found that of the two methods, radiographs that did not experience foreshortening or elongation had the lowest percentage when compared with the three other quality standards. The occurrence of foreshortening / shortening and elongation / elongation is due to vertical angulation errors when directing cones (Letsanda, 2007). This is consistent with Almogbel and Alolayan (Almogbel, dan Alolayan 2017). Studies that the most common errors found on periapical radiographs of the maxillary anterior region are vertical angulation errors. The percentage of radiographic results that did not experience elongation and foreshortening was more found in the method of using lollipop tools and more failure when not using aids. The higher failure rate when not using tools may be due to the implementation of the bisecting angle principle where the accuracy of the visualization of imaginary dividing lines between the film and the gear axis is very important (Williamson 2014).

CONCLUSION

Making periapical radiography without a holder makes visualization of imaginary lines dividing the angle between the dental axis and periapical film more difficult. Whereas in the method of using a lollipop tool, lollipop sticks can visualize the angulation of the film, hence the visualization of angular dividing lines between the film and the dental axis is easier. Thus, the quality of periapical radiographs of maxillary anterior teeth in paediatric patients made using lollipops is better than radiographic results made without using aids.

REFERENCES

- Almogbel AAA dan Alolayan ASS (2017). Quality of periapical radiographs taken by undergraduate dental students at Qassim University. Dental student's research. 2014; hal.14 available from http://dsrjournal.org/images/dsr_library/dsr_3rd_issue/Quality_of_Periapical_Radiographs_Taken_By_Undergraduate_Dental_Students_at_Qassim_University.pdf
- American Academy Of Pediatric Dentistry (2012) (AAPD). Guideline on Prescribing Dental Radiographs for Infants, Children, Adolescents, and Persons with Special Health Care Needs. Reference Manual. 37(6):319. Available from www.aapd.org/media/policies_guidelines/e_radiographs.pdf
- American Cancer Society (2017) (ACS). Getting Help for Nausea and Vomiting. American Cancer Society Inc. 2014; hal.2. available from <https://www.cancer.org/content/dam/cancer-org/cancercontrol/en/booklets-flyers/getting-help-for-nausea-and-vomiting-english.pdf>
- Andrew TB dan Eaton KA. X-Ray Vision: How Audit Can Help You Reveal The Quality Of Your Radiography. Primary Dental Journal. 2013; 2(1):35. [accessed 16 April 2017], available from https://thedentalbusinessacademy.com/resources/docs/free-non-verifiable-cpd/X-Ray_Vision_-_How_audit_can_help_you_reveal_the_quality_of_your_radiography.pdf
- Ardelean L, Bortun C, dan Motoc M (2003). Gag Reflex In Dental Practice – Etiological Aspects. TMJ.; 53(3-4):312,314. available from www.tmj.ro/pdf/2003_number_3_4_82812747591_2445.pdf

- Chim AN. Predicting successful dental examination for children with autism spectrum disorder. University of Washington. 2016; hal.20. [accessed 12 Desember 2017], available from https://digital.lib.washington.edu/researchworks/bitstream/handle/1773/36551/Chim_washington_0250O_15682.pdf?sequence=1
- Chiri R, Awan S, Archibald S dan Abbott PV. (2013). Parental knowledge and attitudes toward dental radiography for children. *Australian Dental Journal*. hal.163. [accessed 12 Desember 2017], available from <http://onlinelibrary.wiley.com/doi/10.1111/adj.12041/pdf>
- Food and Drug Administration (2017). (FDA). Dental radiographic examinations: Recommendations for patient selection and limiting radiation exposure.
- Gupta, A., Devi, P., Srivastava, R., dan Jyoti B (2017). Intra oral periapical radiography - basics yet intrigue: A review. *Bangladesh Journal of Dental Research & Education*. 2014; 4(2):83 available from www.banglajol.info/index.php/BJDRE/article/download/20255/14025
- Kantja, I (2015). Pengaruh Pola Makan Pada Anak Sekolah Dasar Terhadap Status Kesehatan Gigi Dan Mulut. Makassar. Fakultas Kedokteran Gigi Universitas Hasanuddin.; hal.5., available from <https://core.ac.uk/download/pdf/77623805.pdf>
- Kementerian Kesehatan Republik Indonesia (Kemenkes RI) dan World Food Programme (WFP) (2017). Cara mengatasi mual dan muntah. Kemenkes RI. 2014; hal.1., available from http://spiritia.or.id/dokumen/leaflet_mualmuntah.pdf
- Letsanda C. (2007). Tingkat superimpose arkus zigomatikus dengan akar molar satu rahang atas terhadap perubahan sudut penyinaran vertikal pada bisecting technic radiography. Universitas Jember. hal.8-9. available from http://repository.unej.ac.id/bitstream/handle/123456789/16699/c%20%28148%29c_1.pdf?sequence=1
- Looe HK, Pfaffenberger A, Chofor N, Eenboom, F Sering M, Ru'hmann A, Poplawski A, Willborn K, dan Poppe B (2006). Radiation Exposure To Children In Intraoral Dental Radiology. Oxford University Press. hal.1. [accessed 16 April 2017], available from <https://www.oeko.de/uploads/oeko/e-paper/ncl071v1.pdf>
- Machen JB dan Johnson R. (1974). Desensitization, model learning and dental behavior in children. *Journal of Dental Research*.; hal.83. available from <http://journals.sagepub.com/doi/abs/10.1177/00220345740530013701>
- Piero VS, Barcelos R, Souza IPR dan Raymundo R (2008). Pediatric bitewing film holder: Preschoolers' acceptance and radiographs' diagnostic quality. *Pediatric Dentistry*. 30(4):345. <http://www.aapd.org/assets/1/25/342-7.pdf>
- Prashanti E, Sumanth KN, Renjith George P, Karanth L, dan Soe HHK (2015). Management of gag reflex for patients undergoing dental treatment. John Wiley & Sons.; hal.7, available from <http://onlinelibrary.wiley.com/doi/10.1002/14651858.CD011116.pub2/pdf>
- Putri MN (201) Modifikasi Film Holder Sebagai Alat Bantu Pembuatan Radiografik Teknik SLOB Untuk Gigi Molar Ketiga Rahang Bawah Impaksi, Surabaya, Fakultas Kedokteran Gigi Unairhal.1.
- Reddy, E.S.P, Nigam, N., Sinha, S., dan Dwivedy, S (2015). Extraoral Periapical Radiography: A Lost Discovery. *Journal of research and advancement in dentistry*. 4(2):310. [accessed 3 Juli 2017] available from https://www.researchgate.net/publication/295703983_EXTRAORAL_PERIAPICAL_RADIOGRAPHY_A_LOST_DISCOVERY
- Salami A, Halabi MA, Hussein I, dan Kowash M. (2017). An Audit on The Quality of Intra-Oral Digital Radiographs Taken In a Postgraduate Paediatric Dentistry Setting. *OJDM*. 16(1):13. [accessed 16 April 2017], available from <https://www.omicsonline.com/open-access/an-audit-on-the-quality-of-intraoral-digital-radiographs-taken-in-a-postgraduate-paediatric-dentistry-setting.pdf>
- Schwartz S (2015). Radiographic Techniques for the Pediatric Patient. *Dentalcare.com Continuing Education*. hal.2,4,6,8. [accessed 3 Maret 2017], available from <http://media.dentalcare.com/media/dentalcareus/professional-education/ce-courses/course0001-0100/ce63/files/ce63.pdf?la=en-us&v=1-201607212329>
- U.S Department of Health and Human Services. 201; hal. 1. available from <https://www.fda.gov/downloads/Radiation-EmittingProducts/RadiationEmittingProductandProcedures/MedicalImaging/MedicalX-Rays/UCM329746.pdf>
- Williamson GF (2014) Intraoral radiography : Positioning and Radiation Protection. American Dental Association. hal.6 available from https://mafiadoc.com/intraoral-radiography-positioning-and-radiation-protection-pdf_597c30b11723ddaf8e78c4.

The quality of the lollipops use in the making of the anterior upper teeth periapical radiography of in paediatric patients

ORIGINALITY REPORT

5%

SIMILARITY INDEX

4%

INTERNET SOURCES

4%

PUBLICATIONS

0%

STUDENT PAPERS

PRIMARY SOURCES

- | | | |
|---|--|-----|
| 1 | ejmcm.com
Internet Source | 1% |
| 2 | eprints.upnyk.ac.id
Internet Source | 1% |
| 3 | journals.plos.org
Internet Source | 1% |
| 4 | Eachempati, Prashanti, Sumanth Kumbargere Nagraj, P Renjith George, Laxminarayan Karanth, Htoo Htoo Kyaw Soe, and Prashanti Eachempati. "Management of gag reflex for patients undergoing dental treatment", Cochrane Database of Systematic Reviews, 2014.
Publication | <1% |
| 5 | Jenny Sunariani, Christian Khoswanto, Wahyuning Ratih Irmalia. "Difference of brain-derived neurotrophic factor expression and pyramid cell count during mastication of food with varying hardness", Journal of Applied Oral Science, 2019 | <1% |

6

bush.tamu.edu

Internet Source

<1 %

7

Stergios Arizos, Johan K. M. Aps, Konstantinos N. Arapostathis. "Chapter 6 Examination, Diagnosis, and Treatment Plan Implementation", Springer Science and Business Media LLC, 2022

Publication

<1 %

8

Sri Wigati Mardi Mulyani, Diah Savitri Ernawati, Eha Renwi Astuti, Fedik Abdul Rantam. "Hypoxic preconditioning effect on stromal cells derived factor-1 and C-X-C chemokine receptor type 4 expression in Wistar rat's (*Rattus norvegicus*) bone marrow mesenchymal stem cells (in vitro study)", *Veterinary World*, 2018

Publication

<1 %

9

U. B. Dixit, L. Moorthy. "The use of interactive distraction technique to manage gagging during impression taking in children: a single-blind, randomised controlled trial", *European Archives of Paediatric Dentistry*, 2020

Publication

<1 %

Exclude bibliography On

The quality of the lollipops use in the making of the anterior upper teeth periapical radiography of in paediatric patients

GRADEMARK REPORT

FINAL GRADE

/0

GENERAL COMMENTS

Instructor

PAGE 1

PAGE 2

PAGE 3

PAGE 4

PAGE 5
