

# Lengthening of Massive Intercalary Cortical Allograft After Successful Graft Incorporation in Skeletally Immature Bone with Critical-Sized Defect: A Case Report with 6-year Follow-up

*by* Heri Suroto

---

**Submission date:** 09-Feb-2021 10:19AM (UTC+0800)

**Submission ID:** 1505038513

**File name:** 2.\_Lengthening\_of\_Massive\_Intercalary.pdf (1.12M)

**Word count:** 2747

**Character count:** 15459



## CASE REPORT

5

# Lengthening of Massive Intercalary Cortical Allograft After Successful Graft Incorporation in Skeletally Immature Bone with Critical-Sized Defect: A Case Report with 6-year Follow-up

Ferdiansyah Mahyudin<sup>1</sup> · Kukuh Dwiputra Hernugrahanto<sup>1</sup> · Jeffry Andrianus<sup>1</sup> · Lukas Widhiyanto<sup>1</sup> · Mouli Edward<sup>1</sup> · Heri Suroto<sup>1</sup>Received: 21 January 2020 / Accepted: 6 March 2020  
© Indian Orthopaedics Association 2020

## Abstract

Bone allograft serves as an alternative to overcome the limitation of autograft. Some concerns, such as graft rejection, infection, and low union rate, arise from the use of bone allograft since the graft is a non-living and foreign material. We reported a case of critical-sized bone defect in a skeletally immature patient treated with massive intercalary allograft that not only did it show union but also graft incorporation that allowed for subsequent bone lengthening at the site of the incorporated massive allograft. To our knowledge, there has been a report of lengthening of free-vascularized fibular autograft but not the nonvascularized one. Massive intercalary allograft that incorporates well to the host could be an option to treat critical-sized bone defect.

**Keywords** Massive intercalary allograft · Bone lengthening · Critical-sized defect

**MeSH Terms** Massive · Intercalary · Allograft · Lengthening · Critical-sized · Defect

## Introduction

Autologous bone grafting remains the gold standard to treat bone defect, but its limited supply deems bone allograft more feasible for critical-sized defect [1]. Issues like graft rejection and low union rate arise from the use of bone allograft since it is a non-living material [2, 3]. We reported a case of critical-sized bone defect treated with massive intercalary allograft. Not only did it show union but also complete graft incorporation that allowed for subsequent bone lengthening at the site of the allograft. To our knowledge, there has been a report of lengthening of free-vascularized autograft but not the nonvascularized massive allograft.

## Case History

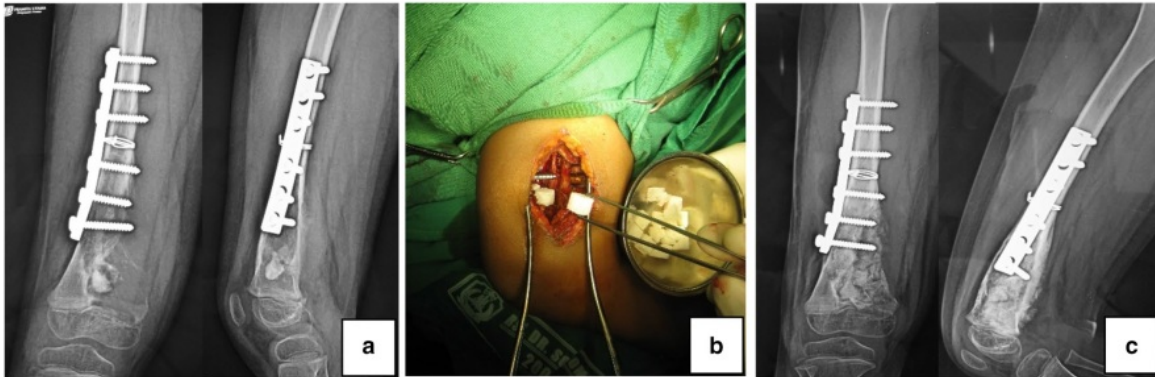
A 10-year-old boy had suffered from right distal femoral fracture and underwent an internal fixation in a remote district hospital. Following the surgery, he was referred to our hospital after an intraoperative finding suggested a haemangioma lesion. Neither CT scan nor MRI had been performed prior to the operation to suggest the presence of haemangioma. Biopsy specimen was taken during the internal fixation surgery in the district hospital. The histopathologic result confirmed the finding of haemangioma. The patient was then scheduled for curettage of the lesion and bone grafting using freeze-dried cancellous bone allograft (Fig. 1).

Six months following the curettage and bone grafting, we observed clearly from the plain x-ray that the lesion continued to expand, and the grafts were resorbed. The expansion also involved the physis distally. The patient was then scheduled for another curettage, but this time bone cement was used instead of bone allograft (Fig. 2).

After 6-month of close follow-up, the patient was 11 years old then, no sign of recurrence was found. The patient underwent another surgery to reconstruct the defect (Fig. 3). Firstly, the bone cement was removed. Upon removal of the

✉ Ferdiansyah Mahyudin  
ferdiansyah@fk.unair.ac.id

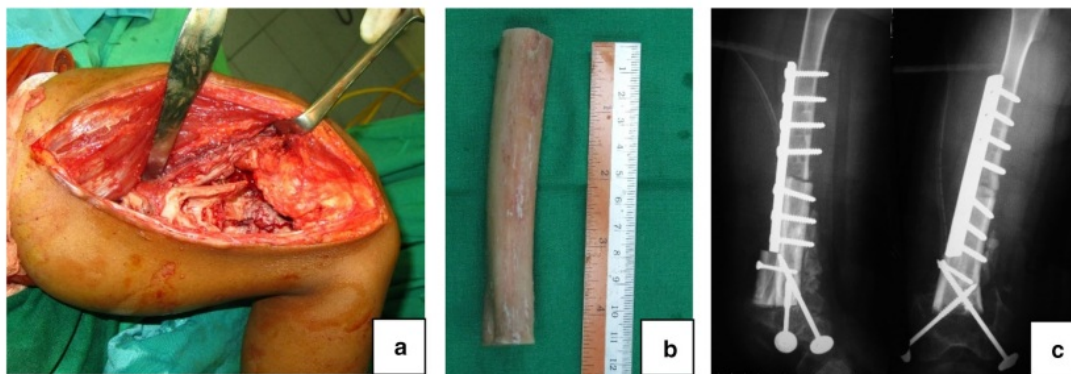
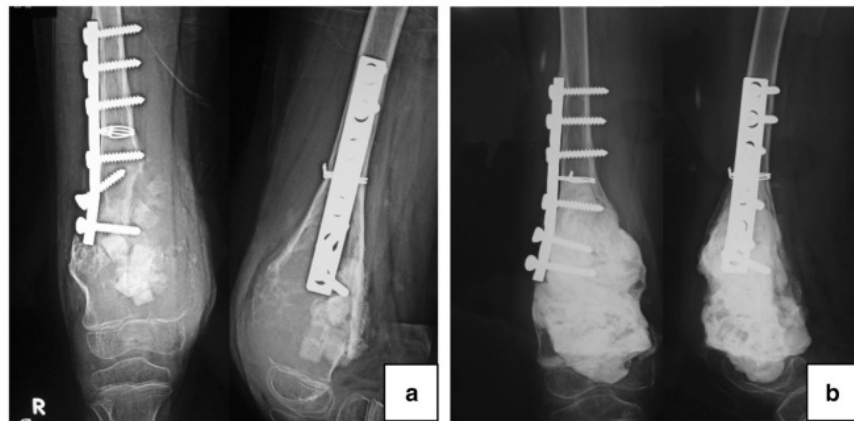<sup>1</sup> Orthopedic and Traumatology Department, Faculty of Medicine, Universitas Airlangga/Dr. Soetomo General Hospital, Jalan Mayjend Prof. Dr. Moestopo No. 6-8, Surabaya, East Jawa, Indonesia



**Fig. 1** The patient was 10 years old: **a** initial X-ray image from the previous hospital suggested a well-demarcated lesion in the distal metaphysis of the right femur; **b** curettage and bone grafting using

cancellous bone allograft; **c** postoperative X-ray image after curettage and bone grafting Source: internal documentation

**Fig. 2** Six months after the first curettage: **a** The lesion continued to expand. Distally, it damaged the physics. Another curettage was needed; **b** second curettage and application of bone cement to fill the defect Source: internal documentation



**Fig. 3** Six months after the second curettage. The patient was 11 years old: **a** critical-sized defect of 10 cm was found; **b** massive intercalary bone allograft was used; **c** the bone graft was inserted and fixed Source: internal documentation

bone cement, intraoperative evaluation did not find any sign of recurrent hemangioma lesion, but a critical-sized bone defect

of 10 cm was found. It was decided to use massive intercalary fresh-frozen bone allograft. The bone allograft had been

procured through careful screening of donor and processed in our hospital tissue bank according to the standard protocols of American Association of Tissue Bank (AATB), European Association of Tissue Bank (EATB), and Asia Pacific Association of Surgical Tissue Bank (APASTB) to ensure the safety and quality of the allograft.

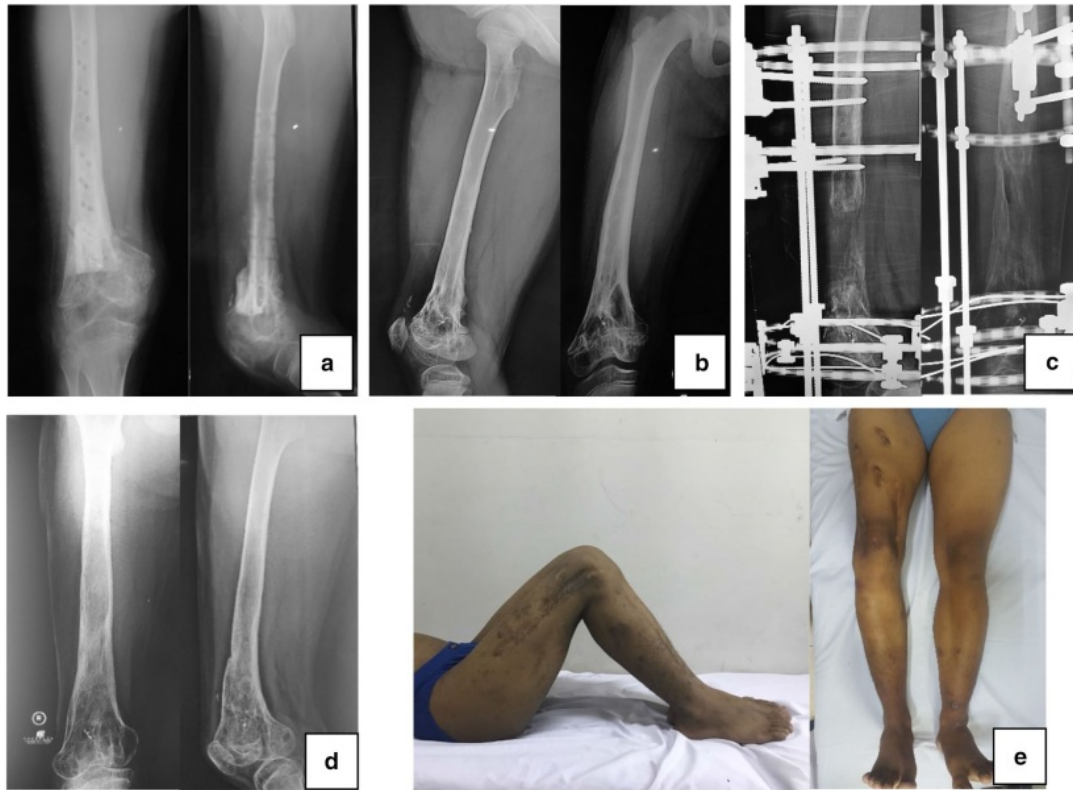
The patient was closely followed up to evaluate any clinical and radiological sign of recurrence, graft rejection, graft failure, infection, fracture, or nonunion. Neither of the sign was found in the patient. After 2 years, the radiological evaluation showed graft union and incorporation. The patient was 13 years old then. Clinical examination found that there was leg-length discrepancy of 2 cm. It was decided to remove all internal fixation and continue to do close observation until the patient passed the period of rapid growth to allow any remaining leg discrepancy to occur. After 3 years of observation, the patient was 16 years old, the leg-length discrepancy increased to 8 cm by then. Limb lengthening procedure was necessary to restore the length of the shortened limb. Gradual lengthening using Ilizarov's distraction osteogenesis was preferred. Osteotomy of the meta-diaphyseal area at the site of the previous intercalary bone allograft with meticulous preservation of the surrounding periosteum and soft tissue was done followed by application of a ring fixator. Seven-day delay was done to allow osteogenesis before starting distraction. We followed the Ilizarov's optimum distraction rule of "one millimeter a day" although in the actual practice the rate of the distraction was adjusted according to the patient's pain assessment and the progress of radiological callus formation. The lengthening procedure was carried out under close monitoring until both limbs achieved equal length. On average, the external fixation index (EFI) was 21.25 days/cm. After a year, equal length with complete radiological union was achieved, and the fixator was removed. Neither clinical nor radiological sign of pin tract infection was observed. We performed close follow-up every 6 months after the last operation to monitor any occurrence of late discrepancy or additional deformity. Although there was residual 5° varus deformity of the right knee found during the 6-month follow-up, the patient was satisfied with his condition. He was able to walk painlessly without limp and to perform daily activity (Fig. 4). According to the Association for the Study and Application of Methods of Ilizarov (ASAMI) outcome criteria, the patient achieved excellent result in both radiological and clinical criteria [4]. The patient was planned for future corrective osteotomy for the varus deformity.

## Discussion

The decision to use bone allograft in this case was due to the massive defect size in which autologous graft would not be sufficient to fill. Intercalary cortical graft was chosen since the defect required structural support. Some concerns arise

from the use of bone allograft. Several studies reported the complication of bone allograft in critical-sized segmental bone defect. Bullens reported that out of 32 patients undergoing reconstruction with massive structural allografts, the fracture rate, infection rate, and union rate after five-year follow up were 13%, 16%, and 25% respectively [5]. Another report from 78 cases with average follow up of 37.9 months by Zheng showed that there were 18 cases (23%) of local rejections, 4 cases (5%) of infection, 5 cases (6.5%) of nonunion [6]. Companacci et al. assessed the long-term results of pediatric osteoarticular allografts after massive resection in 13 distal femoral and 12 proximal tibial tumors. They concluded that allograft mechanical failure was the most important complication, which occurred in 12 cases (60%) [7]. Fracture occurs in about 16% of massive allografts and is usually seen two years after implantation [8]. No finding of infection, graft rejection, fracture, and nonunion was found in this patient. The clinical and radiological evaluation also showed good graft union and incorporation. The complications that occurred were limb shortening and varus deformity.

Stevenson has studied the factors affecting bone graft incorporation. Bone graft incorporation requires the process of revascularization, new bone formation, and host-graft union [9]. The incorporation process of a bone allograft usually occurs at the host-graft junctions since the process is the result of creeping substitution that replaces the allograft with newly formed bone. The nonvascularized massive bone allograft is poorly remodeled which causes the central part of the graft distant from the host-graft junctions to be almost non-viable even after several years of implantation [10]. This makes the allograft entirely dependent on the surrounding tissue for its revascularization. Therefore, the condition of perigraft environment is very important. In this reported case, to prevent any adverse immunologic reaction between the host and the graft, the allograft had been processed under strict standard protocol of AATB, EATB, and APASTB. After allograft implantation, any clinical signs of graft rejection were observed and recorded. No rejection sign was found. The patient was a skeletally immature 10-year old boy. The still-growing pediatric bone provides stronger and thicker periosteum that might have contributed to better revascularization and bone healing, which resulted in good graft incorporation. We performed meticulous and careful handling of the periosteum and the surrounding soft tissues in every stage of the surgery to ensure that the periosteum and the surrounding soft tissues were well preserved. Since infection might also cause poor union rate, we exercised strict monitoring for any sign of pin tract infection both clinically and radiologically. Daily pin sites cleaning, and good personal hygiene were carried out by the patient. In addition, to protect and facilitate the incorporation between the graft and the host bone, optimum mechanical environment



**Fig. 4** **a** Two years after the graft implantation, 13 years old: good graft incorporation and union. Length discrepancy was two centimeters; **b** after 3 years of observation, 16 years old: the graft was fully incorporated. Leg length discrepancy increased to 8 cm; **c** limb

lengthening using Ilizarov's distraction osteogenesis. Osteotomy at the level of meta-diaphyseal junction; **d** one year of lengthening procedure, 17 years old; **e** equal length of both limbs Source: internal documentation

is necessary. This requires stable fixation of the graft using ring fixator [9, 11].

Bone defect in skeletally immature patients often leave the patients with residual leg length discrepancy. Distraction osteogenesis offers an additional therapeutic. According to Ilizarov, the requirements for an optimal result of bone lengthening are minimally traumatic osteotomies preferably located in a metaphysis, solid mechanical fixation across osteotomies, an adequate latency period before lengthening, and sufficient time for callus to mature [12]. Han Jo Kim assess the safety and efficacy of limb reconstruction using Ilizarov's distraction osteogenesis method following treatment of a range of benign and malignant bony conditions. The living bone regenerated in distraction osteogenesis will eventually provide sufficient biomechanical strength, stability, and durability. In growing children, leg-length discrepancies may be corrected by distraction osteogenesis after they have matured [13]. Ilizarov showed that formation of new bone at the osteotomy site is definitely influenced by the amount of damage to the bone, medullary cavity, and

periosteum. Since regeneration of medullary vessels will only occur after 7–10 days following a complete osteotomy, the most important factor for new bone formation at the site of the osteotomy is the integrity of the periosteum [9, 12]. Therefore, we performed careful preservation of the periosteum during the osteotomy to ensure good periosteum cuff around the osteotomy site. For the lengthening to succeed, a period of delay between osteotomy and distraction must be carried out to allow osteogenesis. In an adolescent patient, we consider that 7 days were long enough to allow initial callus formation. Ilizarov suggests one-milimeter-a-day rule for optimum distraction. Several studies on bone distraction in nonunion cases suggested various external fixation index from 1 to 3 months per centimeter gained. As far as our concern, there is still no published reference for distraction rate in allograft. Therefore, we followed the original rule by Ilizarov with some adjustment based on the patient condition and the radiological progress of callus formation. After equal length was achieved, close observation was carried out to monitor complete union, and any residual discrepancy

or deformity. To our knowledge, there has been a report of lengthening of free-vascularized fibular autograft but not the non-vascularized one. The reported case showed successful bone lengthening of the incorporated non-vascularized massive intercalary allograft. This shows that in skeletally immature bone, the graft might achieve complete incorporation to allow subsequent lengthening.

## Conclusion

Optimum perigraft condition that includes infection-free environment, well-preserved periosteum, stable fixation, and proper distraction technique, will facilitate good incorporation and subsequent lengthening of allograft in skeletally-immature bone.

**Author Contributions** Concepts: FM, HS. Design: FM, KDH, JA, LW, ME. Definition of intellectual content: FM, KDH, JA, LW, ME. Literature search: FM, KDH, JA, LW, ME. Clinical studies: FM, KDH, JA, LW, ME. Experimental studies: FM, KDH, JA, LW, ME. Data acquisition: FM, KDH, JA, LW, ME. Data analysis: FM, HS. Statistical analysis: FM, HS. Manuscript preparation: FM, KDH, HS. Manuscript editing: FM, KDH, HS. Manuscript review: FM, KDH, HS. Guarantor: FM, KDH, JA, LW, ME, HS.

**Funding** This research did not receive any specific grant from funding agencies in the public, commercial, or not-for-profit sectors so this research was fully funded personally.

## Compliance with Ethical Standards

**Conflicting interest** No conflict of interest in this study.

**Ethical standard statement** All procedures performed in studies involving human participants were in accordance with the ethical standards of the institutional and/or national research committee and with the 1964 Helsinki declaration and its later amendments or comparable ethical standards.

**Informed consent** Informed consent was obtained from the patient for publication of this case report and accompanying images.

## References

- Utomo, D. N., Hernugrahanto, K. D., Edward, M., Widhiyanto, L., & Mahyudin, F. (2019). International Journal of Surgery Case Reports Combination of bone marrow aspirate, cancellous bone allograft, and platelet-rich plasma as an alternative solution to critical-sized diaphyseal bone defect: A case series. *International Journal of Surgery Case Reports*, 58, 178–185.
- Wang, W., & Yeung, K. W. K. (2017). Bioactive Materials Bone grafts and biomaterials substitutes for bone defect repair: A review. *Bioactive Materials*, 2(4), 224–247.
- Goldberg, V. M., & Akhavan, S. (2005). Biology of bone grafts. In J. R. L. G. E. Friedlaender (Ed.), *Bone Regeneration and Repair: Biology and Clinical Applications* (pp. 57–65). Totowa: Humana Press Inc.
- Paley, D., Catagni, M. A., Argnani, F., Villa, A., Benedetti, G. B., Cattaneo, R., et al. (1989). Ilizarov treatment of tibial nonunions with bone loss. *Clinical Orthopaedics and Related Research*, 241, 146–165.
- Bullens, P. H. J., Minderhoud, N. M., de Waal Malefijt, M. C., Veth, R. P. H., Buma, P., & Schreuder, H. (2009). Survival of massive allografts in segmental oncological bone defect reconstructions. *International Orthopaedics*, 33, 757–760.
- Zheng, X.-F., Huang, H.-Y., Ding, H.-W., Zhang, Y., & Yin, Q.-S. (2009). Reconstruction of bone defects with massive bone allograft for bone tumor treatment in 78 cases. *Journal of Clinical Rehabilitative Tissue Engineering Research*, 9(13), 2978–2983.
- Jamshidi, K., & Bahrabadi, M. M. A. (2017). Long-term results of osteoarticular allograft reconstruction in children with distal femoral bone tumors. *Archives of Bone and Joint Surgery*, 5, 296–301.
- Delloye, C., Cornu, O., Druetz, V., & Barbier, O. (2007). Bone allografts. What they can offer and what they cannot. *The Journal of Bone and Joint Surgery B*, 89(5), 574–579.
- Stevenson, S., Emery, S. E., & Goldberg, V. M. (1996). Factors affecting bone graft incorporation. *Clinical Orthopaedics and Related Research*, 323, 66–74.
- Delloye, C. (2003). How to improve the incorporation of massive allografts? *La Chirurgia Degli Organi di Movimento*, 88(4), 335–343.
- Lindaman, L. (2001). Bone healing in children. *Clinics in Podiatric Medicine and Surgery*, 18(1), 97–108.
- Hvid, I., Horn, J., Huhnstock, S., & Steen, H. (2016). The biology of bone lengthening. *Journal of Children's Orthopaedics*, 10(6), 487–492.
- Frisoni, T., Cevolani, L., Giorgini, A., & Dozza, B. D. D. (2012). Factors affecting outcome of massive intercalary bone allografts in the treatment of tumours of the femur. *The Journal of Bone and Joint Surgery*, 94-B, 836–841.

# Lengthening of Massive Intercalary Cortical Allograft After Successful Graft Incorporation in Skeletally Immature Bone with Critical-Sized Defect: A Case Report with 6-year Follow-up

## ORIGINALITY REPORT

18%

SIMILARITY INDEX

14%

INTERNET SOURCES

14%

PUBLICATIONS

0%

STUDENT PAPERS

## PRIMARY SOURCES

1	<a href="http://medcraveonline.com">medcraveonline.com</a> Internet Source	2%
2	Reggie C., Juan S., Maryam Tabrizi. "Chapter 13 Distraction Osteogenesis and Its Challenges in Bone Regeneration", IntechOpen, 2012 Publication	2%
3	<a href="http://abjs.mums.ac.ir">abjs.mums.ac.ir</a> Internet Source	2%
4	<a href="http://sinta3.ristekdikti.go.id">sinta3.ristekdikti.go.id</a> Internet Source	1%
5	<a href="http://www.semanticscholar.org">www.semanticscholar.org</a> Internet Source	1%
6	<a href="http://online.boneandjoint.org.uk">online.boneandjoint.org.uk</a> Internet Source	1%
7	"Limb Lengthening and Reconstruction Surgery Case Atlas", Springer Science and Business Media LLC, 2015	1%

---

8	<a href="http://www.ncbi.nlm.nih.gov">www.ncbi.nlm.nih.gov</a> Internet Source	1%
9	<a href="http://curis.ku.dk">curis.ku.dk</a> Internet Source	1%
10	McCoy, Thomas H., Han Jo Kim, Michael B. Cross, Austin T. Fragomen, John H. Healey, Edward A. Athanasian, and S. Robert Rozbruch. "Bone tumor reconstruction with the Ilizarov method", <i>Journal of Surgical Oncology</i> , 2013. Publication	1%
11	Prihatma Kriswidyatomo, Maharani Pradnya Paramitha. "Rapid sequence induction/intubation controversies", <i>Hong Kong Journal of Emergency Medicine</i> , 2020 Publication	1%
12	<a href="http://journals.lww.com">journals.lww.com</a> Internet Source	1%
13	McKinley, T.. "Principles of Fracture Healing", <i>Surgery (Oxford)</i> , 20030901 Publication	1%
14	<a href="http://www.bisfoundation.nl">www.bisfoundation.nl</a> Internet Source	1%
15	<a href="http://mafiadoc.com">mafiadoc.com</a> Internet Source	1%

---



---

16

S. Vidyadhara, S.K. Rao. "Techniques in the management of juxta-articular aggressive and recurrent giant cell tumors around the knee", European Journal of Surgical Oncology (EJSO), 2007

Publication

1%

---

17

Jitendra Wadhvani, Rajesh Rohilla, Ramchander Siwach, Roop Singh, Ashish Devgan, Sumedha Vashishth. "Comparison of Clinico-radiological Outcomes of Monolateral Fixator in Infected Non-union of Tibia Based on Bone Gap Quantification", Indian Journal of Orthopaedics, 2020

Publication

1%

---

18

[oa.uni-regensburg.de](http://oa.uni-regensburg.de)

Internet Source

<1%

---

Exclude quotes Off

Exclude matches < 10 words

Exclude bibliography On

# Lengthening of Massive Intercalary Cortical Allograft After Successful Graft Incorporation in Skeletally Immature Bone with Critical-Sized Defect: A Case Report with 6-year Follow-up

---

## GRADEMARK REPORT

---

FINAL GRADE

**/0**

GENERAL COMMENTS

**Instructor**

---

PAGE 1

---

PAGE 2

---

PAGE 3

---

PAGE 4

---

PAGE 5

---