



ISSN 2049-0801

ANNALS OF MEDICINE & SURGERY



DITIO • DILIGENTIA • FIDES

www.annalsjournal.com

ScienceDirect



Annals of Medicine and Surgery

Editorial Board

Editor-in-Chief

Riaz Agha, London, England, UK

Assistant Managing and Executive Editor

Maliha Agha, London, England, UK

Assistant Editors

Adam Frampton, London, England, UK
Jorg Kleef, Munich, Germany
Deepthi Mani, Washington, USA
David Rosin, Bridgetown, Barbados
Peter Schemmer, Heidelberg, Germany

Social Media Editor

Riaz Agha, London, UK

Managing Editor

Alexander James Fowler, London, England, UK

Statistical Editor

Lai-Chu See, Taoyuan, Taiwan

Associate Staff Editors

Sergio Acuna, Toronto, Canada
Guido Alsfasser, Rostock, Germany
Fernando Angarita, Toronto, Canada
James Clark, Plymouth, England, UK
Terry Evans, London, England, UK
Shivani Garg, Wisconsin, USA

Assistant Commissioning Editors

Ahmed Al-Jabir, London, UK
Zaid Alsafi, London, UK
Thomas Franchi, Sheffield, UK
Christos Iosifides, London, UK
Ahmed Kerwan, London, UK

Mehdi Khan, London, UK
Ginimol Mathew, London, UK
Maria Nicola, London, UK
Niamh O'Neill, London, UK
Catrin Sohrabi, London, UK

Junior Staff Editors

Sumita Agrawal, Jodhpur, India
Bakir Al-Dulaimy, London, UK
Mohammed Anwar, London, UK
Martinique Vella Baldacchino, Glasgow, UK
Maria Borrelli, London, UK
Kerry Anne Burke, Manchester, England, UK
Adam Cristaudo, Cairns, Australia
Buket Gundogan, London, UK
Adam Gwozdz, London, England, UK

Mike Hu, California, USA
Tobin Joseph, London, UK
Kiron Koshy, London, UK
Seon-Young Lee, Southampton, England, UK
Chris Limb, London, England, UK
Yasser Al Omran, London, England, UK
Karishma Shah, Oxford, UK
Rachel Thavayogan, London, UK

Executive Committee

Sir Graeme Catto, Aberdeen, Scotland, UK
Sir Barry Jackson, London, England, UK

David Rosin, Bridgetown, Barbados

Editorial Board

Xiao-Ping Chen, Wuhan, China
Marc Cohen, Victoria, Australia
David Green, London, England, UK
Saeed Sadiq Hamid, Karachi, Pakistan
Peter Hutchinson, Cambridge, England, UK
Peter Littlejohns, London, England, UK
Ashok Mahapatra, New Delhi, India
Judy McKimm, Swansea, Wales, UK
Dattatraya Muzumdar, Mumbai, India

Ashish Nabar, Mumbai, India
Fabio Nicoli, London, UK
John Norcini, Philadelphia, PA, USA
Christoph Paasch, Berlin, Germany
Daniel Sokol, London, England, UK
Jamsheer Talati, Karachi, Pakistan
John V. Thomas, Birmingham, AL, USA
Tim Gabe Williams, Kent, England, UK
Zhao-Fan Xia, Shanghai, China

Elsevier

Executive Publisher

Allan Ross, New York, USA

Administrative Editor

Joanne Frankland, Oxford, UK

Marketing Manager

Wendy Montalvo, New York, USA

Journal Manager

Tamsyn Hopkins, Exeter, UK

Senior Business Development

Executive (Reprints)

Emma Steel, London, UK

Advertising Sales Manager

Robert Bayliss, London, UK

Account Manager (Supplements)

Evelina Euren, The Netherlands

Table of Contents

Original Research

Research article ● Open access

“Tocilizumab-an option for patients with COVID-19 associated cytokine release syndrome: A single center experience”, a retrospective study-original article

Aijaz Zeeshan Khan Chachar, Khurshid Ahmed Khan, Javeid Iqbal, Adnan Hussain Shahid, ... Bilal Bin Younis

Article 102165


[Download PDF](#) Article preview 

Research article ● Open access

Prevalence and risk factors of barotrauma in Covid-19 patients admitted to an intensive care unit in Kuwait; a retrospective cohort study

Hussein Elsaaran, Shamlan AlQinai, Dana AlTarrah, Mahdi Abdulrasoul, ... Salman Al-Sabah

Article 102141

[Download PDF](#) Article preview 

Research article ● Open access

Role and value of inflammatory markers in brain tumors: A case controlled study

Ridha Dharmajaya, Dina Keumala Sari

Article 102107

[Download PDF](#) Article preview 

Research article ● Open access

COVID-19 pandemic and breast cancer management: A retrospective observational clinical study from Pakistan

Lubna M. Vohra, Dua Jabeen, Narmeen Asif, Abdul Ahad

Article 102151

[Download PDF](#) Article preview 

Research article ● Open access

The importance of using fine-needle aspiration cytology in the diagnosis of thyroid nodules

Ahlem Bchir, Ahlem Bdioui, Hamza Zammel, Nabihha Missaoui, ... Moncef Mokni

Article 102153



Research article ● *Open access*

Pre-treatment neutrophil-lymphocyte and platelet-lymphocyte ratios as additional markers for breast cancer progression: A retrospective cohort study

Sumadi Lukman Anwar, Roby Cahyono, Widya Surya Avanti, Heru Yudhanto Budiman, ... Teguh Aryandono

Article 102144

[Download PDF](#) Article preview 

Research article ● *Open access*

Is single port laparoscopic cholecystectomy superior to standard cholecystectomy in post-operative pain?

Talal Mohammed Ali Alshahri, Sabry Abounozha, Rashid Ibrahim

Article 102123

[Download PDF](#) Article preview 

Research article ● *Open access*

Effect of autologous fibrin glue on seroma reduction after modified radical mastectomy for breast cancer: A randomized controlled trial

Mohammed Faisal, Sara Salem, Noha kamel, Haidi Abd -Elzaher, ... Hamada Fathy

Article 102135



FEEDBACK 

Research article ● *Open access*

Neutrophil-to-lymphocyte ratio as a predictor of complicated acute diverticulitis: A retrospective cohort study

René M. Palacios Huatuco, Diana A. Pantoja Pachajoa, Nicolás Bruera, Agustín E. Pinsak, ... Matías Parodi

Article 102128

[Download PDF](#) Article preview 

Research article ● *Open access*

The effects of extracorporeal shock wave therapy vs hand massage on serum lipids in overweight and obese women

KyungJin Lee, Jin.Ik Park, Soo.Yeon Oh

Article 102057

[Download PDF](#) Article preview 

Research article ● *Open access*







Cellular pathology practice in the era of COVID-19 pandemic-related lockdowns - Experience from a tertiary hospital: A retrospective observational study

Mohammed Alorjani, Ismail Matalaka, Shaden Abu Baker, Sohaib Al-Khatib, ... Mohammad Al-Qudah

Article 102155



FEEDBACK 

- Research article ● *Open access*
Preoperative skull tongs-femoral traction versus cotrel longitudinal traction for rigid and severe scoliosis: Cohort study
Didik Librianto, Reza Saputra, Yoshi Pratama Djaja, Phedy Phedy, ... Ifran Saleh
Article 102177
[Download PDF](#) Article preview 
- Research article ● *Open access*
Evaluation of serum ferritin for prediction of severity and mortality in COVID-19- A cross sectional study
Sibtain Ahmed, Zeeshan Ansar Ahmed, Imran Siddiqui, Naveed Haroon Rashid, ... Lena Jafri
Article 102163
[Download PDF](#) Article preview 
- Research article ● *Open access*
ICAM-1 levels in patients with covid-19 with diabetic foot ulcers: A prospective study in southeast asia
Mendy Hatibie Oley, Maximillian Christian Oley, Billy Johnson Kepel, Djony E. Tjandra, ... Muhammad Faruk
Article 102171 
- Research article ● *Open access*
The relationship between NFKB, HER2, ER expression and anthracycline -based neoadjuvan chemotherapy response in local advanced stadium breast cancer: A cohort study in Eastern Indonesia
Indra, Christian Manginstar, Andi Asadul Islam, Daniel Sampepajung, ... Muhammad Faruk
Article 102164
[Download PDF](#) Article preview 
- Research article ● *Open access*
Managing appendicitis during the COVID-19 era: A single centre experience & implications for future practice
Oreoluwa Bajomo, Rumneek Hampal, Paul Sykes, Anur Miah
Article 102168
[Download PDF](#) Article preview 
- Research article ● *Open access*
Serum vitamin D receptor and High Mobility Group Box-1 (HMGB1) levels in HIV-infected patients with different immunodeficiency status: A cross-sectional study
Indah Sapta Wardani, Mochammad Hatta, Risna Halim Mubin, Agussalim Bukhari, ... Siti Wahyuni
Article 102174 

Research article ● *Open access*

A local experience of non-operative management for an appendicitis cohort during COVID-19

Dinh Van Chi Mai, Alex Sagar, Nainika Suresh Menon, Oliver Claydon, ... Barrie David Keeler

Article 102160

[Download PDF](#) Article preview 

Research article ● *Open access*

Evaluation of different methods to improve culture-negative peritoneal dialysis-related peritonitis: A single-center study

Duangrat Tanratananon, Soawarat Deekae, Sukit Raksasuk, Thatsaphan Srithongkul

Article 102139

[Download PDF](#) Article preview 

Research article ● *Open access*

The role of angioembolization and C-clamp fixation: Damaged control orthopaedic in haemodynamically unstable pelvic fracture

Ismail Hadisoebroto Dilogo, Ido Prabowo

Article 102157



Research article ● *Open access*

Comparative study of the safety and efficacy of SMOFlipid vs non SMOFlipid as TPN for liver transplantation

Mei-Yun Wu, Sheng-Chih Kuo, Su-Fen Chuang, Cheng-Hsi Yeh, ... Chih-Che Lin

Article 102094

[Download PDF](#) Article preview 

Research article ● *Open access*

Acute necrotizing pancreatitis: Has conservative management replaced surgery? Perspective from a tertiary care centre in Pakistan: A cross-sectional study

Fatima Mannan, Roger Christopher Gill, Abdul Ahad Sohail, Rehman Alvi, Khabir Ahmad

Article 102159

[Download PDF](#) Article preview 

Research article ● *Open access*

[Apoptosis of proximal stump postganglionic brachial plexus injury, before and after six months post-trauma](#)

Gana Adyaksa, Heri Suroto

Article 102156



FEEDBACK 

Research article ● Open access

Association between the confluent form of pancreatic and bile duct and histopathological findings in pancreaticobiliary maljunction: A case series study

Masaki Horiike, Yoshiki Morotomi, Shigekazu Takemura, Shogo Tanaka, ... Shoji Kubo

Article 102180

[Download PDF](#) Article preview 

Research article ● Open access

Trauma magnitude of the meta-epiphyseal cancellous affects the incidence of deep vein thrombosis. A prospective cohort study on the dynamic of Collagen I, Collagen IV, Tissue factor, P-Selectin and Nitric Oxide in the thrombus formation following hip and knee surgeries

Franky Hartono, Irawan Yusuf, Budhianto Suhadi, Andi Fachruddin, Yohanes Augustinus

Article 102190

[Download PDF](#) Article preview 

Research article ● Open access

Fistula incidence after primary repair and correlation with cleft width-to-palatum width ratio: A prospective cohort study

Rosadi Seswandhana, Firdian Makrufardi, Gentur Sudjatmiko

Article 102183

FEEDBACK 



Research article ● Open access

Analysis of SLC7A9 gene mutations among Jordanian patients with cystinuria

Omar M. Halalshah, Mustafa A. Al-Shehabat, Moh'D.A. Al-Ghazo, Ibrahim F. Al-Ghalayini, ... Omar Altal

Article 102182

[Download PDF](#) Article preview 

Research article ● Open access

Retrospective analysis of trends in surgery volumes between 2016 and 2019 and impact of the insurance deductible: Cross-sectional study

Dhairya Shukla, Sharvil Patel, Lesley Clack, Tyler B. Smith, Michael S. Shuler

Article 102176

[Download PDF](#) Article preview 

Research article ● Open access

Functional outcome of implant-free bone-patellar tendon autograft versus hamstring autograft in arthroscopic anterior cruciate ligament reconstruction: A prospective study

Andri Maruli Tua Lubis, Muhammad Budimansyah, I. Gusti Made Febry Siswanto, Yanuarso Yanuarso, Aldo Fransiskus Marsetio

Article 102184



Research article ● Open access

Effectiveness of hemi-thyroidectomy in relieving compressive symptoms in cases with large multinodular goiter

Nuha Alsaleh, Kholoud Albaqmi, Maram Alaql

Article 102140

[Download PDF](#) Article preview 

Review Articles

Review article ● Open access

Intra-gastric balloons – The past, present and future

Eisa Lari, Waleed Burhamah, Ali Lari, Talal Alsaeed, ... Salman Al-Sabah

Article 102138

[Download PDF](#) Article preview 

Review article ● Open access

Trans-cutaneous electrical nerve stimulation to treat dry mouth (xerostomia) following radiotherapy for head and neck cancer. A systematic review

Fatemeh Salimi, Francisco Saavedra, Brain Andrews, James FitzGerald, Stuart C. Winter

FEEDBACK 

Review article ● Open access

Surgical site infection in mesh repair for ventral hernia in contaminated field: A systematic review and meta-analysis

Mohamed Maatouk, Yacine Ben Safta, Aymen Mabrouk, Ghassen Hamdi Kbir, ... Mounir Ben Moussa

Article 102173

[Download PDF](#) Article preview 

Review article ● Open access

The correlation between the gleason score of the biopsy and that of the prostatectomy patch

W. Bai, Y. Fadil, O. Idrissi, M. Dakir, ... R. Abouteib

Article 102169

[Download PDF](#) Article preview 

Case Reports

Case report ● Open access

Unusual migration of distal ventriculoperitoneal shunt to Vagina via fallopian tube: A case report

Imam Hidayat, Dian Adi Syahputra, Muntadhar Muhammad Isa

Article 102158

FEEDBACK 

Case report ● *Open access*

Rebellious headache revealing an extensive rhinoscleroma: A case report and review of the literature

Asmae Bazzout, Azzeddine Lachkar, Drissia Benfadil, Adil abdenbi Tsen, ... Rachid Ghailan

Article 102166

[Download PDF](#) [Article preview](#) 

Case report ● *Open access*

Vertebral artery injury due to air rifle: A case report

Harmantya Mahadhipta, Muhammad Alvin Shiddieqy Pohan, Andryan Hanafi Bakri

Article 102149

[Download PDF](#) [Article preview](#) 

Case report ● *Open access*

Posterior reversible encephalopathy syndrome presenting as refractory status epilepticus in a patient taking Mycophenolate mofetil for IgA nephropathy: A case report

Sushil Khanal, Rohit Kumar Chaudhary, Kripa Kc, Supriya Lamichhane, ... Subhash Prasad Acharya

Article 102147



Case report ● *Open access*

Sub-acute transverse colon volvulus an exceptional cause of large bowel obstruction: Case report

Abdelilah Elbakouri, Oussama Lafkih, Zineb Abbad El Andaloussi, Mounir Bouali, ... Abdelaziz Fadil

Article 102154

[Download PDF](#) [Article preview](#) 

Case report ● *Open access*

A gastrointestinal stromal tumor of stomach presenting with an intratumoral abscess: A case report

Ahmed Ballati, Zakaria Essaidi, Layla El Attar, Driss Errguibi, ... Farid Chehab

Article 102143

[Download PDF](#) [Article preview](#) 

Case report ● *Open access*

Case report--mechanical bowel obstruction with appendicitis without strangulation and leukocytosis

Anil Khetarpal, Ayush Khetarpal

Article 102152

[Download PDF](#) [Article preview](#) 



Case report ● *Open access*

Intrahepatic intraductal papillary cystic neoplasm of the bile duct: A case report

Evangelos G. Baltagiannis, Christina Kalyvioti, Anastasia Glantzouni, Anna Batistatou, ... Georgios K. Glantzounis

Article 102167

[Download PDF](#) [Article preview](#) 

Case report ● *Open access*

Cerebral hydatid cyst during pregnancy: A case report

Othman Benhayoune, Marouane Makhchoune, Abdelhamid Jehri, Mohamed Yassine Haouas, ... Abdelhakim Lakhdar

Article 102161

[Download PDF](#) [Article preview](#) 

Case report ● *Open access*

Successful conservative treatment of a poly-4-hydroxybutyrate mesh infection: A case report

Maarten Lambrecht, Tim Tollens

Article 102162

[Download PDF](#) [Article preview](#) 



Case report ● *Open access*

Dissected saccular aneurysm of the ascending aorta after percutaneous coronary intervention: A case report

Ibrahim Hannoun, Albaraa Bara

Article 102178

[Download PDF](#) [Article preview](#) 

Case report ● *Open access*

Incidental diagnosis of paragonimiasis after histopathological examination of cholecystectomy specimen in Nepal: A case report

Pearlbiga Karki, Pinky Jha, Gaurab Mainali, Manoj Khadka, ... Gayatri Karki

Article 102170

[Download PDF](#) [Article preview](#) 








Case report ● *Open access*

Successfully treated hemi-central retinal artery occlusion following cardiac catheterization; case report


Abdullah Al-kasasbeh, Omar Saleh, Rasheed Ibdah, Sukaina Rawashdeh, Khalid Ibrahim

Article 102175



- Case report ● *Open access*
SURGICEL mimicking a recurrence of a temporomandibular joint chondrosarcoma
Fatema Ez-zahrae Azami Hassani, Faiçal Slimani
Article 102187
[Download PDF](#) Article preview 
- Case report ● *Open access*
Trichobezoar from bristles brush and Carpet yarn requiring emergency laparotomy. Case report
Kusay Ayoub, Abdelaziz Alibraheem, Esraa Masri, Amira Kazan, ... Nihad Mahli
Article 102192
[Download PDF](#) Article preview 
- Case report ● *Open access*
Patent foramen oval: A rare case of acute ischemia of the upper limb: A case with 2 year follow-up
O. Kallel, D. Charmake, I. Chergui, N. El Ouafi, N. Ismaili
Article 102188
[Download PDF](#) Article preview 
- Case report ● *Open access*
Multiple impalement injuries of the torso with two metal bars: A case report
Mhd Belal Alsabek, Mohamad Nour Badi, Mohamed Khatab
Article 102179
[Download PDF](#) Article preview 
- Case report ● *Open access*
Urachal carcinoma revealed by isolated hematuria
Issam Jandou, Adnan Ettanji, Ettaouil Mohammed, Amine Moataz, ... Rachid Aboutaieb
Article 102193
[Download PDF](#) Article preview 
- Case report ● *Open access*
Arteriovenous malformation in cheek and tongue aggravated by cellulitis: A case report and literature review
Amine Kaouani, Ouassime Kerdoud, Rachid Aloua, Faical Slimani
Article 102196
[Download PDF](#) Article preview 
- Case report ● *Open access*
Paraparesis As a Rare First Presentation Of Primary Hyperparathyroidism-Related Brown Tumor in The Thoracic Spine: Case report and literature review
Sultan M. Jarrar, Suleiman S. Daoud, Omar F. Jbarah, Iyad S. Albustami
Article 102197
[Download PDF](#) Article preview 





Cross-sectional Study

Apoptosis of proximal stump postganglionic brachial plexus injury, before and after six months post-trauma

Gana Adyaksa, Heri Suroto*

Department of Orthopedics & Traumatology, Faculty of Medicine, Universitas Airlangga / Dr. Soetomo General Academic Hospital, Surabaya, Indonesia

ARTICLE INFO

Keywords:

Postganglionic brachial plexus injury
Apoptosis
Proximal stump

ABSTRACT

Background: The success of the micro-surgery procedure for the treatment of postganglionic brachial plexus injury was influenced by several factors, including the surgical timing and also the viability of the proximal stump. This study evaluates the evidence of apoptosis in the brachial plexus proximal stump and its correlation with the surgical timing.

Methods: Proximal stump biopsy of postganglionic brachial plexus injury patients were obtained during nerve procedure surgery. The samples were grouped based on the surgical timing, before six months post-trauma (early group) and after six months post-trauma (late group). The apoptosis of motoneurons was evaluated by immunohistochemistry expression of Caspase-3, TNF- α , Caspase-8, and Caspase-9.

Results: Immunohistochemistry findings showed higher expression of Caspase-3 in the late group compared to the early group, as well as the expression of Caspase-8 and Caspase-9 ($p < 0,05$), and with a positive correlation between Caspase-8 and Caspase-9 to Caspase-3. Meanwhile, TNF- α expression was higher in the early group than the late group ($p < 0,05$) and with no correlation between TNF- α to Caspase-3.

Conclusion: Apoptosis of proximal stump motoneuron plexus brachialis on more than six months post-trauma is higher than on less than six months post-trauma.

1. Introduction

Brachial plexus injury (BPI) is a severe trauma that generally occurs in young and productive age patients, usually due to a traffic accident and an injury to the area between the neck and shoulders [1,2]. This injury causes loss of function and ability to carry out their daily activities and work activities, which will impact job loss, economic decline, depression, anxiety, and even suicide [3,4].

There are currently several surgical options for BPI, including nerve graft, nerve transfer, and functional muscle transfer [5–7]. The success of this micro-surgery procedure is influenced by several factors, including the timing of surgery. A systematic review study showed that BPI's surgical procedure performed less than six months after the trauma has a better outcome than if performed after six months post-trauma [8]. This is usually caused by motor endplate degeneration of more than six months of denervated muscle [9,10]. Furthermore, there was evidence that after six months post-trauma, the nerve regeneration capacity was significantly reduced [11].

In postganglionic brachial plexus injury, nerve grafting is one

alternative surgical procedure to restore some muscle functions [12]. In nerve grafting, the proximal stump's viability is essential to ensure the success of the grafting. After trauma, the brachial plexus proximal stump could undergo some particular event, depends on the involved damaged area. The breakdown of the proximal stump is limited and typically only progresses to the first node of Ranvier. If the site of injury is close to the neuronal body, apoptosis may occur [13].

Apoptosis of neural cells could be triggered by two major principal pathways: the intrinsic (or mitochondrial) pathway and the extrinsic (or death receptor) pathway. The extrinsic apoptosis pathway is triggered by the ligation of tumor necrosis factor (TNF)-family death receptors at the cell surface, then recruit an adapter protein, TNF-R-associated death domain (TRADD), and activate the pro-apoptosis caspase-8. The intrinsic (mitochondrial) pathway of apoptosis is triggered within the cell, causing expression or activation of BH3-only proteins that activate Bax to form pores in the outer mitochondrial membrane, releasing cytochrome c to bind APAF-1, activating caspase-9. Finally, both caspase-8 or caspase-9 activate downstream of caspase-3 as the apoptosis executor [14–16].

* Corresponding author. J. Villa Kalijudan XV/ U 7-9, Surabaya, East Java, Indonesia.

E-mail addresses: ganaadyaksa@gmail.com (G. Adyaksa), heri-suroto@fk.unair.ac.id, hsuroto2000@yahoo.com (H. Suroto).

<https://doi.org/10.1016/j.amsu.2021.02.002>

Received 3 December 2020; Received in revised form 2 February 2021; Accepted 2 February 2021

Available online 17 February 2021

2049-0801/© 2021 Published by Elsevier Ltd on behalf of IJS Publishing Group Ltd. This is an open access article under the CC BY license

(<http://creativecommons.org/licenses/by/4.0/>).

Table 1
Sample's characteristics.

	Early Group	Late Group
Sample number	11	9
Gender	Male = 10 Female = 1	Male = 8 Female = 1
The average age	25 yo	29.9 yo
Mode of Injury	Motor Vehicle Accident (100%)	Motor Vehicle Accident (100%)
The average time to surgery (SD, Min-Max)	3.18 months (3,18; 1-6)	32 months (14,52; 10-62)
Biopsy location	C5 = 8, C6 = 3	C5 = 7, C6 = 1, C7 = 1

To date, there was no study evaluating the apoptosis of the proximal stump motorneuron in postganglionic brachial plexus injury and its relation to the surgical timing STS. This study aims to evaluate the evidence of apoptosis in the brachial plexus proximal stump and its correlation to surgical timing in postganglionic BPI patients and further investigate the possible pathway of the occurred apoptosis.

2. Methods

2.1. Type of study and sample

This research is a cross-sectional study. Proximal stump of brachial plexus biopsy from 20 postganglionic brachial plexus injury patients was obtained during brachial plexus nerve surgical procedures. The inclusion criteria for the samples are >18 years old postganglionic BPI patients that underwent nerve surgical procedures (nerve transfer, nerve grafting, or free functional muscle transfer) and excluded if there is a history of infection. They grouped based on the surgical timing, comprised of 11 patients in the early group (before six months post-trauma) and nine patients in the late group (after six months post-trauma). The written informed consent for biopsy was obtained from the patients. This study already had ethical clearance from the Health Study Ethical Committee of Dr. Soetomo General Hospital Surabaya, East Java, Indonesia.

2.2. Immunohistochemistry staining

The biopsy tissue is then fixed with 10% formalin and embedded in paraffin for immunohistochemistry staining. Immunohistochemistry staining was performed using Active Caspase-3 Monoclonal Antibody

Table 2

The immunohistochemistry expression and comparison analysis of Caspase-3, TNF- α , Caspase-8, and Caspase-9.

Variable	Group	N	Mean \pm SD	p ^a
Caspase-3	Early (<6 months)	11	1.52 \pm 0.78	p = 0.003
	Late (>6 months)	9	3.18 \pm 1.36	
TNF-α	Early (<6 months)	11	2.75 \pm 0.86	p = 0.001
	Late (>6 months)	9	1.38 \pm 0.42	
Caspase-8	Early (<6 months)	11	1.77 \pm 1.12	p = 0.001
	Late (>6 months)	9	3.96 \pm 1.28	
Caspase-9	Early (<6 months)	11	1.47 \pm 0.81	p = 0.004
	Late (>6 months)	9	3.24 \pm 1.54	

^a Independent T-Test.

(Bioenzy), TNF- α Monoclonal Antibody (Bioenzy), Caspase-8 Polyclonal Antibody (Bioenzy), and Caspase-9 Polyclonal Antibody (Bioenzy) according to manufacture protocol.

The study was presented in line with the STROCSS criteria [17] and already registered in the Chinese Clinical Trial Registry, and the unique identifying number (UIN) is ChiCTR2000039719 [18].

2.3. Data collection and analysis

A section from each sample's nerve stump in each group was photographed using a digital camera and tested microscopically. Ten randomly selected regions from each slice were evaluated for Caspase-3, TNF- α , Caspase-8, and Caspase-9. Under 400x magnification of a microscope, the motorneuron cell with brown cytoplasm was counted as Caspase-3/TNF- α /Caspase-8/Caspase-9 positive cell for each staining.

2.4. Statistical analysis

The mean and standard deviation of Caspase-3/TNF- α /Caspase-8/Caspase-9 positive cell of each group was calculated. Comparison analysis by independent *t*-test and correlation analysis by Pearson were performed using SPSS version 21. The difference in the expression of each parameter was regarded as statistically significant at p-value <0,05.

3. Results

There were 11 patients in the early group and nine patients in the late group, with the average time to surgery was 3,18 months and 32

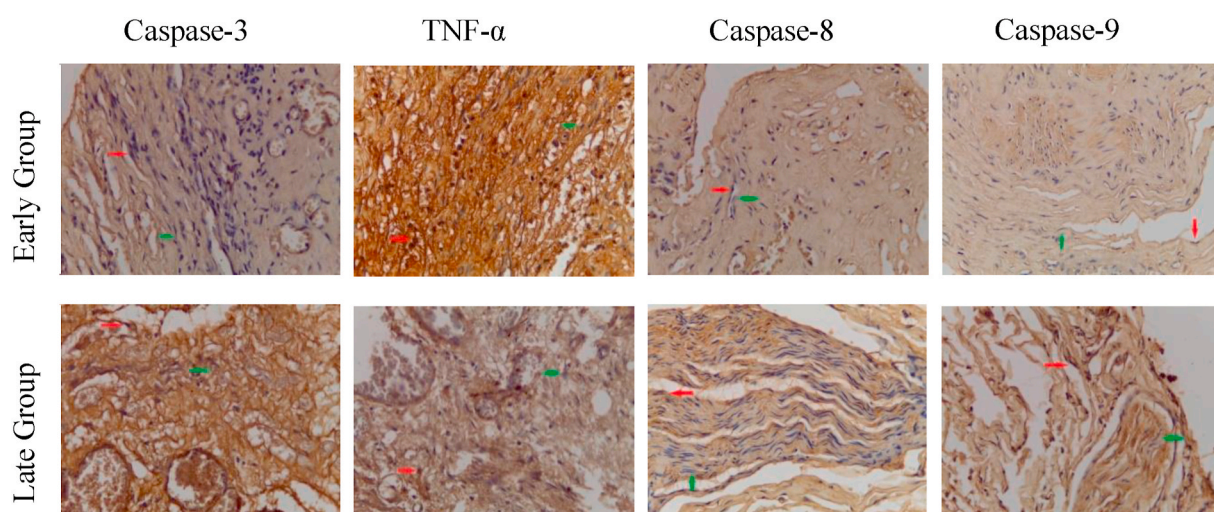


Fig. 1. Immunohistochemistry staining of Caspase-3, TNF- α , Caspase-8, and Caspase-9 expression on brachial plexus proximal stump, in the early group and late group. 400x magnification. (Red arrow = IHC positive cell. Green arrow = IHC negative cell). (For interpretation of the references to colour in this figure legend, the reader is referred to the Web version of this article.)

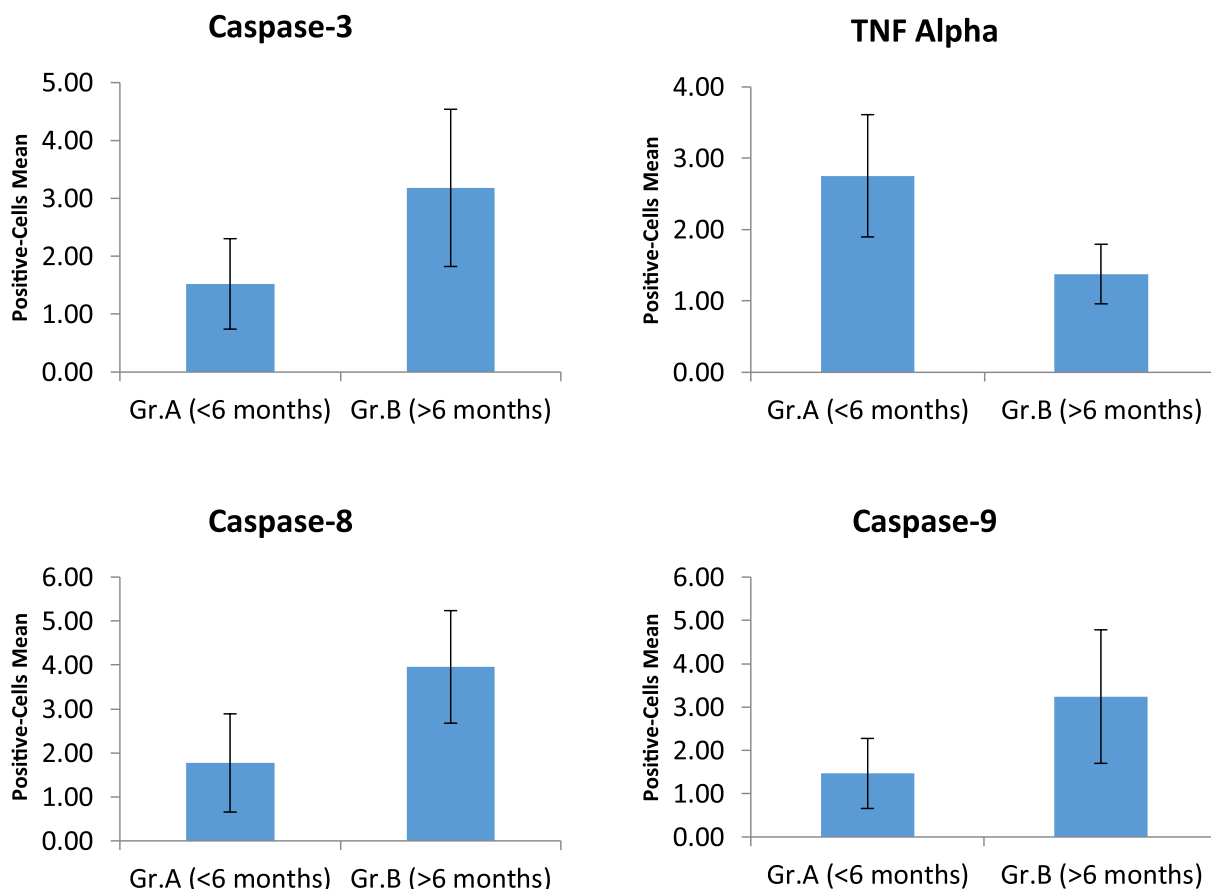


Fig. 2. The immunohistochemistry expression analysis of Caspase-3, TNF- α , Caspase-8, and Caspase-9.

Table 3

Comparison of the Caspase-8 and Caspase-9 expression on early and late group.

Group	Variable	N	Mean \pm SD	p ^a
< 6 months	Caspase-8	11	1.77 \pm 1.12	p = 0.212
	Caspase-9	11	1.47 \pm 0.81	
> 6 months	Caspase-8	9	3.96 \pm 1.28	p = 0.217
	Caspase-9	9	3.24 \pm 1.54	

^a Independent T-Test.

months, respectively. In both groups, most of the biopsy samples were obtained from the C5 root of the brachial plexus. Majority of the patients was male, and all of the injuries were caused by traffic accident (Table 1).

The average of Caspase-3 positive cells, with brown cytoplasm (Fig. 1), on the early group (1.52 \pm 0.78), was lower compared to on the late group (3.18 \pm 1.36) and statistically significant (p = 0.03) (Table 2 and Fig. 2). This suggesting that motorneuron apoptosis was higher in the late group (after six months post-trauma).

The average of TNF- α positive cells in the early group (2.75 \pm 0.86) was higher than in the late group (1.38 \pm 0.42) and statistically significant (p = 0.03) (Table 2 and Fig. 2). This suggests that the expression of TNF- α as an inflammatory mediator and the extrinsic apoptotic pathway's initiator was higher in the early phase of trauma (less than six months post-trauma) than in the late phase.

The Caspase-8 and Caspase-9 positive cells in the early group (1.77 \pm 1.12 and 1.47 \pm 0.81, respectively) were lower than in the late group (3.96 \pm 1.28 and 3.24 \pm 1.54) and statistically significant (p = 0.001 and p = 0.004) (Table 2 and Fig. 2). For the comparison between Caspase-8 and Caspase-9, the expression of Caspase-8 was higher than Caspase-9, both in the early and late group, but without statistically

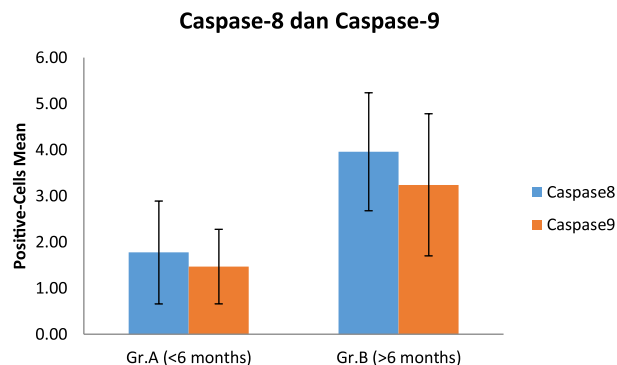


Fig. 3. The comparison of the Caspase-8 and Caspase-9 expression on early and late group.

Table 4

Correlation analysis of the TNF- α , Caspase-8, and Caspase-9 to the Caspase-3 expression.

Variable	N	Correlation test (Pearson)
TNF- α	20	p = 0.075; r = - 0.407
Caspase-3	20	
Caspase-8	20	p = 0.000; r = 0.792
Caspase-9	20	p = 0.008; r = 0.575

significant difference ($p > 0.005$) (Table 3 and Fig. 3).

Furthermore, in correlation analysis, there was no correlation between Caspase-3 expression and TNF Alpha expression. The number of Caspase-3, Caspase-8, and Caspase-9 positive cells was higher in the late group, and in the correlation analysis, there was a positive correlation between Caspase-8 and Caspase-3, and also between Caspase-9 and Caspase-3. (Table 4).

4. Discussion

In the BPI's microsurgical procedure, one of the essential factors determining the nerve procedure's success is the survival of the involved nerve's proximal stump. To date, the apoptosis of the proximal stump of the BPI patients and its relation with the surgical timing is still unclear.

The result of this study showed that apoptosis of motoneuron was undergone in the proximal stump of the brachial plexus, proven by the finding of the Caspase-3 positive cell as a marker of apoptosis event. Furthermore, the motoneuron's apoptosis level was higher in patients who had trauma for more than six months. It suggests that the apoptosis event in the brachial plexus is a timely fashion, which can become a consideration factor for determining the optimal time for nerve-related surgery.

TNF- α is one of the inflammatory mediators playing a role in the systemic response to trauma and infection. It regulates inflammatory responses after the injury to the peripheral or central nervous system and initiates the activation cascade of other cytokines and growth factors [18]. This might cause the expression of TNF- α in the <6 months the post-trauma group was higher than in the >6 months post-trauma group.

In apoptosis, the TNF- α 's biologic activity depends on the activity of their different membrane receptors, namely TNFR1 and TNFR2, which both have different signaling but also overlap [18]. The binding of TNF Alpha to the TNFR1 can activate the survival pathway of NF- κ B and even the caspase-dependent cell death. The binding of TNF Alpha to the TNFR1 activates the TNFR1, then binds the TRADD (TNFR-associated death domain) and bind the TRAFs (TNFR-associated factor) and RIP to activate the NF- κ B (Complex I), which is a survival pathway or anti-apoptosis. In the second step, TRADD and the kinase RIP1 associated with FADD (Fas-associated protein with death domain) and Caspase-8 form a cytoplasmic complex (Complex II), resulting in cell death [20,21].

This study found that the expression of TNF- α was not correlated with the expression of the Caspase-3 as an apoptosis marker. Furthermore, even though TNF alpha expression was higher in the early group than in the late group, the expression of pro-apoptosis caspase-8 and the apoptosis marker caspase-3 precisely low. This is following the result of the Harper et al. study, which states that Caspase-8 and FADD were not recruited to a TNF-induced membrane-bound receptor signaling complex as occurs during CD95 (Fas) or TRAIL (TNF-related apoptosis-inducing ligand) signaling, but instead must be activated elsewhere within the cells [22].

There was no significant difference in expression between Caspase-8 and Caspase-9, both in the early and late groups, so we cannot conclude which one of the apoptosis pathways that are more dominant in initiating apoptosis cascade on brachial plexus injury. Although initially suggested that the death receptor apoptosis pathway initiated through Caspase-8 and the mitochondria-mediated apoptosis pathway through Caspase-9 were two independent pathways, there was cross talk interaction between them. In particular conditions, Caspase-8 could cleave the cytosolic bid (BH3-interaction death domain agonist, one of the Bcl-2 family) and translocate to mitochondria and mediates the release of cytochrome c, and activates the Caspase-9 [21,23].

This limitation of this study is the limited sample number and limited surgical time grouping. Furthermore, more apoptotic proteins pathway, such as FAS, TNF-related pathway, and mitochondrial pathway, also needs to be explored to get a more comprehensive understanding of

apoptosis in BPI.

5. Conclusion

Apoptosis of proximal stump motoneuron plexus brachialis on more than six months post-trauma is higher than on less than six months post-trauma. This further supports the importance of performing nerve-procedure surgery in postganglionic BPI patients as early as possible to obtain the optimal result.

Funding/support statement

This research did not receive any specific grant from funding agencies in the public, commercial, or not-for-profit sectors.

Provenance and peer review

Not commissioned, externally peer-reviewed.

Declaration of competing interest

The authors declare no conflict of interest in this study.

Acknowledgment

None.

Appendix A. Supplementary data

Supplementary data to this article can be found online at <https://doi.org/10.1016/j.amsu.2021.02.002>.

References

- [1] W. Faglioni, M.G. Siqueira, R.S. Martins, C.O. Heise, L. Foroni, The epidemiology of adult traumatic brachial plexus lesions in a large metropolis, *Acta Neurochir.* 156 (2014) 1025–1028, <https://doi.org/10.1007/s00701-013-1948-x>.
- [2] S.S. Noland, A.T. Bishop, R.J. Spinner, A.Y. Shin, Adult traumatic brachial plexus injuries, *J. Am. Acad. Orthop. Surg.* 27 (2019) 705–716, <https://doi.org/10.5435/JAAOS-D-18-00433>.
- [3] R. Kaiser, P. Waldauf, G. Ullas, A. Krajcova, Epidemiology, etiology, and types of severe adult brachial plexus injuries requiring surgical repair: systematic review and meta-analysis, *Neurosurg. Rev.* 43 (2020) 443–452, <https://doi.org/10.1007/s10143-018-1009-2>.
- [4] H. Suroto, R.A. Putra, A. Karimah, Relationship between disability and pain to post-traumatic stress disorder, depression, and anxiety in patient with postoperative brachial plexus injury (BPI), *Br. J. Neurosurg.* (2020) 1–5, <https://doi.org/10.1080/02688697.2020.1784846>.
- [5] J.F. Plate, L.K. Ely, B.R. Pulley, B.P. Smith, Z. Li, Combined proximal nerve graft and distal nerve transfer for a posterior cord brachial plexus injury, *J. Neurosurg.* 118 (2013) 155–159, <https://doi.org/10.3171/2012.10.JNS12425>.
- [6] A.A. Maldonado, M.F. Kircher, R.J. Spinner, A.T. Bishop, A.Y. Shin, Free functioning gracilis muscle transfer with and without simultaneous intercostal nerve transfer to musculocutaneous nerve for restoration of elbow flexion after traumatic adult brachial pan-plexus injury, *J. Hand Surg. Am.* 42 (2017) 293.e1–293.e7, <https://doi.org/10.1016/j.jhsa.2017.01.014>.
- [7] S. Leechavongvongs, K. Malungpaishorpe, C. Uerpairojkit, C.Y. Ng, K. Witoonchart, Nerve transfers to restore shoulder function, *Hand Clin.* 32 (2016) 153–164, <https://doi.org/10.1016/j.hcl.2015.12.004>.
- [8] Z.S. Ali, G.G. Heuer, R.W.F. Faught, S.H. Kaneriya, U.A. Sheikh, I.S. Syed, S. C. Stein, E.L. Zager, Effectiveness of different repair techniques, *J. Neurosurg.* 122 (2015) 195–201, <https://doi.org/10.3171/2014.9.JNS132823.Disclosure>.
- [9] J.P. Chan, J. Clune, S.B. Shah, S.R. Ward, J.D. Kocsis, T. Mozaffar, O. Steward, R. Gupta, Examination of the human motor endplate after brachial plexus injury with two-photon microscopy, *Muscle Nerve* 61 (2020) 390–395, <https://doi.org/10.1002/mus.26778>.
- [10] R. Gupta, J.P. Chan, J. Uong, W.A. Palispis, D.J. Wright, S.B. Shah, S.R. Ward, T. Q. Lee, O. Steward, Human motor endplate remodeling after traumatic nerve injury, *J. Neurosurg.* (2020) 1–8, <https://doi.org/10.3171/2020.8.jns201461>, 0.
- [11] S. Jonsson, R. Wiberg, A.M. McGrath, L.N. Novikov, M. Wiberg, L.N. Novikova, P. J. Kingham, Effect of delayed peripheral nerve repair on nerve regeneration, schwann cell function and target muscle recovery, *PLoS One* 8 (2013), <https://doi.org/10.1371/journal.pone.0056484>.
- [12] A.A. Maldonado, A.T. Bishop, R.J. Spinner, A.Y. Shin, Five operations that give the best results after brachial plexus injury. <https://doi.org/10.1097/RS.0000000000003620>, 2017.

- [13] R.M.G. Menorca, T.S. Fussell, J.C. Elfar, Nerve physiology. Mechanisms of injury and recovery, *Hand Clin.* 29 (2013) 317–330, <https://doi.org/10.1016/j.hcl.2013.04.002>.
- [14] S. Gupta, Tumor necrosis factor- α -induced apoptosis in T cells from aged humans: a role of TNFR-I and downstream signaling molecules, *Exp. Gerontol.* 37 (2002) 293–299, [https://doi.org/10.1016/S0531-5565\(01\)00195-4](https://doi.org/10.1016/S0531-5565(01)00195-4).
- [15] M. Fricker, A.M. Tolkovsky, V. Borutaite, M. Coleman, G.C. Brown, Neuronal cell death, *Physiol. Rev.* 98 (2018) 813–880, <https://doi.org/10.1152/physrev.00011.2017>.
- [16] N. Van Opendenbosch, M. Lamkanfi, Caspases in cell death, inflammation, and disease, *Immunity* 50 (2019) 1352–1364, <https://doi.org/10.1016/j.immuni.2019.05.020>.
- [17] R. Agha, A. Abdall-Razak, E. Crossley, N. Dowlut, C. Iosifidis, G. Mathew, for the StrocSS Group, The STROCSS 2019 guideline: strengthening the reporting of cohort studies in surgery, *Int. J. Surg.* 72 (2019) 156–165.
- [18] Chinese Clinical Trial Register. Chengdu : Ministry of Health. Identifier ChiCTR2000039719, Apoptosis of proximal stump postganglionic brachial plexus injury, before and after 6 months post-trauma, (n.d.). <http://www.chictr.org.cn/showproj.aspx?proj=62860>.
- [20] G. Sreaton, X.N. Xu, T cell life and death signalling via TNF-receptor family members, *Curr. Opin. Immunol.* 12 (2000) 316–322, [https://doi.org/10.1016/S0952-7915\(00\)00093-5](https://doi.org/10.1016/S0952-7915(00)00093-5).
- [21] O. Micheau, J. Tschopp, Induction of TNF receptor I-mediated apoptosis via two sequential signaling complexes, *Cell* 114 (2003) 181–190, [https://doi.org/10.1016/S0092-8674\(03\)00521-X](https://doi.org/10.1016/S0092-8674(03)00521-X).
- [22] S. Gupta, A decision between life and death during, *J. Clin. Immunol.* 22 (2002).
- [23] N. Harper, M. Hughes, M. MacFarlane, G.M. Cohen, Fas-associated death domain protein and caspase-8 are not recruited to the tumor necrosis factor receptor I signaling complex during tumor necrosis factor-induced apoptosis, *J. Biol. Chem.* 278 (2003) 25534–25541, <https://doi.org/10.1074/jbc.M303399200>.