

Apoptosis of proximal stump postganglionic brachial plexus injury, before and after six months post-trauma

by Heri Suroto

Submission date: 26-Apr-2021 04:27PM (UTC+0800)

Submission ID: 1570093818

File name: 1-s2.0-S2049080121001060-main.pdf (1.7M)

Word count: 3367

Character count: 18096



ELSEVIER

Contents lists available at ScienceDirect

Annals of Medicine and Surgery

journal homepage: www.elsevier.com/locate/amsu

Cross-sectional Study

Apoptosis of proximal stump postganglionic brachial plexus injury, before and after six months post-trauma

Gana Adyaksa, Heri Suroto*

Department of Orthopedics & Traumatology, Faculty of Medicine, Universitas Airlangga / Dr. Soetomo General Academic Hospital, Surabaya, Indonesia



ARTICLE INFO

Keywords:

Postganglionic brachial plexus injury
Apoptosis
Proximal stump

ABSTRACT

Background: The success of the micro-surgery procedure for the treatment of postganglionic brachial plexus injury was influenced by several factors, including the surgical timing and also the viability of the proximal stump. This study evaluates the evidence of apoptosis in the brachial plexus proximal stump and its correlation with the surgical timing.

Methods: Proximal stump biopsy of postganglionic brachial plexus injury patients were obtained during nerve procedure surgery. The samples were grouped based on the surgical timing, before six months post-trauma (early group) and after six months post-trauma (late group). The apoptosis of motoneurons was evaluated by immunohistochemistry expression of Caspase-3, TNF- α , Caspase-8, and Caspase-9.

Results: Immunohistochemistry findings showed higher expression of Caspase-3 in the late group compared to the early group, as well as the expression of Caspase-8 and Caspase-9 ($p < 0,05$), and with a positive correlation between Caspase-8 and Caspase-9 to Caspase-3. Meanwhile, TNF- α expression was higher in the early group than the late group ($p < 0,05$) and with no correlation between TNF- α to Caspase-3.

Conclusion: Apoptosis of proximal stump motoneuron plexus brachialis on more than six months post-trauma is higher than on less than six months post-trauma.

1. Introduction

Brachial plexus injury (BPI) is a severe trauma that generally occurs in young and productive age patients, usually due to a traffic accident and an injury to the area between the neck and shoulders [1,2]. This injury causes loss of function and ability to carry out their daily activities and work activities, which will impact job loss, economic decline, depression, anxiety, and even suicide [3,4].

There are currently several surgical options for BPI, including nerve graft, nerve transfer, and functional muscle transfer [5–7]. The success of this micro-surgery procedure is influenced by several factors, including the timing of surgery. A systematic review study showed that BPI's surgical procedure performed less than six months after the trauma has a better outcome than if performed after six months post-trauma [8]. This is usually caused by motor endplate degeneration of more than six months of denervated muscle [9,10]. Furthermore, there was evidence that after six months post-trauma, the nerve regeneration capacity was significantly reduced [11].

In postganglionic brachial plexus injury, nerve grafting is one

alternative surgical procedure to restore some muscle functions [12]. In nerve grafting, the proximal stump's viability is essential to ensure the success of the grafting. After trauma, the brachial plexus proximal stump could undergo some particular event, depends on the involved damaged area. The breakdown of the proximal stump is limited and typically only progresses to the first node of Ranvier. If the site of injury is close to the neuronal body, apoptosis may occur [13].

Apoptosis of neural cells could be triggered by two major principal pathways: the intrinsic (or mitochondrial) pathway and the extrinsic (or death receptor) pathway. The extrinsic apoptosis pathway is triggered by the ligation of tumor necrosis factor (TNF)-family death receptors at the cell surface, then recruit an adapter protein, TNF-R-associated death domain (TRADD), and activate the pro-apoptosis caspase-8. The intrinsic (mitochondrial) pathway of apoptosis is triggered within the cell, causing expression or activation of BH3-only proteins that activate Bax to form pores in the outer mitochondrial membrane, releasing cytochrome c to bind APAF-1, activating caspase-9. Finally, both caspase-8 or caspase-9 activate downstream of caspase-3 as the apoptosis executor [14–16].

* Corresponding author. J. Villa Kalijudan XV / U 7-9, Surabaya, East Java, Indonesia.

E-mail addresses: ganaadyaksa@gmail.com (G. Adyaksa), heri-suroto@fk.unair.ac.id, hsuroto2000@yahoo.com (H. Suroto).

<https://doi.org/10.1016/j.amsu.2021.02.002>

Received 3 December 2020; Received in revised form 2 February 2021; Accepted 2 February 2021

Available online 17 February 2021

2049-0801/© 2021 The Authors. Published by Elsevier Ltd on behalf of IJS Publishing Group Ltd. This is an open access article under the CC BY license

<http://creativecommons.org/licenses/by/4.0/>.

Table 1
Sample's characteristics.

	Early Group	Late Group
Sample number	11	9
Gender	Male = 10 Female = 1	Male = 8 Female = 1
The average age	25 yo	29.9 yo
Mode of Injury	Motor Vehicle Accident (100%)	Motor Vehicle Accident (100%)
The average time to surgery (SD, Min-Max)	3.18 months (3,18; 1-6)	32 months (14,52; 10-62)
Biopsy location	C5 = 8, C6 = 3	C5 = 7, C6 = 1, C7 = 1

To date, there was no study evaluating the apoptosis of the proximal stump motoneuron in postganglionic brachial plexus injury and its relation to the surgical timing STS. This study aims to evaluate the evidence of apoptosis in the brachial plexus proximal stump and its correlation to surgical timing in postganglionic BPI patients and further investigate the possible pathway of the occurred apoptosis.

2. Methods

2.1. Type of study and sample

This research is a cross-sectional study. Proximal stump of brachial plexus biopsy from 20 postganglionic brachial plexus injury patients was obtained during brachial plexus nerve surgical procedures. The inclusion criteria for the samples are >18 years old postganglionic BPI patients that underwent nerve surgical procedures (nerve transfer, nerve grafting, or free functional muscle transfer) and excluded if there is a history of infection. They grouped based on the surgical timing, comprised of 11 patients in the early group (before six months post-trauma) and nine patients in the late group (after six months post-trauma). The written informed consent for biopsy was obtained from the patients. This study already had ethical clearance from the Health Study Ethical Committee of Dr. Soetomo General Hospital Surabaya, East Java, Indonesia.

2.2. Immunohistochemistry staining

The biopsy tissue is then fixed with 10% formalin and embedded in paraffin for immunohistochemistry staining. Immunohistochemistry staining was performed using Active Caspase-3 Monoclonal Antibody

Table 2
The immunohistochemistry expression and comparison analysis of Caspase-3, TNF- α , Caspase-8, and Caspase-9.

Variable	Group	N	Mean \pm SD	p ^a
Caspase-3	Early (<6 months)	11	1.52 \pm 0.78	p = 0.003
	Late (>6 months)	9	3.18 \pm 1.36	
TNF-α	Early (<6 months)	11	2.75 \pm 0.86	p = 0.001
	Late (>6 months)	9	1.38 \pm 0.42	
Caspase-8	Early (<6 months)	11	1.77 \pm 1.12	p = 0.001
	Late (>6 months)	9	3.96 \pm 1.28	
Caspase-9	Early (<6 months)	11	1.47 \pm 0.81	p = 0.004
	Late (>6 months)	9	3.24 \pm 1.54	

^a Independent T-Test.

(Bioenzy), TNF- α Monoclonal Antibody (Bioenzy), Caspase-8 Polyclonal Antibody (Bioenzy), and Caspase-9 Polyclonal Antibody (Bioenzy) according to manufacture protocol.

The study was presented in line with the STROCSS criteria [17] and already registered in the Chinese Clinical Trial Registry, and the unique identifying number (UIN) is ChiCTR2000039719 [18].

2.3. Data collection and analysis

A section from each sample's nerve stump in each group was photographed using a digital camera and tested microscopically. Ten randomly selected regions from each slice were evaluated for Caspase-3, TNF- α , Caspase-8, and Caspase-9. Under 400x magnification of a microscope, the motoneuron cell with brown cytoplasm was counted as Caspase-3/TNF- α /Caspase-8/Caspase-9 positive cell for each staining.

2.4. Statistical analysis

The mean and standard deviation of Caspase-3/TNF- α /Caspase-8/Caspase-9 positive cell of each group was calculated. Comparison analysis by independent t-test and correlation analysis by Pearson were performed using SPSS version 21. The difference in the expression of each parameter was regarded as statistically significant at p-value <0,05.

3. Results

There were 11 patients in the early group and nine patients in the late group, with the average time to surgery was 3,18 months and 32

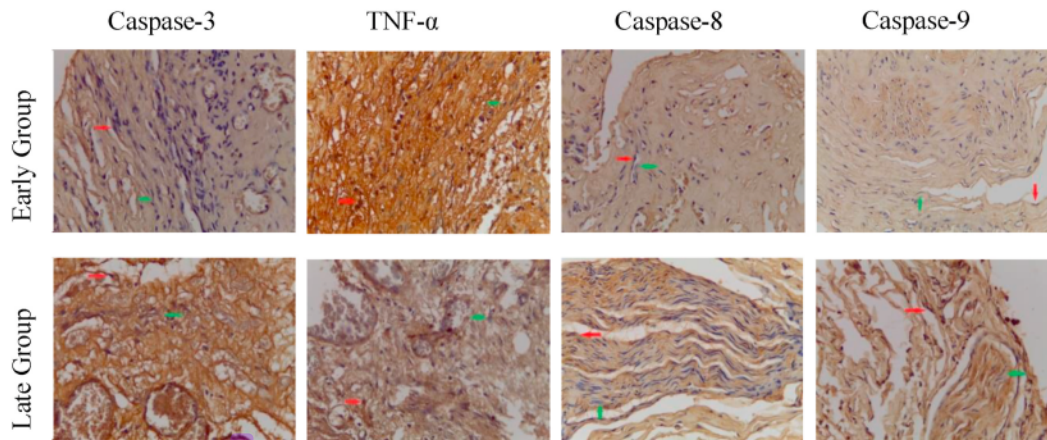


Fig. 1. Immunohistochemistry staining of Caspase-3, TNF- α , Caspase-8, and Caspase-9 expression on brachial plexus proximal stump, in the early group and late group. 400x magnification. (Red arrow = IHC positive cell. Green arrow = IHC negative cell). (For interpretation of the references to colour in this figure legend, the reader is referred to the Web version of this article.)

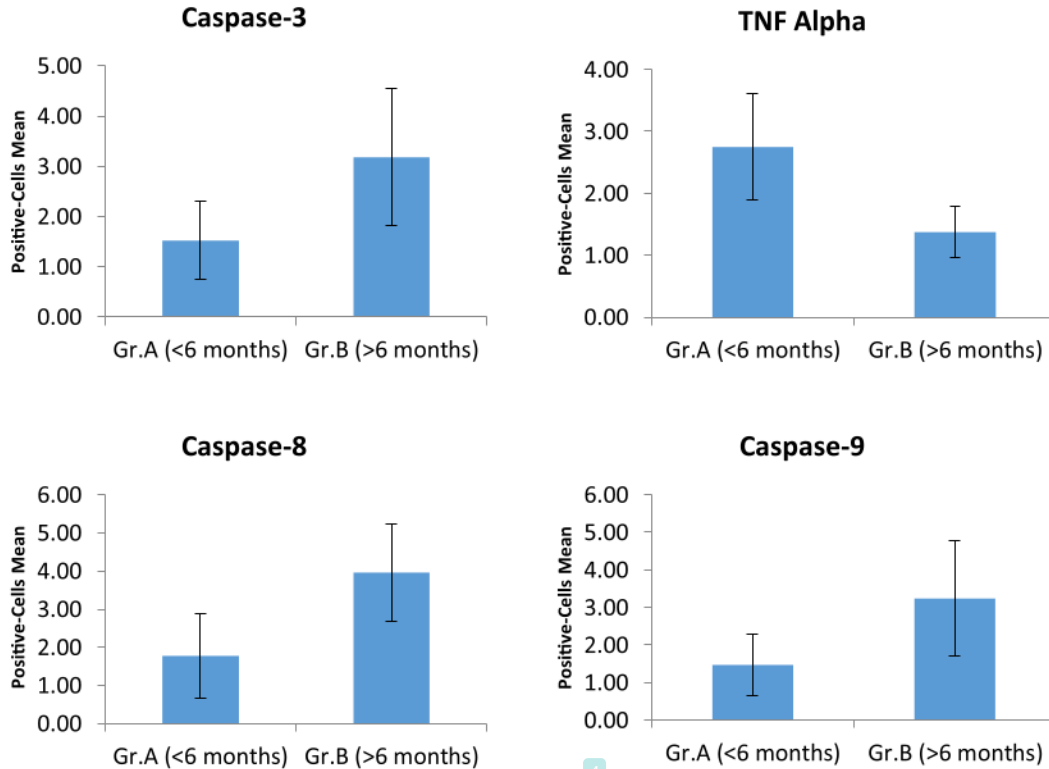


Fig. 2. The immunohistochemistry expression analysis of Caspase-3, TNF- α , Caspase-8, and Caspase-9.

Table 3
Comparison of the Caspase-8 and Caspase-9 expression on early and late group.

Group	Variable	N	Mean \pm SD	p ^a
< 6 months	Caspase-8	11	1.77 \pm 1.12	p = 0.212
	Caspase-9	11	1.47 \pm 0.81	
> 6 months	Caspase-8	9	3.96 \pm 1.28	p = 0.217
	Caspase-9	9	3.24 \pm 1.54	

^a Independent T-Test.

months, respectively. In both groups, most of the biopsy samples were obtained from the C5 root of the brachial plexus. Majority of the patients was male, and all of the injuries were caused by traffic accident (Table 1).

The average of Caspase-3 positive cells, with brown cytoplasm (Fig. 1), on the early group (1.52 \pm 0.78), was lower compared to on the late group (3.18 \pm 1.36) and statistically significant (p = 0.03) (Table 2 and Fig. 2). This suggesting that motoneuron apoptosis was higher in the late group (after six months post-trauma).

The average of TNF- α positive cells in the early group (2.75 \pm 0.86) was higher than in the late group (1.38 \pm 0.42) and statistically significant (p = 0.03) (Table 2 and Fig. 2). This suggests that the expression of TNF- α as an inflammatory mediator and the extrinsic apoptotic pathway's initiator was higher in the early phase of trauma (less than six months post-trauma) than in the late phase.

The Caspase-8 and Caspase-9 positive cells in the early group (1.77 \pm 1.12 and 1.47 \pm 0.81, respectively) were lower than in the late group (3.96 \pm 1.28 and 3.24 \pm 1.54) and statistically significant (p = 0.001 and p = 0.004) (Table 2 and Fig. 2). For the comparison between Caspase-8 and Caspase-9, the expression of Caspase-8 was higher than Caspase-9, both in the early and late group, but without statistically

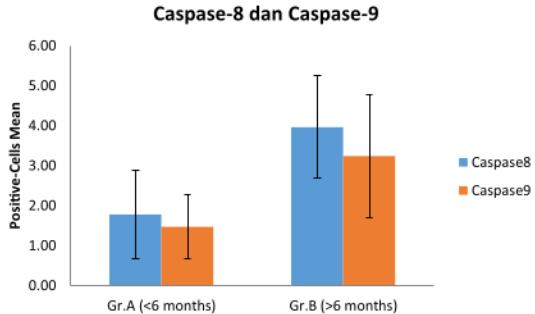


Fig. 3. The comparison of the Caspase-8 and Caspase-9 expression on early and late group.

Table 4
Correlation analysis of the TNF- α , Caspase-8, and Caspase-9 to the Caspase-3 expression.

Variable	N	Correlation test (Pearson)
TNF- α	20	p = 0.075; r = -0.407
Caspase-3	20	
Caspase-8	20	p = 0.000; r = 0.792
Caspase-9	20	
Caspase-3	20	p = 0.008; r = 0.575
Caspase-9	20	

significant difference ($p > 0.005$) (Table 3 and Fig. 3).

Furthermore, in correlation analysis, there was no correlation between Caspase-3 expression and TNF Alpha expression. The number of Caspase-3, Caspase-8, and Caspase-9 positive cells was higher in the late group, and in the correlation analysis, there was a positive correlation between Caspase-8 and Caspase-3, and also between Caspase-9 and Caspase-3. (Table 4).

4. Discussion

In the BPI's microsurgical procedure, one of the essential factors determining the nerve procedure's success is the survival of the involved nerve's proximal stump. To date, the apoptosis of the proximal stump of the BPI patients and its relation with the surgical timing is still unclear.

The result of this study showed that apoptosis of motoneuron was undergone in the proximal stump of the brachial plexus, proven by the finding of the Caspase-3 positive cell as a marker of apoptosis event. Furthermore, the motoneuron's apoptosis level was higher in patients who had trauma for more than six months. It suggests that the apoptosis event in the brachial plexus is a timely fashion, which can become a consideration factor for determining the optimal time for nerve-related surgery.

TNF- α is one of the inflammatory mediators playing a role in the systemic response to trauma and infection. It regulates inflammatory responses after the injury to the peripheral or central nervous system and initiates the activation cascade of other cytokines and growth factors [18]. This might cause the expression of TNF- α in the <6 months the post-trauma group was higher than in the >6 months post-trauma group.

In apoptosis, the TNF- α 's biologic activity depends on the activity of their different membrane receptors, namely TNFR1 and TNFR2, which both have different signaling but also overlap [18]. The binding of TNF Alpha to the TNFR1 can activate the survival pathway of NF- κ B and even the caspase-dependent cell death. The binding of TNF Alpha to the TNFR1 activates the TNFR1, then binds the TRADD (TNFR-associated death domain) and bind the TRAFs (TNFR-associated factor) and RIP to activate the NF- κ B (Complex I), which is a survival pathway or anti-apoptosis. In the second step, TRADD and the kinase RIP1 associated with FADD (Fas-associated protein with death domain) and Caspase-8 form a cytoplasmic complex (Complex II), resulting in cell death [20,21].

This study found that the expression of TNF- α was not correlated with the expression of the Caspase-3 as an apoptosis marker. Furthermore, even though TNF alpha expression was higher in the early group than in the late group, the expression of pro-apoptosis caspase-8 and the apoptosis marker caspase-3 precisely low. This is following the result of the Harper et al. study, which states that Caspase-8 and FADD were not recruited to a TNF-induced membrane-bound receptor signaling complex as occurs during CD95 (Fas) or TRAIL (TNF-related apoptosis-inducing ligand) signaling, but instead must be activated elsewhere within the cells [22].

There was no significant difference in expression between Caspase-8 and Caspase-9, both in the early and late groups, so we cannot conclude which one of the apoptosis pathways that are more dominant in initiating apoptosis cascade on brachial plexus injury. Although initially suggested that the death receptor apoptosis pathway initiated through Caspase-8 and the mitochondria-mediated apoptosis pathway through Caspase-9 were two independent pathways, there was cross talk interaction between them. In particular conditions, Caspase-8 could cleave the cytosolic bid (BH3-interaction death domain agonist, one of the Bcl-2 family) and translocate to mitochondria and mediates the release of cytochrome c, and activates the Caspase-9 [21,23].

This limitation of this study is the limited sample number and limited surgical time grouping. Furthermore, more apoptotic proteins pathway, such as FAS, TNF-related pathway, and mitochondrial pathway, also needs to be explored to get a more comprehensive understanding of

apoptosis in BPI.

5. Conclusion

Apoptosis of proximal stump motoneuron plexus brachialis on more than six months post-trauma is higher than on less than six months post-trauma. This further supports the importance of performing nerve-procedure surgery in postganglionic BPI patients as early as possible to obtain the optimal result.

Funding/support statement

This research did not receive any specific grant from funding agencies in the public, commercial, or not-for-profit sectors.

Provenance and peer review

Not commissioned, externally peer-reviewed.

Declaration of competing interest

The authors declare no conflict of interest in this study.

Acknowledgment

None.

Appendix A. Supplementary data

Supplementary data to this article can be found online at <https://doi.org/10.1016/j.amsu.2021.02.002>.

References

- [1] W. Faglioni, M.G. Siqueira, R.S. Martins, C.O. Heise, L. Foroni, The epidemiology of adult traumatic brachial plexus lesions in a large metropolis, *Acta Neurochir.* 156 (2014) 1025–1028, <https://doi.org/10.1007/s00701-013-1948-x>.
- [2] S.S. Noland, A.T. Bishop, R.J. Spinner, A.Y. Shin, Adult traumatic brachial plexus injuries, *J. Am. Acad. Orthop. Surg.* 27 (2019) 705–716, <https://doi.org/10.5435/JAAOS-D-18-00433>.
- [3] R. Kaiser, P. Waldauf, G. Ullas, A. Krajcová, Epidemiology, etiology, and types of severe adult brachial plexus injuries requiring surgical repair: systematic review and meta-analysis, *Neurosurg. Rev.* 43 (2020) 443–452, <https://doi.org/10.1007/s10143-018-1009-2>.
- [4] H. Suroto, R.A. Putra, A. Karimah, Relationship between disability and pain to post-traumatic stress disorder, depression, and anxiety in patient with postoperative brachial plexus injury (BPI), *Br. J. Neurosurg.* (2020) 1–5, <https://doi.org/10.1080/02688697.2020.1784846>.
- [5] J.F. Plate, L.K. Ely, B.R. Pulley, B.P. Smith, Z. Li, Combined proximal nerve graft and distal nerve transfer for a posterior cord brachial plexus injury, *J. Neurosurg.* 118 (2013) 155–159, <https://doi.org/10.3171/2012.10.JNS12425>.
- [6] A.A. Maldonado, M.F. Kircher, R.J. Spinner, A.T. Bishop, A.Y. Shin, Free functioning gracilis muscle transfer with and without simultaneous intercostal nerve transfer to musculocutaneous nerve for restoration of elbow flexion after traumatic adult brachial plexus injury, *J. Hand Surg. Am.* 42 (2017) 293.e1–293.e7, <https://doi.org/10.1016/j.jhsa.2017.01.014>.
- [7] S. Leechavengvongs, K. Malungpaishorpe, C. Uerpairojkit, C.Y. Ng, K. Wittoonchart, Nerve transfers to restore shoulder function, *Hand Clin.* 32 (2016) 153–164, <https://doi.org/10.1016/j.hcl.2015.12.004>.
- [8] Z.S. Ali, G.G. Heuer, R.W.F. Faught, S.H. Kaneriyi, U.A. Sheikh, I.S. Syed, S. C. Stein, E.L. Zager, Effectiveness of different repair techniques, *J. Neurosurg.* 122 (2015) 195–201, <https://doi.org/10.3171/2014.9.JNS132823>. Disclosure.
- [9] J.P. Chan, J. Clune, S.B. Shah, S.R. Ward, J.D. Kocsis, T. Mozaffar, O. Steward, R. Gupta, Examination of the human motor endplate after brachial plexus injury with two-photon microscopy, *Muscle Nerve* 61 (2020) 390–395, <https://doi.org/10.1002/mus.26778>.
- [10] R. Gupta, J.P. Chan, J. Uong, W.A. Palispis, D.J. Wright, S.B. Shah, S.R. Ward, T. Q. Lee, O. Steward, Human motor endplate remodeling after traumatic nerve injury, *J. Neurosurg.* (2020) 1–8, <https://doi.org/10.3171/2020.8.jns201461>, 0.
- [11] S. Jonsson, R. Wiberg, A.M. McGrath, L.N. Novikov, M. Wiberg, L.N. Novikova, P. J. Kingham, Effect of delayed peripheral nerve repair on nerve regeneration, schwann cell function and target muscle recovery, *PLoS One* 8 (2013), <https://doi.org/10.1371/journal.pone.0056484>.
- [12] A.A. Maldonado, A.T. Bishop, R.J. Spinner, A.Y. Shin, Five operations that give the best results after brachial plexus injury. <https://doi.org/10.1097/RS.0000000000003620>, 2017.

- [13] R.M.G. Menorca, T.S. Fussell, J.C. Elfar, Nerve physiology. Mechanisms of injury and recovery, *Hand Clin.* 29 (2013) 317–330, <https://doi.org/10.1016/j.hcl.2013.04.002>.
- [14] S. Gupta, Tumor necrosis factor- α -induced apoptosis in T cells from aged humans: a role of TNFR-I and downstream signaling molecules, *Exp. Gerontol.* 37 (2002) 293–299, [https://doi.org/10.1016/S0531-5565\(01\)00195-4](https://doi.org/10.1016/S0531-5565(01)00195-4).
- [15] M. Fricker, A.M. Tolkovsky, V. Borutaite, M. Coleman, G.C. Brown, Neuronal cell death, *Physiol. Rev.* 98 (2018) 813–880, <https://doi.org/10.1152/physrev.00011.2017>.
- [16] N. Van Opdenbosch, M. Lamkanfi, Caspases in cell death, inflammation, and disease, *Immunity* 50 (2019) 1352–1364, <https://doi.org/10.1016/j.immuni.2019.05.020>.
- [17] R. Agha, A. Abdall-Razak, E. Crossley, N. Dowlut, C. Iosifidis, G. Mathew, for the StrocSS Group, The STROCCS 2019 guideline: strengthening the reporting of cohort studies in surgery, *Int. J. Surg.* 72 (2019) 156–165.
- [18] Chinese Clinical Trial Register. Chengdu : Ministry of Health. Identifier ChiCTR2000039719, Apoptosis of proximal stump postganglionic brachial plexus injury, before and after 6 months post-trauma, (n.d.). <http://www.chictr.org.cn/showproj.aspx?proj=62860>.
- [20] G. Sreaton, X.N. Xu, T cell life and death signalling via TNF-receptor family members, *Curr. Opin. Immunol.* 12 (2000) 316–322, [https://doi.org/10.1016/S0952-7915\(00\)00093-5](https://doi.org/10.1016/S0952-7915(00)00093-5).
- [21] O. Micheau, J. Tschopp, Induction of TNF receptor I-mediated apoptosis via two sequential signaling complexes, *Cell* 114 (2003) 181–190, [https://doi.org/10.1016/S0092-8674\(03\)00521-X](https://doi.org/10.1016/S0092-8674(03)00521-X).
- [22] S. Gupta, A decision between life and death during, *J. Clin. Immunol.* 22 (2002).
- [23] N. Harper, M. Hughes, M. MacFarlane, G.M. Cohen, Fas-associated death domain protein and caspase-8 are not recruited to the tumor necrosis factor receptor 1 signaling complex during tumor necrosis factor-induced apoptosis, *J. Biol. Chem.* 278 (2003) 25534–25541, <https://doi.org/10.1074/jbc.M303399200>.

Apoptosis of proximal stump postganglionic brachial plexus injury, before and after six months post-trauma

ORIGINALITY REPORT

21 %
SIMILARITY INDEX

15 %
INTERNET SOURCES

17 %
PUBLICATIONS

0 %
STUDENT PAPERS

PRIMARY SOURCES

1 ecommons.aku.edu 3 %
Internet Source

2 journals.physiology.org 3 %
Internet Source

3 dmauldin.gdxbase.org 1 %
Internet Source

4 Satoru Yui, Tomoya Kudo, Kazumi Hodono, Yoshihiro Mimaki, Minpei Kuroda, Yutaka Sashida, Masatoshi Yamazaki. "Characterization of the growth-inhibitory and apoptosis-inducing activities of a triterpene saponin, securioside B against BAC1.2F5 macrophages", Mediators of Inflammation, 2003 1 %
Publication

5 ousar.lib.okayama-u.ac.jp 1 %
Internet Source

6 Ron M.G. Menorca, Theron S. Fussell, John C. Elfar. "Nerve Physiology", Hand Clinics, 2013 1 %
Publication

7	pubmed.ncbi.nlm.nih.gov Internet Source	1 %
8	rd.springer.com Internet Source	1 %
9	repository.unair.ac.id Internet Source	1 %
10	www.chictr.org.cn Internet Source	1 %
11	Issam Jandou, Adnan Ettanji, Ettaouil Mohammed, Amine Moataz, Dakir Mohammed, Adil Debbagh, Rachid Aboutaieb. "Mucosal urinary secretion revealing adenocarcinoma of urachus", <i>Annals of Medicine and Surgery</i> , 2021 Publication	1 %
12	Leet, A.S.. "Influence of CNI-Free versus CNI-Based Immunosuppression on Rejection and Infection After Heart Transplantation", <i>Heart, Lung and Circulation</i> , 2007 Publication	1 %
13	Nicholas Harper, Michelle Hughes, Marion MacFarlane, Gerald M. Cohen. "Fas-associated Death Domain Protein and Caspase-8 Are Not Recruited to the Tumor Necrosis Factor Receptor 1 Signaling Complex during Tumor Necrosis Factor-induced	1 %

Apoptosis", Journal of Biological Chemistry,
2003

Publication

14

cancerres.aacrjournals.org

Internet Source

1 %

15

Cheng, G.. "Apoptosis induced by simvastatin in rat vascular smooth muscle cell through Ca²⁺-calpain and caspase-3 dependent pathway", Pharmacological Research, 200312

Publication

1 %

16

journal2.unusa.ac.id

Internet Source

1 %

17

Mansour A. Alghamdi, Abdelaziz M. Hussein, Laith N. AL-Eitan, Eman Elnashar et al.
"Possible mechanisms for the renoprotective effects of date palm fruits and seeds extracts against renal ischemia/reperfusion injury in rats", Biomedicine & Pharmacotherapy, 2020

Publication

<1 %

18

ascopubs.org

Internet Source

<1 %

19

C. Baral. "A knowledge based approach for representing and reasoning about signaling networks", Bioinformatics, 08/04/2004

Publication

<1 %

20

Sergio E. Flores, Kristina R. Borak, Alan L. Zhang. "Hip Arthroscopic Surgery for

<1 %

Femoroacetabular Impingement: A Prospective Analysis of the Relationship Between Surgeon Experience and Patient Outcomes", Orthopaedic Journal of Sports Medicine, 2018

Publication

21

link.springer.com

Internet Source

<1 %

22

www.mdpi.com

Internet Source

<1 %

23

Gupta, S.. "CD95-mediated apoptosis in naive, central and effector memory subsets of CD4+ and CD8+ T cells in aged humans", Experimental Gerontology, 200804

Publication

<1 %

Exclude quotes Off

Exclude matches < 10 words

Exclude bibliography On

Apoptosis of proximal stump postganglionic brachial plexus injury, before and after six months post-trauma

GRADEMARK REPORT

FINAL GRADE

/100

GENERAL COMMENTS

Instructor

PAGE 1

PAGE 2

PAGE 3

PAGE 4

PAGE 5
