

Tekelan Leaves (*Chromolaena odorata*) Infusion and 10% Povidone-Iodine on Incision Wound Healing Process of Mice (*Mus musculus*) Infected with *Staphylococcus aureus*

by Iwan Sahrial Hamid

Submission date: 21-Jul-2021 12:28PM (UTC+0800)

Submission ID: 1622231164

File name: Bukti_C_01_Molecular_Docking_of_Ferulic_Acid....pdf (288.29K)

Word count: 4649

Character count: 25580

Tekelan Leaves (*Chromolaena odorata*) Infusion and 10% Povidone-Iodine on Incision Wound Healing Process of Mice (*Mus musculus*) Infected with *Staphylococcus aureus*

Arif Caesar Budi¹, Iwan Sahrial Hamid^{1*}, and Djoko Legowo²

¹Department of Veterinary Basic Medicine, Faculty of Veterinary Medicine, Universitas Airlangga, Surabaya-60115, Indonesia

²Department of Veterinary Pathology, Faculty of Veterinary Medicine, Universitas Airlangga, Surabaya-60115, Indonesia

*Corresponding author's Email: kelana_dawley68@yahoo.com; ORCID: 0000-0001-6786-7491

ABSTRACT

Skin is considered to be the most prone organ to injury and infection compared to other body organs. Skin infections are most commonly caused by *Staphylococcus aureus*. The most commonly used synthetic drugs to overcome skin problems is Povidone-iodine. Considering the Indonesian traditional method, injuries could be cured by dripping Tekelan leaves (*Chromolaena odorata*) infusion on the wounded skin area. This study aimed to compare the treatment effects of Tekelan leaves (*Chromolaena odorata*) infusion and povidone-iodine in the wound healing process of mice skin. The subjects of this study were 25 mice (*Mus musculus*) which were incised and infected with *Staphylococcus aureus* in 5 groups, namely, P0 (without treatment), P1 (povidone-iodine 10%), P2 (Tekelan infusion 5%), P3 (Tekelan infusion 10%), and P4 (Tekelan infusion 20%). Observations were made microscopically on wound conditions based on a total assessment of the four observed parameters (epithelization, inflammation rate, connective tissue proliferation, and angiogenesis). The results showed that the total observation score in the P0 and P2 groups was lower than the other groups. The P1 group obtained the highest score. The Kruskal-Wallis test showed a significant difference among the treatment groups ($p < 0.05$). While the Mann Whitney test indicated P1 had a significant difference with P0, P2, and P3, it had no significant difference with P4. It can be concluded that the Tekelan Leaves (*Chromolaena odorata*) infusion can be used as an alternative of povidone-iodine with an optimal concentration of 20%.

Keywords: *Chromolaena odorata*, Histopathology, Povidone-iodine, Skin, Wound healing

INTRODUCTION

Skin protects the organs and underlying tissues of a human body from environmental harms, including ultraviolet radiation, chemicals, allergens, and microorganisms. The skin also plays a pivotal role in the process of homeostasis by regulating body temperature and blood pressure. Skin as an organ that interacts directly with the environment often experiences injuries induced by surgery, burns, and accidents. Skin can become infected during the process of healing, through which a microorganism enters the body and multiplies. The infection itself can be caused by a variety of factors, including bacteria, viruses, fungi, and parasites. In fact, all open wounds contain and are contaminated with different levels of bacteria until successful wound closure has been accomplished (Hamer et al., 1975). One of the bacteria that often cause wound infections in the skin is *Staphylococcus aureus*.

Staphylococcus aureus is a flora normally found on the skin. *Staphylococcus aureus* infection can be transmitted directly through the mucous membranes that are in contact with the skin leading to festering inflammation (Jawetz et al., 2013). Synthetic drugs that contain various chemicals to treat wound infections have been developed and are available in the market. However, these costly synthetic drugs have side effects and can harm vital organs since they can be toxic. One of the most frequent examples of synthetic drugs used in wound healing, especially on the skin, is povidone-iodine (Sammartino et al., 2012). This antiseptic is considered a safe alternative to antibiotics for surgeries with a high risk of wound infection induced by operative bacterial contamination (Gilmore et al., 1997). Therefore, *Chromolaena odorata* (Tekelan) is regarded as an inexpensive and efficient alternative substitute with fewer side effects and a lower level of toxicity.

Chromolaena odorata is a kind of weed that quickly grows and covers open areas, such as plantations. The herbicides that are used in the extermination of this weed can cause pollution in the soil and the surrounding environment (Mugwedi, 2020). Although this plant causes problems, inhabitants of some regions in Indonesia (e.g., Aceh) have traditionally been accustomed to using the Tekelan leaves to treat diabetes and ulcers. Tekelan leaves have also been applied traditionally in Vietnam and several other tropical countries to treat leech bites, soft tissue injuries, burns, and skin infections. The infusion is extracted by squeezing young leaves until they break, and the resulting liquid is used to treat skin sores (Marianne et al., 2014). Tekelan leaves can be used as malaria or jaundice treatment or an antipyretic

ORIGINAL ARTICLE
pII: S232245682100008-11
Received: 01 Jan 2021
Accepted: 19 Feb 2021

agent (Vital and Rivera, 2009) since they have antibacterial, antifungal, and antiprotozoal effects (Atindehou et al., 2013).

Tekelan leaves contain flavonoids, saponins, and tannins (Ngozi et al., 2009). Flavonoid compounds are known to function as antibacterial, antifungal, antiviral⁶ and anti-inflammatory agents. Saponin stimulates the formation of collagen which is a structural protein playing a role in the¹⁷ process of wound healing. Saponin as well as tannin has an antibacterial function. With this background in mind, it is necessary to conduct a comparative study on the histopathological differences induced by the effects of Tekelan leaves (*Chromolaena odorata*) infusion and povidone-iodine on mice (*Mus musculus*) infected with *Staphylococcus aureus*. In addition, the present study sought to determine the optimal concentration of Tekelan leaves infusion by analyzing the obtained score of each method.

MATERIALS AND METHODS

Materials

Tekelan leaves (*Chromolaena odorata*) obtained from the slopes of Mount Penanggungan, Pasuruan, East Java were used in the current study. Povidone-iodine 10% was used as a comparison benchmark in wound healing tests. Ketamine was administered as an anesthetic drug. *Staphylococcus aureus* was used as an infectious agent. Polyzwitterions (PZ) was utilized as a bacterial suspension material which could improve the antibiofouling properties of membrane surfaces. H₂SO₄ and BaCl₂ were used as raw material for McFarland's solution. Mannitol Salt Agar was used as a medium for bacterial propagation. Bacterial identification test was performed using the following materials: carbol gentian violet, Lugol, H₂O₂, safranin, acetone alcohol, emersion oil, 70% ethanol, and rabbit blood plasma. Fish pellets were used as mice feed. Other materials used in the preparation of histopathological consisted of Haematoxylin-Eosin dyes, alcohol, xylol, paraffin, and 10% formalin.

Animal

The sample in this study consisted of 25 white male mice BALB/c, aged 1.5-2 months old with a weight of 25-30 grams obtained from the Farm Veterinary Center in Surabaya. *Staphylococcus aureus* bacteria²³ was used as an agent model to infect incision wounds obtained from the Veterinary Bacteriology and Mycology Laboratory, Faculty of Veterinary Medicine, Universitas Airlangga, Surabaya, Indonesia.

Making Tekelan Leaves Simplisia

Tekelan leaves (*Chromolaena odorata*) simplisia was made by drying the leaves at a moderately high temperature to eliminate the possibility of changes in active ingredient compounds. The followed stages included raw material collection, wet sorting, washing, and drying without direct sunlight (DepKes, 1995).

Manufacture of Tekelan Leaves Infusion

Tekelan leaves infusion was made with a concentration of 5%, 10%, and 20%. The 20% infusion was prepared using 20 grams of Tekelan leaves simplisia put into the pan with 100 ml of water and heated 15 minutes. When it reached 90°C, the mixture was occasionally stirred. The extract was filtered using flannel cloth while it was still hot. In case the volume of water reached below 100 ml, hot water was added in the pulp to obtain the volume of 100 ml (DepKes, 1995). The concentration of 10% and dilution of 5% was obtained from the infusion of 20% concentration.

Clinical Trials

Adaptation of Experimental Animals²⁵

Before the initiation of the study, all mice were adapted to the environment⁶ ± 7 days to control their health conditions. The daily feeding system of experimental animals was the same. All 25 mice were divided into 5 treatment groups while each treatment group contained 5 mice. The group that received no treatment was set as a negative control (P0), Povidone-iodine 10% group was considered as a positive control (P1), infusion treatment groups 5% as P2, 10% as P3, and finally, 20%²⁹ as P4. The mice were weighed after the adaptation period. The adaptation of experimental animals was carried out in experimental animal cages of Veterinary Medicine Faculty, Universitas Airlangga.

Suspension of *Staphylococcus aureus*

Some bacterial colonies *Staphylococcus aureus* obtained from the Bacteriology and Mycology Laboratory of the Faculty of Veterinary Medicine, Universitas Airlangga were bred to the media Mannitol Salt Agar (MSA) and incubated at 37°C for 24 hours. Afterwards, identification was carried out to the species stage, namely rejuvenation on MSA¹

media, gram staining, and catalase test up to coagulase test. Furthermore, the suspension was made by taking several colonies of *Staphylococcus aureus* to be put into a test tube that contains 10 ml of PZ.

Staphylococcus aureus Dose

The lowest score for 100% infecting experimental animals was obtained by comparing the density of the colony suspension *Staphylococcus aureus* with McFarland concentration on number 1 (3x10⁸ cells/ml), following that a 10-2 series dilution was made by taking 1 ml from the previous tube into 9 ml PZ to obtain a bacterial count of 3x10⁶ cells/ml. (Umar et al., 2012)

Experimental Animal Treatment

After the experimental animals were adapted, 25 mice (*Mus musculus*) were first anesthetized by ketamine with a dose of 40 mg/kg body weight for each mouse. In the next step, the fur of the wound section was shaved. In order to make the wound, the mice were incised on the *musculus gluteus medius* of the right hand using a scalpel of 1 cm long and 2 mm deep. In the next step, the skin was stretched with the index finger and thumb of the left hand, acting as stretchers and presses. Scalpel held by the right hand formed an angle of 30-40 degrees on the skin. The incision was made by dragging the scalpel toward the caudal (Chandra et al., 2018). Afterwards, the wounds were infected using *Staphylococcus aureus* by dropping the bacterial suspension of 10 µl using a micropipette (Umar et al., 2012). All 25 mice were then randomly divided into 5 treatment groups. The P0 treatment group that received treatment was set as the negative control, P1 was given povidone-iodine 10% as the positive control, P2 was subjected to Tekelan leaves infusion concentration of 5%, P3 was treated using Tekelan leaves infusion concentration of 10%, and P4 was given Tekelan leaves infusion concentration of 20%. Topical treatment was given by dripping with a solution of Tekelan leaves and povidone-iodine 10% in 1 drop of Pasteur pipette. The treatment was carried out twice a day with a 12-hour interval for ten days. It was started from the second day after the experimental animals were being infected with *Staphylococcus aureus*. After ten days, euthanization was carried out on mice by cervicalis (breaking joints atlantooccipitalis) dislocation. Finally, the skin area was taken to sample the wound for the preparation of histopathological preparations.

Experimental Design

This research was conducted during March 2017. The research process was carried out in the Bacteriology and Mycology Laboratory as well as the Experimental Animals Quarantine of the Faculty of Veterinary Medicine, Universitas Airlangga, Campus C, Mulyorejo, Surabaya. This research was an experimental study in a laboratory with a completely randomized design (CRD) since there was only one source of diversity, namely the treatment that was discriminated against in addition to random influences (Kusriningrum, 2008). Table 1 shows the scoring details of each observed parameter.

Table 1. Score on each parameter in wound healing process of Mice

Parameters	Treatment	Description
Epithelialization	Score 0	No epithelialization occurs
	Score 1	Epithelium formed (0-25%)
	Score 2	Epithelium formed (25-50%)
	Score 3	Epithelium formed (50-75%)
	Score 4	Epithelium formed (75-100%)
The level of inflammation is based on the number of inflammatory cells in the five fields of view at a magnification of 1000	Score 0	More than 100
	Score 1	75-100
	Score 2	50-75
	Score 3	25-50
	Score 4	Less than 25
Proliferation of connective tissue is based on comparison of the number of fibroblasts in the wound area with normal areas	Score 0	5 times normal tissue
	Score 1	4 times the normal tissue
	Score 2	3 times the normal tissue
	Score 3	2 times the normal tissue
	Score 4	equal or less than 2 times of the normal network
Angiogenesis is based on a comparison between the number of blood vessels that form in the wound and the normal area	Score 0	5 times normal tissue
	Score 1	4 times the normal tissue
	Score 2	3 times the normal tissue
	Score 3	2 times the normal tissue
	Score 4	equal or less than 2 times of the normal network

Experimental design

The examination was carried out by observing the histopathological picture of five treatments with each of five replications on the microscope addressing four parameters of epithelialization, level of inflammation, proliferation of connective tissue, and angiogenesis (Greenhalgh et al., 1990). Statistical method was based on ANOVA method, and completely randomized design (CRD) was conducted. Observations were based on four parameters in five treatments; starting from the first observation of the incised wound area then being shifted 9 twice to the left and twice to the right horizontally. Then a score of zero to four is performed according to the results of microscopic observations on each parameter observed and totaled.

Data Analysis

The data on the healing property of Tekelan leaves infusion on mice incision wound that was infected with *Staphylococcus aureus* was obtained from the wound healing value of each treatment group. The data were analyzed statistically using the *Kruskal-Wallis* proceeded with the *Mann Whitney* test. P-value less than 0.05 was considered statistically significant. Statistical analysis was performed using the SPSS software, version 20.

RESULTS

The obtained results of the *Kruskal-Wallis* test indicated that H0 was rejected ($p = 0.009$) and H1 was accepted. This means that there was a histopathological difference in the skin between the administrations of Tekelan leaves (*Chromolaena odorata*) infused with povidone-iodine 10% in the mice (*Mus musculus*) infected with *Staphylococcus aureus*. To find out more about the differences between the treatment groups and povidone-iodine groups, the *Mann Whitney Test* was performed later. The findings of the *Mann Whitney* test revealed that P1 significantly differed from P0 and P2 ($p=0.030$). Likewise, there was a significant difference between P1 and P3 ($p=0.007$). However, the comparison of P1 and P4 indicated that there was no significant difference. Table 2 indicated the results of the average and standard deviation. Based on Table 2 the highest average values were for the treatment groups of P1, P3, and P4 with the mean values of 12.80, 10.20, 11.20, respectively. The P2 and P0 treatment groups means of 9.40 and 9.20 had the lowest value. Table 1 reveals the significant difference between P1 and the treatment groups of P0, P2, P3, and P4.

Table 2. Mean and standard deviation of histopathological score of the skin

Treatment group	Skin histopathological score (X ± SD)
P0 (without treatment)	9.20 ± 1.92 ^a
P1 (Povidone-iodine 10%)	12.80 ± 0.45 ^b
P2 (Tekelan Infusion 5%)	9.40 ± 1.82 ^a
P3 (Tekelan Infusion 10%)	10.20 ± 0.84 ^a
P4 (Tekelan Infusion 20%)	11.20 ± 1.30 ^{ab}

Note: Different superscripts in the same column show a significant difference based on the *Mann Whitney* test ($p < 0.05$). X: Mean, SD: Standard deviation.

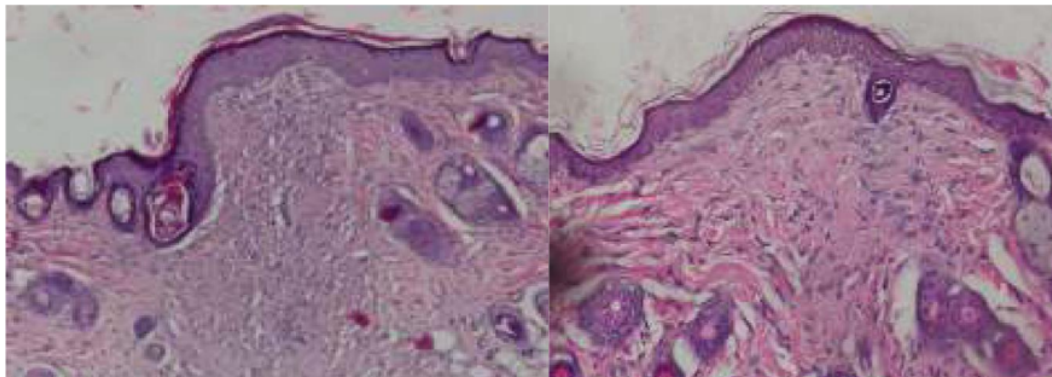


Figure 1. P0 and P1 with a magnification of 100X in wound healing process of mice (*Mus musculus*) infected with *Staphylococcus aureus*

Histopathological description

Based on microscopic observations of the wound area, the histopathological picture of mice skin for each treatment group indicated closure on the tenth day of epithelialization. The level of inflammation in the treatment group of P0, P2, and P3 was still high, compared to the other groups, and the least was found in the treatment P1. The connective tissue and angiogenesis were also observed in the same order of occurrence. The new capillaries and fibroblasts were found to be quite dense in P0, P2, and P3, compared to other groups and decreased in number in the P4 group. As can be seen in Figure 1, the P1 group was the one with the least new capillaries and had fibroblasts that had begun to lose in contrast to the other treatment groups. In P0 treatment group, there was a marked difference especially in the level of inflammation that appeared to be very dark blue. The color was due to the high number of inflammatory cells and fibroblasts in the healing area and the maturity of the collagen coils on the edge of the healing area which was red in color and visible on P1.

DISCUSSION

Concerning the healing process of the investigated samples infected with *Staphylococcus aureus*, a histopathological difference was observed between the healed skin by the administration of infused Tekelan leaves (*Chromolaena odorata*) and the one with povidone-iodine 10%. The samples in the P1 group (the administration of povidone-iodine 10%) significantly differed from those with no treatment group (P0), 5% infusion administration (P2), and 10% infusion administration (P3). The 20% infusion (P4) showed no significant difference meaning that the administration of povidone-iodine 10% had better healing values than the other treatment alternatives. Therefore, the P4 group with a concentration of 20% had the highest value among the other treatment groups that were close to the healing value of povidone-iodine 10%.

The fewest number of inflammatory cells were observed in the histopathological observation of P1. The reason povidone-iodine naturally acts as an antiseptic to kill bacteria by inhibiting bacteria enzyme metabolism and preventing their replication. The reduction of infection in the wound area resulted in a normal wound healing process. In the initial stages of the wound healing process, there was an inflammatory and formation phase of reactive oxygen species (ROS) produced by neutrophils and macrophages as part of the immune system to help speed up wound cleaning. Aside from positive effects, ROS also had a negative impact. It is a toxic byproduct of aerobic metabolism required for many important signaling reactions (Mittler, 2017). Redox biology involved a small increase in ROS levels that activated signaling pathways to initiate biological processes while oxidative stress denoted high levels of ROS resulting in the damage to DNA, proteins, or lipids (Schieber and Chandel, 2014).

Flavonoids as powerful antioxidants can eradicate free radicals to protect the body against ROS, enhance the function of endogenous antioxidants, and increase antioxidant enzymes in granulation tissue (Auf Dem Keller et al., 2006). This can be observed in the treatment group that received the infusion of Tekelan (*Chromolaena odorata*), especially in P4. In this group, the number of inflammatory cells and fibroblasts was almost the same as in P1. Unlike the other groups, P0, P2, and P3 obtained a higher number of inflammatory cells and fibroblasts. This was due to the differences in the concentrations of P2 and P3, and finally in the P0 group which received no treatment leading to the slowest speed of the healing process. The tannin and saponin active substances in Tekelan leaves acted as antimicrobials, increased wound contraction, and epithelialization rate (Thakur et al., 2011). This was evident by the closure of all epithelium in each treatment group that was administered with Tekelan leaves infusion (*Chromolaena odorata*). Saponins could also increase TGF- β receptors in fibroblasts to bind TGF- β , which was a growth factor needed by fibroblasts in synthesizing collagen (Agarwal et al., 2009). Collagen was an extracellular matrix that acted as a framework for keratinocyte migration. The formation of a denser extracellular matrix would stimulate the process of epithelialization of keratinocytes (Nayak and Pereira, 2006). This could be observed in the group treated with Tekelan leaves (*Chromolaena odorata*) infusion, where the higher the infusion concentration, fibroblast proliferation occurred more quickly on a high amount, consequently accelerating the synthesis and maturation of collagen.

Tannins played a role in the regulation of transcription and translation of vascular endothelial growth factor (VEGF) (Li et al., 2011). VEGF which acted according to paracrine not only worked on the skin vascular endothelial cells but also on keratinocytes and immune cells that promoted re-epithelialization. Moreover, VEGF stimulated angiogenesis and improved oxygen perfusion (Gogiraju et al., 2019; Olfati and Moradi-kor, 2019). This was evident in the P2 and P3, where a large number of new blood vessels were formed. The number of new blood vessels would continue to decrease in line with the speed of wound healing and granulation tissue maturation based on the amount of Tekelan leaves infusion (*Chromolaena odorata*) which was seen in the group P4.

The present study substantiated that povidone-iodine 10% and Tekelan leaves infusion could increase the healing value of incision wounds in mice infected with *Staphylococcus aureus* based on its concentration. Similarly, the optimal concentration of Tekelan leaves infusion was regarded as 20%. Therefore, in the present study, the concentration of 20% obtained the highest value and it was close to the value and quality of povidone-iodine 10%.

CONCLUSION

The administration of povidone-iodine 10% could lead to a significant difference compared to 5% and 10% Tekelan leaves infusion. The Tekelan leaves infusion with a concentration of 20% led to no significant difference. To be specific, the optimal concentration of Tekelan leaves infusion in the wound incision healing process of mice (*Mus musculus*) infected with *Staphylococcus aureus* was obtained at a concentration of 20%.

DECLARATION

Author's contribution

Arif Caesar BUDI S., Iwan Sahrial HAMID, and Djoko LEGOWO had similar roles in conduction, writing and editing of manuscript.

Competing interest

The author did not report any conflicts of interest in the current research.

REFERENCES

- Agarwal PK, Singh A, Gaurav K, Goel S, Khanna HD, and Goel RK (2009). Evaluation of wound healing activity of extracts of plantain banana (*Musa sapientum* var. *paradisica*) in rats. *Indian Journal of Experimental Biology*, 47(1): 32-40. PMID: 19317349
- Atindehou M, Lagnika L, Guérolod B, Strub JM, Zhao M, and Van Dorsselaer A (2013). Isolation and identification of two antibacterial agents from *Chromolaena odorata* L. active against four diarrheal strains. *Advances in Microbiology*, 3: 115-121. DOI: <http://dx.doi.org/10.4236/aim.2013.31018>
- Auf Dem Keller U, Kümmin A, Braun S, and Werner S (2006). Reactive oxygen species and their detoxification in healing skin wounds. *Journal of Investigative Dermatological Symposium Proceedings*, 11: 106-111. DOI: <https://www.doi.org/10.1038/sj.jidsymp.5650001>
- Chandra S, Podder I, Chatterjee M, and Field L (2018). Anatomy and applications of the #15 scalpel blade and its variations. *Journal of Cutaneous and Aesthetic Surgery*, 11(2): 79-82. DOI: https://www.doi.org/10.4103/JCAS.JCAS_70_16
- DepKes RI (1995). *Farmakope indonesia edisi IV*. Jakarta Dep Kesehatan Republik Indones, Departemen Kesehatan RI, Jakarta, pp. 112-115. Available at: https://bbpombandung.app/bandung.pom.go.id/library/detail_buku_fisik/4
- Gilmore OJ, Reid C, and Strokon A (1977). A study of the effect of povidone-iodine on wound healing. *Postgraduate Medical Journal*, 53(617): 122-125. DOI: <https://www.doi.org/10.1136%2Fpgmj.53.6.122>
- Gogiraju R, Bochenek ML, and Schäfer K (2019). Angiogenic endothelial cell signaling in cardiac hypertrophy and heart Failure. *Frontiers in cardiovascular medicine*, P. 20. DOI: <https://www.doi.org/10.3389/fcvm.2019.00020>
- Greenhalgh DG, Sprugel KH, Murray MJ, and Ross R (1990). PDGF and FGF stimulate wound healing in the genetically diabetic mouse. *The American Journal of Pathology*, 136(6): 1235-1246. PMID: 2356856
- Hamer ML, Robson MC, Krizek TJ, and Southwick WO (1975). Quantitative bacterial analysis of comparative wound irrigations. *Annals of Surgery*, 181(6): 819-822. DOI: <https://www.doi.org/10.1097%2F00000658-197506000-00010>
- Jawetz E, Melnick JL, and Adelberg EA (2013). *Medical Microbiology*. Springer-Verlag, UK, pp. 117-121. Available at: http://microbiology.sbm.ac.ir/uploads/jawetz_2013_medical_micobiology.pdf
- Kusningrum RS (2008). *Perancangan percobaan*. Universitas Airlangga Press. Surabaya, p. 84. Available at: <http://library.um.ac.id/free-contents/index.php/buku/detail/perancangan-percobaan-kusningrum-r-s-33764.html>
- Li K, Diao Y, Zhang H, Wang S, Zhang Z, and Yu B (2011). Tannin extracts from immature fruits of *Terminalia chebula* Fructus Retz. promote cutaneous wound healing in rats. *BMC Complementary and Alternative Medicine*, 11(1): Article number: 86. DOI: <https://www.doi.org/10.1186/1472-6882-11-86>
- Marianne M, Lestari D, Sukandar EY, Kumiati NF, and Nasution R (2014). Antidiabetic Activity of Leaves Ethanol Extract *Chromolaena odorata* (L.) RM King on Induced Male Mice with Alloxan Monohydrate. *Jurnal Natural*, 14: 1-4. Available at: <http://www.jurnal.unsyiah.ac.id/natural/article/view/1382>
- Mittler R (2017). ROS are good. *Trends in Plant Science*, 22(1): 11-19. DOI: <https://www.doi.org/10.1016/j.tplants.2016.08.002>
- Mugwedi L (2020). Harnessing Opportunities Provided by the Invasive *Chromolaena odorata* to Keep It under Control. *Sustainability*, 12: Article number: 6505. DOI: <https://www.doi.org/10.3390/su12166505>
- Nayak BS, and Pereira LMP (2006). *Catharanthus roseus* flower extract has wound-healing activity in Sprague Dawley rats. *BMC Complementary and Alternative Medicine*, 6(1): 41. DOI: <https://www.doi.org/10.1186/1472-6882-6-41>
- Ngozi IM, Jude IC, and Catherine IC (2009). Chemical profile of *Chromolaena odorata* L (King and Robinson) leaves. *Pakistan Journal of Nutrition*, 8: 521-524. DOI: <https://www.doi.org/10.3923/pjn.2009.521.524>
- Olfati A, and Moradi-kor N (2019). The therapeutic effect of statins on survival of patients with gastrointestinal cancer: a Review. *International Journal of Advanced Biological and Biomedical Research*, 7(3): 191-203. Available at: http://www.ijabbr.com/article_34662_6432f4ff2c033909462f4efef7176e79.pdf
- Sammartino G, Tia M, Tete S, Perillo L, and Trosino O (2012). Adverse reaction to irrigation with povidone-iodine after deep-impacted, lower third molar extraction. *Journal of Biological Regulators and Homeostatic Agents*, 26(1): 145-149. PMID: 22475107
- Schieber M, and Chandel NS (2014). ROS function in redox signaling and oxidative stress. *Current Biology*, 24(10): 453-462. DOI: <https://dx.doi.org/10.1016%2Fj.cub.2014.03.034>
- Thakur R, Jain N, Pathak R, and Sandhu SS (2011). Practices in wound healing studies of plants. Evidence-based Complement Alternative Medicine, Article ID: 438056. DOI: <https://www.doi.org/10.1155/2011/438056>
- Umar A, Krihariyani D, and Mutiarawati DT (2012). Pengaruh pemberian ekstrak daun binahong (*Anredera cordifolia*) terhadap kesembuhan luka infeksi *Staphylococcus aureus* pada mencit. *Jurnal Ilmiah Mahasiswa Veteriner*, 2: 68-75. DOI: <https://www.doi.org/10.21157/jim%20vet.v2i1.5655>
- Vital PG, and Rivera WL (2009). Antimicrobial activity and cytotoxicity of *Chromolaena odorata* (L. f.) King and Robinson and *Uncaria perrottetii* (A. Rich) Merr. Extracts. *Journal of Medicinal Plant Research*, 3(7): 511-518. DOI: <https://www.doi.org/10.5897/JMPR.9000160>

Tekelan Leaves (*Chromolaena odorata*) Infusion and 10% Povidone-Iodine on Incision Wound Healing Process of Mice (*Mus musculus*) Infected with *Staphylococcus aureus*

ORIGINALITY REPORT

11%

SIMILARITY INDEX

6%

INTERNET SOURCES

9%

PUBLICATIONS

0%

STUDENT PAPERS

PRIMARY SOURCES

1 knepublishing.com 1%
Internet Source

2 Michael Schieber, Navdeep S. Chandel. "ROS Function in Redox Signaling and Oxidative Stress", *Current Biology*, 2014 1%
Publication

3 "Topical and Transdermal Drug Delivery", Wiley, 2011 1%
Publication

4 Ameta Primasari, Edikin Raja Sinulingga. "Differences of Wound Healing in the Buccal Part and Oral Mucosa Labial After Giving Lemongrass Extracts (*Cymbopogon ciratus*)", *International Journal of Homeopathy & Natural Medicines*, 2019 1%
Publication

5 bmchealthservres.biomedcentral.com 1%
Internet Source

6	Muhammad N. Salim, Moma Silvia, Dwinnna Aliza, Dian Masyitha et al. " Efficacy of Latex Cream in The Epithelialization Phase of Wound Healing in Mice Skin ", E3S Web of Conferences, 2020 Publication	<1 %
7	W O Southwick. "Quantitative bacterial analysis of comparative wound irrigations.", Annals of surgery, 06/1975 Publication	<1 %
8	www.ojs.uma.ac.id Internet Source	<1 %
9	onlinelibrary.wiley.com Internet Source	<1 %
10	docplayer.net Internet Source	<1 %
11	cjns.gums.ac.ir Internet Source	<1 %
12	garuda.ristekbrin.go.id Internet Source	<1 %
13	www.ncbi.nlm.nih.gov Internet Source	<1 %
14	www.strategicmarketingmontreal.ca Internet Source	<1 %
15	mafiadoc.com Internet Source	<1 %

<1 %

16

İclal Yücel, Gülseren Bağcı, Yaşar Duranoğlu, Arzu Öztürk, Güler Aksu, Güven Lüleci. "The Effect of Hydroxyurea on Rabbit Subconjunctival Fibroblast Culture and Use of Hydroxyurea in Rabbits after Glaucoma Filtration Surgery", *Ophthalmologica*, 1999

Publication

<1 %

17

Gonçalo Pombo, Jorge Gomes. "Employees' perceptions and the relationship between human resource management and organizational performance: a conceptual view", *Knowledge and Performance Management*, 2019

Publication

<1 %

18

TAINA ISOTALO, JUHA-PEKKA NUUTINEN, ANU VAAJANEN, PAULA M. MARTIKAINEN et al. "BIOCOMPATIBILITY AND IMPLANTATION PROPERTIES OF 2 DIFFERENTLY BRAIDED, BIODEGRADABLE, SELF-REINFORCED POLYLACTIC ACID URETHRAL STENTS: AN EXPERIMENTAL STUDY IN THE RABBIT", *The Journal of Urology*, 2005

Publication

<1 %

19

Yingping Wu, Tiejun Zhao, Riqiang Deng, Xiaoping Xia, Bin Li, Xunzhang Wang. "A study of differential circRNA and lncRNA

<1 %

expressions in COVID-19-infected peripheral blood", Scientific Reports, 2021

Publication

20

pdfs.semanticscholar.org

Internet Source

<1 %

21

publications.waset.org

Internet Source

<1 %

22

www.hindawi.com

Internet Source

<1 %

23

www.thieme-connect.com

Internet Source

<1 %

24

"Proceedings of the 1st International Conference on Electronics, Biomedical Engineering, and Health Informatics", Springer Science and Business Media LLC, 2021

Publication

<1 %

25

Alexander Patera Nugraha, Ida Bagus Narmada, Diah Savitri Ernawati, Aristika Dinaryanti et al. "Osteogenic potential of gingival stromal progenitor cells cultured in platelet rich fibrin is predicted by core-binding factor subunit- α 1/Sox9 expression ratio (in vitro)", F1000Research, 2018

Publication

<1 %

26

Robert A. DeFilipps, Gary A. Krupnick. "The medicinal plants of Myanmar", PhytoKeys, 2018

<1 %

27

Surgery, 2001.

Publication

<1 %

28

repositori.usu.ac.id

Internet Source

<1 %

29

www.e-sciencecentral.org

Internet Source

<1 %

30

"Proceedings of the Second International Conference on the Future of ASEAN (ICoFA) 2017 – Volume 2", Springer Science and Business Media LLC, 2018

Publication

<1 %

31

Gang Lei, Hong-Yu Zhang, Zhao-Hai Wang, Ling-Xia Wei, Pei Fu, Jian-Bo Song, Dong-Hui Fu, Ying-Jin Huang, Jiang-Lin Liao. " High Nighttime Temperature Induces Antioxidant Molecule Perturbations in Heat-Sensitive and Heat-Tolerant Coisogenic Rice () Strains ", Journal of Agricultural and Food Chemistry, 2018

Publication

<1 %

32

R.N. Asomugha, A.N. Ezejiofor, P.N. Okafor, I.I. Ijeh. "Acute and Cytotoxicity Studies of Aqueous and Ethanolic Leaf Extracts of Chromolaena odorata", Pakistan Journal of Biological Sciences, 2015

Publication

<1 %

Exclude quotes Off

Exclude matches Off

Exclude bibliography On

Tekelan Leaves (*Chromolaena odorata*) Infusion and 10% Povidone-Iodine on Incision Wound Healing Process of Mice (*Mus musculus*) Infected with *Staphylococcus aureus*

GRADEMARK REPORT

FINAL GRADE

/0

GENERAL COMMENTS

Instructor

PAGE 1

PAGE 2

PAGE 3

PAGE 4

PAGE 5

PAGE 6
