

Surface Electromyography Unveil the Relationship between Masticatory Muscle Tone and Malocclusion Class I & II in Javanese Ethnic Patient

I Gusti Aju Wahyu Ardani¹, Dwi Rahmawati^{1*}, Ida Bagus Narmada¹, Alexander Patera Nugraha¹, Sarah Nadia², Haydar Taftazani¹, Martha Kurnia Kusumawardani³

1. Departement of Orthodontic, Faculty of Dental Medicine, Universitas Airlangga, Surabaya, Indonesia.

2. Undergraduate Student, Faculty of Dental Medicine, Universitas Airlangga, Surabaya, Indonesia.

3. Department of Physical Medicine & Rehabilitation, Faculty of Medicine, Universitas Airlangga, Surabaya, Indonesia.

Abstract

Aim to evaluate the difference of masticatory muscle activity of Malocclusion Class I and Class II malocclusion in Javanese ethnic patient detected by surface electromyography (sEMG).

Observational analytic cross-sectional study was done. The sample consisted of 16 patients, 18-21 years-old taken by the total sampling. The classification of malocclusion based on Angle's malocclusion classification then divided into Class I malocclusion ($ANB < 4^\circ$) and Class II Malocclusion group ($ANB > 4^\circ$) based on cephalometric, study models and intra-oral examination ($n=8$). The cephalometry was traced using the Orthovision™ digital program and then the anatomical points are determined. The measurement of muscle activity was recorded by means of sEMG. Determine the installation of black-red electrodes according to the direction of muscle contraction from origo to insertio. Pairing the electrode pad then parallel to the muscle belly with muscle fibers with a distance of 1 cm between the electrodes and ground plug. Select the feedback mode and sensitivity according to muscle strength. The right and left side of masseter, temporalis, suprahyoid muscles activity was examined. Mann-Whitney analysis ($p < 0.05$) was done based on homogeneity and normality data test ($p > 0.05$).

Only the right side of temporal muscle activity was significantly different in Class I and Class II malocclusions in Javanese ethnic patient ($p=0.0001$). Meanwhile, the masseter and suprahyoid muscles right side, have no significant differences were found in Javanese ethnic patient ($p=0.99$). Therefore, there was no significant different in left side of temporalis ($p=0.11$), masseter ($p=0.99$) and suprahyoid ($p=0.104$) muscle activity between malocclusion class I and II in Javanese ethnic patient.

Temporalis, masseter, and suprahyoid muscle activity detected by sEMG have no significant difference in malocclusion Class I and II in Javanese ethnic patients.

Clinical article (J Int Dent Med Res 2020; 13(4): 1447-1454)

Keywords: Dental Medicine, Electromyography, Malocclusion, Masticatory Muscle, Skeletal.

Received date: 13 August 2020

Accept date: 19 September 2020

Introduction

Malocclusion is an abnormal condition of dentocraniofacial growth that affect tooth position in the dental arch that can interfere with the aesthetics, function of chewing, ingestion, speech, and facial esthetic and harmony.¹ The prevalence of malocclusion in Indonesia is quite high ranging from 80%.² Malocclusion can occur due to abnormalities in the teeth (dental), upper

and lower jaw bone (skeletal), a combination of teeth and jaw bone (dentoskeletal) and soft tissue abnormalities (masticatory muscles).³ Malocclusion was common and sometimes difficult to identify the etiology that makes hard to diagnose due to many factors. Those factors can affect the growth of teeth and jaws, including genetic factors, congenital factors and environmental factors, and all three of which are interrelated and involve soft tissue such as neuromuscular system.⁴

Class I malocclusion according to Angle's classification has a molar occlusion relation called neutroclusion shown by the mesiobuccal cusps of the maxillary permanent first molar in the buccal groove of the mandibular

*Corresponding author:

Dwi Rahmawati,
Department of Orthodontics, Faculty of Dental Medicine,
Universitas Airlangga, Surabaya, Indonesia.
E-mail: dwi-rahmawati@fkg.unair.ac.id

permanent first molar. The maxillary permanent canine is in the embrasure between the mandibular permanent canine and the mandibular permanent first premolar. Class I malocclusion is still considered a normal occlusion because in terms of aesthetics and function in normal range. In Class I malocclusion can be accompanied by abnormalities such as teeth crowding, open bite, canine extostem, anterior overbite, or posterior cross bite. The skeletal relation in Class I malocclusion in the sagittal direction is generally Class I. In the vertical and transverse direction, the skeletal pattern in Class I malocclusion is usually normal.⁵

Class II malocclusion according to Angle's Classification is characterized by the presence of a molar relationship with the distobuccal cusp of the maxillary first permanent molar in occlusion in the buccal groove of the mandibular first permanent molar.³ Class II malocclusion can be found with a variety of facial morphological conditions caused by a small mandible or can be normal, but sometimes it can be found in large mandible conditions. Various studies show that in Class II malocclusions various symptoms with dentoalveolar, skeletal or neuromuscular differences can be found.⁶

Muscles are important factor that can affect the occurrence of malocclusion. Muscles have a function for mandibular elevation i.e. masseter muscles, temporal muscles, and medial pterygoid muscles. Muscles that have functions for mandible depression, which is lateral pterygoid muscles.⁷ Some muscles affect the tooth occlusion, i.e. the muscles of the tongue; masseter muscle and buccinator muscle; and orbicularis oris muscle. Normal development in dentofacial structure depends on the normal function of the muscles around the mouth. The imbalance between the orofacial muscles will affect the development of the dentofacial structure.⁸ Masticatory muscle disorder can be seen from the presence or absence of muscle activity. Muscle activity is the electrical activity of muscle that is produced and maintained by the muscle continuously. Muscle activity can be detected using an instrument called a surface electromyography (sEMG).⁹

SEMG is an instrument that is often used to evaluate the function and efficiency of muscles and nerves by recording the potential electrical activity generated by skeletal muscles

by using electrodes that are connected to equipment to amplify signals.^{9,10} SEMG measured electrical potential by placing two electrodes in a muscle or area near the muscle. The electrical potential is generated by membrane depolarization of muscle fibers and represents an electrical analog that can be measured from the contraction of individual motor units. The shape and amplitude of the recorded signal depends on the original depolarization characteristics, the distance of the active fiber from the electrode site, and the impedance characteristics of the intervening tissue.^{10,11}

In the diagnosis of malocclusion, it is important to consider the etiology of malocclusion, one of which is abnormalities in masticatory muscle activity. The masticatory muscle activity can be affected by hereditary such as ethnicity. The malocclusion class I and class II may alter the masticatory muscle activity or back and forth. This needs to be evaluated and corrected due to it often leads to incorrect diagnoses and errors in determining treatment plans. Until now, there is no study about the evaluation of masticatory muscle activity in malocclusion Class I and Class II malocclusion in Javanese ethnic patient. Therefore, the aim of this study is to evaluate the difference of masticatory muscle activity in Malocclusion Class I and Class II malocclusion in Javanese ethnic patient detected by surface electromyography (sEMG).

Materials and methods

Study and Design:

This study was observational analytic cross-sectional study. The study protocol was approved by ethical clearance for human subject study of Faculty of Dental Medicine, Airlangga University, Surabaya Indonesia with appointment number 773/ HRECC. FODM / XII/ 2019 and Ethical Clearance Committee of Dr. Soetomo General Academic Hospital, Surabaya, East Java, Indonesia with number: 1767/KEPK/I/2020.

Sampling Criterias:

The population in this study was 16 Javanese ethnic patients (8 males and 8 females) between 18-21 years-old (19.7 ± 1.1) undergoing the orthodontic treatment at the Orthodontic Clinic of Airlangga University Dental Hospital, Surabaya taken by the total sampling

method. The subject was approved to join the study after read the study protocol and confirmed by filled the written informed consent form. Thus, the confidentiality of the patient's identity remains protected. The inclusion criteria are Class I and II malocclusion based on Angle's malocclusion classification; female or male ethnic Javanese patient who had never done any orthodontics treatment before full permanent dentitions. The exclusion criteria are Class III malocclusion based on Angle's malocclusion classification, patient with oral bad habits such as tongue thrust swallowing, mouth breathing, lip biting, thumb sucking; supernumerary teeth, Cleft Lip and Palate.

The classification of malocclusion based on Angle's malocclusion classification then divided into Class I malocclusion group ($ANB < 4^\circ$) and Class II Malocclusion group ($ANB > 4^\circ$) based on cephalometric, study models and intra-oral examination ($n=8$). The cephalometry was traced using the Orthovision™ digital program and then the anatomical points are determined. Cephalometry analysis for skeletal malocclusion diagnosis Class I ($ANB < 4^\circ$). (see Figure 1A) and Class II ($ANB > 4^\circ$) (see **Figure 1B**).

Masticatory Muscle Activity Measurement

The measurements of muscle activity taken by Surface Electromyography Device (sEMG) (Enraf-Nonius Myomed 632X, Lisburn, Co. Antrim, Northern Ireland). The examiners were calibrated to operate the sEMG device. Preparation of muscle activity measurement, we disinfect the area to be installed with alcohol swab then dry it by tissue wipe. The operator of sEMG determine the installation of black-red electrodes according to the direction of muscle contraction from origo to insertio. The black electrode is a cathode (-) placed on the muscle insertion. The red electrode is an anode (+) placed on the muscle origo. Pairing the electrode pad is then parallel to the muscle belly with muscle fibers with a distance of 1 cm between the electrodes and ground plug. Select the feedback mode and sensitivity according to muscle strength and estimate that maximum contraction is still recorded). The patient was instructed to take physiologic rest position by sitting in a chair and relaxed state. Arms are placed on the thighs and feet are placed on the floor. The patient's head is upright and the Frankfurt line is parallel to the floor.

For masticatory muscle activity examination by sEMG, patients were instructed to take maximal voluntary contraction. The temporal muscle examination, subjects were instructed to perform maximal clenching for 5 seconds and continued resting for 5 seconds. This cycle was repeated as many as 5 times with 50 seconds per-cycle (Figure 2A). The patient was instructed to perform maximal clenching for 5 seconds and continued resting for 5 seconds for masseter muscle examination. The cycle is carried out as many as 5 times a cycle that is for 50 seconds (Figure 2B). Finally, in the suprahyoid muscle examination, subjects were instructed to open their mouths for a maximum of 5 seconds and continue the resting position for 5 seconds. The cycle is carried out as many as 5 times a cycle that is for 50 seconds. Make sure that the subject feels comfortable and relaxed without feeling tense or afraid (Figure 2C).

Statistical analysis

All data obtained were examined by averages of Statistical Package for Social Science (SPSS) 20.0 version (IBM Corporation, Illinois, Chicago, US). Mann-Whitney analysis ($p < 0.05$) was done to examine the significant difference between groups.

Results

The clinical results of average temporal muscle activity in the Class II malocclusion group showed high results compared with the Class I malocclusion group. Mann-Whitney test results found that only the temporalis muscle strength in the right side between Class I and Class II malocclusion had a significant difference ($p < 0.05$). Meanwhile, the other muscle sEMG test found no significant difference ($p > 0.05$) (Table 1).

Discussion

In this study, we found that there was only the temporalis muscle strength in the right side between Class I and Class II malocclusion have significant difference. Meanwhile, the other muscle sEMG test found no significant difference. The normal development of dentofacial depends on the normal function of the muscles in the orofacial region. The imbalance between the orofacial muscles will affect the development of the dentofacial structure.⁸

Masseter and temporal muscles are important masticatory muscles they have important role in the mandibular elevation, proclination and retraction functions. Clenching movements can be influenced by teeth that are not located in the correct arch that affect muscle activity.¹²

The clinical results of average temporal muscle activity in the Class II malocclusion group showed high results compared with the Class I malocclusion group. Our study result is accordance with Petrović and team stated that there was a relationship between Class II dental malocclusion and masticatory muscle activity seen from the presence of excessive temporal muscle activity when compared to Class I dental malocclusion which has normal occlusion.¹³ The masticatory muscle activity in Class II dental malocclusion showed excessive masseter muscle activity when compared with Class I dental malocclusion which had normal occlusion.¹³ According to a study by Ko and team that evaluate the EMG activity of the anterior masseter and temporal muscles during maximal clenching in Class II division 1 malocclusion patients. Their statistical result analysis did not show the significant differences between groups.¹⁴ There was no significant difference between group that might happen due to the lack of study subject that affect standard deviation becomes higher and the placement of surface electrodes carried out by different operators can affect the location that is incompatible with the origo and insersio of each muscle. In the Class II malocclusion subjects, an average ANB angle of 5.9° was obtained, while ANB angles greater than 6° showed a greater severity of malocclusion so they could show significant results when compared to Class I malocclusions which had a normal ANB angle (ANB<4°) (see figure 1). In the Class II, mandibular retraction has previously been shown to be a major determinant of ANB differences. Skeletal and dental characteristics in Malocclusion Class II, maxillary interpremolar width and SNB was positively correlated, while SNB was negatively correlated in Javanese ethnic malocclusion patient.¹⁵ The mandible may be the main determinant because it is the least mature structure in the craniofacial complex and is influenced by the greatest environmental and genetic factors.¹⁶

Genetic factor may have influence to malocclusion class II occurrence. LEPR gene on

on chromosomal locus 1p31 may affect the retrognathic mandible incidence. According to previous study mentioned that the genotyped AA and dominant allele A of LEPR Q223R polymorphism can be considered to carry a risk of Class II malocclusion.¹⁷

In this study reveal the average suprahyoid muscle activity in the Class II malocclusion group was lower compared to the Class I malocclusion group. In general, the function of the suprahyoid muscle to support the hyoid bone elevation and open the mouth to extremes such as yawning or biting an apple.¹⁴ This can be attributed to the results of study that suprahyoid muscle activity is a small influence with the function and use that is less so that it can inhibit the growth of the mandible. At the time of mouth opening activity, the posterior fibers of the temporal and masseter muscles are in a state of relaxation.^{18,19} In this study, temporal, and masseter muscle activity in Class II malocclusion was higher than Class I. Furthermore, the relationship between suprahyoid muscle activity and malocclusion can be found which is lower when compared based on muscle function in moving the mandible.²⁰

The limitation of this study is only examined the masticatory muscle activity in malocclusions class I and II with small sample size (N=16) in Javanese ethnicity. In the future, it would be better to distinguish the difference of masticatory muscle activity between gender in malocclusion class I, II and III with related involving others etiology factors in wider sample size and various ethnicity with better study design.

Conclusion

In sum, temporalis, masseter, and suprahyoid muscle activity examined by sEMG have no significant difference in malocclusion Class I and II in Javanese ethnic patients but it was the masseter muscle activity that played large role in class II malocclusion. Evaluation of masticatory muscle activity related to malocclusion may help orthodontist to determine the treatment plan for better treatment outcome. Further study is necessary to distinguish the difference of masticatory muscle activity between gender in malocclusion class I, II and III with related involving others etiology factors with better study setting.

Future Scope

We examined only Javanese population in general, different ethnicity sample should be examined and compared with bigger sample size. Therefore, the examination in this study were limited. In the future, it would be better to distinguish the difference of masticatory muscle activity between gender in malocclusion class I, II and III.

Patient declaration of consent

Informed written consent for participation were taken in the study and publication of the data for research and educational purposes.

Acknowledgement: The author would like to thanks the Orthodontics Clinic, Dental Hospital, Faculty of Dental Medicine, Universitas Airlangga and Physical medicine and medical rehabilitation Clinic, Dr. Soetomo General Hospital, Surabaya, East Java, Indonesia for supporting our study.

Ethical policy and Institutional Review board statement

The study protocol was approved by ethical clearance for human subject study of

Faculty of Dental Medicine, Airlangga University, Surabaya Indonesia with appointment number 773/ HRECC. FODM / XII/ 2019 and Ethical Clearance Committee of Dr. Soetomo General Academic Hospital, Surabaya, East Java, Indonesia with number: 1767/KEPK/I/2020. All the procedures have been performed as per the ethical guidelines laid down by Declaration of Helsinki (1964)

Abbreviations

SPSS: Statistical Package for Social Science.

Acknowledgements

This study was supported by *Penelitian Dosen Pemula (PDP)* Annual Work Plan Budget Funding 2019, Faculty of Dental Medicine, Universitas Airlangga, Surabaya, Indonesia (1408//UN3/2019)

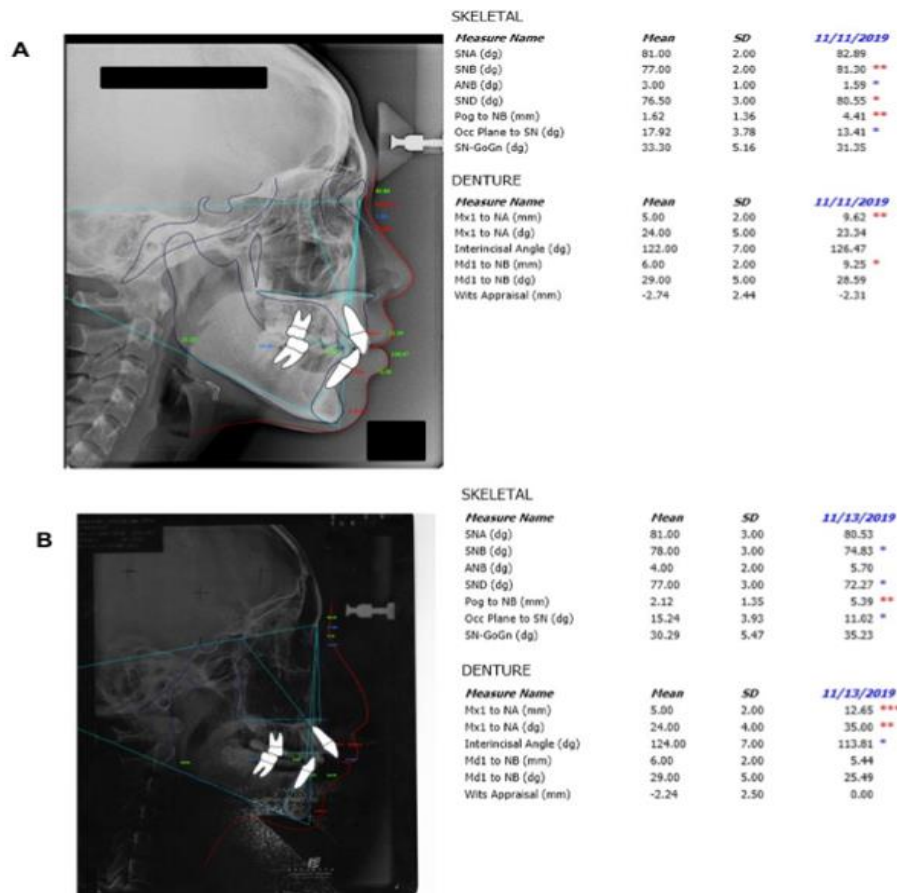


Figure 1. Cephalometry analysis for skeletal malocclusion diagnosis Class I (ANB <4°) (A) and Class II (ANB >4°) (B). Information: SNA: The angle between the cranii base (SN) and the NA line; SNB: The angle between the cranii base (SN) and the NB line; ANB: The angle between the SNA and SNB lines.

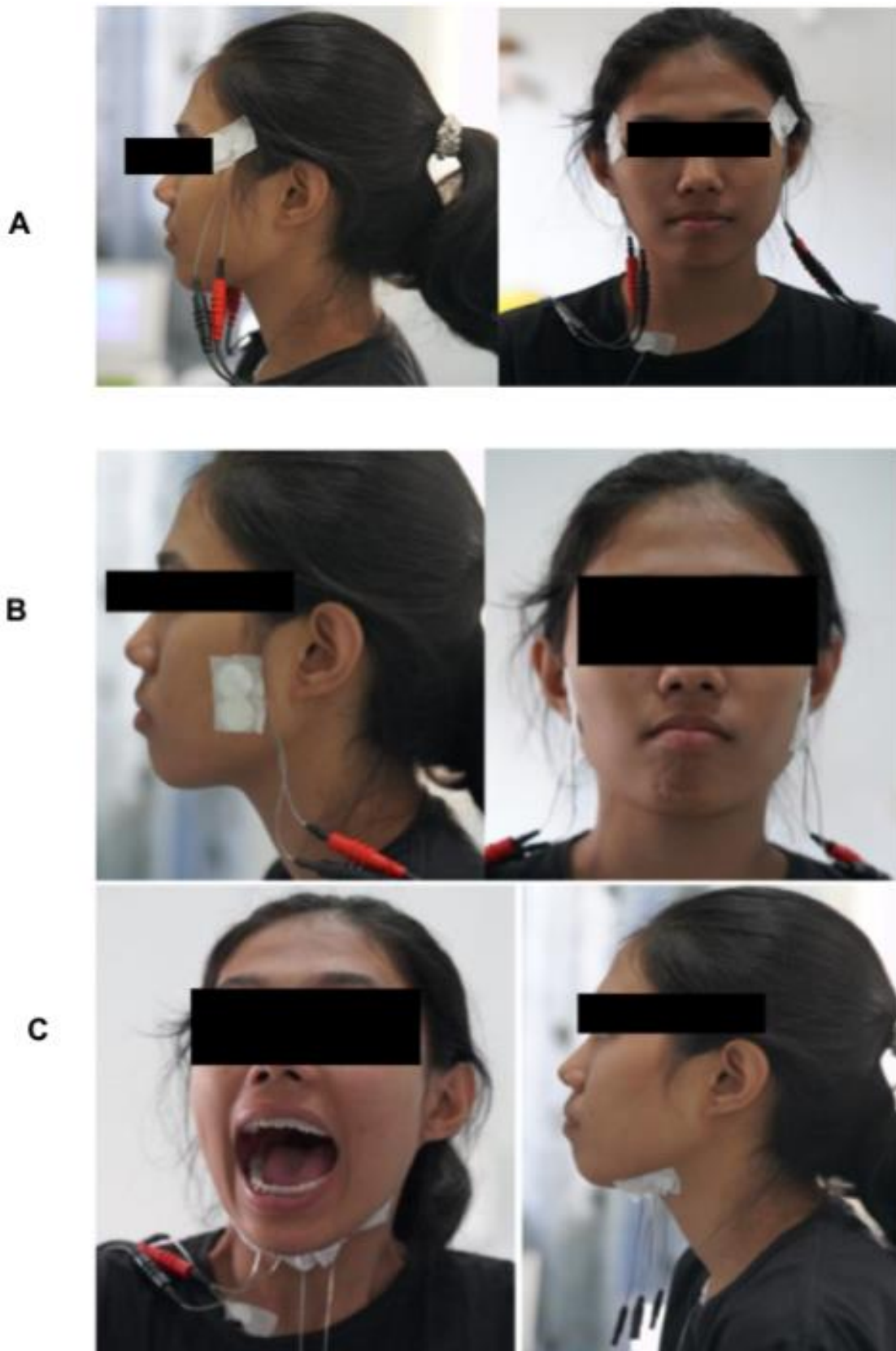

Figure 2. (A) Electrode and subject position during temporal muscles examination; (B) Electrode and subject position during masseter muscles examination; (C) Electrode and subject position during suprahyoid muscles examination.

Masticatory Muscle (side)	Sample	Type of mal-occlusion	Average \pm Std. Deviation	p-value
Temporal right	8	Class I	25.8950 \pm 16.61824	0.0001*
	8	Class II	91.7250 \pm 16.84236	
Masseter right	8	Class I	54.3550 \pm 20.16988	0.9999
	8	Class II	80.0500 \pm 43.25014	
Suprahyoid right	8	Class I	64.1700 \pm 15.57370	0.9999
	8	Class II	41.0000 \pm 18.73713	
Temporal left	8	Class I	30.4300 \pm 11.50978	0.1109
	8	Class II	72.0000 \pm 22.73437	
Masseter left	8	Class I	47.3250 \pm 27.98207	0.999
	8	Class II	61.4350 \pm 39.17246	
Suprahyoid left	8	Class I	72.4775 \pm 9.53958	0.1043
	8	Class II	63.3071 \pm 8.42847	

Tabel 1. The Mann-Whitney test result in the masticatory muscle activity in right and left side of malocclusion class I and class II in Javanese ethnic patients. Note:*Significant difference at $p < 0.05$.

Declaration of Interest

The authors report no conflict of interest in this work.

References

- Ardani IGAW, Sanjaya ML, Sjamsudin J. Cephalometric Characteristic of Skeletal Class II Malocclusion in Javanese Population at Universitas Airlangga Dental Hospital. *Contemp Clin Dent.* 2018;9(Suppl 2):S342–S346. doi:10.4103/ccd.ccd_465_18
- Nugraha AP, Rezkita F, Putra KG, Narmada IB, Ernawati DS, Rantam FA. Triad Tissue Engineering: Gingival Mesenchymal Stem Cells, Platelet Rich Fibrin and Hydroxyapatite Scaffold to ameliorate Relapse Post Orthodontic Treatment. *Biochem. Cell. Arch.* 2019; 19(2):3689–3693.
- Ardani IGAW, Willyanti I, Narmada IB. Correlation between vertical components and skeletal Class II malocclusion in ethnic Javanese. *Clin Cosmet Investig Dent.* 2018;10:297–302.
- Ardani I G, Kannayyah D, Triwardhani A. Correlation of maxillary and mandibular arch form and tooth size ratio in ethnic Javanese malocclusion patient. *J Int Oral Health* 2019;11:75-9
- Alhammadi MS, Halboub E, Fayed MS, Labib A, El-Saaidi C. Global distribution of malocclusion traits: A systematic review [published correction appears in *Dental Press J Orthod.* 2019 Aug 01;24(3):113]. *Dental Press J Orthod.* 2018;23(6):40.e1–40.e10.
- Plaza SP, Reimpell A, Silva J, Montoya D. Relationship between skeletal Class II and Class III malocclusions with vertical skeletal pattern. *Dental Press J Orthod.* 2019 July-Aug;24(4):63-72.
- Iyer M, and Valiathan A. Electromyography and its application in orthodontics. *Current Science-Bangalore.* 2001; 80(4):503-506.
- Marquezin MC, Gavião MB, Alonso MB, Ramirez-Sotelo LR, Haiter-Neto F, Castelo PM. Relationship between orofacial function, dentofacial morphology, and bite force in young subjects. *Oral Dis.* 2014 Sep;20(6):567-73.
- Woźniak K, Piątkowska D, Lipski M, Mehr K. Surface electromyography in orthodontics – a literature review. *Med Sci Monit* 2013; 19:416-423.
- Shala KS, Dula LJ, Bimbashi V. Electromyography Activity of the Chewing Muscles During Adaptation among Complete Denture Wearers. *J Int Dent Med Res* 2020; 13(2): 651-658.
- Tomonari H, Seong C, Kwon S, Miyawaki S. Electromyographic activity of superficial masseter and anterior temporal muscles during unilateral mastication of artificial test foods with different textures in healthy subjects. *Clin Oral Investig.* 2019 Sep;23(9):3445-3455.

12. Nishi SE, Basri R, Rahman NA, Husein A, Alam MK. Association between muscle activity and overjet in class II malocclusion with surface electromyography. *J Orthod Sci* 2018; 7(1): 3.
13. Petrović D, Vujkov S, Petronijević B, Šarčev I, Stojanac I. Examination of the bioelectrical activity of the masticatory muscles during Angle's Class II division 2 therapy with an activator. *Vojnosanit Pregl* 2014; 71(12):1116–1122.
14. Ko EW, Teng TT, Huang CS, Chen Y. The effect of early physiotherapy on the recovery of mandibular function after orthognathic surgery for class III correction. Part II: Electromyographic activity of masticatory muscles. *Journal of Cranio-Maxillofacial Surgery* 2015; 43(1):138–143.
15. Ardani IGAW, Anandamaya D, Alida. The Relationship Between Skeletal and Dental Characteristics in Patients with Class II Malocclusion. *Journal of International Dental and Medical Research* 2019; 12 (4):1421-1425.
16. Jacob HB, Buschang PH. Mandibular growth comparisons of Class I and Class II division 1 skeletofacial patterns. *Angle Orthod.* 2014 Sep;84(5):755-61.
17. Jazaldi F, Handayani ED, Damayanti YNU, Sarwono AT, Soegiharto BM, Soedarsono N, Auerkari EI. The LEPR Q223R Polymorphisms a Potential Bioindicator of Class II Malocclusion. *Journal of International Dental and Medical Research* 2016; 9 (Special Issue, U.I. 1st International Workshop on Dental Research): 351-355
18. Khan YS, Bordonni B. Anatomy, Head and Neck, Suprahyoid Muscle. [Updated 2019 Sep 7]. In: StatPearls [Internet]. Treasure Island (FL): StatPearls Publishing; 2020 Jan-. Available from: <https://www.ncbi.nlm.nih.gov/books/NBK546710/>
19. Rathee M, Jain P. Anatomy, Head and Neck, Stylohyoid Muscle. [Updated 2019 Oct 2]. In: StatPearls [Internet]. Treasure Island (FL): StatPearls Publishing; 2020 Jan-. Available from: <https://www.ncbi.nlm.nih.gov/books/NBK547653/>
20. Biondi K, Lorusso P, Fastuca R, Mangano A, Zecca PA, Bosco M, Caprioglio A, Levrini L. Evaluation of masseter muscle in different vertical skeletal patterns in growing patients. *Eur J Paediatr Dent.* 2016 Mar;17(1):47-52.