

Long term follow-up of multidrug resistant tb in pubertal child

by Andri Kurnia Wahyudhi

Submission date: 16-Mar-2021 08:28PM (UTC-0700)

Submission ID: 1535077612

File name: g_term_follow-up_of_multidrug_resistant_tb_in_pubertal_child.pdf (1,001.5K)

Word count: 3654

Character count: 20702

Long term follow-up of multidrug resistant tuberculosis in a pubertal child

Andri Kurnia Wahyudhi, Retno Asih Setyoningrum, Ahmad Suryawan

6
Increasing awareness of the rising global rates of multidrug-resistant tuberculosis (MDR-TB) has led to a concerted international effort to confront this disease. Nonetheless, despite cure rates >80% in some programs, MDR-TB patients tend to have chronic disease and require prolonged therapy.¹⁻³ Little is known about the long-term results and follow-up of patients with MDR-TB, include the recurrence rate and chronic disability in patients who have recovered from TB.⁴

There are many side effects and adverse reactions to drugs can occur during MDR-TB treatment. These could be physical and or psychological, as well as reversible or irreversible. Treatment of MDR-TB requires a combination regimen, consists of second and third-line anti-tuberculosis drugs which more toxic than the first-line drugs. Additionally, MDR-TB treatment requires a long duration of treatment (18-24 months) and causes discomfort in the patient.⁵ In a cohort of 60 patients treated for MDR-TB, the most common side effects included gastritis (100%), dermatological disorders (43%), and peripheral neuropathy (16.7%).⁶ While in a cohort of 75 patients, the incidence of depression, anxiety, and psychosis for MDR-TB treatments was 13.3%, 12.0%, and 12.0%, respectively.⁷

Aggressive and effective management are needed so the patient can tolerate the treatment and remain adhere to the treatment.⁸ Long-term follow-up is required for the rehabilitation of disorders due to psychosocial sequelae. As such, psychosocial support can be benefit pediatric MDR-TB patients.

Here, we present a case report on a two-year follow-up of a pubertal child with MDR-TB, focusing on medical aspects and her development. [Paediatr Indones. 2018;58:198-204; doi: <http://dx.doi.org/10.14238/pi58.4.2018.198-204>].

Keywords: MDR-TB; pubertal children; long-term follow-up

The Case

A 13-year-old girl came to Dr. Soetomo Hospital emergency room complaining of shortness of breath, which worsened in two days prior to hospital admission. Other complaints were cough, sub-febrile, sweating, decrease in appetite since two years before admission, and no weight gain since three years before admission. Sixteen months before admission, she has been treated as pulmonary tuberculosis in Jombang

1
From the Department of Child Health, Universitas Airlangga Medical School/Dr. Soetomo Hospital, Surabaya, East Java, Indonesia.

Corresponding author: Andri Kurnia Wahyudhi. Department of Child Health, Airlangga University Medical School/Dr. Soetomo Hospital. Jl. Mayjen. Prof. Dr. Moestopo No 6-8, Surabaya, East Java, Indonesia. Tel. +62-31-5501695, fax. +62-31-5501748. Email: andrikumiaw@gmail.com.

District Hospital. She received four anti-tuberculous drugs (rifampicin 300 mg, isoniazid/INH 200 mg, and pyrazinamide 600 mg). After completed the course of treatment, the patient stopped taking the medications, despite her condition was worsened. The history of TB contact was her father. He has been diagnosed as pulmonary tuberculosis ten months before the patient getting sick. He already completed his tuberculosis treatment. Our patient had been received BCG immunization.

Physical examination on admission revealed bodyweight was 20 kg ($P < 5$, CDC NCHS, 2000),⁹ height 136.5 cm (P25-50, CDC NCHS, 2000),⁹ percent ideal body weight (IBW) 62%,⁹ head circumference 51 cm (< 0 SD, Nellhaus, 1968).¹⁰ Nasal flare, sternocleidomastoid muscles contraction, enlarged lymph nodes of the neck, lag of left chest movement, and intercostal retractions were found. Percussion of the chest wall revealed resonant sound on right chest and dim sound on left chest. There were decreased vesicular breath sounds on the left chest, and coarse crackles in both the right and left chest.

Laboratory results on admission were leukocytes 9,300/uL, hemoglobin 11.7 g/dL, blood gas analysis revealed pH 7.37, PaCO₂ 30.1mmHg, PaO₂ 164.4, HCO₃ 28.4 mmol/L, TCO₂ 29.3 mmol/L, BE 6.2

mmol/L, and SO₂ 95.7%. Chest X-ray showed fibroinfiltrate on right lung field, left lung damage, and tracheal deviation to left side. Subsequent examination in the ward revealed positive sputum acid-fast stain, multi-slice computed tomography (MSCT) scan of the chest revealed fibroinfiltrate on right lung, multiple bullae on left lung, pleural thickening on upper right and whole left lung. GeneXpert examination revealed positive for *Mycobacterium tuberculosis* (MTB) resistant to rifampicin.

Patient was treated as MDR-TB. The first 6-month regimen included kanamycin, ethionamide, cycloserine, levofloxacin, pyrazinamide, and ethambutol, and followed by 18 months treatment with ethionamide, cycloserine, levofloxacin, pyrazinamide, and ethambutol. She experienced adverse effects of anti-tuberculous drugs include vomiting, dizziness, numbness, glare at eyes, sleep disorders, emotional disorders, and hyperuricemia. Vomiting and dizziness resolved spontaneously after the end of treatment. Numbness subsided after patient received pyridoxine. Glare testing has been consulted to Ophthalmology Department that revealed no abnormalities was found and glare at eyes were disappeared after the treatment had been completed.

As a result of pulmonary TB, patient experienced

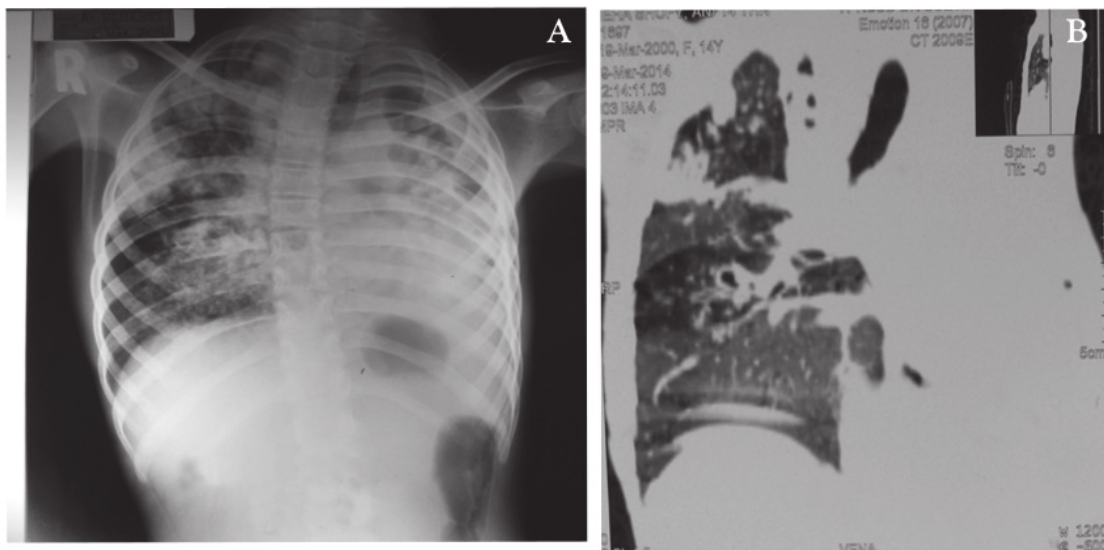


Figure 1. A. Patient chest X-rays on Emergency Department of Dr. Soetomo Hospital revealed the presence of infiltrate on right lung, tracheal deviation to the left, and left lung damage. B. MSCT scan also showed left lung damage.

severe pulmonary parenchymal damage in her left lung. Patient was easily fatigued while walking. The results of the pulmonary function tests included forced expiratory volume-1/forced vital capacity (FEV1/FVC) 98.9% predictive value and FVC 51.1%, indicate presence of restrictive lung abnormalities. The lung damage also had caused pulmonary hypertension. Echocardiography revealed pressure gradient (PG) value between the right atrium and

pulmonary artery was 52 mmHg, therefore, the patient was given sildenafil citrate. Damage to the lungs had led scoliosis, hence, patient underwent rehabilitation, using a Milwaukee Brace for scoliosis correction, as well as training, in the form of exercises for scoliosis, breathing, and endurance.

Monthly evaluation of sputum acid-fast smear staining was negative and sputum culture revealed no MTB growth on the 1st to 24th month of evaluation.

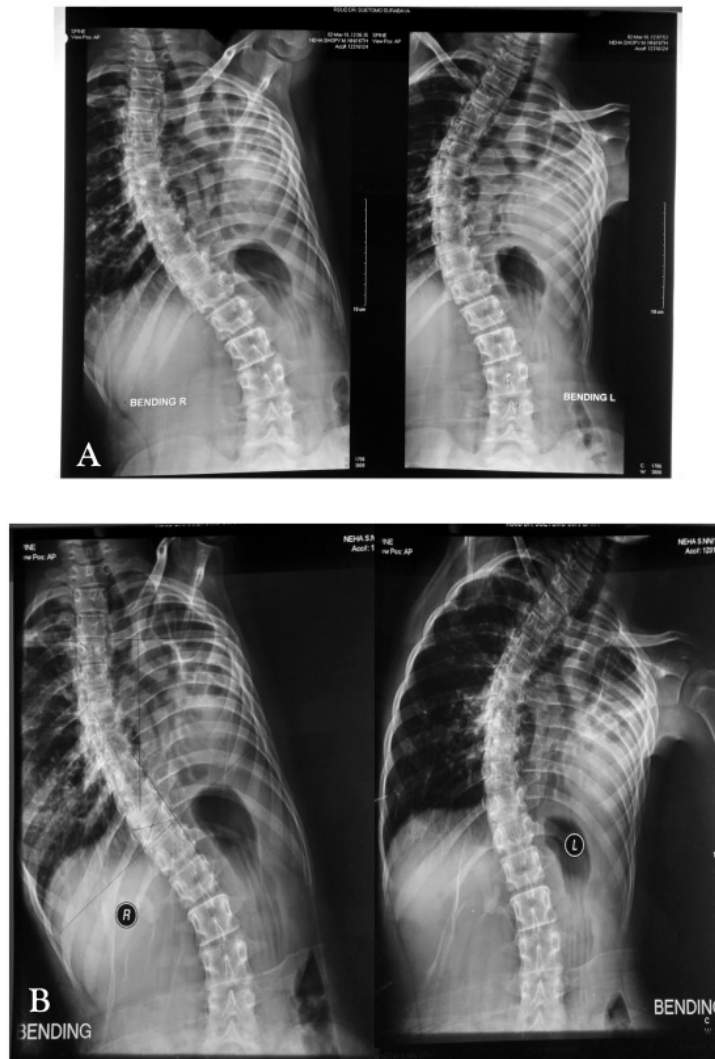


Figure 2. A. Radiological examination of scoliosis when the patient first visited the Psychiatric and Rehabilitation Department revealed double curve scoliosis and Cob angle was 53°. B. Six-month evaluation after the patient underwent full-time bracing (Milwaukee brace) and scoliosis exercises revealed single curve scoliosis and Cob angle was 50°.

Laboratory results for monitoring the adverse and side effects of drugs revealed normal results of complete blood count, normal serum electrolyte, normal kidney function, and normal liver function. However there was increasing in uric acid and improved by allopurinol therapy.

Had been completed the treatment for two years, her bodyweight was 30 kg ($P < 5$, CDC NCHS, 2000),⁹ height 143 cm ($P < 5$, CDC NCHS, 2000),⁹ and nutritional status poor nutrition (% IBW 54%)⁹ and stunted. Mid-parental height (MPH) of the patient ranged from 142.5 to 159.5 cm. Patient have reached Tanner stage A2M2P2 and menarche after MDR-TB treatment was completed at the age of 15 years.

During the course of treatment, she experienced emotional and behavioral disorders. Her family reported she was sensitive and grumpy. She had been screened for behavioral disorders using *Pediatric Symptom Checklist 17 (PSC-17)*.¹¹ Her initial PSC-17 evaluation revealed internalization 8, externalization 12, attention 8, and total score 28. These mean that she had behavioral disorders. After completing the MDR-TB treatment, PSC-17 scores was improved. Internalization score was 5, externalization score was 6, attention score was 4, and total score was 15. She was referred to the Psychiatry Department for further management.

Our patient had a lower quality of life at the beginning treatment of MDR-TB. Assessment HRQoL of the patient using patient-centered PedsQL showed the lowest score in physical health and emotional function. Assessment HRQoL using parent-centered PedsQL revealed the lowest scores in physical-health and school function. The assessment results of HRQoL using PedsQL, both patient and parents-centered, at six months after completing treatment revealed that the lowest score among the three functions was in physical-health function.

Discussion

The patient has been treated for pulmonary tuberculosis using appropriate regimens and durations, but she showed no improvement. In general, the possible reasons for treatment failure were non-adherence, drug resistance, drug malabsorption, laboratory errors, and patient's biological variation (polymorphism) of drugs

metabolism, mutation and strain of MTB.¹²⁻¹⁴ In our patient, drug resistance, patient's biological variation (polymorphism) of drugs metabolism, mutation and strain of MTB were couldn't be evaluated. There are two types of drug-resistant TB, primary and secondary. Primary drug-resistant TB means that the patient was infected with resistant MTB, while secondary drug-resistant TB means that the patient acquired drug resistance during TB treatment, due to spontaneous mutation in the genetic material of the mycobacteria.¹⁵ Our patient likely had secondary drug-resistant TB, as several factors could led to spontaneous mutations. The first was social factor, including medication discontinuation and non-adherence. Patient refused to be referred after completing six months of treatment, despite experienced no clinical improvement. The second factor was the presence of fibro-cavitary lesion, which may have prevented MTB from exposure to optimum levels of the drugs.¹⁶ The third factor was malnourished nutritional status, which cause poor drug absorption in gut. In addition, low serum albumin levels cause increased levels of free drugs in circulation, resulting in increasing renal clearance of drugs. Both mechanisms result in low serum drug levels and potentially subsequent drug resistance.¹⁷

GeneX-pert examination revealed positive. Sputum culture revealed MTB growth resistant to rifampicin and INH. Patient received MDR-TB drug treatment for children in accordance with management of adult patients.^{18,19} During the treatment, many patients experience side effects and adverse drugs reaction. Second and third-line anti-tuberculous drugs often associated with side effects and adverse drug reactions, causing discontinuation and even a change in treatment regimen. Study reported that of 39 patients with MDR TB, 41% experience some side effects and 21.1% required discontinuation or change in medication.²⁰ Close monitoring is necessary to identify side effects early. The most common side effects are rash, gastrointestinal symptoms (nausea, vomiting, and diarrhea), psychiatric symptoms (psychosis, anxiety, depression, and suicidal thoughts), jaundice, ototoxicity, and peripheral neuropathy.^{8,20,21}

Sequelae of TB on the lungs cause a decrease in lung capacity. Spirometry test in our patient revealed FEV1 predictive value of 51.1%, indicate the presence of restrictive abnormality. However, FEV1/FVC was 98.9% predictive value, means that there was no obstructive

abnormality. Mild physical activity was not impaired in this patient, but moderate was. Respiratory symptoms is generally not seen in patients with chronic lung disease until FEV1 reach 50% of predictive value.²² Tuberculous destroyed lung (TDL) respiratory disorder caused by anatomical abnormalities, such as damage to the bronchi due to extensive fibrosis and stricture of endobronchial tissue that obstruct the airway.²³ Asymptomatic patients may not require therapy, but patients with severe disease require multiple modalities, include hospitalization for respiratory disorders.²⁴ Tuberculous destroyed lung with severe clinical symptoms such as massive hemoptysis, empyema, secondary fungal infection, secondary amyloidosis, septicemia, and pulmonary-systemic shunt often need surgery to improve clinical symptoms and quality of life.²⁵

Long term, this lung damage can lead to heart failure due to high pressure in the pulmonary vasculature. Echocardiography examination of patient showed an increase in pulmonary blood vessels. Echocardiography revealed pressure gradient ≥ 40 mmHg in pulmonary artery and considered to be pulmonary hypertension.^{26,27} However, the gold standard diagnostic modality of pulmonary hypertension is right heart catheterization (RHC). But a study comparing RHC and echocardiography reported that echocardiography is a reliable and valid diagnostic method for pulmonary hypertension.²⁸ Administration of sildenafil citrate for pulmonary hypertension in pulmonary fibrosis causes selective pulmonary vasodilation of blood vessels in the area of ventilation without interrupting gas exchange in pulmonary vasculature.^{28,29}

Patient underwent physiotherapy and bracing for her scoliosis. Evaluation of six months revealed improvement in endurance, six-minute walking test increased from 1.5 to 24 minutes. She also had a clinical improvement in the scoliosis, as indicated by Cobb angle, from 53° to 50°. The basic objectives of comprehensive conservative treatment of idiopathic scoliosis are: 1) to stop curve progression at puberty (or possibly even reduce it); 2) to prevent or treat respiratory dysfunction; 3) to prevent or treat spinal pain syndromes; and 4) to improve aesthetics via postural correction.³⁰ Patient's bone maturation was stage 3 Risser classification, adolescent, and Cobb angle was over 50° why full-time bracing was appropriate for the management of scoliosis of the patient. Surgery is

another choice if the bracing result was not sa.^{31,32}

During the observation, patient experienced symptoms of mental and emotional disorder. Her initial PSC-17 evaluation revealed internalization score 8, externalization score 12, attention score 8, and total score 28 and improved to internalization score was 5, externalization score was 6, attention score was 4, and total score 15. Internalizing disorders persisted until the treatment was completed, manifest as depression and mood disorder. Depression is a mental disorder that occur in TB patients, with a prevalence of 40% to 80%.³³ There is a direct relationship between physical injury and mental health deterioration. Increasing in production of interleukin-6 mediates endocrine cascade reactions that causes depression.^{34,35} Gender also has an effect on the occurrence of mental health deterioration, some studies reported mental health deterioration in TB is more common in female.³⁵ Biological processes, self-image, and coping mechanism in women more often lead to depression than men.³⁶

The overall score of HRQoL using PedsQL was low during observation, but it increased greatly over time compared to the beginning of the observation. Chronic disease symptoms and damage due to MDR-TB, as well as the duration of therapy using drugs with toxic properties can cause many residual disorders after treatment completion.³⁷

In conclusion, MDR-TB causes illnesses, physical activity limitation, physical disability, nutritional disorder, and mental health disorder. Long-term follow up with multidisciplinary approach can be expected to improve the quality of life patients with chronic disease. Monitoring medical problem and quality of life of patient should be continued to meet better outcome. Psychosocial support is necessary so they can be accepted and be involved in their environment.

16 Conflict of Interest

None declared.

References

1. Mitnick C, Bayona J, Palacios E, Shin S, Furin J, Alcantara F, et al. Community-based therapy for multidrug-resistant

- tuberculosis in Lima, Peru. *N Engl J Med.* 2003;348:119-28.
2. Tahaoglu K, Torun T, Sevim T, Atac G, Kir A, Karasulu L, et al. The treatment of multidrug-resistant tuberculosis in Turkey. *N Engl J Med.* 2001;345:170-4.
 3. Leimane V, Riekstina V, Holtz T, Zarovska E, Skripconoka V, Thorpe L, et al. Clinical outcome of individualized treatment of multidrug-resistant tuberculosis in Latvia: a retrospective cohort study. *Lancet.* 2005;365:318-26.
 4. Ando M, Mori A, Esaki H, Shiraki T, Uemura H, Okazawa M, et al. The effect of pulmonary rehabilitation in patients with post-tuberculosis lung disorder. *Chest.* 2003;123:1988-95.
 5. Acha J, Sweetland A, Guerra D, Chalco K, Castillo H, Palacios E. Psychosocial support groups for patients with multidrug-resistant tuberculosis: five years of experience. *Glob Public Health.* 2007;2:404-17.
 6. Furin JJ, Mitnick CD, Shin SS, Bayona J, Becerra MC, Singler JM, et al. Occurrence of serious adverse effects in patients receiving community-based therapy for multidrug-resistant tuberculosis. *Int J Tuberc Lung Dis.* 2001;5:648-55.
 7. Vega P, Sweetland A, Acha J, Castillo H, Guerra D, Smith Fawzi MC, et al. Psychiatric issues in the management of patients with multidrug-resistant tuberculosis. *Int J Tuberc Lung Dis.* 2004;8:749-59.
 8. Arbex MA, Varella MCL, Siqueira HR, Mello FA. Antituberculosis drugs: drug interactions, adverse effects, and use in special situations. Part 2: second-line drugs. *J Bras Pneumol.* 2010;36:641-56.
 9. Hendarto A and Sjarif DR. Antropometri Anak dan Remaja. In: Sjarif DR, Lestari ED, Mexitalia M, and Nasar SS, editor. *Buku Ajar Nutrisi Pediatrik dan Penyakit Metabolik.* Balai Penerbit IDAI, 2011:p25-37.
 10. Nellhaus G. Head circumference from birth to eighteen years: practical composite international and interracial. *Pediatrics.* 1968;41:106-14.
 11. Murphy M, Bergmann P, Chiang C, Stumer R, Howard B, Abel MR, et al. The PSC-17: subscale scores, reliability, and factor structure in a new national sample. *Pediatrics.* 2016;138:e20160038.
 12. Dheda K, Gumbo T, Gandhi NR, Murray M, Theron G, Udwadia Z, et al. Global control of tuberculosis: from extensively drug-resistant to untreatable tuberculosis. *Lancet Respir Med.* 2014;2:321-38.
 13. Ford CB, Shah RR, Maeda MK, Gagneux S, Murray MB, Cohen T, et al. Mycobacterium tuberculosis mutation rate estimates from different lineages predict substantial differences in the emergence of drug-resistant tuberculosis. *Nat Genet* 2013; 45: 784-90.
 14. Chigutsa E, Visser ME, Swart EC, Denti P, Pushpakom S, Egan D, et al. The SLCO1B1 rs4149032 polymorphism is highly prevalent in South Africans and is associated with reduced rifampin concentrations: dosing implications. *Antimicrob Agents Chemother* 2011; 55: 4122-27.
 15. Biadlegne F, Sack U, and Rodloff AC. Multidrug-resistant tuberculosis in Ethiopia: efforts to expand diagnostic services, treatment and care. *Antimicrob Resist Infect Control.* 2014;3:31-40.
 16. Dheda K, Gumbo T, Gandhi NR, Murray M, Theron G, Udwadia Z, et al. Global control of tuberculosis: from extensively drug-resistant to untreatable tuberculosis. *Lancet Respir Med.* 2014;2:321-38.
 17. Byrd RP Jr, Mehta JB, and Roy TM. Malnutrition and pulmonary tuberculosis. *Clin Infect Dis.* 2002;35:634-5.
 18. Direktorat Jendral Penanggulangan Penyakit dan Kesehatan Lingkungan, Kementerian Kesehatan Republik Indonesia. Petunjuk teknis manajemen TB anak. Jakarta: Kemenkes RI; 2013. p. 44-8.
 19. Direktorat Jendral penanggulangan penyakit dan kesehatan lingkungan, Kementerian Kesehatan Republik Indonesia. Petunjuk teknis manajemen terpadu pengendalian tuberculosis resisten obat. Jakarta: Kemenkes RI; 2013. p. 1-69.
 20. Prasad R, Verma SK, Sahai S, Kumar S, Jain A. Efficacy and safety of Kanamycin, Ethionamide, PAS and Cycloserine in multi-drug resistant pulmonary tuberculosis patients. *Indian J Chest Dis Allied Sci.* 2006; 48:183-186.
 21. Arbex MA, Varella MCL, Siqueira HR, Mello FAF. Antituberculosis drugs: drug interactions, adverse effects, and use in special situations. Part 1: second-line drugs. *J Bras Pneumol.* 2010;36:626-40.
 22. Pasipanodya JG, Miller TL, Vecino M, Munguia G, Garmon R, Bae S, et al. Pulmonary impairment after tuberculosis. *Chest.* 2007;131:1817-24.
 23. Lee EJ, Lee SY, In KH, Yoo SH, Choi EJ, Oh YW, et al. Routine pulmonary function test can estimate the extent of tuberculous destroyed lung. *Scientific World Journal.* 2012;2012:835031.
 24. Ryu YJ, Lee JH, Chun EM, Chang JH, and Shim SS. Clinical outcomes and prognostic factors in patients with tuberculous destroyed lung. *Int J Tuberc Lung Dis.* 2011;15:246-50.
 25. Eren S, Eren MN, and Balci AE. Pneumonectomy in children for destroyed lung and the long-term consequences. *J Thorac Cardiovasc Surg.* 2003;126:574-81.
 26. Ahmed AEH, Ibrahim AS, and Elshafie SM. Pulmonary hypertension in patients with treated pulmonary tuberculosis: analysis of 14 consecutive cases. *Clin Med Insights Circ Respir Pulm Med.* 2011;5:1-5.

27. Bhattacharyya P, Saha D, Bhattacharjee PD, Das SK, Bhattacharyya PP, Dey R. Tuberculosis associated pulmonary hypertension: the revelation of a clinical observation. *Lung India*. 2016;33:135-9.
28. Hammerstingl C, Schueler R, Bors L, Momcilovic D, Pabst S, Nickenig G, et al. Diagnostic value of echocardiography in the diagnosis of pulmonary hypertension. *PLoS One*. 2012;7:e38519.
29. Ghofrani HA, Wiedemann R, Rose F, Schermuly RT, Olschewski H, Weissmann N, et al. Sildenafil for treatment of lung fibrosis and pulmonary hypertension: a randomised controlled trial. *Lancet*. 2002;360:895-900.
30. Seeger W, Adir Y, Barberà JA, Champion H, Coghlan JG, Cottin V, et al. Pulmonary hypertension in chronic lung diseases. *J Am Coll Cardiol*. 2013;62:109-16.
31. Society on Spinal Orthopaedic and Rehabilitation Treatment. Guideline Committee, Weiss HR, Negrini S, Rigo M, Kotwicki T, Hawes MC, et al. Indications for conservative management of scoliosis (guidelines). *Scoliosis*. 2006;1:5.
32. Negrini S, Aulisa AG, Aulisa L, Circo AB, de Mauroy JC, Durmala J, et al. 2011 SOSORT guidelines: Orthopaedic and Rehabilitation treatment of idiopathic scoliosis during growth. *Scoliosis*. 2012;7:3.
33. Peltzer K, Naidoo P, Matseke G, Louw J, McHunu G, Tutshana B. Prevalence of psychological distress and associated factors in tuberculosis patients in public primary care clinics in South Africa. *BMC Psychiatry*. 2012;12:89.
34. Cassileth BR, Lusk EJ, Strouse TB, Miller DS, Brown LL, Cross PA, et al. Psychosocial status in chronic illness: a comparative analysis of six diagnostic groups. *N Eng J Med*. 1984;311:506-11.
35. Kiecolt-Glaser JK, Glaser R. Depression and immune function: central pathways to morbidity and mortality. *J Psychosom Res*. 2002;53:873-6.
36. Weissman MM, Bland RC, Canino GJ, Faravelli C, Greenwald S, Hwu HG, et al. Cross-national epidemiology of major depression and bipolar disorder. *JAMA*. 1996;276:293-9.
37. Ahmad N, Javaid A, Syed Sulaiman SA, Basit A, Afridi AK, Jaber AA, et al. Effects of multidrug resistant tuberculosis treatment on patients' health related quality of life: results from follow up study. *PLoS One*. 2016;11:e0159560.

Long term follow-up of multidrug resistant tb in pubertal child

ORIGINALITY REPORT

17%

SIMILARITY INDEX

15%

INTERNET SOURCES

9%

PUBLICATIONS

0%

STUDENT PAPERS

PRIMARY SOURCES

1	www.coursehero.com Internet Source	4%
2	paediatricaindonesiana.org Internet Source	3%
3	scoliosisjournal.biomedcentral.com Internet Source	2%
4	wwwnc.cdc.gov Internet Source	2%
5	www.tandfonline.com Internet Source	2%
6	www.pih.org Internet Source	1%
7	Chandra Prakash Bhatt, B KC. "SIDE EFFECTS ASSOCIATED WITH DRUGS USED IN TREATMENT OF MULTI DRUG RESISTANT TUBERCULOSIS AND TREATMENT RELATED FACTORS OF MULTI DRUG RESISTANT TUBERCULOSIS PATIENTS IN KATHMANDU VALLEY", SAARC Journal of Tuberculosis,	1%

Lung Diseases and HIV/AIDS, 2017

Publication

-
- | | | |
|----|---|-----|
| 8 | Eren, S.. "Pneumonectomy in children for destroyed lung and the long-term consequences", The Journal of Thoracic and Cardiovascular Surgery, 200308
Publication | 1% |
| 9 | kitakyushu.iges.or.jp
Internet Source | 1% |
| 10 | www.cdc.gov
Internet Source | 1% |
| 11 | "Drug Resistance in Bacteria, Fungi, Malaria, and Cancer", Springer Science and Business Media LLC, 2017
Publication | <1% |
| 12 | bm Cresnotes.biomedcentral.com
Internet Source | <1% |
| 13 | Parida, Shreemanta K., Rebecca Axelsson-Robertson, Martin V. Rao, Nalini Singh, Iqbal Master, Anton Lutckii, Salmaan Keshavjee, Jan Andersson, Alimuddin Zumla, and Markus Maeurer. "Totally-drug resistant tuberculosis and adjunct therapies", Journal of Internal Medicine, 2014.
Publication | <1% |
| 14 | www.mdpi.com | |
-

<1%

15

J. Acha, A. Sweetland, D. Guerra, K. Chalco, H. Castillo, E. Palacios. "Psychosocial support groups for patients with multidrug-resistant tuberculosis: Five years of experience", Global Public Health, 2007

Publication

<1%

16

R. K. Riezebos. "The association of depressive symptoms with survival in a Dutch cohort of patients with end-stage renal disease", Nephrology Dialysis Transplantation, 08/04/2009

Publication

<1%

17

eprints.manipal.edu

Internet Source

<1%

Exclude quotes Off

Exclude matches Off

Exclude bibliography Off

Long term follow-up of multidrug resistant tb in pubertal child

GRADEMARK REPORT

FINAL GRADE

/100

GENERAL COMMENTS

Instructor

PAGE 1

PAGE 2

PAGE 3

PAGE 4

PAGE 5

PAGE 6

PAGE 7
