



Gonial Angle Characteristics of Class III Malocclusion in Javanese Ethnic

Melisa Budipramana¹, Theresia Indah Budhy¹, I Gusti Aju Wahyu Ardani²

¹Postgraduate School, Universitas Airlangga, Surabaya, Indonesia.

²Orthodontic Department, Faculty of Dental Medicine, Universitas Airlangga, Surabaya, Indonesia.

Correspondence: I G. A. Wahyu Ardani, DDS, MSc, Ph.D., Department of Orthodontic, Faculty of Dental Medicine, Universitas Airlangga, Campus A, Jl Prof. Dr. Moestopo, No. 47, Surabaya 60132, East Java, Indonesia. **E-mail:** wahju_ardani@fkg.unair.ac.id

Academic Editor: Ana Maria Gondim Valença

Received: 01 July 2020 / **Review:** 05 September 2020 / **Accepted:** 27 October 2020

How to cite: Budipramana M, Budhy TI, Ardani IGAW. Gonial angle characteristics of class III malocclusion in Javanese ethnic. *Pesqui Bras Odontopediatria Clín Integr.* 2021; 21:e0153. <https://doi.org/10.1590/pboci.2021.051>

ABSTRACT

Objective: To describe the gonial angle characteristics in class III skeletal malocclusion in Javanese ethnic.

Material and Methods: Pretreatment lateral cephalometric radiographs of 43 Javanese ethnic patients were measured: upper (Go1) and lower gonial angle (Go2), anterior (AFH) and posterior face height ratio (PFH), maxilla-mandibular length difference, mandibular plane angle (FMA), Y axis, ramus position, ANB angle, posterior cranial base/ramus height and mandibular body length/anterior cranial base. The relation between Go1, Go2 and other variables were analysed using correlation and regression analysis. **Results:** The total gonial angle is within normal range, but Go1 is below normal and Go2 is above normal. There is no difference between male and female gonial angle measurements ($p=0.939$ and $p=0.861$, respectively). Ramus position is positively correlated to Go1 ($p=0.003$), while AFH ($p=0.000$), maxilla-mandibular length difference ($p=0.000$), FMA ($p=0.000$), Y axis ($p=0.000$), and posterior cranial base/ramus height ($p=0.018$) are positively correlated to Go2. PFH is negatively correlated to Go2 ($p=0.018$). **Conclusion:** The upper gonial angle is influenced by the position of mandibular ramus, while the lower gonial angle is affected by the posterior and anterior lower facial height and mandibular size and rotation. Javanese with class III malocclusion tends to have hypodivergent facial type, with more posteriorly located mandibular ramus and excess mandibular length.

Keywords: Orthodontics; Malocclusion, Angle Class III; Cephalometry.

Introduction

There are many factors that cause a malocclusion, including genetic and environmental factors. Class III skeletal malocclusion has a tendency to be inherited in the family, so it can be inferred that there is a strong relationship between genetic and malocclusion. The fact that the prevalence of class III malocclusion varies greatly in various races is a strong evidence of the genetic influence on malocclusion. The highest prevalence is found in the Chinese population (19.9%), while the lowest prevalence is in the Israeli population (0.7%) [1]. The prevalence in African population is 4.59%, while it varies between 2% to 6% in European population [2]. Malaysia population has a relatively high prevalence of 16.59% [3]. The Javanese, as one of the most common ethnic groups in Indonesia, is included in the same Deutero Malay sub-race as the Malaysian [4], so that they may have the same prevalence of class III malocclusion. However, there is still no study about the prevalence and characteristics of class III skeletal malocclusion in Javanese population.

Class III skeletal malocclusion in those populations have its own diverse characteristics. This will affect the orthodontic treatment plan that will be carried out [5], especially on growing patients. One of the important characteristics of malocclusion that affects facial aesthetics is the gonial angle. According to anthropometric standards, the normal gonial angle should be in the range of $123.5^\circ \pm 5.9^\circ$ in men and $122.2^\circ \pm 4.2^\circ$ in women. The increased gonial angle is generally caused mandibular clockwise rotation in class III malocclusion. The changes in the gonial angle can also affect anterior and posterior facial height and are influenced by age, sex, and teeth [6]. Jarabak and Fizzell divided the gonial angle into upper and lower gonial angle [7].

The specific characteristics of class III skeletal malocclusion in certain ethnic groups may affect orthodontic treatment plan on growing patients. Several interceptive approaches are available for treating class III skeletal malocclusion, for example, removable functional appliances, chin cup and skeletal anchorage systems [8]. These treatments have their own advantages and disadvantages. The use of chin cup causes clockwise rotation and delayed growth of the mandible [9], while miniscrew-anchored inverted FRD causes distalization of mandibular dentition without increasing anterior facial height [10].

Therefore, this study was conducted to observe the gonial angle characteristics in class III skeletal malocclusion in Javanese ethnic group. The result of this study will be used to be a help when determining orthodontic treatment plan in Javanese patients with class III skeletal malocclusion, as their mandibular growth trend is known.

Material and Methods

Ethical Clearance

This study was reviewed and approved by Ethical Review Board of Faculty of Dental Medicine Universitas Airlangga (No. 042/HRECC.FODM/II/2020).

Sample

Pretreatment lateral cephalometric radiographs of all Javanese ethnic group patients in orthodontic clinic at Universitas Airlangga Dental Hospital in 2018-2019 were analyzed. There were 494 (78.5%), 69 (11%) and 66 (10.5%) patients with class I, II and III skeletal malocclusions, respectively. Only 43 patients (19 men and 24 women, age range 18-29 years old) met the sample criteria in this study. The inclusion criteria are: Javanese individuals, ANB < 0°, negative overjet, and minimum 18 years old. The exclusion criteria include previous history of orthodontic treatment or orthognathic surgery, the presence of craniofacial deformity or genetic syndrome, missing teeth and supernumerary teeth.

Data Collection

After patients' consents had been obtained, their pretreatment cephalometric radiographs were analyzed using OrthoVision (Vatech Co., Ltd., Gyeonggi-do, South Korea) by a single examiner (an orthodontist). Each radiograph was examined twice with a 2-week interval. The cephalometric measurements are (Figure 1):

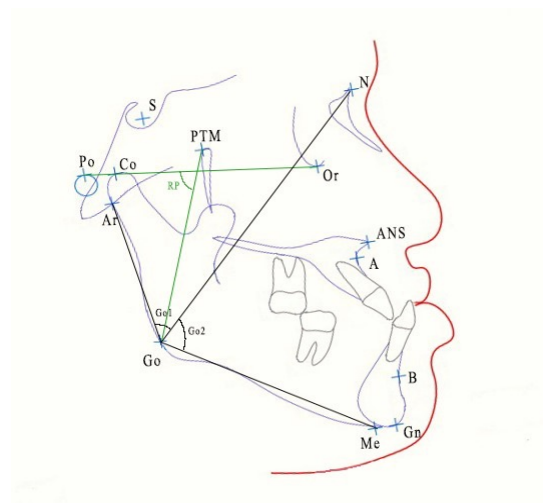


Figure 1. Cephalometric landmarks used in this study. Go1, Go2 and RP angles are shown.

- Upper gonial angle (Go1): the angle between point Articulare (Ar) - Gonion (Go) - Nasion (N).
- Lower gonial angle (Go2): the angle between point N - Go - Menton (Me).
- Anterior face height ratio (AFH): length ratio percentage of Anterior Nasal Spine (ANS) - Me and N - Me.
- Posterior face height ratio (PFH): length ratio percentage of Sella Tursica (S) - Go and N - Me.
- Maxilla-mandibular length difference (MMD): the length of Condylion (Co) - Point A minus the length of Co - Gnathion (Gn).
- Mandibular plane angle (FMA): the angle between Frankfurt Horizontal (Porion (Po) - Orbita (Or)) and Go - Gn.
- Y axis: the angle between Frankfurt Horizontal and S - Gn.
- Ramus position (RP): the angle between Frankfurt Horizontal and Pterygomaxillary fissure (PTM) - Go.
- ANB: the angle between point A - N - point B.
- Posterior cranial base/ramus height (PCrRH): length ratio of S - Ar and Ar - Go.
- Mandibular body length/anterior cranial base (MBACr): length ratio of Go - Me and N - S.

Data Analysis

All data were analysed using IBM SPSS version 24. All variables' descriptive statistics were analyzed. All data were analysed using Shapiro-Wilk normality test and Levene's homogeneity test. The upper and lower gonial angle data were then analysed with Brown-Forsythe's confounding test to compare each Go1 and Go2 measurements in male and female subjects. The relation between Go1 and Go2, respectively, and other variables were analysed using correlation and regression analysis.

Results

The average and standard deviation of each variable are shown in Table 1. The upper gonial angle is lower than normal, but the lower gonial angle is higher than normal. However, the total gonial angle is within normal range. The anterior face height ratio is within normal range, but the posterior face height ratio is below normal. The difference between mandibular and maxilla length is quite big. Mandibular plane angle shows that it is slightly higher than normal, while Y axis is within normal range. Ramus position, ANB angle and the ratio of posterior cranial base and ramus height is below the normal range, while the ratio of mandibular body length and anterior cranial base is higher than normal.

Table 1. Descriptive statistics of class III malocclusion in Javanese ethnic group.

Variables	Mean	SD	Normal
Upper Gonial Angle	46.5495	3.4679	53.50 ± 1.50
Lower Gonial Angle	75.9353	6.1629	72.50 ± 2.50
Total Gonial Angle	122.4849	7.5749	110.32 ± 123.0
Anterior Face Height Ratio	54.8726	2.4240	55.45 ± 1.79
Posterior Face Height Ratio	65.4040	4.9447	85.00 ± 5.50
Maxilla-mandibular Length Difference	48.0393	5.6385	28.00 ± 3.20
Mandibular Plane Angle	29.3614	8.3256	24.20 ± 4.60
Y Axis	62.7128	5.5826	61.00 ± 2.80
Ramus Position	62.6784	5.2526	73.60 ± 3.50
ANB	-4.1400	2.5233	2.40 ± 1.80
Posterior Cranial Base/Ramus Height	0.6730	0.0887	0.72 ± 0.08
Mandibular Body Length/Anterior Cranial Base	1.2167	0.0723	1.08 ± 0.03

There is no significant difference between male and female gonial angle measurements ($p > 0.05$) (Table 2).

Table 2. Gonial angle measurements.

Gonial Angle	Sex	Mean	SD	Confounding Test p-value
Upper Gonial Angle	Male	46.5016	4.1009	0.939
	Female	46.5875	2.9659	
Lower Gonial Angle	Male	75.7474	6.2691	0.861
	Female	76.0842	6.2086	

As shown in Table 3, all data were normal and homogen, except mandibular plane angle (not normal, $p < 0.05$). The correlation p-values are shown in Table 3. Ramus position (RP) is the only variable that significantly correlated to Go1. Hence, the regression formula of ramus position and Go1 correlation is: $Go1 = 28.415 + (0.289 \times RP)$.

There are several variables that significantly correlated to Go2, which are anterior and posterior face height ratio, maxilla-mandibular length difference, mandibular plane angle, Y axis, and posterior cranial base/ramus height. These variables correlate in a positive manner with Go2, except posterior face height ratio. The linear regression formula for each variable are:

- $Go2 = 2.076 + (1.346 \times AFH)$
- $Go2 = 137.230 - (0.937 \times PFH)$
- $Go2 = 43.417 + (0.677 \times EMM)$
- $Go2 = 56.759 + (0.653 \times FMA)$
- $Go2 = 29.931 + (0.734 \times Yaxis)$
- $Go2 = 59.173 + (24.906 \times PCrRH)$

Table 3. The significance (p) values of normality and homogeneity test.

Variables	p-values		Correlation p-values	
	Normality	Homogeneity	Go1	Go2
Upper Gonial Angle	0.169	0.136		
Lower Gonial Angle	0.339	0.953		
Anterior Face Height Ratio	0.484	0.846	0.971	0.000 ^a
Posterior Face Height Ratio	0.737	0.544	0.111	0.000 ^a
Maxilla-mandibular Length Difference	0.921	0.680	0.584	0.00 ^a
Mandibular Plane Angle	0.015 ^b	0.635	0.500 ^c	0.000 ^{a c}
Y Axis	0.632	0.304	0.203	0.000 ^a
Ramus Position	0.943	0.219	0.003 ^a	0.299
ANB	0.123	0.413	0.994	0.314
Posterior Cranial Base/Ramus Height	0.879	0.332	0.504	0.018 ^a
Mandibular Body Length/Anterior Cranial Base	0.812	0.064	0.084	0.686

^aSignificant Correlation; ^bData Not Normal; ^cUsing Spearman's Rho Correlation.

Discussion

Craniofacial bone remodelling and displacement during growth in class III skeletal malocclusion are highly dependent on biological processes that are influenced by various balancing factors, such as muscular tone and tooth position. Craniofacial growth in class III skeletal malocclusion is largely determined by genetic factors, spontaneous structural changes, or adaptation to environmental changes that cause musculoskeletal imbalances [11]. Bjork suggested that the condyle is the center of mandibular growth and plays an important role in determining mandibular length. Chin position is also determined by the direction of condylar growth [12].

There are various types of class III skeletal malocclusion, including normal maxilla and mandibular overgrowth (true mandibular prognathism); overgrowth of both maxilla and mandible but the mandible grows more excessively; and maxillary hypoplasia and normal mandible. The dominant facial type of class III skeletal malocclusion among Asian population is the second type (overgrowth of both jaws but mandible grows more excessively). This data may affect the treatment plan when orthognathic surgery is chosen as therapy. The surgery will have to be performed on both jaws so that it will not cause bimaxillary protrusion [5].

The gonial angle is the confluence between mandibular plane and the tangent line along the outer border of mandibular ramus. This angle is influenced by age, sex, thickness of ramus bone cortex, condylar growth, and the strength of mandibular masticatory muscles [13]. The gonial angle has an important role in determining facial aesthetics. Orthodontists often use gonial angle as an indicator of mandibular growth pattern and rotation, as it also significantly correlates to facial height. Patients with mandibular downward and backward rotation accompanied by an increase in gonial angle are classified as "high angle", while upward and forward mandibular rotation with decreasing gonial angle are categorized as "low angle" [14].

Apart from cephalometric radiographs, gonial angle can also be observed through panoramic radiographs. Both radiograph projections can detect gonial angles accurately [15]. In this study, pretreatment cephalometric radiographs are used as they have been routinely used in Universitas Airlangga Dental Hospital to observe their diagnosis of malocclusion further before any orthodontic treatment is conducted.

In this study, there is no significant difference between male and female gonial angles. This result is in line with a study conducted by Park et al. [15] and Radhakrishnan et al. [16]. However, other studies state that the gonial angle in women is greater than men [17,18]. Other research by Larrazabal-Moron and Sanchis-Gimeno [19] in Mediterranean Caucasian population shows that the gonial angle in 16-21 years old male is significantly higher than female in the same age range, but there is no significant difference in the older age group, which is 21-31 years old.

It is observed that in Javanese population, class III malocclusion patients tend to have smaller upper gonial angle and greater lower gonial angle compared to normal range. Even so, the total gonial angle is within the normal range. Based on the correlation and regression analysis results, Go1 is influenced by ramus position. The more posterior the ramus is, the smaller the Go1 measurement. On the contrary, the mean of Go2 is slightly above the normal range, which is caused by excess mandibular length and clockwise rotation of mandible. These Go1 and Go2 results are in line with the results of previous study on class III malocclusions of Javanese population, but the total gonial angle in the previous study is greater than normal range [20]. Another study conducted by Rodriguez-Cardenas et al. gives different results, where the total gonial angle in class III malocclusion is greater than normal, with a normal Go1 and greater Go2 [10]. The total gonial angle in class III malocclusion of female Japanese and Caucasian also shows greater than normal results [21], with an average value greater than that of the Javanese population in the study by Ardani et al. [20].

Another study on class II skeletal malocclusion of Javanese ethnic group also shows that the mean of Go1 is smaller than normal, while Go2 is greater than the normal range. In that study, it is concluded that the great value of Go2 is caused by clockwise rotation of mandible [22]. However, this result gives rise to the suspicion that the normal gonial angle in Javanese population is different from that of the Caucasian.

The ratio of anterior lower face height in this study is within the normal range. This result is different from that of Syrian population, where class III malocclusion patients tend to have increased anterior lower facial height [23]. The ratio of posterior facial height/ anterior facial height is also lower than normal, which indicates that the Javanese tend to have hypodivergent facial type. Another study states that class III malocclusion patients tend to have hyperdivergent facial type due to the increase of lower anterior facial height and the reduction of posterior facial height [10].

Although the mandibular plane angle is slightly larger than the normal range, Y axis angle, which also indicates the direction of mandibular growth, is within the normal range. This result indicates that there is slight clockwise rotation of mandible. This is consistent with a study of Syrian population [23]. Compared to other Asian populations, the steepest angle of mandibular plane angle is found in the Japanese population, while the Chinese and Korean have a less steep mandibular plane angle [21].

The average length difference of maxilla and mandible is far above the normal range, which indicates that there is excess mandibular length with or without the presence of maxillary retrusion. In this study, pure linear distance measurements were not used to reduce the probability of error in scale. Therefore, ratio of linear distance is used, such as the ratio of anterior and posterior facial height, and the ratio of posterior cranial base length and ramus height. The ratio of posterior cranial base and ramus height is lower than normal, which is due to the relatively large ramus height and/or shorter posterior cranial base length.

The ratio of mandibular length and anterior cranial base is greater than normal. This may be caused by excess mandibular length and the shorter anterior cranial base length. This is consistent with a study conducted by Mouakeh [23], which states that the Asian population tend to have maxillary growth deficiency which is related to shorter anterior cranial base. On the other hand, mandibular prognathism is an important component of class III skeletal malocclusion in European-American [23]. In this case, the Javanese population have the combination of both.

The position of mandibular ramus is much smaller than normal. This means that the ramus is located more posterior than that of class I skeletal type. A more posterior ramus should be advantageous in class III patients to compensate excess mandibular growth and improve the facial profile [23]. However, the length of mandible in class III malocclusion in the Javanese population is much longer than normal, so mandibular

prognathism persists. This result is different from Ricketts' hypothesis about class III growth patterns, which states that the ramus position is usually located more forward than normal [24].




As the Javanese with class III malocclusion tends to have hypodivergent facial type, with more posteriorly located mandibular ramus and excess mandibular length, it can be inferred that clockwise mandibular rotation can be done in treating Javanese class III patients in the growing age. The use of chin cap may be advantageous, as it tends to cause downward-backward rotation of mandible and the increase of anterior facial height [25].

The drawback of this study is that the normal cephalometric value of Javanese population is not available for some cephalometric analysis. Besides, the number of samples is relatively small because it is quite difficult to find adults with class III skeletal malocclusion who have not undergone any orthodontic or surgical treatment. In addition, most studies only examine the total gonial angle without separating it into more detailed upper and lower gonial angle, so that it is not yet possible to compare the Go1 and Go2 of Javanese ethnic group to those of other ethnic groups. As this is the result of this study is population-based, it may be difficult to apply to all patients. However, this study can still be helpful when there is no previous history of craniofacial growth pattern of a patient.

Conclusion

The gonial angle in class III malocclusion in Javanese population is within the normal range. However, the upper gonial angle is below the normal range and the lower gonial angle is higher than normal. The upper gonial angle is influenced by the position of mandibular ramus, while the lower gonial angle is affected by the posterior and anterior lower facial height, and mandibular size and rotation. Javanese with class III malocclusion tends to have hypodivergent facial type, with more posteriorly located mandibular ramus and excess mandibular length.

Authors' Contributions

MB		https://orcid.org/0000-0002-2620-3311	Conceptualization, Methodology, Formal Analysis, Investigation, Writing - Original Draft and Writing - Review and Editing.
TIB		---	Conceptualization, Methodology, Formal Analysis, Investigation, Writing - Original Draft and Writing - Review and Editing.
IGAA		https://orcid.org/0000-0002-4874-2906	Conceptualization, Methodology, Formal Analysis, Investigation, Writing - Original Draft and Writing - Review and Editing.

All authors declare that they contributed to critical review of intellectual content and approval of the final version to be published.

Financial Support

Annual Work Plan and Budget of Faculty of Dental Medicine, Universitas Airlangga No. 601/UN3.14/PT/2020.

Conflict of Interest

The authors declare no conflicts of interest.

Data Availability

The data used to support the findings of this study can be made available upon request to the corresponding author.

References

- [1] Alhammadi MS, Halboub E, Fayed MS, Labib A, El-Saaidi C. Global distribution of malocclusion traits: a systematic review. *Dental Press J Orthod* 2018; 23(6):40.e1-10. <https://doi.org/10.1590/2177-6709.23.6.40.e1-10.onl>
- [2] Hardy DK, Cubas YP, Orellana MF. Prevalence of Angle class III malocclusion: a systematic review and meta-analysis. *OJEpi* 2012; 2(4):75-82. <https://doi.org/10.4236/ojepi.2012.24012>

- [3] Woon KC, Thong YL, Kadir AR. Permanent dentition occlusion in Chinese, Indian and Malay groups in Malaysia. *Aust Orthod J* 1989; 11(1):45-48
- [4] Hatin WI, Nur-Shafawati AR, Zahri MK, Xu S, Jin L, Tan SG, et al. Population genetic structure of Peninsular Malaysia Malay Sub-Ethnic Groups. *PLoS ONE* 2011; 6(4):e18312. <https://doi.org/10.1371/journal.pone.001831>
- [5] Park JU, Baik SH. Classification of angle class III malocclusion and its treatment modalities. *Int J Adult Orthod Orthognath Surg* 2001; 16(1):19-29.
- [6] Claudio R, Claudio U, Alessandro A, Massimiliano T, Angelo M. Variations of the gonial angle in vertical surgical reduction of the maxillary-mandibular complex. *J Craniofac Surg* 2005; 16(4):716-719. <https://doi.org/10.1097/01.scs.0000157203.19557.b7>
- [7] Jarabak JR, Fizzell JA. *Technique and Treatment with Light-Wire Edgewise Appliances*. 2nd. ed. Saint Louis: C. V. Mosby Co.; 1972. 588p.
- [8] Wendl B, Stampfl M, Muchitsch AP, Droschi H, Winsauer H, Walter A, et al. Long-term skeletal and dental effects of facemask versus chin cup treatment in Class III patients: a retrospective study. *J Orofac Orthop* 2017; 78(4):293-9. <https://doi.org/10.1007/s00056-017-0083-3>
- [9] Mousoulea S, Tsolakis I, Ferdianakis E, Tsolakis AI. The effect of chin-cup therapy in class III malocclusion: a systematic review. *Open Dent J* 2016; 10:664-79. <https://doi.org/10.2174/1874210601610010664>
- [10] Eissa O, ElShennawy M, Gaballah S, ElMehy G, El-Bialy T. Treatment of class III malocclusion using miniscrew-anchored inverted Forsus FRD: controlled clinical trial. *Angle Orthod* 2018; 88(6):692-701. <https://doi.org/10.2319/110717-760.1>
- [11] Auconi P, Scazzocchio M, Caldarelli G, Nieri M, McNamara JA, Franchi L. Understanding interactions among cephalometrics variables during growth in untreated Class III subjects. *Eur J Orthod* 2017; 39(4):1-7. <https://doi.org/10.1093/ejo/cjw084>
- [12] Ghiz MA, Ngan P, Gunel E. Cephalometric variables to predict future success of early orthopedic Class III treatment. *Am J Orthod Dentofacial Orthop* 2005; 127(3):301-306. <https://doi.org/10.1016/j.ajodo.2004.02.014>
- [13] Folaranmi N. Gonial angle values in 12 to 15-year-old Nigerians. *J Coll Med* 2010; 14(2):60-5.
- [14] Xiao D, Gao H, Ren Y. Craniofacial morphological characteristics of Chinese adults with normal occlusion and different skeletal divergence. *Eur J Orthod* 2011; 33(2):198-204. <https://doi.org/10.1093/ejo/cjq064>
- [15] Park SH, Kim YJ, Lee SH, Kim CC, Jang KT. The simple regression model of gonial angles: comparison between panoramic radiographs and lateral cephalograms. *J Korean Acad Pediatr Dent* 2017; 44(2):129-37. <https://doi.org/10.5933/JKAPD.2017.44.2.129>
- [16] Radhakrishnan PD, Varma NKS, Ajith VV. Dilemma of gonial angle measurement: panoramic radiograph or lateral cephalogram. *Imaging Sci Dent* 2017; 47(2):93-7. <https://doi.org/10.5624/isd.2017.47.2.93>
- [17] Jensen E, Palling M. The gonial angle: a survey. *Am J Orthod* 1954; 40(2):120-33. [https://doi.org/10.1016/0002-9416\(54\)90127-X](https://doi.org/10.1016/0002-9416(54)90127-X)
- [18] Bhardward D, Kumar JS, Mohan M. Radiographic evaluation of mandible to predict the gender and age. *J Clin Diagn Res* 2014; 8(10):ZC66-69. <https://doi.org/10.7860/JCDR/2014/9497.5045>
- [19] Larrazabal-Moron C, Sanchis-Gimeno JA. Gonial angle growth patterns according to age and gender. *Ann Anat* 2018; 215:93-6. <https://doi.org/10.1016/j.aanat.2017.09.004>
- [20] Ardani IGAW, Wicaksono A, Hamid T. The occlusal plane inclination analysis for determining skeletal class III malocclusion diagnosis. *Clin Cosmet Investig Dent* 2020; 12:163-71. <https://doi.org/10.2147/CCIDE.S248983>
- [21] Ishii N, Deguchi T, Hunt NP. Craniofacial differences between Japanese and British Caucasian females with a skeletal class III malocclusion. *Eur J Orthod* 2002; 24(5):493-9. <https://doi.org/10.1093/ejo/24.5.493>
- [22] Ardani IGAW, Willyanti I, Narmada IB. Correlation between vertical components and skeletal Class II malocclusion in ethnic Javanese. *Clin Cosmet Investig Dent* 2018; 10:297-302. <https://doi.org/10.2147/CCIDE.S188414>
- [23] Mouakeh M. Cephalometric evaluation of craniofacial pattern of Syrian children with Class III malocclusion. *Am J Orthod Dentofacial Orthop* 2001; 119(1):640-9. <https://doi.org/10.1067/mod.2001.112671>
- [24] Schulhof RJ, Nakamura S, Williamson WV. Prediction of abnormal growth in class III malocclusions. *Am J Orthod* 1977; 71(4):421-30. [https://doi.org/10.1016/0002-9416\(77\)90245-7](https://doi.org/10.1016/0002-9416(77)90245-7)
- [25] Naidu S, Suresh A. Effects of chin cup in the management of class III malocclusion. *JIDA* 2018; 12(10):39-42.