

Early healing phase in rat's calvarial critical-size defect after implantation of bovine cortical membrane

by Pratiwi Soesilowati

Submission date: 26-Feb-2020 06:56PM (UTC+0800)

Submission ID: 1264499170

File name: l-size_defect_after_implantation_of_bovine_cortical_membrane.pdf (1.64M)

Word count: 2315

Character count: 12865

EARLY HEALING PHASE IN RAT'S CALVARIAL CRITICAL-SIZE DEFECT AFTER IMPLANTATION OF BOVINE CORTICAL MEMBRANE

EKO WICAKSONO SUBAGIO¹, DAVID B. KAMADJAJA^{*2,4}, DIANIZA AFIKANINGTYAS¹, ZEFRY ZAINAL ABIDIN¹, PRATIWI SOESILOWATI³ AND COEN PRAMONO²

¹ Residency Program, Department of Oral and Maxillofacial Surgery, Faculty of Dental Medicine, Universitas Airlangga, Surabaya, Indonesia

² Department of Oral Maxillofacial Surgery, Faculty of Dental Medicine, Universitas Airlangga, Surabaya, Indonesia

³ Department of Oral Biology, Faculty of Dental Medicine, Universitas Airlangga, Surabaya, Indonesia

⁴ Stem Cell Research and Development Center, Universitas Airlangga, Surabaya, Indonesia

(Received 25 September, 2018; accepted 15 November, 2018)

Key words : Guided Bone Regeneration, Demineralized freeze dried bovine cortical bone membrane, Fibroblast, Angiogenesis

Abstract- Bovine pericardium collagen membrane (BPCM) had been widely used in guided bone regeneration (GBR) for alveolar bone augmentation; but it has prolonged biodegradation characteristic. A newly developed demineralized freeze-dried bovine cortical bone membrane (BCBM) is supposed to have osteogenic induction capacity. Yet, its effect on early bone healing phase needs to reveal. this study attempt to analyse the initial mechanisms of bone defect healing after implantation of BCBM in rat's calvaria critical-size defect compared with BPCM. Thirty rats used as samples were divided into 2 groups; the experimental and control group in which BCBM and BPCM were applied over calvaria defects, respectively. Five samples were sacrificed after 3, 5, and 7 days for histology examination using Haematoxylin Eosin (HE) staining. The amount of fibroblast and angiogenesis were counted and statistically analysed using Anova and t-test with significance being $p < 0.05$. There were no significant differences in the amount of fibroblast in both groups of after implantation on day 3, 5, and 7. There were no significant differences in the amount of angiogenesis between the two groups at 3 and 5 day after implantation ($p > 0.05$), but it was statistically higher than control group ($p < 0.05$) on day 7 post implantation. Bovine cortical bone membrane shows comparable effect on early healing phase of calvaria critical-size defect compared to bovine pericardial membrane. It is, therefore, has potential for use as guided bone regeneration membrane.

INTRODUCTION

Guided Bone Regeneration (GBR) is a combination of bone graft material and membrane that put between bone graft material and soft tissue. This membrane are used to protect bone healing process from fibroblast cell infiltration which induce fibrotic healing in bone defect (Buser *et al.*, 2009). Biological principle in GBR is using membrane to prevent epithelial cell tissue and connective tissue or non osteogenic cell infiltrate and proliferate into the bone defect.

One of the membranes that is widely used is bovine pericardium membrane (BPCM), which is made from the parietal part of the superficial pericardium.

BPCM is known for its non- antigenic property which makes it a mechanically strong membrane. However, it is associated with slow degradation (Liu dan Kerns, 2014). An alternative membrane to overcome BPCM weakness is, therefore, needed.

Bovine Cortical Bone Membrane (BCBM) is a novel membraneprocessed from bovine cortical bone. It is made by demineralization process to eliminate mineral component from the cortical bone so that organic matrix remains which logically contains proliferative growth factors such as PDGF, IGF, TGF which might induce bone defect healing (Liu and Kerns, 2014). Kamadjaja *et al.* (2017) has proved the safety of BCBM membrane. This study would evaluate the initial process of bone defects healing

*Corresponding author's email: david-b-k@fkg.unair.ac.id

after implantation of BCBM in rat's calvarial bone defect. Some variables of tissue healing in proliferative phase in initial healing process will be observed.

MATERIALS AND METHOD

This research is *Post Test Only Control Group Design* with observation of angiogenesis and fibroblast in rat's calvaria bone defect histologically after implantation of BCBM and BPCM in day 3, 5, and 7. In the first group the bone defects were covered with BCBM and in the second group the bone defect were implanted with BPCM.

The rats are first prepared for calvaria bone defect. It begin with Ketamine HCL intramuscular injection (20mg/kg body weight) as sedative. The hair on calvaria region is shaved and disinfected with povidone iodine 10%. Working area isolation with sterile plastic with hole in the centre part. The skin is incised until contacted with bone and then the bone defect were made by using micro motor, straight handpiece, wheel bur. Irrigation with NaCl 0.9% were used during this procedure.

Implantation of the membrane was done by using sterile instrument. Both BCBM and BPCM were cut and prepared for implantation with a size of 1cm x 1cm. Wound closure were done by suturing the incision wound with silk 3/0 above.

There were 3 groups: (1) BCBM group; (2) BPCM group); (3) control group (without membrane) each

of which consists of 15 samples. From each of the three groups five samples were taken from rat's calvaria on day 3, 5, and 7 post implantation and fixated in 10% formalin liquid. After that it is decalcified with formiate acid for 10 days. The calvaria parafin block is produced and then sliced from coronal side perpendicular to the base of calvaria bone defect, and then it is stained with Haematoxylin Eosin (HE) and examined histologically for angiogenesis and fibroblast using light microscope. Fibroblast cell count and angiogenesis were done by using "cellSens" standard program in the computer. The count were done randomly from the edge of bone defect in every sample, and then the average point were noted.

RESULTS

Histological result confirm more fibroblast cell and more dense in BCBM group day 3 and 5 compared with BPCM and control group. While in day 7 BPCM group shows more fibroblast cell but still BCBM implantation group is higher and shows significant differences ($p < 0.05$) than control group in day 5. Fibroblast average count in BCBM, BPCM, and control group is shown in Figure 2.

From the diagram above it is shown that after day 3, angiogenesis on BCBM implantation is higher than BPCM but it is almost show the same value, but on the contrary, there are more

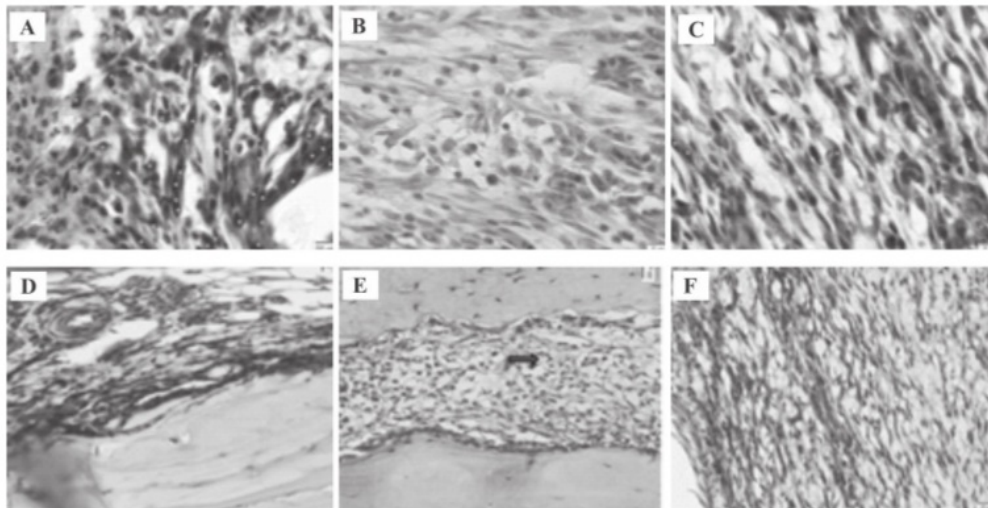


Fig. 1. Microscopy of early phase of tissue healing in rats' calvaria defect 5 days post implantation of BCBM BPCM and control group. Point a, b, c shows the fibroblast count in BCBM, BPCM, and control group after 5 days. Point d, e, f shows angiogenesis in BCBM, BPCM, and control group after 5 days

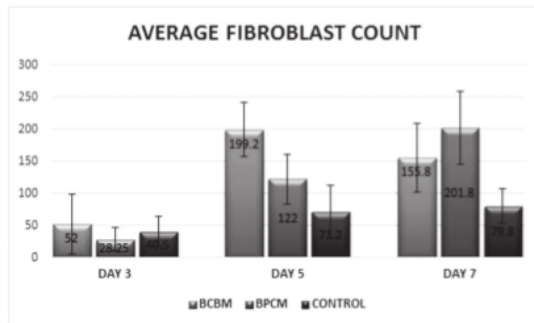


Fig. 2. Average Fibroblastin BCBM group, BPCM group, and control group after day 3, 5, and 7

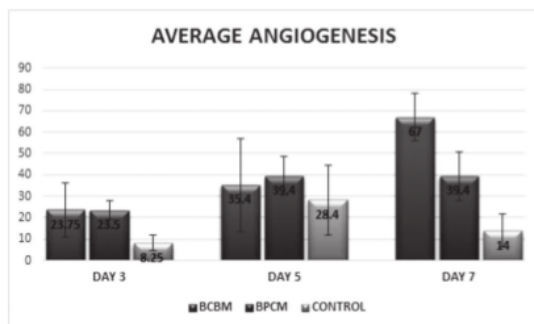


Fig. 3. Average Angiogenesis in BCBM group, BPCM group, and control group after day 3, 5, and 7

angiogenesis present in BPCM implantation group after day 5. While the angiogenesis on BCBM implantation group is far higher than BPCM implantation group and control group.

The result data is tested with Shapiro-Wilk normality test and continued with Anova and HSD Tukey test if data normally distributed or Kruskal-Wallis and Mann-Whitney test if the data not normally distributed. Statistical analysis shows significant differences ($p < 0.05$) in fibroblast count in BCBM group against control group in day 5, fibroblast count in BPCM group against control group in day 7. Statistical analysis in angiogenesis count show significant differences ($p < 0.05$) in BCBM group against BPCM and control group in day 7, and BPCM group against control group in day 7.

DISCUSSION

From the results after three-day implantation, histological examination show that the fibroblast after BCBM membrane implantation is more dense, darker, and tighter compared with BPCM membrane implantation and control group. This

result was also confirmed in Figure 2. It was obtained that the average fibroblasts in BCBM membrane implantation were more dense and darker than those of BPCM and control groups. This could happen because there is an inflammatory phase on the third day, where in this phase macrophages invade bone defects and fibrin deposition occurs in the tissues around bone defects (Boden *et al.*, 1995).

Likewise, statistically in the 5th day BCBM implantation group shows a histological picture (Figure 1) with higher fibroblast with significant difference ($p < 0,05$) and more spreaded than in BPCM implantation group and control group. This could occur because on the 5th day of the bone healing phase, chondroblast proliferation and osteoblasts occur from the peripheral periosteal and endosteal (Boden *et al.*, 1995). In addition to that, on cell proliferation stage, after approximately 5 days, hematoma will be organized, forming fibrin threads in the blood clot, forming tissue for revascularization, and invasion of fibroblasts and osteoblasts that developed from osteocytes, endothelial cells, and bone cells. Thus, fibrous connective tissue and cartilage (osteoid) are formed (Willie, 2010).

While the number of fibroblasts after 7 days, tended to be higher on BPCM implantation group than BCBM group. Nevertheless, the number of fibroblasts in BCBM membranes is still descriptively higher than the control group. The pericardial membrane network structure has three layers, which consist mostly of collagen and elastic fiber tissue embedded in an amorphous matrix with porous surfaces for cellular attachment and proliferation, but also in sufficient density for soft tissues (Rothamel *et al.*, 2012).

Histological picture of the number of angiogenesis on the 3rd day after BCBM membrane implantation compared with BPCM membrane and control group obtained more angiogenesis results in BPCM membrane than BCBM membrane and control group, but more porosity on BPCM and without membranes (indicating the number of larger blood vessels and capillaries around the membrane). Statistically, in figure 3 the results of the differences were not significant. It means that angiogenesis in the BCBM and BPCM groups did not differ much.

Histological picture of the number of angiogenesis on the 5th day after BCBM membrane implantation (Figure 1 point D) compared with BPCM membrane and control group without

membrane obtained the results of angiogenesis in control groups appearing the least, but there is still an inflammatory process, seen with the presence of several inflammatory cells compared to BCBM membrane group, but with different patterns, without spreading on the row. This could happen because there is still more inflammation in the group of bone defects without membranes, while the number of angiogenesis on day 5 in the group with both membranes appears more due to vasculogenesis to supply oxygenation to the tissue to avoid tissue hypoxia. This is because the tissue response to GBR membrane implantation in the early stages of acute inflammation, inflammatory cells and angiogenesis around the membrane could penetrate the membrane through clefts or pores (Oliveira *et al.*, 2004).

Histological feature of the number of angiogenesis on 7th day after BCBM membrane implantation compared with BPCM membrane and control group without membrane showed more angiogenesis results on BCBM membranes with significant difference ($p < 0.05$) than BPCM and control groups. More pores between capillaries in BCBM membrane group. Statistically, the results of angiogenesis on 7th day of BCBM membrane group were higher than BPCM and control group, with statistical test obtained significant differences. During the angiogenesis and cartilage formation phase, during the first 7 to 10 days of bone healing, histological features show the formation of connective tissue including new cartilages and capillaries from pre-existing blood vessels near the periosteum and external soft tissues (Chairuddin, 1998).

BCBM still contains protein which plays a role in bone healing. It contains Bone Morphogenic Proteins (BMPs) which are reported to induce mesenchymal stem cells to proliferate and cell induction mediators to differentiate into osteoblasts (Galia, 2004). In addition, BCBM contains Transforming Growth Factor- β (TGF- β). TGF- β is a protein that plays a role in cell differentiation and proliferation. TGF- β is secreted by platelets, osteoblasts and chondroblasts. TGF- β binds to two specific receptors and stimulates intracellular signals from the SMAD protein and stimulates RUNX expression which is the key to osteoblast differentiation. All of these factors stimulate new bone formation (Hughes *et al.*, 2006).

CONCLUSION

Bovine cortical bone membrane shows comparable effect on early healing phase of calvaria critical-size defect compared to bovine pericardial membrane. It is, therefore, has potential for use as guided bone regeneration membrane.

REFERENCES

- Boden, S.D., Schimandle, J.H. and Hutton, W.C. 1995. An experimental intertransverse process spinal fusion model: radiographic, histologic, and biomechanical healing characteristics. *Spine*. 20 : 412-420.
- Buser, D., Dula, K., Hirt, H.P. and Schenk, R.K. 1996. Lateral Ridge Augmentation Using Autografts and Barrier Membranes/: A Clinical Study with 40 Partially Edentulous Patients. *Journal of Oral and Maxillofacial Surgery*. 54 (4) : 420-433.
- Chairuddin, R. 1998. *Pengantar Ilmu Bedah Orthopedi*. Cetakan I. Penerbit: Bintang Lamumpatue, Ujung Pandang: hal 6-11.
- Galia, A.C. 2004. Physicochemical Characterization of Two Deproteinized Bovine Xenografts. *Journal of Braz oral Res*. 5-10
- Hughes, F.J., Turner, W., Belibasakis, G. and Martuscelli, G. 2006. Effects Of Growth Factors and Cytokines on Osteoblast Differentiaton. *Journal of Periodontology*. 41: 4872.
- Kamadajaja, B.K. and Wahyuni, E. 2017. Uji Toksisitas Dan Differensiasi Osteogenic Demineralized Freeze Dried Cortical Bone Membrane Terhadap Kultur Rabbit Bone Marrow Mesenchymal Stem Cell (Eksperimental Laboratorik *in vitro*). *Karya Tulis Akhir*.????????????????
- Liu, J. and Kerns, D.G. 2014. Mechanism of guided bone regeneration : a review. *Open Dent J*. 8 : 56-65.
- Oliveira, R.C., Menezes, R., Cestari, T.M., Taga, E.M., Taga, R., Buzalaf, M.A.R. and Granjeiro, J.M. 2004. Tissue Response to A Membrane of Demineralized Bovine Cortical Bone Implanted in The Subcutaneous Tissue of Rats. *Brazilian Dental Journal*. 15 (1) : 3-8.
- Rothamel, D., Schwarz, F., Sager, M., Herten, M., Sculean, A. and Becker, J. 2005. Biodegradation of Differently Cross-Linked Collagen Membranes/: An Experimental Study in The Rat. *Clinical Oral Implants Research*. 16 (3) : 369-378.
- Willie, B.M., Petersen, A., Schmidt-Bleek, K., Cipitria A, Mehta, M., Strube, P., Lienau, J., Wildemann, B., Fratzl, P. and Duda, G. 2010. Designing Biomimetic Scaffolds for Bone Regeneration: Why Aim for A Copy of Mature Tissue Properties if Nature Uses A Different Approach?. *Soft Matter*. 6 : 4976-4987.

Early healing phase in rat's calvarial critical-size defect after implantation of bovine cortical membrane

ORIGINALITY REPORT

10%

SIMILARITY INDEX

7%

INTERNET SOURCES

7%

PUBLICATIONS

3%

STUDENT PAPERS

PRIMARY SOURCES

1	doaj.org Internet Source	3%
2	repository.ubaya.ac.id Internet Source	1%
3	www.thieme-connect.de Internet Source	1%
4	"New Perspectives in Regeneration", Springer Nature, 2013 Publication	1%
5	wwwsoc.nii.ac.jp Internet Source	1%
6	Kazuo Shirakawa, Masabumi Shibuya, Yuji Heike, Shigemitsu Takashima et al. "Tumor-infiltrating endothelial cells and endothelial precursor cells in inflammatory breast cancer", International Journal of Cancer, 2002 Publication	1%
7	Sri Wigati Mardi Mulyani, Eha Renwi Astuti, Otty	

Ratna Wahyuni, Diah Savitri Ernawati, Nastiti Faradilla Ramadhani. "Xerostomia Therapy Due to Ionized Radiation Using Preconditioned Bone Marrow-Derived Mesenchymal Stem Cells", European Journal of Dentistry, 2019

Publication

<1%

8

Rodrigo Cardoso de Oliveira, Renato Menezes, Tânia Mary Cestari, Eulázio Mikio Taga et al. "Tissue response to a membrane of demineralized bovine cortical bone implanted in the subcutaneous tissue of rats", Brazilian Dental Journal, 2004

Publication

<1%

9

www.ajol.info
Internet Source

<1%

10

Sheikh, Zeeshan, Corneliu Sima, and Michael Glogauer. "Bone Replacement Materials and Techniques Used for Achieving Vertical Alveolar Bone Augmentation", Materials, 2015.

Publication

<1%

11

www.i-scholar.in
Internet Source

<1%

12

Yoshiya Ueyama, Kunio Ishikawa, Takamitsu Mano, Takahiro Koyama, Hitoshi Nagatsuka, Kazuomi Suzuki, Kazuo Ryoke. "Usefulness as guided bone regeneration membrane of the alginate membrane", Biomaterials, 2002

<1%

13

Eliane P. Barboza, Carlos Eduardo B. Lugão.
"Treatment of a Human Transosseous
Mandibular Defect By Guided Bone
Regeneration", Journal of Periodontology, 2001

Publication

<1%

14

David B. Kamadjaja, Achmad Harijadi, Pratiwi
Soesilawati, Eny Wahyuni et al. "Demineralized
Freeze-Dried Bovine Cortical Bone: Its Potential
for Guided Bone Regeneration Membrane",
International Journal of Dentistry, 2017

Publication

<1%

Exclude quotes On

Exclude matches Off

Exclude bibliography On

Early healing phase in rat's calvarial critical-size defect after implantation of bovine cortical membrane

GRADEMARK REPORT

FINAL GRADE

/100

GENERAL COMMENTS

Instructor

PAGE 1

PAGE 2

PAGE 3

PAGE 4
