

EFFECT OF MUCOADHESIVE  
GINGIVAL PATCH FROM  
MANGOSTEEN PERICARP  
(GARCINIA MANGOSTANA L.)  
EXTRACT ON THE SOD LEVELS  
AND THE NUMBER OF  
NECROTIC CELLS DUE TO  
PANORAMIC RADIOGRAPHY

**Submission date:** 02-Aug-2022 11:00AM (UTC+0800)

**Submission ID:** 1877941628

**File name:** mber\_of\_necrotic\_cells\_due\_to\_panoramic\_radiography\_radiatio.pdf (69.05K)

**Word count:** 4376

**Character count:** 23497

RADIATION IN ACUTE PHASE

by Otty Ratna Wahjuni

## EFFECT OF MUCOADHESIVE GINGIVAL PATCH FROM MANGOSTEEN PERICARP (*GARCINIA MANGOSTANA* L.) EXTRACT ON THE SOD LEVELS AND THE NUMBER OF NECROTIC CELLS DUE TO PANORAMIC RADIOGRAPHY RADIATION IN ACUTE PHASE

Yunita Savitri<sup>1\*</sup>, Sri Wigati Mardi Mulyani<sup>1</sup>, Eha Renwi Astuti<sup>1</sup>, Otty Ratna Wahyuni<sup>1</sup>, Deny Saputra<sup>1</sup>, Fika Aisyah Yurike Dalu<sup>2</sup>, Tiara Nurramadhanty<sup>2</sup>, Efrinia Breta Pangkitya<sup>2</sup> and Aqil Fadhilah Karisma Lady<sup>2</sup>

<sup>1</sup>Department of Dentomaxillofacial Radiology, Faculty of Dental Medicine, Universitas Airlangga, Surabaya, Indonesia.

<sup>2</sup>Undergraduate Students, Faculty of Dental Medicine, Universitas Airlangga, Surabaya, Indonesia.

\*e-mail: yunita-s@fkg.unair.ac.id

(Received 18 July 2020, Revised 12 September 2020, Accepted 26 September 2020)

**ABSTRACT :** Panoramic radiography is a low-dose x-ray radiation technique often used in dentistry to determine the diagnosis, treatment plans and monitoring the results of treatments. It has ionizing radiation effect which cause free radical formation. The increase of free radical activity in cells can cause tissue damage by increasing peroxidation lipid process and resulting in necrosis. Superoxide Dismutase (SOD) as an endogenous antioxidant produced by the body to reduce free radicals has not been able to prevent cell death. Mangosteen's pericarp (*Garcinia mangostana*) contains xanthone as a bioactive component that has a high level of antioxidants. This study utilizes mucoadhesive gingival patches containing mangosteen's pericarp extract that facilitate the absorption of the bioactive substance in the gingival tissue that were exposed by radiation. The aim of this study is to determine the effect of mangosteen pericarp's mucoadhesive gingival patch on the SOD levels and necrotic cells number in gingival tissues due to panoramic radiography radiation. Thirty-five *Rattus norvegicus* samples were divided into 7 groups, given with mucoadhesive gingival patches and were exposed with x-ray radiation. The gingival tissues were taken for histopathological examination to determine the necrotic cell number and ELISA test to measure SOD levels. There were differences in SOD levels and necrotic cell number in gingival tissue between rats that were given mangosteen gingival patches and those that were not. Application of mangosteen's pericarp mucoadhesive patches can increase the SOD levels and decrease the number of necrotic cells in rat's gingival tissues due to panoramic radiography radiation in acute phase.

**Key words :** Panoramic radiography radiation, SOD, herbal medicine mucoadhesive gingival patch, mangosteen pericarp (*Garcinia mangostana* L.).

### INTRODUCTION

Panoramic radiography is a diagnostic radiology that can describe the entire maxilla and mandible in a single sheet of film so that it is useful for detecting dental abnormalities, dental support tissue and surrounding structures. Based on these advantages, panoramic radiography is one of the most commonly used radiographic tools in the field of clinical dentistry (Toppo, 2012). However, panoramic radiographs that use X-rays can pose a dangerous potential. X-rays are ionizing radiation can interact with cells or tissues of the human body, causing changes in the body due to the formation of free radicals (Bandu, 2014; Fakhurreza and Majidah, 2018).

Free radicals formed by x-ray exposure can trigger oxidative stress. This condition can cause lysis of cell membranes resulting in cell death by necrosis (Yuslianti,

2018). Necrosis is a type of cell death that can be caused by free radicals with marked membrane damage and changes in the cell nucleus, namely pyknosis, karyorrhexis and karyolysis (Lestari and Mulyono, 2011; Oktarian *et al*, 2017). In the acute phase, it can be found that there is a change in cell activity in the form of a cell nucleus that changes color to eosinophils (Hayati *et al*, 2016).

Physiologically free radicals in the human body will cause a spontaneous response in the form of the production of endogenous antioxidants such as the enzyme superoxide dismutase (SOD). Antioxidants act as inhibitors of oxidation by reacting with reactive free radicals to form non-reactive free radicals so they can protect cells or tissues from the harmful effects of free radicals (Khaira, 2010; Nugraha *et al*, 2020). SOD is an antioxidant metalloenzyme that will act by capturing superoxide anions through a rapid dismutase reaction and

then converted to a form of a less reactive free radical, namely hydrogen peroxide (Simamura and Fitri, 2009).

The existence of X-ray radiation exposure causes an imbalance of free radical levels more than antioxidants so that it can increase oxidative stress. If this continues, it will cause more serious abnormalities (Ighodaro and Akinloye, 2017). Under conditions of oxidative stress, the consumption of antioxidants is needed to increase the work requirements of antioxidants. Exogenous antioxidants can easily be found in herbal ingredients, one of which is mangosteen pericarp (Khaira, 2010; Narmada *et al*, 2020). Mangosteen pericarp contains antioxidants that have the effect of reducing the radiation generated can prevent tissue damage (Gutierrez-Orozco and Failla, 2013). The content of xanthenes in mangosteen pericarp has antioxidant functions that function through the mechanism of antioxidant scavengers that donate electrons to free radicals (Ansori *et al*, 2020). This is the first step of the free radical process which is the first step of the initiation and free radical propagation is hampered (Ighodaro and Akinloye, 2017).

Mangosteen pericarp extract contains antioxidants that are applied in the form of an adhesive gingival patch. Mucoadhesive gingival patches are fully applied pharmaceutical preparations that are designed to attach to the mucosal lining and have the ability to facilitate drug delivery in the gingival mucosa that supports the delivery system of drugs or conventional medicines (Setyawan *et al*, 2014).

From the expected exposure, mangosteen pericarp mucoadhesive gingival patch can overcome the effects of acute-phase panoramic radiographic radiation in experimental animals with indicators of increasing SOD levels and reducing the number of cells that improve necrosis.

## 17 MATERIALS AND METHODS

9 The study was a laboratory experimental analytic study with randomized post-test only control group design. In this study, the sample used were rats (*Rattus norvegicus*) with 7 study group designs, with replication of 5 rats per study group. The study was conducted after obtaining the Ethical Clearance certificate number 340 / HRECC. FODM / VI / 2019 issued by the Health Research Ethical Clearance Commission, Faculty of Dentistry, Airlangga University.

The classification of the study group was based on a combination of panoramic radiographic free variables and the application of mangosteen pericarp extract mucoadhesive gingival patch. The positive control group (K +) was not given radiation exposure and without being

given a patch, the negative control group 1 (KK1) was given radiation exposure and not given a patch with gingival tissue taking time on day 1, the negative control group 2 (KK2) was given radiation exposure and were not patched with gingival tissue taking time on day 5, negative control group 3 (KK3) were given radiation exposure and were not patched with gingival tissue taking time on day 7, treatment group 1 (KP1) were given radiation exposure and were patched with gingival tissue taking time 1 day, treatment group 2 (KP2) were given radiation exposure and patched with gingival tissue taking day 5, treatment group 3 (KP3) were given radiation exposure and patched with gingival tissue taking day to day -7.

**Preparation of experimental animals** began with the adaptation of 35 samples of Wistar rats (*Rattus norvegicus*) in accordance with the criteria for 7 days in a cage placed in a room with sufficient water and light flow and given food and drink to maintain the condition of the rat.

**Making mangosteen pericarp extract** begins with taking the pericarp from the mangosteen fruit and then cut into small pieces and dried for a day. After drying, then blended and sifted. The result is yellowish-brown flour then macerated in 96% ethanol for 2 days and then filtered with filter paper. The liquid obtained is evaporated using a Rotary Vacuum Evaporator at 40°C. The final extract was obtained in the form of a paste (Loegito, 2018).

**Making mangosteen pericarp extract mucoadhesive gingival patch using the solvent casting technique** (Shantiningsih and Diba, 2015; Tiensi, S and Sulaiman, n.d.). The composition of the preparation consists of formula 1, namely CMC-Na 1.5 gr which is dissolved in 30 ml of distilled water and then allowed to stand for 15 minutes and crushed to form a gel, the formed gel is added hot water as much as 60.3 gr. Then formula 2, which is menthol as much as 0.5gr is dissolved in 95% ethanol and added 0.5 grams of mangosteen peel extract paste and stirred until completely mixed to then add 2.5 g of propylene glycol. Furthermore, formula 1 and formula 2 are mixed until homogeneous. After being homogeneous, the formula is weighed as much as 70 grams and put into a petri dish for later in the oven at 45°C. The final patch that is ready to use is stored at room temperature.

**The installation of the mucoadhesive gingival patch of mangosteen pericarp extract in experimental animals** was carried out throughout the maxillary and mandibular gingiva that had been done with

ketamine anesthetic as much as 0.2 cc and maintained for  $\pm$  60 minutes. Patches are cut into small pieces and adjusted to the size of the gingival mucosa in the rat's jaw. Patching is done by opening the rat's jaw using a needle holder and patching is done using dental tweezers.

**X-ray radiation on rat** was carried out using Asahi Hyper-X CM digital panoramic dental radiography (power supply 220 V; 1.2 V; 1.5 kVA; 50/60 Hz). *Rattus norvegicus* model in anesthetized conditions arranged in a way on a wooden board measuring 15 x 20 cm with a height parallel to the horizontal panoramic radiographic machine.

**The taking and processing of tissue samples for measurement of the number of necrotic cells** were performed on all rat gingival tissue through surgery using a 10% ketamine anesthesia lethal dose according to the group of days post-treatment. Then take the rat's mandibula. On necrosis examination, the rat's mandibula was stored and fixed using 10% formalin buffer for 24 hours and continued with EDTA decalcification until the bone became soft so that it was ready for tissue processing. Gingival tissue processing on rats in necrosis examination was carried out starting from cutting macros, blocking, cutting, and deparaffinization so that preparation for histopathological examination was obtained. The preparations were stained with Hematoxylin-eosin to see cells undergoing necrosis (Mescher, 2011).

**Tissue sampling and processing for measurement of SOD activity** were carried out in all rats' gingival tissues through surgery using ketamine anesthetic 10% lethal dose according to the group of days after treatment. The tissue is stored in a polypropylene tube with NaCl solution before tissue processing. The initial stage of tissue processing begins by placing and cutting gingival tissue in a cold mortar placed in a block of ice then given a PBS-Tween: PMSF (9:1) solution of 1 mL and quartz sand to be crushed until smooth. Fine gingival tissue was added with PBS-Tween: PMSF (9:1) solution 2 ml and then transferred to a polypropylene tube to be homogeneous using vortex for 10 minutes, then sonicated with sonicator for 1 minute and then centrifuged for 15 minutes (6000 rpm). The supernatant formed is then taken and added to absolute cold ethanol in a ratio of 1: 1, and left for 1 night to form a precipitate. After that the sample was centrifuged for 15 minutes (10000 rpm), the sediment was taken and dried until the ethanol odor disappeared. The precipitate was then added with a solution of 0.02 M Tris HCl pH 6.5 cold with a volume ratio of 1: 1 (Aji, 2014).

**Measurement of the number of necrotic cells** was carried out by measuring the anatomic

histopathological preparations that had been stained HE under the light of a Nikon Multihead type microscope with 400 x magnification to see changes in the cell nucleus (pyknosis, karyorrhexis, and karyolysis) of five visual fields (Lestari and Mulyono, 2011).

**Measurement of SOD activity** was carried out by the ELISA method using the SOD Assay Kit (Bioenzy BZ-08188610-EB). A sample solution, standard solution, and a solution of Superoxide Dismutase Assay Kit reagents were prepared and put in a well. The plates were incubated at 37°C for 60 minutes, then rinsed using a washing buffer 5 times, then added a substrate solution A and B, and re-incubated for 10 minutes at 37°C. After incubation is complete, add stop solution and color develop which will change the color blue to good to yellow. After the color change occurs, the absorbance value is read at a wavelength of 450 nm using a microplate reader / ELISA reader, 10 minutes after the stop solution is added (Aji, 2014).

**Data analysis** using SPSS 21 program. Analysis of research data using the Shapiro-Wilk Test to find data normally distributed. A homogeneity test was carried out using the Levene test. Non-parametric comparison hypothesis testing uses Kruskal Wallis because the data are not normally distributed (Pumomo and Bramantoro, 2018).

## RESULTS

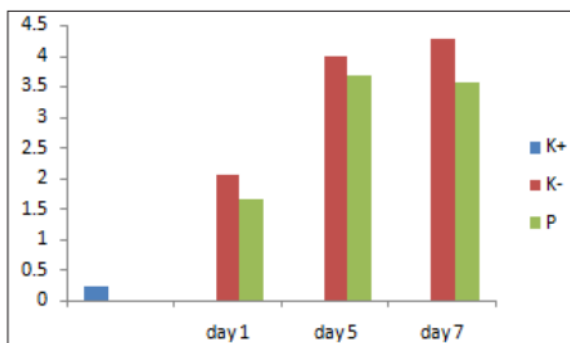
Mangosteen pericarp extract mucoadhesive gingival patch was tested on phantom to evaluate the quality of radiography films. The trial results show that the mangosteen pericarp extract mucoadhesive gingival patch does not affect the contrast, detail, and sharpness of the radiography film so that the radiography film can be interpreted properly.

The mean and results of the statistical hypothesis test on the number of necrotic cells are in Table 1 and the mean and the results of the statistical hypothesis test on the SOD concentration are in Table 2.

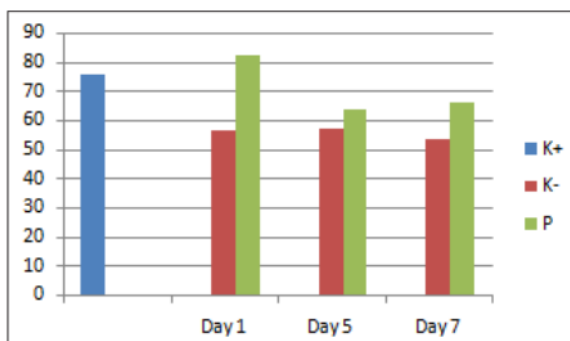
Table 1 shows the average of necrosis cell counts of and the Kruskal-Wallis Hypothesis Test in the positive control, negative control, and treatment groups on days 1, 5 and 7. The Kruskal-wallis shows significant result ( $p < 0.05$ ).

The number of necrotic cells found treatment group (P) was less than the number of necrotic cells in the negative control group (K-) (Fig. 1).

Table 2 shows the average of necrosis cell counts of and the Kruskal-Wallis Hypothesis Test in the positive control, negative control and treatment groups on days 1,



**Fig. 1 :** Graph of the number of necrotic cells between groups on day 1, 5 and 7 observations.



**Fig. 2 :** Graph of SOD concentration between groups on day 1, 5 and 7 observations.

**Table 1 :** Average value and Kruskal-wallis test of necrotic cells.

Variable	Mean	Asym. Sig ( P<0,05)
K+	0,24	0,01
K- 1	2,04	
K- 2	4	
K- 3	4,28	
P1	1,65	
P2	3,68	
P3	3,56	

**Table 2 :** Mean SOD concentrations and the Kruskal-Wallis Hypothesis Test in the positive control, negative control, and treatment groups on days 1, 5 and 7.

Variable	Mean	Asym. Sig ( P<0,05)
K+	75,58	0,226
K- 1	56,31	
K- 2	56,97	
K- 3	53,33	
P1	82,46	
P2	63,64	
P3	65,76	

5 and 7.

The number of SOD concentration found in treatment group (P) was more than the number of SOD concentration in the negative control group (K-) (Fig. 2).

**DISCUSSION**

Panoramic radiography is ionizing radiation that uses low-dose X-ray exposure. The use of ionizing radiation, not only can the benefits be taken, but some biological effects that can be caused, both direct and indirect effects. This study uses the levels of the enzyme superoxide dismutase and the amount of cell necrosis in the gingival tissue of experimental animals as indicators of lipid membrane damage, as well as cell damage caused by free radicals. Measurement of superoxide dismutase enzyme levels and the number of necrotic cells was carried out at the time of collection 24 hours, 5 days and 7 days after administration of panoramic radiographic radiation.

Based on the results of studies published in Tables 1 and 2, it is recognized as an increase in the number of cell necrosis and a decrease in SOD concentrations in the negative control group. This shows radiographic radiation that can cause cellular responses that are initiated by energy deposition during radiation against sensitive cellular targets. The radiation process will produce free radicals. Free radical compounds in the body can cause damage to others with polyunsaturated fatty acids that can damage cell membranes that can cause cell walls to become brittle and cause cell damage based on necrosis (Sudiana, 2008). In addition, calculating excess free radicals will cause SOD as a biomolecule to be damaged and its enzymatic activity will decrease (Nurhayati *et al*, 2011). Excessive free radicals also cause SOD enzymes that function as first-line antioxidants unable to neutralize free radicals resulting in oxidative stress (Aji, 2014).

The results of the research group support in Tables 1 and 2 obtained the number of necrotic cells and increased SOD concentrations compared to the negative control group. Decreasing the number of necrotic cells added by increasing SOD in the group that contributes to mangosteen pericarp extract through the application of mucoadhesive gingival fillings has good antioxidant activity and can increase the activity of endogenous antioxidants produced by the SOD enzyme. Exogenous antioxidants from the active ingredient of mangosteen peel extract namely xanthone compounds, antioxidants as scavengers that will donate electrons to free radicals resulting in inhibition of free radicals initiation and propagation (Ighodaro and Akinloye, 2017; Saraswati *et al*, 2018). With the exogenous antioxidants, the lipid

peroxidation process that occurs in cells will be inhibited so that it can decrease the number of necrosis cells. The role of antioxidant scavenger will maintain a high level of SOD concentration so that it can support further free radicals. One of the xanthone compositions which have this antioxidant effect is  $\alpha$ -mangostin. The  $\alpha$ -mangostin compound in mangosteen pericarp extract can reduce oxidative stress and reduce the presence of lipid peroxidation so it can decrease the number of necrotic cells.

The mean number of necrotic cells in a statistical test showed significant differences in several study groups. This shows that the mangosteen pericarp extract mucoadhesive gingival patch is able to provide a protective effect against panoramic radiographic radiation and has antioxidant properties so it can decrease the number of necrotic cells. The mean SOD concentration in the statistical test obtained was no significant difference in the SOD activities between the study groups. An insignificant difference was also found in the statistical tests between the consultation group and the negative control group on the number of necrotic cells. This can be caused by the use of digital panoramic radiography which has a lower effective dose than conventional panoramic radiography. This effective dose is used to estimate the risk of radiation in humans (White and Pharoah, 2014). With lower effective dosages, digital panoramic radiography can also produce a lower radiation effect compared to the use of conventional panoramic radiography (Shantiningsih and Diba, 2018). Cell death due to radiation can depend on the dose, duration of radiation, and the speed of the process of cell death (Yunus and Bandu, 2019). In addition, the effects of radiation from the panoramic radiography used can still be influenced by endogenous antioxidants to form SOD enzymes, so that they do not cause differences in the interest produced in SOD enzyme levels between treatments.

Differences in tissue radiosensitivity can also cause insignificant results. Periodontal tissue is composed of gingival and periradicular tissue. Gingiva which is part of the oral mucosa formed by the epithelium is classified as cells with high enough radiosensitivity, whereas periodontal bone is classified as cells with fairly low radiosensitivity (Iannucci and Howerton, 2017). However, the level of radiosensitivity of these two cells is still lower than endothelial cells of blood vessels that will receive X-ray radiation will quickly cause an acute response that increases vascular permeability which increases blood flow. Increased blood flow in the oral cavity can be known by increasing GCF (Shantiningsih and Diba, 2018).

Whereas, the new periodontal tissue will be very sensitive to high doses of radiation (Fernando and Lessang, 2017).

Another factor that may be important is the frequency of patching which is only done once before giving the radiation. This allows the level of mangosteen peel extract delivered to the gingival mucosa is not maximal (Shantiningsih and Diba, 2015). The patch is attached to the gingival mucosa only during anesthesia. The length of time that patches survive on the last mucosa by the inadequate patch material in improving bioadhesive properties. Modified patch materials such as a combination of polymers and support layers are supported to improve patch properties. Selection and modification of polymer materials with good swelling properties can improve the bioadhesive properties of the patch, while the support layer works to prevent the entry of water/saliva into the patch preparation so that the release time of the active substance from the patch lasts longer. Patches used in this study do not combine polymeric materials and do not use a backing layer of material, thus allowing the patch to be released in a short time (Shivhare *et al*, 2014).

## CONCLUSION

Application of mangosteen pericarp (*Garcinia mangostana* L.) extract mucoadhesive gingival patch in *Rattus norvegicus* animals can decrease the number of necrotic cells and increase the SOD level of panoramic radiographic radiation during the acute-phase. In further research, needs to be done with greater radiographic radiation exposure or repeated radiation exposure to get more optimal results, research is needed on other studies that discuss more about cooperatives that can be done by improving patch adhesions, can be verified and combined gingival patch material that can increase the retention of mucoadhesive gingival patches in tissues and research needs to be done on tissues that increase radiosensitivity.

## REFERENCES

- Aji Y L (2014) Effect of Putri Malu Leaf Extract Therapy (*Mimosa pudica* Linn) on Superoxide Dismutase (SOD) Enzyme Activity (SOD) and Lung Histopathology in Rats (*Rattus norvegicus*) Asthma Model. Universitas Brawijaya.
- Ansori A N M, Susilo R J K, Fadholly, Hayaza S, Nugraha A P and Husen S A (2020) Antidiabetes Type 2 Phytomedicine: Mangosteen (*Garcinia mangostana* L.) - A Review. *Biochem. Cell. Arch.* **20**(Supplement 1), 3173-3177.
- Bandu K (2014) *Effects of x-ray radiation on children*. Universitas Hasanuddin.
- Fakhrurraza M and Majidah P K (2018) The Effect of the amount of radiation and changes in X-Ray energy on increased free radical formation in water. **2**(1), 34-40.

- Fernando R and Lessang R (2017) Impact of Radiotherapy On the Periodonsium. In: *Cosmetic and Functional in Modern Periodontic. Cosmetic and Functional in Modern Periodontic* 12–17.
- Gutierrez-Orozco F and Failla M L (2013) Biological Activities and Bioavailability of Mangosteen Xanthenes/ : A Critical Review of Current Evidence. *J. Nutrients* **5**, 3163–3183.
- Hayati K, Astuti E R and Martini T (2016) Superoxide Dismutase, Catalase, and Malondialdehyde Levels of Wistar Rat's Submandibular Glands after Gamma Ray Irradiation. *J. Syiah Kuala Dentistry Society* **1**(2), 110–121.
- Iannucci J M and Howerton L J (2017) *Dental Radiography Principles and Techniques* (5th ed.). St. Louis: Elsevier Ltd.
- Ighodaro O M and Akinloye O A (2017) First line defence antioxidants-superoxide dismutase (SOD), catalase (CAT) and glutathione peroxidase (GPX): Their fundamental role in the entire antioxidant defence grid First line defence antioxidants-superoxide dismutase (SOD), catalase (CAT). *Alexandria J. Med.* **9**, 001.
- Khaira K (2010) Counteract Free Radicals with Anti-Oxidants. *Sainstek* **2**(2), 183–187.
- Lestari A S P and Mulyono A (2011) Kidney Image Analysis for Identification of Picnosis and Necrosis Cells. *Jurnal Neutrino* **4**(1), 48–66.
- Loegito M (2018) Effect of Ethanol Extract of Mangosteen (*Garcinia mangostana* L.) Rind on Testicular Histopathological Structure, Spermatozoa Epidymis MDA and SOD Levels, and Spermatozoa Motility and Viability of Wistar Rats (*Rattus norvegicus*) Exposed to Cigarette Smoke. Universitas Brawijaya: Dissertation.
- Mescher A L (2011) *Basic Histology Junqueira: text & atlas*.
- Narmada I B, Sarasati A, Wicaksono S, Rezkita F, Wibawa K G P, Hayaza S and Nugraha A P (2020) Phytochemical screening, antioxidant activity, functional groups and chemical element characterization analysis of (-)-Epigallocatechin-3-Gallate (EGCG) in East Javanese Green Tea Methanolic extract: an experimental *in vitro* study. *Sys. Rev. Pharm.* **11**(5), 511–519.
- Nurhayati S, Kisananto T and Syaifudin M (2011) Superoxide Dismutase (SOD): What and How It Role in Radiotherapy. *Buletin Alara* **13**(2), 67–74.
- Nugraha A P, Narmada I B, Sitasari P I, Inayati F, Wira R and Triwardhani A (2020) High mobility group box 1 and heat shock protein-70 expression post (-)-epigallocatechin-3-gallate in East Java green tea methanolic extract administration during orthodontic tooth movement in wistar rats. *Pesqui Bras Odontopediatria Clín Integr.* **20**, e5347, 1–6
- Oktarian A, Budiman H and Aliza D (2017) Renal image analysis for identification of pycnotic and necrotic cells. *Jimvet* **1**(3), 316–323.
- Purnomo W and Bramantoro T (2018) *Introduction to Health Research Methodology* (1st ed.). Surabaya: Airlangga University Press.
- Saraswati R A, Maharani N and Utomo A W (2018) Effect of Mangosteen Skin Extract (*Garcinia mangostana* L.) on Rats Superoxide Dismutase (SOD) Enzyme Levels Induced by WV. *Jurnal Kedokteran Diponegoro.* **7**(2), 1511–1519.
- Setyawan E I, Dewantara I G and Putra I M D (2014) Optimization of the Mucoadhesive Patch Matrix Formula Betel Leaf Extract (Piper betle L.) using Menthol and PEG 400 as a Permeation Enhancer and Plasticizer. *Media Farmasi.* **11**(2), 120–132.
- Shantiningsih R R and Diba S F (2015) Effects of  $\beta$ -Carotene Mucoadhesive Gingival Patch Application Due to Panoramic Radiography Exposure. *Majalah Kedokteran Gigi Indonesia* **1**(2), 186–192.
- Shantiningsih R R and Diba S F (2018) Biological changes after dental panoramic exposure/: conventional versus digital. *Majalah Kedokteran Gigi Indonesia* **51**(1), 25–28.
- Shivhare U D, Suruse P B and Varvandkar S S (2014) Formulation and Evaluation of Buccal Patch Containing Aceclofenac. *J. Applied Pharmacy* **6**(1), 65–76.
- Simamura D and Fitri L E (2009) Antioxidants in malaria infection. *Jurnal Molluca Mesrisuldica* **2**(1), 47–56.
- Sudiana I K (2008) Molecular Pathobiology of Cancer. In : *Salemba Medika*.
- Tiensi ANS T R and Sulaiman T N S (2008) FBuccal Patch Formulation of Betel Leaf Essential Oil (*Piper betle* L.) with Variation in CMC-Na and Carbopol Levels as Mucoadhesive Polymers. **14**(1), 20–28.
- Toppo S (2012) Distribution of periapical and panoramic radiography on third molar mandibular. *Dentofasial.* **11**(2), 75–78.
- White S C and Pharoah M J (2014) *Oral Radiology Principles and Interpretation Edition 7* (7th ed.). St. Louis, Missouri: Elsevier Ltd.
- Yunus B and Bandu K (2019) Efek Radiasi Sinar-X pada Anak-anak. *Makassar Dental J.* **8**(2), 101.
- Yuslianti E R (2018) *Introduction to Free Radicals and Antioxidants* (1<sup>st</sup> ed). Yogyakarta.

# EFFECT OF MUCOADHESIVE GINGIVAL PATCH FROM MANGOSTEEN PERICARP (GARCINIA MANGOSTANA L.) EXTRACT ON THE SOD LEVELS AND THE NUMBER OF NECROTIC CELLS DUE TO PANORAMIC RADIOGRAPHY RADIATION IN ACUTE PHASE

## ORIGINALITY REPORT

9%

SIMILARITY INDEX

5%

INTERNET SOURCES

6%

PUBLICATIONS

0%

STUDENT PAPERS

## PRIMARY SOURCES

- 1** E N Indasari, A P W Marhendra, A W Wardhana. "Extract Bee Propolis (*Trigona* sp) for Preventive Increase Protease Activity and Defect of Trachea Histology in Rats (*Rattus norvegicus*) Exposed to Cigarette Smoke", IOP Conference Series: Earth and Environmental Science, 2019  
Publication 1%
- 2** [ppjp.ulm.ac.id](http://ppjp.ulm.ac.id)  
Internet Source 1%
- 3** M Najoan, F R Wolayan, F N Sompie. "Nutrient content and bioactive compounds characterization of Goroho banana (*Musa acumunafe* sp) stem meal fermented with *Trichoderma viride* as an alternative feed for broiler chickens", IOP Conference Series: Earth and Environmental Science, 2020  
Publication 1%



4	<a href="http://jurnal.pdgi.or.id">jurnal.pdgi.or.id</a> Internet Source	1 %
5	<a href="http://id.123dok.com">id.123dok.com</a> Internet Source	<1 %
6	<a href="http://www.um.edu.mt">www.um.edu.mt</a> Internet Source	<1 %
7	Subasini Uthirapath, Javed Ahamad, Omji Porwal, Muath S. Mohammed A, Esra T. Anwer. "GCMS Analysis and Hypolipidemic Activity of Dioscorea bulbifera (L) in High Fat Diet Induced Hypercholesterolemic Rats", Research Journal of Phytochemistry, 2021 Publication	<1 %
8	<a href="http://jurnal.ugm.ac.id">jurnal.ugm.ac.id</a> Internet Source	<1 %
9	<a href="http://media.neliti.com">media.neliti.com</a> Internet Source	<1 %
10	<a href="http://www.ejobios.org">www.ejobios.org</a> Internet Source	<1 %
11	Rajbir Bhatti, Jatinder Singh, Kunal Nepali, M. P. S. Ishar. "Possible Involvement of PPAR- $\gamma$ in the Anticonvulsant Effect of Aegle marmelos (L.) Correa", Neurochemical Research, 2013 Publication	<1 %
12	Sara Franceschelli, Mirko Pesce, Alessio Ferrone, Antonia Patruno et al. "A Novel	<1 %

Biological Role of  $\alpha$ -Mangostin in Modulating Inflammatory Response Through the Activation of SIRT-1 Signaling Pathway",  
Journal of Cellular Physiology, 2016

Publication

13

[faculty.uobasrah.edu.iq](http://faculty.uobasrah.edu.iq)

Internet Source

<1 %

14

[jofs.in](http://jofs.in)

Internet Source

<1 %

15

[ojs.sbp.pl](http://ojs.sbp.pl)

Internet Source

<1 %

16

"OS02: Tuberculosis 1 : Oral Sessions",  
Respirology, 2013.

Publication

<1 %

17

I Gusti Aju Wahyu Ardani, Bintiana Susanti,  
Irwadi Djaharu'ddin. "Force degradation trend  
of latex and nonlatex orthodontic elastics  
after 48 hours stretching", Clinical, Cosmetic  
and Investigational Dentistry, 2018

Publication

<1 %

18

Lai-xiang Lin, Xiang-yu Bo, Yuan-zhen Tan,  
Feng-xian Sun, Ming Song, Juan Zhao, Zhi-  
hong Ma, Mei Li, Kai-jun Zheng, Shu-mei Xu.  
"Feasibility of  $\beta$ -Sheet Breaker Peptide-H102  
Treatment for Alzheimer's Disease Based on  
 $\beta$ -Amyloid Hypothesis", PLoS ONE, 2014

Publication

<1 %

19

Zhaolu Feng, Yindong Wang, Xuefeng Bai. "Preparation of highly dispersed Pd/SBA-15 catalysts for dodecahydro-N-ethylcarbazole dehydrogenation reaction by ion exchange-glow discharge", Environmental Science and Pollution Research, 2022

Publication

---

&lt;1 %

20

[ejmcm.com](http://ejmcm.com)

Internet Source

---

&lt;1 %

21

Ezgi Tan, İbrahim Mizan Kahyaoğlu, Selcan Karakuş. "A sensitive and smartphone colorimetric assay for the detection of hydrogen peroxide based on antibacterial and antifungal matcha extract silver nanoparticles enriched with polyphenol", Polymer Bulletin, 2021

Publication

---

&lt;1 %

22

Sri Wigati Mardi Mulyani, Eha Renwi Astuti, Otty Ratna Wahyuni, Diah Savitri Ernawati, Nastiti Faradilla Ramadhani. "Xerostomia Therapy Due to Ionized Radiation Using Preconditioned Bone Marrow-Derived Mesenchymal Stem Cells", European Journal of Dentistry, 2019

Publication

---

&lt;1 %

23

Kresnoadi Utari, Ruslianda Diva Amelia, Laksono Harry. "The potential for induction of the expression of bone morphogenetic

&lt;1 %

protein-7 and alkaline phosphatase in  
postextraction tooth sockets using a  
combination of mangosteen peel extract and  
DFDBBX", Journal of Applied Pharmaceutical  
Science, 2022

Publication

---

---

Exclude quotes      Off

Exclude matches      Off

Exclude bibliography      On

# EFFECT OF MUCOADHESIVE GINGIVAL PATCH FROM MANGOSTEEN PERICARP (GARCINIA MANGOSTANA L.) EXTRACT ON THE SOD LEVELS AND THE NUMBER OF NECROTIC CELLS DUE TO PANORAMIC RADIOGRAPHY RADIATION IN ACUTE PHASE

---

GRADEMARK REPORT

---

FINAL GRADE

**/0**

GENERAL COMMENTS

**Instructor**

---

PAGE 1

---

PAGE 2

---

PAGE 3

---

PAGE 4

---

PAGE 5

---

PAGE 6

---