

Attenuation of hyperplasia in lung parenchymal and colonic epithelial cells in DMBA-induced cancer by administering *Andrographis paniculata* Nees extract using animal model

by Aniek Setiya Budiatin

Submission date: 25-Aug-2021 03:06PM (UTC+0800)

Submission ID: 1635659943

File name: Attenuation_of_hyperplasia_in_lung_-_Ilham.pdf (13.49M)

Word count: 4851

Character count: 26502

Aniek Setiya Budiati, Ilham Bagus Sagitaras, Ika Putri Nurhayati, Nismatun Khairah, Khoirotin Nisak, Imam Susilo and Junaidi Khotib*

Attenuation of hyperplasia in lung parenchymal and colonic epithelial cells in DMBA-induced cancer by administering *Andrographis paniculata* Nees extract using animal model

<https://doi.org/10.1515/jbcpp-2020-0440>

Received December 27, 2020; accepted March 7, 2021

Abstract

Objectives: This study was designed to evaluate the potential of *Andrographis paniculata* ethanolic extract to inhibit the increase in proliferation and induction of abnormal cell death.

Methods: The hyperplasia stage as an early stage of cancer development was induced by oral administration of 20 mg/Kg BW DMBA to SD rats twice a week for 5 weeks. There were five groups in this study include negative control, positive control, and treatment groups of DMBA induction followed by administration of *A. paniculata* ethanolic extract in doses equivalent to 10, 30 or 100 mg/Kg BW andrographolide once per day for 6 consecutive weeks. On the last day, rats were sacrificed, lung and colon tissues were collected. Histological examination by HE staining and immunohistochemistry using p53, telomerase, and caspase-3 antibodies were aimed at observing hyperplasia state in these tissues.

Results: DMBA induction to SD rats was able to produce hyperplasia in lung parenchymal and colon epithelial tissue. This can be showed by the increasing number of proliferated cells and as indicated by the number of brown-colored nuclei with sharper intensity. As well telomerase appears to be overexpressed strongly, while p53 and caspase-3 show low intensity. The administration of

A. paniculata extract for 6 weeks showed a decrease in the number of cells that actively proliferate, a decrease in telomerase activity, and an increase in caspase-3 levels which indicate cellular death activity.

Conclusions: *A. paniculata* ethanolic extract can inhibit the development of cancer at the hyperplasia stage by reducing telomerase activity and increasing apoptosis, marked by an increase of caspase-3 expressions.

Keywords: *Andrographis paniculata*; caspase-3; DMBA-induced cancer in rats; hyperplasia; telomerase.

Introduction

Cancer is a group of disorders characterized by uncontrolled cell growth, local tissue invasion, and distant metastases. Abnormal cell proliferation leads to hyperplasia, an increase in the number of cells in an organ, and can spread to other organs through the metastasis process where metastasis is the main cause of cancer death. The formation of cancer cells is believed as the result of physical, biological, or chemical carcinogen damage and alters genetic and epigenetic [1, 2].

According to the report, cancer is the second leading cause of death globally, accounting for an estimated 9.6 million deaths, or one in six deaths, in 2018. Lung and colorectal cancer are the most common type of cancer in both men and women, and the most common cause of cancer death. Its high mortality rate is due to the absence early diagnosis and the symptoms in the early stage, so it can be detected and treated after reaching an advanced stage [3]. For this reason, inhibition of abnormal cell growth at the hyperplasia stage becomes critical in reducing the rate of cancer development and the incidence of death.

The current paradigm of cancer research is focused on therapy that has a more selective target so as to minimize the toxic effects on normal cells. Therapies that selectively act directly on target proteins, growth receptors or small

*Corresponding author: Junaidi Khotib, Department of Clinical Pharmacy, Faculty of Pharmacy, Airlangga University, Jl Mulyorejo, Kampus C Unair, 60286, Surabaya, East Java, Indonesia, E-mail: junaidi-k@ff.unair.ac.id

Aniek Setiya Budiati, Ilham Bagus Sagitaras, Ika Putri Nurhayati, Nismatun Khairah and Khoirotin Nisak, Department of Clinical Pharmacy, Faculty of Pharmacy, Airlangga University, Surabaya, East Java, Indonesia

Imam Susilo, Department of Pathological Anatomy, Faculty of Medicine, Airlangga University, Surabaya, East Java, Indonesia

molecule inhibitors that have overexpression on cancer cells. With an understanding of the genetic changes and cell cycle in cancer cells compared to normal cells, it will encourage the discovery of new drugs that are selective in cancer cells. The expected effects of anticancer therapy include decreased cell proliferation and increased apoptosis.

The components that play a role in cell proliferation are telomere and telomerase. Telomeres are repeated DNA complexes (TTAGGG) that have an important role in the life of cancer cells. They are maintained by an enzyme called telomerase in the vast majority of tumors. The mechanisms underlying the maintenance of telomere length (TL) and telomerase expression are related to transcription, post-transcription, and epigenetic regulation, and an in-depth understanding of these mechanisms can provide new biomarkers and targets for early detection of disease, determination of disease prognosis, and development of therapy [4].

Inhibition of telomerase activity can induce apoptosis, which is programmed cell death that genetically regulates the development and homeostasis of an organism. Apoptotic activation occurs in two pathways, intrinsic and extrinsic, each of which can activate the effector caspases, caspase-3 and 7. If the effector caspase is activated, the cell will experience apoptosis [5]. In cancer patients, where cell proliferation cannot be controlled, apoptosis is important as a mechanism to control cancer cell growth. Drugs that inhibit telomerase activity and induce apoptosis can be used as an effective and selective alternative to colon cancer therapy so as to minimize side effects.

Cancer treatment depends on the stage of the cancer. In the early stages (I, II, III) cancer can be cured, but in the late stage (IV) treatment is aimed at palliative therapy to reduce symptoms, prevent complications, and prolong life [1]. Cancer is used to be treated with surgery, radiation, and systemic anticancer agent where the choice of treatment is based on the type and stage of cancer. Systemic anticancer agents such as chemotherapy, targeted therapy, and immunotherapy, aimed to kill cancer cells and minimizing side effects on healthy cells [1]. Therefore, it is necessary to develop new anticancer agents that can increase the effectiveness and tolerance.

One of the plants that have been suspected of having an anticancer effect is *Andrographis paniculata* Ness, with andrographolide as a chemical substance that is responsible for its anticancer activity. *A. paniculata* extracts and their major diterpenoid component has been reported that able to suppress cell proliferation, induce cell cycle arrest, and induce cell apoptosis of cancer cells [6]. Combination of andrographolide and fluorouracil (5-FU) is used for

treatment 5-FU resistance in colorectal cancer. Andrographolide in combination with fluorouracil (5-FU) is used for the treatment of 5-FU resistance in colorectal cancer. Andrographolide can induce apoptotic cell death so that 5-FU sensitivity in cancer cells increases [7]. *A. paniculata* ethanolic extract played a role in the intervention of cancer formation. Administration of *A. paniculata* extract in colon cancer can reduce the number of aberrant cancer cells and frequencies of aberration per cell [8]. *A. paniculata* extract can reduce telomerase activity and increase apoptosis by activating the PI3K/AKT/AP-1 signaling pathway [9]. Therefore, this study was designed to evaluate the potential of andrographolide in *A. paniculata* ethanolic extract to inhibit the increase in proliferation and induction of abnormal cell death.

Materials and methods

A. paniculata Ness ethanolic extract obtained from the Pharmacognosy and Phytochemical Laboratory of Faculty of Pharmacy Airlangga University. The extract was suspended with CMC Na 0.1% (w/v) in aquadest. The preparations were made in three different doses that equivalent to 10, 30 and 100 mg andrographolide/kgBW. Andrographolide content was determined using Thin Layer Chromatography (TLC) and Densitometer Shimadzu CS-930. Mixture of chloroform and methanol (9:1) was used as an eluent in TLC method.

Female Sprague Dawley (SD) rats, 7–10 weeks of age, were acquired from Integrated Research and Testing Laboratory of Gadjah Mada University. In this study, SD rats were divided into five groups. Group 1 (negative control) was fed orally with Oleum Maydis twice a week for 5 weeks (at induction phase) and CMC-Na everyday (at treatment phase). Group 2 (positive control) was induced by oral administration of 20 mg/Kg BW DMBA to SD rats twice a week for 5 weeks (induction phase) and CMC-Na everyday (at treatment phase). Group 3, 4, and 5 (treatment groups), were induced by DMBA and followed with administration of doses that equivalent to 10, 30 or 100 mg/Kg BW andrographolide in ethanolic extract once per day for 6 consecutive weeks. On the last day, rats were sacrificed, lung and colon tissues were collected. Doses of 10, 30 or 100 mg/kg BW andrographolide was adopted as low, medium, and high dosage that altered the expression of genes in cellular compromise, cell cycle, and "DNA recombination, replication, and repair" [10].

Telomerase and caspase-3 were detected using affinity purified rabbit anti-rat caspase-3 antibody (Bioworld Technology Inc.) and rabbit anti-rat telomerase antibody (Bioworld Technology Inc.). Tissue sections were rehydrated using alcohol solution with a decrease in concentration every 2 min (99, 99, 90, 80, 70%) and subjected to specific antigen retrieval treatment. Endogenous peroxidase activity was blocked with H₂O₂ 0.3%/methanol. Background was blocked using Block Serum Free X 0909, dropped in "marking pen immunologic" area at room temperature for 5 min, then washed with TRIS buffer/Tween 20 for 5 min and swap the tissue around "marking pen immunologic" area.

For immunohistochemistry (IHC), Primary antibodies were dropped into the "Marking pen immunologic" area and then incubated in

closed magnetic immunostaining at room temperature for 1 h and incubate 4 °C overnight with the tissue, washed with TRIS buffer/Tween 20 for 5 min and swap the tissue around "marking pen immunologic" area. Secondary antibodies (Biotin-labeled Link) was dropped on "marking pen immunologic" area at room temperature for 10 min, washed then dropped HRP (Streptavidin Peroxidase Conjugate) and incubate at room temperature for 10 min. Washed then dropped DAB at room temperature for 5–10 min and washed with water for 5 min. Then, tissue sections were counterstained with hematoxylin and dehydrated. The results of immunohistochemistry staining were analyzed qualitatively on the expression of telomerase and caspase-3 proteins by observing using a 1000x magnification light microscope.

Results

Andrographolide content in *A. paniculata* ethanolic extract had been shown in Table 1. The result show that *A. paniculata* ethanolic extract that used in this research contain 11.65% w/v andrographolide.

Administration of *A. paniculata* extract to SD rats that had been induced by DMBA was able to improve the lung structure of rats as shown in Figure 1. In this figure, it has

shown the histology of the lungs in rats that have been given *A. paniculata* extract with doses equivalent to 10, 30 and 100 mg/kg BW andrographolide. Compared with the histology of the lungs in rats that were only given DMBA (A), the alveolar structure began to appear with narrower space between the alveoli and the wider alveolar cavity on the lung histology after administration of *A. paniculata* extracts (B), (C), and (D).

From Figure 1, it can be seen that giving the extract with andrographolide dose of 10 mg/kg BW suppresses the rate of cell proliferation not as much as the extract with andrographolide dose of 30 and 100 mg/kg BW. This can be seen from the number of cells that are still quite large in the alveolar space compared to the other two doses. Meanwhile, the extract with andrographolide doses of 30 and 100 mg/kg BW resulted in almost the same histological picture of lung structure improvement.

The ability of *A. paniculata* extract in suppressing the rate of cell proliferation is associated with decreased telomerase activity in cells, shown in Figure 2. From the results of observations of telomerase using a light microscope qualitatively, it was found that *A. paniculata* extract could

Table 1: Andrographolide content in *A. paniculata* ethanolic extract.

Samples	Total andrographolide applied in TLC, 2 µL	Total andrographolide measured, 5.0 mL	Total weighed sample	Andrographolide content in sample
1	922.20 ng	2.305 mg	20.4 mg	11.32%
2	973.74 ng	2.434 mg	20.3 mg	11.99%
Mean andrographolide concentration in sample				11.65%

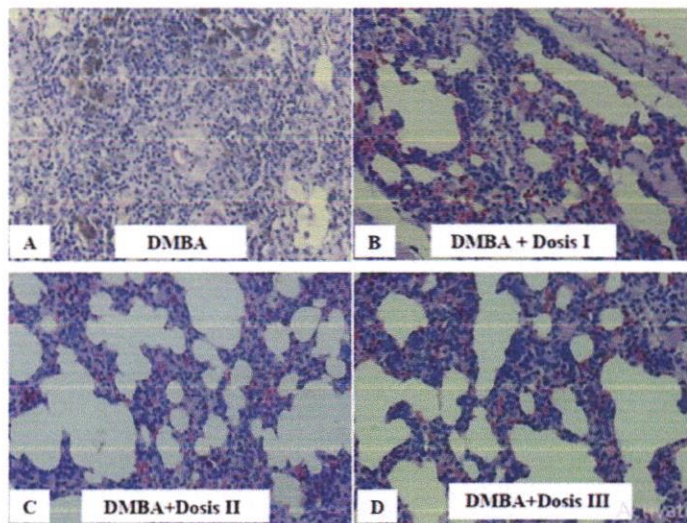


Figure 1: Histopathology of SD rats lung given DMBA (A) and given *A. paniculata* extract with doses equivalent to 10 mg/kg BW (B), 30 mg/kg BW (C), and 100 mg/kg BW (D) andrographolide using Hematoxylin-Eosin staining at 400x Magnification.

reduce the expression of telomerase protein. The decrease in telomerase protein expression at the extract with dose of andrographolide 10 mg/kg BW was lower than the other doses (Figure 2B), it appears that the number of cells that absorb brown is still quite a lot. Whereas at the extract with andrographolide dose of 100 mg/kg BW (Figure 2D), it appears that number of cells that absorb the brown color less than the other doses. However, from these observations it was not certain that the dose that was able to suppress telomerase activity was the best among the three doses given.

In observing caspase-3 activity, the results showed that there was an increase in the expression of caspase-3 after giving treatment as seen in Figure 3 where cells absorbed more brown in the treatment group compared to the DMBA group. The extract with andrographolide dose of 10 mg/kg BW showed the lowest caspase-3 expression among other doses.

Changes in colonic tissue morphology after treatment with *A. paniculata* extract can be observed in Figure 4. When compared with DMBA group (Figure A), where the epithelial cells appear thicker due to increased proliferation and hyperchromatic nuclei, the three treatment groups showed improvement in decreasing cell proliferation. In treatment group I extract with a dose of andrographolide 10 mg/kg BW (Figure 4B) showed that the enlargement of the nucleus was reduced, but the epithelial cells that proliferated and showed hyperchromatic nuclei were still present. Treatment group II extract with a dose of andrographolide 30 mg/kg BW (Figure C) showed a more pronounced decrease in proliferation and cell boundaries.

Treatment group III extract with a dose of andrographolide 100 mg/kg BW (Figure D) also showed a decrease in proliferation, but the difference with treatment group II was not clear.

Telomerase expression after treatment with *A. paniculata* extract in the three treatment groups can be observed in Figure 5. When compared with DMBA group, it can be clearly observed that the telomerase expression in the treatment group decreased. This can be seen from the reduced number of cells whose nuclei are brown. The color intensity in the treatment group appeared sharper and varied. In treatment group I (Figure 5B), cells expressing nuclear telomerase appear larger and elongated, indicating that the cell is in a mitotic state. The difference in telomerase expression between treatment groups could not be known because scoring could not be done due to cutting the tissue that was too thick. From immunohistochemistry, it is known that treatment using *A. paniculata* extract can reduce the proliferation of colonic epithelial cells exposed to DMBA which is characterized by a decrease in telomerase expression.

The expression of caspase-3 in the group that had received *A. paniculata* extract treatment can be seen in Figure 6. The difference in the immunohistochemistry between DMBA group and the treatment group that received *A. paniculata* extract treatment was that the number of caspase-3 expressions was more often found in the treatment group. When compared with the test control group (Figure 6A), the color intensity of epithelial cells expressing caspase-3 in treatment groups I (Figure 6B) and II (Figure 6C) was sharper. In the treatment group III

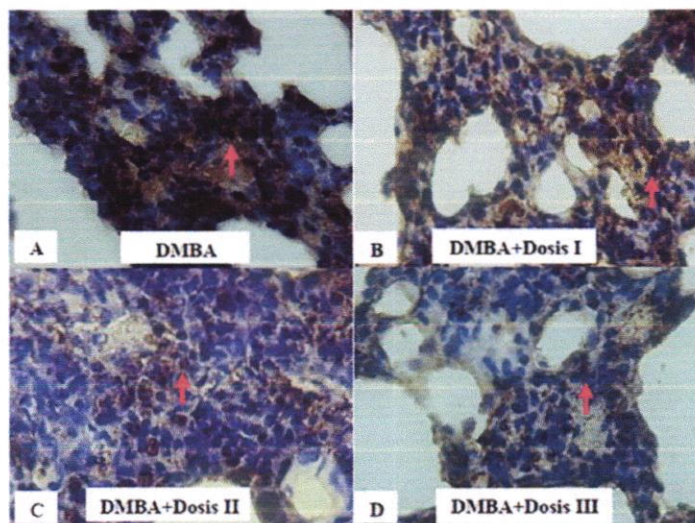


Figure 2: Immunohistochemistry staining using telomerase antibodies in SD rats lung given DMBA (A) and given *A. paniculata* extract with doses equivalent to 10 mg/kg BW (B), 30 mg/kg BW (C), and 100 mg/kg BW (D) andrographolide using Hematoxylin-Eosin staining at 400x magnification. Red arrows indicate cells that express telomerase.

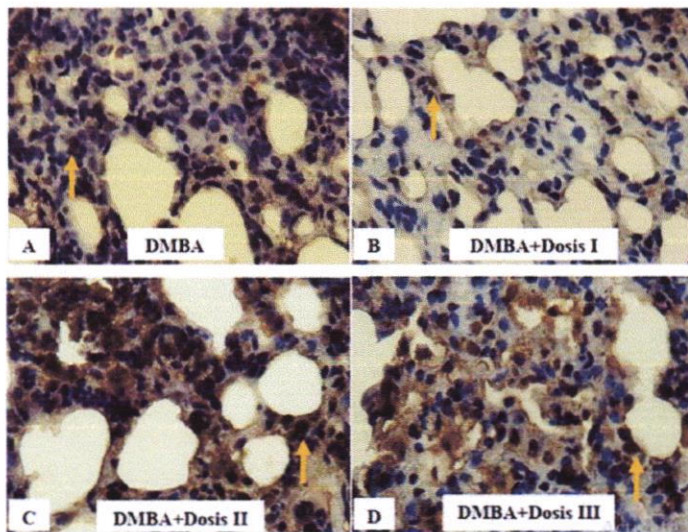


Figure 3: Immunohistochemistry staining using caspase-3 antibodies in SD rats lung given DMBA (A) and given *A. paniculata* extract with doses equivalent to 10 mg/kg BW (B), 30 mg/kg BW (C), and 100 mg/kg BW (D) andrographolide using Hematoxylin-Eosin staining at 400x magnification. Yellow arrows indicate cells that express caspase-3.

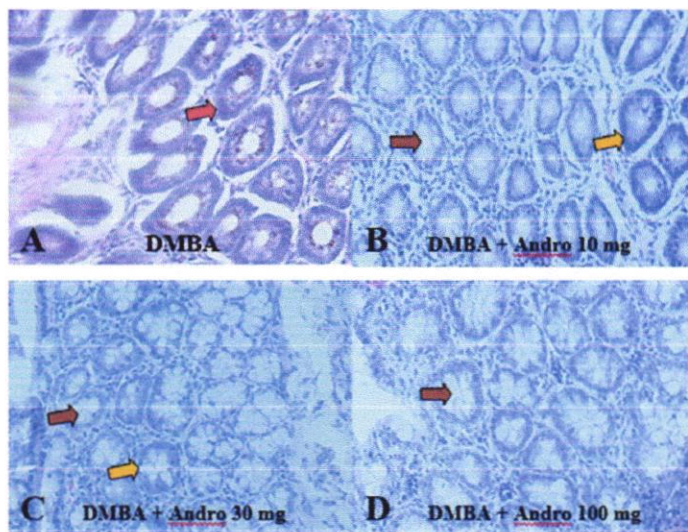


Figure 4: Histopathology of SD rats colon given DMBA (A) and given *A. paniculata* extract with doses equivalent to 10 mg/kg BW (B), 30 mg/kg BW (C), and 100 mg/kg BW (D) andrographolide Hematoxylin-Eosin staining at 400x magnification. Red arrow indicates epithelial cells without treatment, yellow arrow indicates epithelial cells after treatment, brown color indicates goblet cells.

(Figure 6D), the apoptosis also increased with a more diverse color intensity.

Discussion

Lung and colon cancer is one of the leading causes of cancer death. Several studies on the causes of this cancer state that the development of these cancers is related to dietary factors, environment, lifestyle, and comorbid

conditions as well as genetic factors due to genetic mutations and physical weakness [1]. Experimental models showing complex cancer-causing interaction equations are needed to test various mechanisms and determine the carcinogenic potential of a chemical compound. In this study, the effect of telomerase and caspase-3 expression on lung and colon cancer that given *A. paniculata* extract was carried out using experimental animals Sprague-Dawley rats with induction of 7,12-Dimethylbenz(a)anthracene (DMBA).

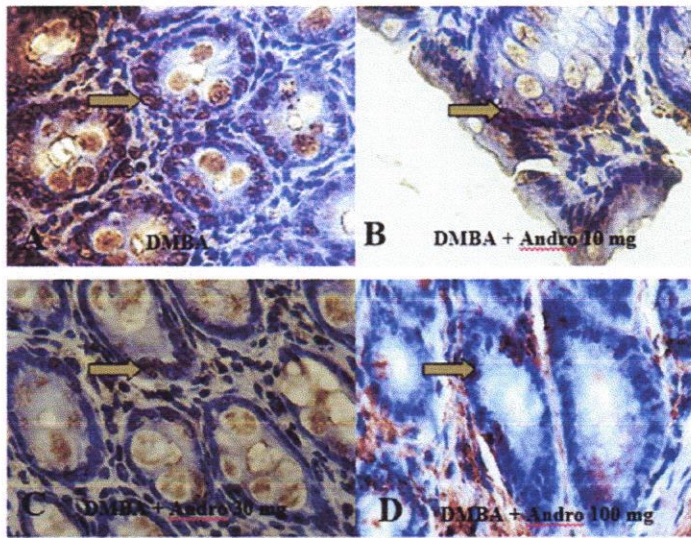


Figure 5: Immunohistochemistry staining using telomerase antibodies in SD rats colon given DMBA (A) and given *A. paniculata* extract with doses equivalent to 10 mg/kg BW (B), 30 mg/kg BW (C), and 100 mg/kg BW (D) andrographolide using Hematoxylin-Eosin staining at 400x magnification. Gray arrows indicate cells that express telomerase.

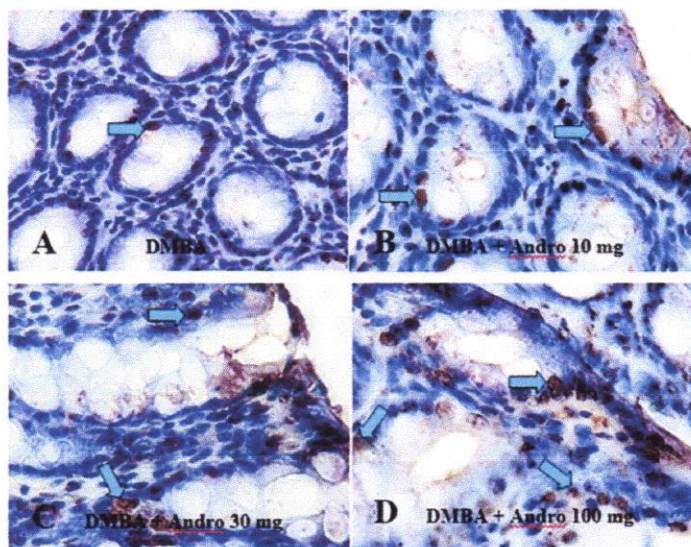


Figure 6: Immunohistochemistry staining using caspase-3 antibodies in SD rats colon given DMBA (A) and given *A. paniculata* extract with doses equivalent to 10 mg/kg BW (B), 30 mg/kg BW (C), and 100 mg/kg BW (D) andrographolide using Hematoxylin-Eosin staining at 400x magnification. Blue arrows indicates cells that express caspase-3.

The use of experimental animals in cancer research is supported by the fact that experimental animals have in common with humans in terms of response to exposure to carcinogens. Some of the protooncogenes and gene suppressor tumors in humans are homologous to rats. The difference is that in rats, fewer genetic changes are required [11]. Long-term studies on rat models prove that this model is useful for knowing the stages of initiation, promotion, and progress of carcinogenesis.

DMBA is a polycyclic aromatic hydrocarbon (PAH) carcinogen. Chronic exposure to PAH class carcinogens can lead to cancer, especially in cells that have a fast replicative cycle, for example bone marrow, skin, and lungs. Previous research conducted by Harris et al. [12] stated that the induction of benzo (a) pyrene can cause adenoma in the colon. In other studies, it is demonstrated that oral administration of DMBA can induce lung cancer [13].

Evaluation of the effect of *A. paniculata* extract on lung and colon carcinogenesis in rats was carried out by histological observation using Immunohistochemistry. Cell proliferation can be determined by observing protein expression telomerase in cancer [14]. In addition, an observation of the expression of caspase-3 which was an effector caspase in the apoptosis process with immunohistochemistry staining using caspase-3 antibodies. In lung carcinogenesis, pulmonary septal interalveolar cells of rats given DMBA, whereas in normal rats, there was no expression of telomerase. In normal cells, the expression of telomerase is very low due to the activation of checkpoints in the cell cycle which causes telomere shortening. The shortening of the telomere causes the cell to enter the senescence phase, which was the phase where the cell does not divide anymore [2].

Observations of caspase-3 activity were also carried out to determine the presence of apoptosis in cells. From the observations, it was found that no caspase-3 expression was seen in normal cells, while cells that had been exposed to DMBA appeared to express caspase-3. An increase in caspase-3 expression indicated apoptosis due to DMBA administration which could cause DNA damage that triggered apoptosis.

Efforts that can be made to inhibit carcinogenic processes are by suppressing telomerase activity so as to suppress cell proliferation and induce apoptosis. *A. paniculata* is a plant known to have anticancer properties. Therefore, the observation of the effect of *A. paniculata* extract on proliferation and apoptosis in lung cells of SD rats that had been induced by DMBA was conducted. To determine the effect of *A. paniculata* extract on rats that have been induced by DMBA, histological microscopic observation using immunohistochemistry was carried out using telomerase and caspase-3 antibodies.

Observation of telomerase activity was carried out qualitatively by looking at the cells that expressed telomerase, cells whose nuclei were brown due to the application of chromogen DAB on immunohistochemistry staining. Observations were made using a light microscope with 400x and 1000x magnifications. The decrease in telomerase protein expression was carried out by observing interalveolar septal cells in several fields of view and then compared between treatment groups. From these observations, it was found that there was a decrease in telomerase expression in rat lung cells after giving *A. paniculata* extract. Meanwhile, on the caspase-3 activity examination to determine the presence of apoptosis, the results showed that there was an increase in caspase-3 expression in the lung cells of rats given *A. paniculata* extract which was shown in brown on the cells. However, from the qualitative analysis conducted, it was not known

the optimal dose that could significantly suppress telomerase activity and induce apoptosis.

In colon carcinogenesis, the difference in cell morphology between the DMBA-given group and the treatment group (*A. paniculata* extract) can be seen in Figure 4. With an increase in the dose of *A. paniculata* extract given, it was seen that there was an improvement in the form of decreased epithelial cell proliferation and goblet cell formation began to clear. Although hyperchromatic nuclei were still observed in the treatment group, its intensity was not as big as the control group. *A. paniculata* extract plays a role in reducing the initiation and promotion of carcinogens against colon cancer but does not inhibit its progress. This mechanism is often obtained in the anticancer of plant extracts [15].

Furthermore, an immunohistochemistry examination was carried out to determine how changes in cell proliferation and apoptosis after DMBA exposure and treatment with *A. paniculata* extract. In this study, an increase in cell proliferation due to chronic DMBA exposure to rats colonic epithelial cells was observed with an increase in telomerase enzyme expression. Telomerase acts as a major positive regulator of telomere length and can bind to telomeres which facilitate the elongation of chromosomes and prevent their shortening. Progressive shortening occurs during cell division so that increased telomerase activity can be found in cells that are actively proliferating. Cells that express telomerase positive will appear brown in the nucleus region. The immunohistochemistry features using telomerase antibodies can be seen in Figure 5.

In Figure 5, it is clear that the expression of the telomerase in the DMBA-given group is greater than that in the normal control group. This suggests that exposure to DMBA can increase the proliferation of colonic epithelial cells. The DNA adducts binding between DMBA metabolites and DNA causes mutations. In the treatment group that received *A. paniculata* extract treatment equivalent to 10, 30, and 100 mg andrographolide/kg BW of rats showed a decrease in telomerase enzyme expression. This shows that *A. paniculata* extract can reduce the expression of the telomerase enzyme so that it can limit uncontrolled cell growth as the beginning of carcinogenesis.

In addition to reducing cell proliferation, apoptosis is indispensable to prevent carcinogenesis. Apoptosis as an important mechanism in controlling cancer cell growth was observed in this study using immunohistochemistry examination with caspase-3 antibodies. In cancer conditions, the apoptosis process cannot run properly, so that cell growth is not controlled. Cells that are positive to express caspase-3 will show a brown color in the cytoplasm and over time it can be observed in the nucleus [16].

Immunohistochemistry results of colonic tissue with caspase-3 antibodies can be seen in Figure 6. Both treatment groups I, II, and III, colonic epithelial cells express caspase-3. Observation of the color intensity shows that the intensity in the treatment group is greater and clearer than the control test. The number of cells expressing caspase-3 in the treatment group was also higher.

The use of caspase-3 antibodies to detect apoptosis is a sensitive, accurate, and independent method of DNA fragmentation [16]. Previously, it was known that treatment with *A. paniculata* extract could reduce the activity of the telomerase enzyme. Inhibition of telomerase activity can induce apoptosis, namely programmed cell death which genetically regulates the development and homeostasis of an organism [5]. Because hyperplasia is an early stage of cancer development, it is hoped that *A. paniculata* extract can be used as an alternative to more effective colon cancer therapy.

Conclusions

From this study, it can be seen that *A. paniculata* extract is able to suppress telomerase activity and increase the occurrence of apoptosis, this can be used as an early stage in developing the use of *A. paniculata* as an anticancer. Moreover, *A. paniculata* extract has the ability to inhibit carcinogenesis in colonic epithelial cells due to chronic DMBA exposure through inhibition of telomerase enzyme activity, thereby reducing proliferation and inducing apoptosis which is marked by an increase in caspase-3.

Acknowledgments: We thank our colleagues from the Department of Clinical Pharmacy, Faculty of Pharmacy, University of Airlangga for all supporting during research.

Research funding: This research was funded by the Ministry of Research, Technology, and Higher Education of Republic of Indonesian through a scheme of Mandate Research Grant 2019–2020.

Author contributions: All authors have accepted responsibility for the entire content of this manuscript and approved its submission.

Competing interests: Authors state no conflict of interest.

Ethical approval: All experiments were conducted at the Animal Research Laboratory of the Faculty of Pharmacy University of Airlangga, Surabaya, Indonesia in accordance with the Guideline for the Care and Use of Laboratory Animals issued by the National Institutes of Health revised in 1985. The Ethic Committee of Faculty of

Veterinary Medicine Universitas Airlangga, Surabaya, Indonesia, approved the study protocol.

References

1. Cordes LM, Shord SS. Cancer treatment and chemotherapy. In: Dipiro JT, Yee BG, Posey LM, Haines ST, Nolin TD, Ellingrod V, editors. *Pharmacotherapy a pathophysiologic approach*. New York: Mc Graw Hill; 2020.
2. Kumar V, Abbas AK, Aster JC. *Robbins basic pathology*, 10th ed. Philadelphia: Elsevier; 2018.
3. World Health Organization. Latest global cancer data: Cancer burden rises to 18.1 million new cases and 9.6 million cancer deaths in 2018. Geneva: WHO; 2018.
4. Jafri MA, Ansari SA, Alqahtani MH, Shay JW. Roles of telomeres and telomerase in cancer, and advances in telomerase-targeted therapies. *Genome Med* 2016;8:1–18.
5. Artandi SE, DePinho RA. Telomeres and telomerase in cancer. *Carcinogenesis* 2010;31:9–18.
6. Dai Y, Chen SR, Chai L, Zhao J, Wang Y, Wang Y. Overview of pharmacological activities of *Andrographis paniculata* and its major compound andrographolide. *Crit Rev Food Sci Nutr* 2019; 59(1 Suppl):S17–29.
7. Wang W, Guo W, Li L, Fu Z, Liu W, Gao J, et al. Andrographolide reversed 5-FU resistance in human colorectal cancer by elevating BAX expression. *Biochem Pharmacol* 2016;121: 8–17.
8. Ahmad MS, Ahmad S, Arshad M, Afzal M. *Andrographis paniculata* a Miracle Herbs for cancer treatment: in vivo and in vitro studies against Aflatoxin B1 Toxicity. *Egypt J Med Hum Genet* 2014;15:163–71.
9. Duan MX, Zhou H, Wu QQ, Liu C, Xiao Y, Deng W, et al. Andrographolide protects against HG-induced inflammation, apoptosis, migration, and impairment of angiogenesis via PI3K/AKT-eNOS signalling in HUVECs. *Mediat Inflamm* 2019:1–15. <https://doi.org/10.1155/2019/6168340>.
10. Forestier-Román IS, López-Rivas A, Sánchez-Vázquez MM, Rohena-Rivera K, Nieves-Burgos G, Ortiz-Zuazaga H, et al. Andrographolide induces DNA damage in prostate cancer cells. *Oncotarget* 2019;10:1085–101.
11. Anisimov VN, Ukraintseva SV, Yashin AI. Cancer in rodent: does it tell us about cancer in human. *Nature* 2005;5:807–17.
12. Harris D, Washington MK, Hood DB, Robert LJ II, Ramesh A. Dietary fat-induced development of colon neoplasia in ApcMin mice exposed to benzo(a)pyrene. *Toxicol Pathol* 2009;37: 938–46.
13. Mun'im A, Andrajati R, Susilowati S. Uji Hambatan Tumorigenesis Sari Buah Merah (*Pandanus Conoideus* LAM.) terhadap Tiuks Putih Betina yang Diinduksi 7,12 Dimetilbenz(a)antrasen (DMBA). *Maj Ilm Kefarmasian* 2006;3:153–61.
14. Meyerson M. Role of telomerase in normal and cancer cell. *J Clin Oncol* 2000;18:2626–34.
15. Airlley R. *Cancer chemotherapy*. UK: John Wiley & Sons Ltd.; 2009.
16. Cor A, Pizem J, Gale N. Immunohistochemical analysis of pro- and active- caspase-3 in laryngeal squamous cell carcinoma. *Vischows Arch* 2004;444:439–46.

Attenuation of hyperplasia in lung parenchymal and colonic epithelial cells in DMBA-induced cancer by administering *Andrographis paniculata* Nees extract using animal model

ORIGINALITY REPORT

8%

SIMILARITY INDEX

5%

INTERNET SOURCES

7%

PUBLICATIONS

0%

STUDENT PAPERS

PRIMARY SOURCES

- 1 Yan Dai, Shao-Ru Chen, Ling Chai, Jing Zhao, Yitao Wang, Ying Wang. " Overview of Pharmacological Activities of and its Major Compound Andrographolide ", Critical Reviews in Food Science and Nutrition, 2018
Publication 1%
- 2 www.tehrantimes.com
Internet Source 1%
- 3 "Telomere length regulation through epidermal growth factor receptor signaling in cancer", Genes & Cancer, 2017
Publication 1%
- 4 genomemedicine.biomedcentral.com
Internet Source 1%
- 5 worldwidescience.org
Internet Source <1%
- 6 Shin-ichi Tsukumo. "Requirement of cooperative functions of two repeated death <1%

effector domains in caspase-8 and in MC159 for induction and inhibition of apoptosis, respectively", *Genes to Cells*, 9/1999

Publication

7 Shiva Kumar Goud Gadila, Gorazd Rosoklija, Andrew J. Dwork, Brian A. Fallon, Monica E. Embers. "Detecting *Borrelia Spirochetes*: A Case Study With Validation Among Autopsy Specimens", *Frontiers in Neurology*, 2021

Publication

8 Giulia Greco, Eleonora Turrini, Massimo Tacchini, Immacolata Maresca, Carmela Fimognari. "The Alcoholic Bark Extract of *Terminalia Arjuna* Exhibits Cytotoxic and Cytostatic Activity on Jurkat Leukemia Cells", *Venoms and Toxins*, 2021

Publication

9 hyper.ahajournals.org

Internet Source

10 pesquisa.bvsalud.org

Internet Source

11 www.frontiersin.org

Internet Source

12 www.oncotarget.com

Internet Source

13 Fahri Sahin. "Gossypol exerts its cytotoxic effect on HL-60 leukemic cell line via

decreasing activity of protein phosphatase 2A and interacting with human telomerase reverse transcriptase activity", Hematology, 06/01/2010

Publication

14

Nagendra Kumar Chandrawanshi, Shekhar Verma. "chapter 18 Recent Research and

Development in Stem Cell Therapy for Cancer Treatment", IGI Global, 2021

Publication

www.scribd.com

Internet Source

15

>1%

www.spandidos-publications.com

Internet Source

16

>1%

Alyssa A. Sprouse. "Pharmaceutical regulation of telomerase and its clinical potential",

Journal of Cellular and Molecular Medicine,

01/2012

Publication

17

>1%

Panagiota A. Sotiropoulou, Sonia A. Perez, Michael Papamichail. "Chapter 17 Clinical

Grade Expansion of Human Bone Marrow

Mesenchymal Stem Cells", Springer Science

and Business Media LLC, 2007

Publication

18

>1%

Shoji Fukushima, Samuel M. Cohen, Gerhard Eisenbrand, Nigel J. Gooderham et al. "FEMA

19

>1%

GRAS assessment of natural flavor complexes: Lavender, Guaiac Coriander-derived and related flavoring ingredients", Food and Chemical Toxicology, 2020

Publication

20

T. K. Lim. "Edible Medicinal And Non-Medicinal Plants", Springer Science and Business Media LLC, 2012

Publication

<1 %

21

Xianjun Cai, Minhong Shen, Xishi Liu, Jichan Nie. "The Possible Role of Eukaryotic Translation Initiation Factor 3 Subunit e (eIF3e) in the Epithelial-Mesenchymal Transition in Adenomyosis", Reproductive Sciences, 2018

Publication

<1 %

22

jmhg.springeropen.com

Internet Source

<1 %

23

www.hindawi.com

Internet Source

<1 %

24

www.iarc.fr

Internet Source

<1 %

25

www.ijddr.in

Internet Source

<1 %

26

Ingrid S. Forestier-Román, Andrés López-Rivas, María M. Sánchez-Vázquez, Krizia Rohena-Rivera et al. "Andrographolide

<1 %

induces DNA damage in prostate cancer cells", Oncotarget, 2019

Publication

27

Li, Tao, Feng Gao, and Xi-Peng Zhang. "miR-203 enhances chemosensitivity to 5-fluorouracil by targeting thymidylate synthase in colorectal cancer", Oncology Reports, 2014.

Publication

<1 %

Exclude quotes Off

Exclude matches Off

Exclude bibliography On

Attenuation of hyperplasia in lung parenchymal and colonic epithelial cells in DMBA-induced cancer by administering *Andrographis paniculata* Nees extract using animal model

GRADEMARK REPORT

FINAL GRADE

/0

GENERAL COMMENTS

Instructor

PAGE 1

PAGE 2

PAGE 3

PAGE 4

PAGE 5

PAGE 6

PAGE 7

PAGE 8
