

ISSN: 0976-237X

CCD

CONTEMPORARY CLINICAL DENTISTRY

www.contempclindent.org

Volume 10 / Issue 3 / July - September 2019

Editorial Board

Editor-in Chief

Prof. G .M. Sogi

Maharishi Markandeshwar (Deemed to be University),
Mullana, Ambala (HR)
INDIA-133207
Email- chiefeditor.ccdjournal@mmumullana.org

Associate Editors

Prof. Sivakumar Nuvvula

Narayana Dental College and Hospital
Nellore, Andhra Pradesh
INDIA -524003

Dr. Monika Gupta

Maharishi Markandeshwar (Deemed to be University),
Mullana, Ambala (HR)
INDIA-133207

Dr Deepak Gupta

Maharishi Markandeshwar (Deemed to be University),
Mullana, Ambala (HR)
INDIA-133207

Assistant Editors

Dr. Prachi Goyal

Maharishi Markandeshwar (Deemed to be University),
Mullana, Ambala (HR)
INDIA-133207

Dr Jasneet Sudan

Maharishi Markandeshwar (Deemed to be University),
Mullana, Ambala (HR)
INDIA-133207

International Advisory Editorial Board

Dr. Raman Bedi, Head of Centre for International Child Oral Health, King's College, London, United Kingdom

Dr. Prathip Phantumvanit, Dean Emeritus, Faculty of Dentistry, Thammasat University, Pathum Thailand

Dr. Monty Duggal, Professor of Paediatric Dentistry, National University of Singapore, Singapore

Dr. Simrit Malhi, Head, Department of Paediatric Dentistry and Orthodontics, Westmead Hospital, Sydney, Australia

Dr. Paul Mullasseril, Chair of Restorative dentistry at Oklahoma University. USA

Dr. Richard Welbury, Professor / Professor / Honorary Consultant in Paediatric Dentistry., University of Central Lancashire, UK

Dr. Lars Andersson, Chairman of Department of Surgical Sciences, Faculty of Dentistry, Kuwait University, Kuwait

Dr. Arthur M Kemoli, Chairman, Paediatric Dentistry and Orthodontics, University of Nairobi, Kenya

Prof Wim van Palenstein Helderman WHO Collaborating Centre, Nijmegen, The Netherlands

Dr. Richard Widmar, Head of Paediatric Dentistry, Sydney Children's Hospital Network, Sydney, Australia

Dr. Alessandro Cavalcanti, Chair of the Post Graduate Program in Public Health at the State University of Paraiba, Brazil

Dr. Duygu Ilhan, member Education committee of Istanbul Dental Chamber, Turkey

Dr. David M. Okuji, Associate Director-Extramural Residency Training, NYU Lutheran Medical Center of Dental Medicine, New York USA

Dr. Chad Gehani, trustee from the Second District (New York State) American Dental Association USA

Dr. Stephen J Moss, President at Health Education Enterprises, Greater New York City Area

Dr. Denis Bourgeois, Claude Bernard University Lyon, France

Prof. Dr. Drg.Tri Erri Astoeti, MKes, Dean Faculty of Dentistry Trisakti University, Jakarta, Indonesia

Prof. Dr. Armelia Sari Widyarman, Head Department of Oral Microbiology, Faculty of Dentistry, Trisakti University, Jakarta, Indonesia


Feedback

[Subscribe](#)

[Advertise](#)

 [Submit article](#)

 [Most popular articles](#)

 [Join as Reviewer](#)

 [Email alerts](#)

 [Recommend this journal to your library or friends](#)

Dr. Wen Sheng Rong, Professor, Department of Preventive Dentistry, Peking University, School & Hospital of Stomatology, China

Dr. Vineet K Dhar, Associate professor and interim-chair of Orthodontics and Paediatric Dentistry University of Maryland, USA

Dr. How Kim Chuan, Managing Director and Chief Consultant at Imperial Dental Specialist Centre, Malaysia

Dr Ali Farahani, Craniofacial and Special Care Orthodontics (Children's Hospital Los Angeles, USC)

Dr. Maryam Khoroushi, Isfahan University of Medical Sciences Isfahan, Iran

Dr. Soni Stephen, Director and Principal Specialist Southside Paediatric Dentistry, Miranda, Sydney, Australia

Dr. Archana Viswanath, Department of Oral and Maxillofacial Surgery, Tufts University, USA

Dr. Vajihesadat Mortazavi, Professor of Restorative Dentistry, Isfahan University of Medical Sciences, Iran

Dr. Prasad Amaratunga, Professor, Faculty of Dental Sciences and Hospital, University of Peradeniya, Sri Lanka.

Dr. Bhumija Gupta, Assistant Professor of Clinical Dentistry, Eastman Institute for Oral Health University of Rochester, New York, USA

Section Editors Board

Public Health Dentistry

Dr. R. K. Bali, Former President, Dental Council of India, New Delhi

Dr. S. S. Hiremath, Senior Professor and Head, Department of Public Health Dentistry, The Oxford Dental College, Hospital and Research Centre, Bengaluru, Karnataka, India

Dr. Ganesh Shenoy, Professor and Head, Department of Public Health Dentistry, Yenepoya Dental College, Mangaluru, India

Dr. M. B. Aswath Narayanan, Professor and Head, Department of Public Health Dentistry, Tamil Nadu Govt. Dental College, Chennai, TN, India

Conservative Dentistry

Dr. Dibyendu Mazumder, President, Dental Council of India

Dr. Sanjay Tewari, Principal, Dental College (PGIMER), Rohtak, Haryana, India

Dr. Naseem Shah, Former Head, AIIMS, New Delhi

Dr. T. Rambabu, Professor and Head, Drs. Sudha & Nageswara Rao Siddhartha Institute of Dental Sciences, Chinoutapally, Gannavaram (M), Krishna Dist., Andhra Pradesh

Dr. Rajiv Chugh, Private Practice, New Delhi

Dr. Abhay Kamra, Former Professor & Head, Dept. Conservative Dentistry & Endodontics - C.S.M.S.S. Dental College & Hospital, Aurangabad.

Dr. Devender Chaudhary, Principal, Head, Maharaja Ganga Singh Dental College & Research Centre

Dr. Mithra Hegde, Senior Professor & Head of the Department, A.B Shetty Memorial Institute of Dental Sciences, Mangalore

Dr. Vinod Babu Mathew, King Khalid University, Saudi Arabia

Dr. Karthick, K, KSR Institute of Dental Science and Research, Tiruchengode, TN.

Esthetic Dentistry

Dr. Sandesh Mayekar, Esthetic Dentist, Private practice, Mumbai

Dr. Poras Turner, Professor of Postgraduate studies in the Dept. of Prosthodontics at A. B. Shetty Institute of Dental Studies, Mangalore, India

Dr. Deepak Mucchala, Private practice, Mumbai

General Dentistry

Dr. R. Bellie, Private practice, Coimbatore, Tamil Nadu

Dr. George Thomas, Private practice, Kumbakonam, Tamilnadu

Dr. Bhagwant Singh, Private practice, Ludhiana

HIV & Oral Health

Dr. Amar Pazare, Prof. & HOD Medicine at Seth G. S. Medical College & KEM hospital, Parel, Mumbai

Pedodontics

Dr. A.K. Munshi, Former Director, Principal, K. D. Dental College & Hospital, Mathura

Dr. Krishan Gauba, Head, Oral Health Sciences Centre, PGI, Chandigarh

Dr. I. K. Pandit, Principal, D. A. V. Dental College & Hospital, Yamuna Nagar, Haryana

Dr. Navneet Grewal, Prof. and Head, Govt. Dental College, Amritsar

Dr. Narendra Chandranee, Former Professor & Head, VSPM Dental College & Research, Nagpur, Maharashtra

Dr. Ashima Goyal, Professor, OHSC, PGI, Chandigarh

Dr. Attiguppe R Prabhakar, Vice Principal, Professor and Head, Bapuji Dental College & Hospital, Davangere

Dr. TN Tilak Raj, Professor and Head, Shymla Reddy Dental College, Bangalore

Dr. J. Baby John, Principal, VMS Dental College, Salem

Dr. Shalini Garg, Professor and Head, Sudha Rahstogi Dental College, Faridabad

Dr. B. Nandlal, Professor, J S S, Dental College, Mysore
Dr. Nikhil Srivastava, Principal and Dean, Subharti Dental College and Hospital, Meerut
Dr. Sham Bhat, Vice Principal and Head, Yenepoya Dental College, Mangalore
Dr. Abi Thomas, Principal, Christian Dental College, Ludhiana
Dr. Mousumi Singh, Professor and Head, ITS Dental College, Greater Noida (U.P.)
Dr. Ramakrishna Yeluri, Professor and Head, Teerthankar Mahavidyalaya, Moradabad
Dr. Adesh Kakde, Nair Hospital Dental College, Mumbai
Dr. Amita Tiku, Prof and Head, Bharti Vidhyapeeth Dental College, Navi Mumbai, Maharashtra
Dr. N. Venugopal Reddy, Prof and Head, Mamata Dental College Khammam Andhra Pradesh
Dr. Vijay P Mathur, Professor and Head, AIIMS .New Delhi
Dr. Tejashree Gupte, Professor, Nair Hospital Dental College, Mumbai

Periodontics

Dr. A. Kumarswamy, Periodontist, Private Practice, Chembur East, Mumbai
Dr. D.S Mehta, Professor & Head, Bapuji Dental College
Dr. C. S. Saimbi, Former Professor and Head, Dental College, Lucknow, Uttar Pradesh
Dr. Gururaja Rao, Ex-Principal, AME Dental College ,Raichur, Karnataka
Dr. Tamal Kanti Pal, Professor & Head, Guru Nanak Institute of Dental Science & Research and Hospital, Kolkata
Dr. Vijay Kumar Chava, Prof and Head, Narayana Dental College, Nellore, AP.
Dr. Dilip G Naik, Former Dean, Professor, Manipal College of Dental Sciences, Mangalore
Dr. Shalu Bathla, Professor, M.M.College of Dental Sciences, Mullana, Ambala, Haryana.
Dr. Sreenivas Nagarakanti, Professor, Narayana Dental College, Nellore, AP.
Dr. Neeraj Deshpande, Professor, K.M.Shah Dental College, Vadodara ,Gujrat

Prosthodontics

Dr. Hari Prakash- Director General at I.T.S Centre for Dental Studies & Research, Muradnagar,
Dr. Mahesh Verma, Director Principal, Maulana Azad Institute of Dental Sciences, New Delhi
Dr. Manu Rathi, Prof & Head, Post Graduate Institute Of Dental Sciences, Rohatak ,Haryana
Dr. Narendra Gupta, Professor, Baba Banarasidas Dental College, Lucknow
Dr. Himanshu Aeran, Director Principal, Seema Dental College & Hospital, Rishikesh
Dr. Dileepnag Vinnakota, Professor, Narayana Dental College, Nellore, AP.
Dr. Sushant Garg, Yamuna Institute of Dental Sciences, Yamuna Nagar, Haryana
Dr. Sanjay Bansal, Eklavya Dental College, Kotputli, Rajasthan
Dr. Umesh Pai, Manipal College of Dental Sciences, Mangalore, Karnataka
Dr. Meena Aras, Govt.Dental College, Goa.

Oral Medicine

Dr. Frey Karjodkar Prof & Head, Nair Hospital Dental College Mumbai
Dr. Jayachandran, Prof and Head, Govt Dental College, Chennai
Dr. Kannan Natarajan, Professor and Head, Narayana Dental College, Nellore, AP.
Dr. Rajendra Patil, Professor and Head, Kothiwal Dental College, Moradabad, UP

Oral Pathology

Dr. Dinesh Daftary, Former Scientist. Tata Institute of Fundamental Research, Mumbai
Dr. C.R. Ramchandran, Former Dean, RM Dental College, Annamalai Nagar,Chidambaram,TN.
Dr. R.R Paul, Vice Principal, Senior Professor, Guru Nanak Institute of Dental Sciences & Research, Kolkata
Dr. V. K. Hazarey, Former Dean, Government Dental College, Nagpur.
Dr. Ranganathan, Professor and HOD, Ragas Dental College
Dr. B. Ajay Reginald, Principal, Narayana Dental College, Nellore, AP.

Oral Surgery

Dr. Neelima Malik, Vice Chancellor, Krishna University Karad
Dr. Mohan Baliga, Associate Dean & Professor of MCODS, Mangalore
Dr. Sripathi Rao BH, Dean, Yenepoya Dental College Manglore
Dr. Rajiv Borle, Vice Chancellor, Datta Meghe Deemed University Wardha
Dr. Vidya Rattan, Professor PGI Chandigarh

Dr. L. Krishna Prasad, Principal and Dean, Sibar Institute of Dental Sciences, Guntur

Dr. Venkata Kishore Kumar Rayaduragam, Narayana Dental College, Nellore A P

Dr. Rajshekhar Gali, Professor, Narayana Dental College Nellore AP

Orthodontics

Dr. Ashok Utreja, Former Head Oral Health PGI , Chandigarh

Dr. Sadashiva Shetty, Principal Prof. and Head, Babuji Dental College

Dr. O.P. Kharbanda, Prof. and Head, All India Institute and Medical Sciences, New Delhi.

Dr. Ashok Dhoble, Hon. Secretary General at Indian Dental Association (H.O.)

Dr. T. Samraj, Director, VMS Dental College, Lakshmipuram,, Gandhi Road, Salem

Dr. S. P. Singh, Prof of Orthodontics PGI Chandigarh

Dr. U. S. Krishna Nayak, Principal, A.B. Shetty Dental College Manglore

Dr. Vinay Dua, Director, Principal, Professor & Head, National Dental College & Hospital, Dera Bassi (Punjab)

Biotechnology

Prof. (Dr). Anil Sharma
Maharishi Markandeshwar (Deemed to be University),
Mullana, Ambala (HR)
INDIA-133207

[Sitemap](#) | [What's New](#) | [Feedback](#) | [Disclaimer](#)

© 2020 Contemporary Clinical Dentistry | Published by Wolters Kluwer - Medknow

Online since 10th March, 2010

[Editorial and Ethics Policies](#)

 [Open Access](#)  [View mobile site](#)

ISSN: Print -0976-237X, Online - 0976-2361

Table of Contents - Current issue



July-September 2019
 Volume 10 | Issue 3
 Page Nos. 407-581

Online since Wednesday, March 11, 2020

Accessed 1,042 times.

PDF access policy

Full text access is free in HTML pages; however the journal allows PDF access only to users from **INDIA, developing countries** and paid subscribers.

EPub access policy

Full text in EPub is free except for the current issue. Access to the latest issue is reserved only for the paid subscribers.

[View issue as eBook](#)

[Issue statistics](#)

[RSS](#)

[Show all abstracts](#) [Show selected abstracts](#) [Export selected to](#) [Add to my list](#)

Feedback
Subscribe
Advertise

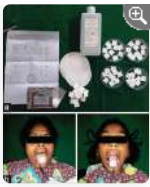- [Submit article](#)
- [Most popular articles](#)
- [Join as Reviewer](#)
- [Email alerts](#)
- [Recommend this journal to your library or friends](#)

GUEST EDITORIAL

- Current therapeutic modalities of immunobullous lesions** POPULAR p. 407
 Jayachandran Sadaksharam
 DOI:10.4103/ccd.ccd_464_19
[\[HTML Full text\]](#) [\[PDF\]](#) [\[Mobile Full text\]](#) [\[EPub\]](#) [\[Sword Plugin for Repository\]](#)^{Beta}

ORIGINAL ARTICLES

- Applicability of Tanaka–Johnston, Moyers, and Bernabé and Flores–Mir mixed dentition analyses in school-going children of Sri Ganganagar City, Rajasthan (India): A cross-sectional study** p. 410
 Ashish Kakkar, Kanika Gupta Verma, Purshottam Jusuja, Suruchi Juneja, Nishtha Arora, Shobhit Singh
 DOI:10.4103/ccd.ccd_654_18
[\[ABSTRACT\]](#) [\[HTML Full text\]](#) [\[PDF\]](#) [\[Mobile Full text\]](#) [\[EPub\]](#) [\[Sword Plugin for Repository\]](#)^{Beta}
- Communicating risk: Assessing compliance of tobacco products to cigarettes and other tobacco products act (Packaging and labelling) amendment rules 2015 in Delhi, India** p. 417
 Puneet Chahar, Manasi Karnani, Vikrant R Mohanty
 DOI:10.4103/ccd.ccd_668_18
[\[ABSTRACT\]](#) [\[HTML Full text\]](#) [\[PDF\]](#) [\[Mobile Full text\]](#) [\[EPub\]](#) [\[Sword Plugin for Repository\]](#)^{Beta}
- Fluoride concentration in saliva following professional topical application of 2% sodium fluoride solution** p. 423
 Manjit Talwar, Amrit Tewari, HS Chawla, Vinod Sachdev, Suresh Sharma
 DOI:10.4103/ccd.ccd_681_18
[\[ABSTRACT\]](#) [\[HTML Full text\]](#) [\[PDF\]](#) [\[Mobile Full text\]](#) [\[EPub\]](#) [\[Sword Plugin for Repository\]](#)^{Beta}
- A comparative evaluation of efficacy of gingival retraction using polyvinyl siloxane foam retraction system, vinyl polysiloxane paste retraction system, and copper wire reinforced retraction cord in endodontically treated teeth: An *in vivo* study** p. 428
 Sonal Mehta, Hemali Virani, Sarfaraz Memon, Narendra Nirmal
 DOI:10.4103/ccd.ccd_708_18
[\[ABSTRACT\]](#) [\[HTML Full text\]](#) [\[PDF\]](#) [\[Mobile Full text\]](#) [\[EPub\]](#) [\[Sword Plugin for Repository\]](#)^{Beta}
- Regenerative capacity of leukocyte-rich and platelet-rich fibrin in indirect sinus elevation procedure may be dependent on model-specific modification of the centrifugation cycle** p. 433
 Rampalli Viswa Chandra, Varanasi Vaishnavi, Y S. H S. Chakravarthy
 DOI:10.4103/ccd.ccd_715_18
[\[ABSTRACT\]](#) [\[HTML Full text\]](#) [\[PDF\]](#) [\[Mobile Full text\]](#) [\[EPub\]](#) [\[Sword Plugin for Repository\]](#)^{Beta}
- Correlation of mother and child's taste perception and their caries experience** p. 440
 K Abhiram, AJ Sai Sankar, E Sridevi, M Sridhar, K Pranitha, D Aruna
 DOI:10.4103/ccd.ccd_726_18



[ABSTRACT] [HTML Full text] [PDF] [Mobile Full text] [EPub] [Sword Plugin for Repository]^{Beta}

Role of dental discomfort questionnaire-based approach in recognition of symptomatic expressions due to dental pain in children with autism spectrum disorders p. 446

Chandana Penmetsa, Sarada Penmetcha, Sampath Reddy Cheruku, Sreekanth Kumar Mallineni, Anil Kumar Patil, Srinivas Namineni

DOI:10.4103/ccd.ccd_728_18

[ABSTRACT] [HTML Full text] [PDF] [Mobile Full text] [EPub] [Sword Plugin for Repository]^{Beta}

Effect of dentifrice containing crab-shell chitosan on the accumulation of dental plaque in fixed orthodontic appliances patients: A randomized controlled trial p. 452

J C. P Heryumani Sulandjari, Afina Zahra Chairunnisa, Ananto Ali Alhasyimi

DOI:10.4103/ccd.ccd_740_18

[ABSTRACT] [HTML Full text] [PDF] [Mobile Full text] [EPub] [Sword Plugin for Repository]^{Beta}

Comparative evaluation of boric acid gel versus chlorhexidine gel in the treatment of chronic periodontitis: Randomized, placebo-controlled clinical study p. 457

Alefiya Mamajiwala, Kunal Sunder Sethi, Swapna A Mahale, Chetan Purushottam Raut, Prerna A Karde, Aishwarya M Kale

DOI:10.4103/ccd.ccd_752_18

[ABSTRACT] [HTML Full text] [PDF] [Mobile Full text] [EPub] [Sword Plugin for Repository]^{Beta}

Degree of conversion and polymerization shrinkage of low shrinkage bulk-fill resin composites p. 465

Haidy N Salem, Sherif M Hefnawy, Shaymaa M Nagi

DOI:10.4103/ccd.ccd_756_18

[ABSTRACT] [HTML Full text] [PDF] [Mobile Full text] [EPub] [Sword Plugin for Repository]^{Beta}

Evaluation of primary stability of cylindrical and tapered implants in different bone types by measuring implant displacement: An *In vitro* study p. 471

Tsutomu Sugiura, Kazuhiko Yamamoto, Satoshi Horita, Kazuhiro Murakami, Tadaaki Kirita

DOI:10.4103/ccd.ccd_788_18

[ABSTRACT] [HTML Full text] [PDF] [Mobile Full text] [EPub] [Sword Plugin for Repository]^{Beta}

Antibacterial and mechanical properties of pit and fissure sealants containing zinc oxide and calcium fluoride nanoparticles p. 477

Dara Lakshmi Swetha, C Vinay, KS Uloopi, Kakarla Sri RojaRamy, Rayala Chandrasekhar

DOI:10.4103/ccd.ccd_805_18

[ABSTRACT] [HTML Full text] [PDF] [Mobile Full text] [EPub] [Sword Plugin for Repository]^{Beta}

Clinical and radiographic success of three adhesive restorative materials in primary molar proximal lesions: A randomized clinical trial p. 483

SK Inthihas, S V. S G. Nirmala, Venkata Ratnakumar Rudhravarm

DOI:10.4103/ccd.ccd_809_18

[ABSTRACT] [HTML Full text] [PDF] [Mobile Full text] [EPub] [Sword Plugin for Repository]^{Beta}

Effect of indigenously developed nano-hydroxyapatite crystals from chicken egg shell on the surface hardness of bleached human enamel: An *In Vitro* study p. 489

Divya Kunam, Vidhya Sampath, Sujatha Manimaran, Mahalaxmi Sekar

DOI:10.4103/ccd.ccd_810_18

[ABSTRACT] [HTML Full text] [PDF] [Mobile Full text] [EPub] [Sword Plugin for Repository]^{Beta}

Root anatomy of mandibular second premolars in french subpopulation: A retrospective observational case series p. 494

Naji Kharouf, Youssef Haikel, Davide Mancino

DOI:10.4103/ccd.ccd_841_18

[ABSTRACT] [HTML Full text] [PDF] [Mobile Full text] [EPub] [Sword Plugin for Repository]^{Beta}

Salivary interleukin-6 levels among polycystic ovary syndrome patients with and without chronic periodontitis – A comparative study p. 498

Arun Varghese, Pratebha Balu, R Saravanakumar, Jananni Muthu, K Vineela

DOI:10.4103/ccd.ccd_848_18

[ABSTRACT] [HTML Full text] [PDF] [Mobile Full text] [EPub] [Sword Plugin for Repository]^{Beta}

Impact of oral health educational intervention on smoking among male adolescents p. 502

Hassan AIAbdullah, Ali Sadeq AlFahid, Abdulaziz AlQarni, Muhammad Ashraf Nazir

DOI:10.4103/ccd.ccd_863_18

[ABSTRACT] [HTML Full text] [PDF] [Mobile Full text] [EPub] [Sword Plugin for Repository]^{Beta}

Caries risk factors among children aged 3–5 years old in Indonesia p. 507

Sri Ratna Laksmiastuti, Tri Erri Astoeti, Heriandi Sutadi, Sarworini B Budiardjo

DOI:10.4103/ccd.ccd_877_18

[ABSTRACT] [HTML Full text] [PDF] [Mobile Full text] [EPub] [Sword Plugin for Repository]^{Beta}

Comparative evaluation of extrusion of apical debris in primary anterior teeth using two p. 512



different rotary systems and hand files: An *In Vitro* study

Ahsana Asif, Ganesh Jeevanandan, Lavanya Govindaraju, R Vignesh, EM G. Subramanian
DOI:10.4103/ccd.ccd_884_18

[ABSTRACT] [HTML Full text] [PDF] [Mobile Full text] [EPub] [Sword Plugin for Repository]^{Beta}

p. 517



Quantification and comparison of the impact of the smoking status on oral polymorphonuclear leukocyte and malondialdehyde levels in individuals with chronic periodontitis: A double-blinded longitudinal interventional study

Ninad Milind Padhye, Ashvini Mukul Padhye, Himani Swatantrkumar Gupta
DOI:10.4103/ccd.ccd_906_18

[ABSTRACT] [HTML Full text] [PDF] [Mobile Full text] [EPub] [Sword Plugin for Repository]^{Beta}

p. 525



High-mobility group box 1 expression in mandibular bone cells of experimental periodontitis

Yuliana Mahdiyah Da'at Arina, Mohamad Rubianto, F Ferdiansyah, I Ketut Sudiana, Retno Pudji Rahayu, Hari Basuki Notobroto
DOI:10.4103/ccd.ccd_907_18

[ABSTRACT] [HTML Full text] [PDF] [Mobile Full text] [EPub] [Sword Plugin for Repository]^{Beta}




Evaluation of efficacy of curcumin along with lycopene and piperine in the management of oral submucous fibrosis

Basudev Mahato, Chandraday Proadhan, Samir Mandal, Avirup Dutta, Parna Kumar, Tushar Deb, Tarun Jha, Keya Chaudhuri
DOI:10.4103/ccd.ccd_937_18

[ABSTRACT] [HTML Full text] [PDF] [Mobile Full text] [EPub] [Sword Plugin for Repository]^{Beta}

p. 531



Comparative evaluation of cleaning efficacy of self-adjusting file and waveone file: An *in vitro* scanning electron microscopic study

Balakrishnan Bakthavatchalam, Muthukrishnan Sudharshana Ranjani, Krishnan Amudhalakshmi
DOI:10.4103/ccd.ccd_160_19

[ABSTRACT] [HTML Full text] [PDF] [Mobile Full text] [EPub] [Sword Plugin for Repository]^{Beta}

p. 542

CASE REPORTS

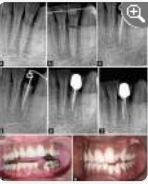

Vestibular Incision Subperiosteal Tunnel Access (VISTA) for Surgically Facilitated Orthodontic Therapy (SFOT)

Homayoun H Zadeh, Ali Borzabadi-Farahani, Mehdi Fotovat, Seong-Hun Kim
DOI:10.4103/ccd.ccd_720_18

[ABSTRACT] [HTML Full text] [PDF] [Mobile Full text] [EPub] [Sword Plugin for Repository]^{Beta}

p. 548



Management of subgingival root fracture with decoronation and orthodontic extrusion in mandibular dentition: A report of two cases

Gaurav Kumar, Neha Verma, Sachin Parashar
DOI:10.4103/ccd.ccd_736_18

[ABSTRACT] [HTML Full text] [PDF] [Mobile Full text] [EPub] [Sword Plugin for Repository]^{Beta}

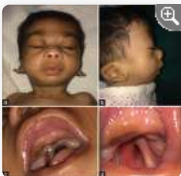p. 554

Feeding difficulty in an infant with stickler's syndrome

Parvathy Vijay, Parvathy Kumaran, Arun Mamachan Xavier, R Balagopal Varma, J Suresh Kumar
DOI:10.4103/ccd.ccd_749_18

[ABSTRACT] [HTML Full text] [PDF] [Mobile Full text] [EPub] [Sword Plugin for Repository]^{Beta}

p. 558

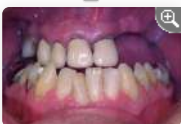

Rehabilitation with fixed prosthodontics associated with removable partial prosthesis: A 5-year follow-up clinical evaluation

Tassiana Cançado Melo Sá, Francisco Ivison Rodrigues Limeira, Ricardo Antonio Alpino Rodrigues, Júlio Celso Melo de Sá, Cláudia Silami de Magalhães, Allyson Nogueira Moreira, Monica Yamauti
DOI:10.4103/ccd.ccd_750_18

[ABSTRACT] [HTML Full text] [PDF] [Mobile Full text] [EPub] [Sword Plugin for Repository]^{Beta}

p. 561



Plasma-cell gingivitis a challenge to the oral physician

Bhupender Singh Negi, Nileena R Kumar, PS Haris, Jiwane Achal Yogesh, C Vijayalakshmi, Jeswin James
DOI:10.4103/ccd.ccd_776_18

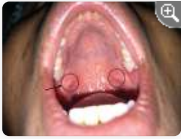[ABSTRACT] [HTML Full text] [PDF] [Mobile Full text] [EPub] [Sword Plugin for Repository]^{Beta}

p. 565



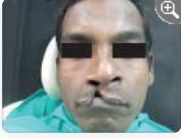The pterygoid hamulus syndrome – An important differential in orofacial pain

p. 571



Prajwalit Kende, Neha Aggarwal, Vikas Meshram, Jayant Landge, Vijaylaxmi Nimma, Paul Mathai
DOI:10.4103/ccd.ccd_796_18

[\[ABSTRACT\]](#) [\[HTML Full text\]](#) [\[PDF\]](#) [\[Mobile Full text\]](#) [\[EPub\]](#) [\[Sword Plugin for Repository\]](#)^{Beta}



Prosthetic lip with the retentive attachment for a unilateral cleft lip patient: A clinical report p. 577

Khushboo Singh, Nayana Prabhu, Dhanasekar Balkrishanan, Aparna I Narayana, S Pradeep
DOI:10.4103/ccd.ccd_801_18

[\[ABSTRACT\]](#) [\[HTML Full text\]](#) [\[PDF\]](#) [\[Mobile Full text\]](#) [\[EPub\]](#) [\[Sword Plugin for Repository\]](#)^{Beta}

[Sitemap](#) | [What's New](#) | [Feedback](#) | [Disclaimer](#)

© 2010 Contemporary Clinical Dentistry | Published by Wolters Kluwer - Medknow

Online since 10th March, 2010

[Editorial and Ethics Policies](#)

 [BY-NC-SA](#)  **Open Access**  [View mobile site](#)

ISSN: Print -0976-237X, Online - 0976-2361

High-Mobility Group Box 1 Expression in Mandibular Bone Cells of Experimental Periodontitis

Abstract

Background: High-mobility group box 1 (HMGB1) was suggested to be associated with the pathogenesis of chronic periodontitis which characterized by alveolar bone loss. HMGB1 was defined as a bone-active cytokine, but the role of HMGB1 in bone loss of chronic periodontitis is still understood. **Aim:** The aim of this study is to investigate the expression of HMGB1 on osteoblasts and osteoclasts in the mandible of chronic periodontitis. **Methods:** This experimental study was conducted to rats injected by *Porphyromonas gingivalis* into the buccal and lingual subgingival area at a concentration of 2×10^9 CFU/mL three times a week with 2-day apart for 2, 3, 4, and 6 weeks as chronic periodontitis group and injected by normal saline as control group. Analysis of variance was used to examine the differences between groups followed by least significant difference *post hoc* test with the level of significance was <0.05 . **Results:** The HMGB1 expression was found in both osteoclasts and osteoblasts of mandibular bone by immunohistochemistry analysis. There was a difference of HMGB1 expression on osteoblasts and osteoclasts of chronic periodontitis. HMGB1 expression was found increased significantly in mandibular osteoblasts of chronic periodontitis, whereas the HMGB1 expression in mandibular osteoclast is higher in 2 and 3 weeks, but it was lower in 4 and 6 weeks. **Conclusions:** This study indicated a potential role for HMGB1 in bone loss of chronic periodontitis. HMGB1 on mandibular osteoclasts and osteoblasts may play different rules in the onset and progression of chronic periodontitis.

Keywords: Bone loss, chronic periodontitis, high-mobility group box 1, mandibular bone cell, osteoblasts/osteoclasts

Introduction

High-mobility group box 1 (HMGB1) was a nonhistone chromatin-binding protein that was the most highly expressed of all the high-mobility group family members.^[1] HMGB1 is located in the nucleus, but HMGB1 has been reported to be present in the cytoplasm and cell membrane. Nuclear HMGB1 acts as an architectural protein in chromosomes to maintain nucleosome structure and acts as a DNA chaperone and regulates gene transcription.^[2] HMGB1 can translocate from nucleus to cytoplasm because of some stressors, including cytokine, chemokine, heat, hypoxia, and oncogene.^[2] A recent study showed that HMGB1 can be released into the extracellular by necrotic and damaged cells and can act as a signal of tissue damage and mediates inflammation and tissue regeneration.^[3] It has been reported that HMGB1 is a potent

pro-inflammatory cytokine that orchestrated in systemic and local inflammation. HMGB1 is involved in the development and contributes to the outcome of some diseases such as bacterial sepsis, diabetes, postischemic brain and heart disease, rheumatoid arthritis, and skin lesions in systemic lupus erythematosus.^[2,3]

It was suggested that HMGB1 has a potential role in the pathogenesis of chronic periodontitis. The increased HMGB1 was found in gingiva and gingival crevicular fluid of the patient with chronic periodontitis.^[4-6] Expression of HMGB1 can be detected higher in chronic periodontitis patients and decreased after periodontal treatment.^[5] Chronic periodontitis is a chronic infectious disease, resulting in inflammation within the supporting tissues of the teeth, progressive attachment loss, and bone loss.^[7] *Porphyromonas gingivalis* (*P. gingivalis*) has been identified as one of the major periodontal pathogens of chronic periodontitis.^[8] The virulence

Yuliana Mahdiyah Da'at Arina, Mohamad Rubianto¹, F. Ferdiansyah², I. Ketut Sudiana³, Retno Pudji Rahayu⁴, Hari Basuki Notobroto⁵

Department of Periodontology, Faculty of Dentistry, Jember University, Jember; Departments of ¹Periodontology and ⁴Oral and Maxillofacial Pathology, Faculty of Dental Medicine, Airlangga University, ²Department of Orthopedics and Traumatology, Dr. Soetomo General Hospital, ³Department of Pathology Anatomy, Faculty of Medicine, Airlangga University, ⁵Department of Biostatistics and Population, Faculty of Public Health, Airlangga University, Surabaya, Indonesia

Address for correspondence:
Dr. Yuliana Mahdiyah Da'at Arina, Department of Periodontology, Faculty of Dentistry, Jember University, Kalimantan 37 Jember 68121, Indonesia.
E-mail: yulianamahdiyah@gmail.com

Access this article online

Website:

www.contempclindent.org

DOI: 10.4103/ccd.ccd_907_18

Quick Response Code:



How to cite this article: Da'at Arina YM, Rubianto M, Ferdiansyah F, Sudiana IK, Rahayu RP, Notobroto HB. High-mobility group box 1 expression in mandibular bone cells of experimental periodontitis. Contemp Clin Dent 2019;10:525-30.

This is an open access journal, and articles are distributed under the terms of the Creative Commons Attribution-NonCommercial-ShareAlike 4.0 License, which allows others to remix, tweak, and build upon the work non-commercially, as long as appropriate credit is given and the new creations are licensed under the identical terms.

For reprints contact: reprints@medknow.com

factors of these bacteria can contribute to extracellular matrix destruction and modulate inflammatory and immune responses, resulting in deeper tissue destruction and bone resorption.^[9] *P. gingivalis* LPS, lipids, and metabolic products can inhibit the differentiation and osteogenesis of osteoblasts, and modulate receptor activator of nuclear factor-kappa B ligand (RANKL) and/or osteoprotegerin (OPG) expression in osteoblasts to stimulate osteoclastogenesis, resulting in bone loss.^[10,11]

Alveolar bone loss is a hallmark of periodontitis progression. Mandibular bone cells, osteoclasts, and osteoblasts were the key cells in bone loss in periodontitis. Although HMGB1 was defined as a bone-active cytokine,^[12] the role of HMGB1 in alveolar bone loss in periodontitis was remaining understood. A study by Charoonpatrapong *et al.*^[13] found that rat calvarial osteoblast and primary osteoclasts derived from mouse bone marrow cells expressed and released HMGB1. HMGB1 released into the bone microenvironment and induced inflammatory bone loss through the release of RANKL, interleukin 6 (IL-6), and tumor necrosis factor-alpha (TNF- α) by osteoblast.^[12] Studies reported that HMGB1 expression was higher in gingiva and periodontal ligament of experimental periodontitis.^[14,15] However, the study reported the expression HMGB1 in mandibular bone cells is not found yet. This study conducted to investigate the expression of HMGB1 on mandibular bone cells of experimental periodontitis induced by *P. gingivalis*.

Methods

All experimental procedure was performed under a protocol approved by Committee Ethical of Faculty of Dentistry, Airlangga University (Ethical Clearance Certificate Number 017/HRECC.FODM/II/2017). Forty Wistar –Strain of *Rattus norvegicus*, 3–4-month-old male, 200–220 g in weighing, were randomly divided into two equal groups, periodontitis and control group. Throughout the experimental period, rats were housed in plastic cages, fed a standard laboratory diet, and given water *ad libitum*.

Bacterial strain and culture

P. gingivalis (ATCC 33277, MediMark, France) was cultured at 37°C on Trypton Soya Agar plates with 10% sheep blood, supplemented with 0.4 μ L/mL Vitamin K and hemin in an oxygen-free atmosphere (80% nitrogen, 10% carbon dioxide, and 10% hydrogen). After 14 days, *P. gingivalis* colonies were selected, and a solution of 2×10^9 CFU/mL in 100 μ L of 0.9% sodium chloride was prepared. This solution was prepared immediately before use. Gram's method was used to confirm the purity of the colonies.

Experimental periodontitis

The rat in the periodontitis group was injected by 0.05 mL live-*P. gingivalis* at a concentration of 2×10^9 CFU/mL into buccal and lingual subgingival sulcus area between the left

first and second mandibular molar three times a week with 2 days interval for 2, 3, 4, and 6 weeks. The bacterial injection was performed using tuberculin disposable syringe (OneMed, Indonesia) with needle 30Gauge (BD PrecisionGlide™ Needle, USA). The control group was injected by normal saline as periodontitis group protocol. One day after 2, 3, 4, and 6 weeks following injection, five rats in each group were sacrificed. The mandibular specimens were harvested and fixed in normal buffer formalin. Then, the tissues were demineralized in 10% EDTA for 2 months. The demineralized tissues were dehydrated using gradient ethanols, cleared with xylene and embedded in paraffin. Serial sections of 5 mm in thickness were made in the mesiodistal direction for hematoxylin and eosin and immunohistochemical staining.

Immunohistochemical staining

The sections were deparaffinized using xylene, hydrated in gradient ethanols, and then the sections were treated with 3% H₂O₂ for 10 min at room temperature to inhibit endogenous peroxidase activities and washed with 0.01 M PBS 5 min \times 2 times. The sections were treated with 5% normal blocking serum (UltraTekHRP, Scytec) for 5 min to block nonspecific background staining and washed with 0.01 M PBS 5 min \times 2 times. Then, the sections were reacted with polyclonal antibody HMGB1 (HMG-1, sc-135809, Santacruz Biotechnologi, Inc.) for 1 h at 4°C as recommended by the manufacturer. After washing with 0.01 M PBS 5 min \times 3 times, the sections were then incubated with Poly-HRP anti-goat/rabbit IgG (UltraTekHRP, Scytec) for 15 min at 37°C. Afterward, the sections were visualized with 3,3-diaminobenzidine tetrahydrochloride for 10 min (UltraTekHRP, Scytec). 0.01 M PBS instead of antibody served as negative control. The sections were examined and photographed with a light microscope (Nikon E100 J fully equipped digital camera ILCE A7 Sony). The number of osteoblasts and osteoclasts cells with positive the expression of HMGB1 was calculated.

Statistical analysis

Data were presented as mean \pm standard deviation One-way analysis of variance was used to examine the differences between groups followed by Least Significant Difference *post hoc* test. The data were considered statistically significant when the *P* value was < 0.05 .

Results

The result showed that HMGB1 was expressed in osteoblast as well as in osteoclast of mandibular bone. Immunohistochemical analysis of mandibular osteoblast demonstrated that weak staining of HMGB1 was observed primarily in the cytoplasm [Figure 1], but in the mandibular osteoclasts, the expression of HMGB1 was found in strong staining in cytoplasm and nucleus [Figure 2].

HMGB1 expressed either in the chronic periodontitis model group and control group. The HMGB1 expression

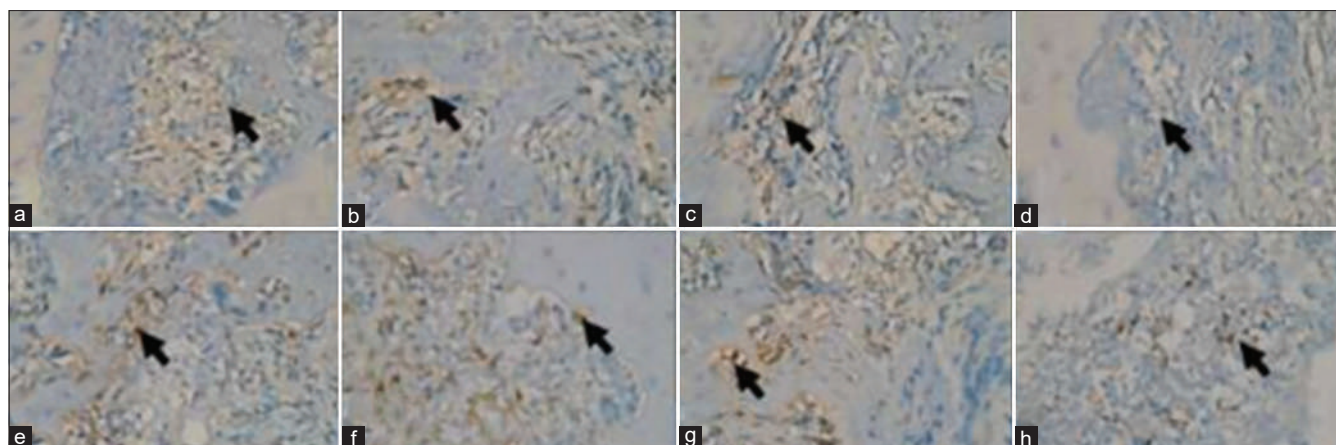


Figure 1: The immunoexpression of high-mobility group box 1 in mandibular osteoblast. High-mobility group box 1 observed in weak staining of the cytoplasm of periodontitis group 2 week (e), 3 weeks (f), 4 weeks (g) and 6 weeks (h) and in control group 2 week (a), 3 weeks (b), 4 weeks (c) and 6 weeks (d)

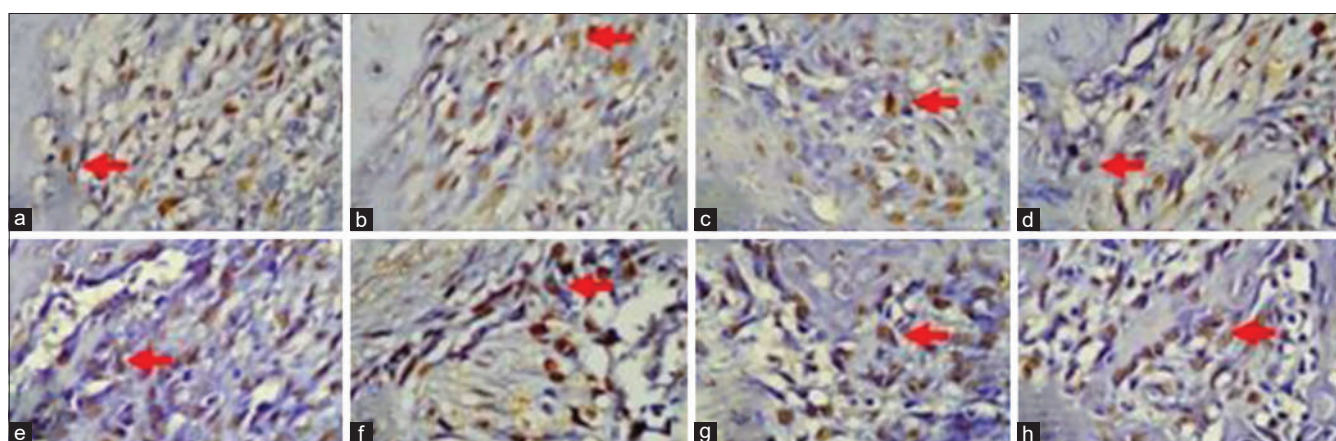


Figure 2: The immunoexpression of high-mobility group box 1 in mandibular osteoclast. Nuclear and cytoplasmic staining of high-mobility group box 1 observed in control group 2 week (a), 3 weeks (b), 4 weeks (c) and 6 weeks (d) and periodontitis Group 2 week (e), 3 weeks (f), 4 weeks (g) and 6 weeks (h)

in mandibular osteoblast of all periodontitis groups was higher significantly than the control group ($P < 0.05$). The HMGB1 expression in osteoblast of the periodontitis group was decreased significantly in line with the time of injection until 4 weeks; however, it increased but not statistically significant ($P = 0.087$) in 6 weeks injection [Figure 3]. A different result found in mandibular osteoclast of periodontitis groups. The HMGB1 expression of mandibular osteoclast in periodontitis group 2 and 3 weeks were higher than control group, but HMGB1 expressions in periodontitis group 4 and 6 weeks were lower significantly than control group ($P < 0.05$). By the time of injection, the HMGB1 expression in osteoclast of periodontitis group was decreased significantly ($P < 0.05$); although; the decreasing periodontitis 6 weeks was not significant periodontitis 4 weeks ($P = 0.121$) [Figure 4]. In all of the periodontitis groups, the expression of HMGB1 in osteoblast was higher significantly than osteoclast ($P < 0.05$).

Discussion

It has been suggested that HMGB1 has a potential role in the pathogenesis of chronic periodontitis.^[4,5] The level

of gingival crevicular fluid HMGB1 in periodontitis patients has a positive correlation with probing depth and clinical attachment loss.^[6] Chronic periodontitis was characterized by alveolar bone loss which is mediated by the host immune and inflammatory response to the microbial challenge.^[16] *P. gingivalis* can inhibit the differentiation and osteogenesis of osteoblasts and stimulate osteoclastogenesis and osteoclast activation resulting in bone loss.^[9,10] Mandibular osteoclast and osteoblast were the principle cells regulated mechanism of the bone loss in periodontitis. Therefore the expression of HMGB1 on mandibular bone cells should be determined.

This study successfully found the expression of HMGB1 on osteoblasts and osteoclasts of mandibular bone both in the experimental periodontitis and control rats. There was an increase in HMGB1 expression in osteoblast and osteoclast in periodontitis group than in control group. The result of this study supported the potential role of HMGB1 in the pathogenesis of periodontitis. In experimental periodontitis, HMGB1 expression was also reported higher in gingiva and periodontal ligament.^[14,15]

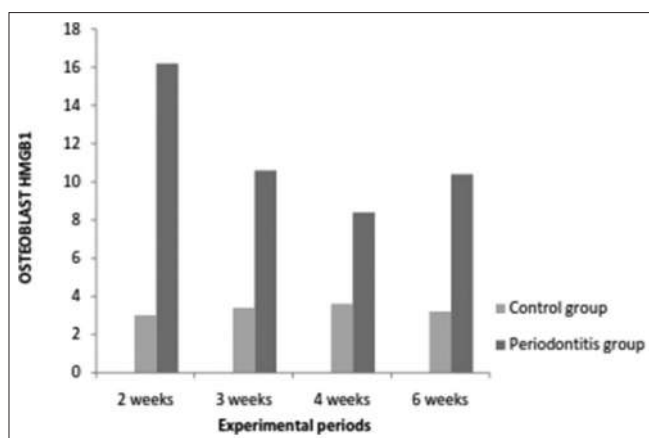


Figure 3: The immunoexpression of high-mobility group box 1 in mandibular osteoblast of experimental periodontitis different experimental periods. All of periodontitis group showed the higher expression significantly than control group ($P < 0.05$)

According to our knowledge, this is the first study reporting the immunoexpression of HMGB1 in mandibular bone cells. In mandibular osteoblast, HMGB1 expression observed mainly in the cytoplasm with weak staining, whereas in mandibular osteoclast, strong staining of HMGB1 observed in the nucleus and cytoplasm. This study was nearly same with the previous study that found HMGB1 expressed in osteoblast lined the trabecular surface of a rat femoral metaphysis and in primary osteoclast derived from mouse bone marrow chondrocytes.^[13] The immunoexpression of HMGB1 primarily localized to the nucleus of osteoblasts, but weak staining was observed in the cytoplasm. Primary osteoclasts expressed HMGB1 in the nuclei and in the perinuclear region.^[13] HMGB1 was also detected in the nuclei of prehypertrophic chondrocytes and in the cytosol of hypertrophic chondrocytes.^[17]

Naturally, the HMGB1 was located in nuclei, but it can translocate to the cytoplasm or perinuclear because of some stressor including cytokine, chemokine, heat, hypoxia, and oncogene.^[2,3] Study Morimoto *et al.*^[18] found that in healthy gingival tissues, HMGB1 is located mainly in the nucleus of epithelial cells while in inflamed gingival epithelial cells it is located in the perinuclear and in the cytoplasm. *In vitro* study in gingival fibroblast conducted by Feghali *et al.*^[19] found that before the induction of LPS *Actinobacillus actinomycetemcomitans* dan *P. gingivalis*, HMGB1 was expressed in the nucleus. After 6 h induction of that LPS, HMGB1 began expressed in the cytoplasm and after 12 h all of the nuclear HMGB1 translocate to cytoplasm. A study in ligature and *Escherichia coli* LPS-induced periodontitis found that HMGB1 was more expressed in the nucleus and cytoplasm of the fibroblast of periodontal ligament than in the extracellular space suggest that periodontal disease could contribute to HMGB1 translocation from the nucleus to the cytoplasm in the epithelial and connective cells.^[15] *P. gingivalis* induces translocation of HMGB1 from the nucleus to

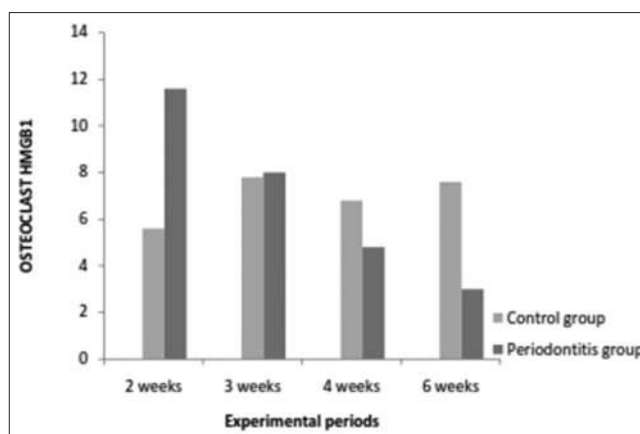


Figure 4: The immunoexpression of high mobility group box 1 in mandibular osteoclast of experimental periodontitis in different experimental periods. The high-mobility group box 1 expression of mandibular osteoclast in periodontitis group 2 was higher than control group, but high-mobility group box 1 expressions in periodontitis group 4 and 6 weeks were lower significantly than control group ($P < 0.05$)

the cytosol.^[20] In this study, it has been suggested that experimental periodontitis induced by *P. gingivalis* increased the HMGB1 expression in osteoblast and osteoclast and might induce translocating that molecule to the perinuclear or cytoplasm. Further study was needed to clarify this assumption.

The higher HMGB1 expression in osteoblast was observed in all of the periodontitis groups than in the control group and in osteoclasts, but HMGB1 expression in osteoclasts of periodontitis group presented higher at 2 and 3 weeks followed by decreased at 4 and 6 weeks than in control group. The study by Nogueira *et al.*^[15] found that the expression of HMGB1 in gingiva from ligature induced periodontitis higher at 7 and 14 days following by a decrease at 30 days.

The HMGB1 expression in osteoblast and osteoclast of the periodontitis group was decreased in line with the experimental periods. It was suggested that by the time of periodontitis progression, the HMGB1 translocated from the cytoplasm to the extracellular. According to study Charoonpatrapong *et al.*^[13] that osteoblasts and osteoclasts have been released HMGB1 to the bone environment. HMGB1 can be secreted from the cytoplasm to the extracellular actively by stimulated cells or passively by necrotic or damaged cells.^[2,3] Although the level of HMGB1 in tissue or gingival crevicular fluid as extracellular HMGB1 was not determined in this study, the increased level of HMGB1 in tissue or gingival crevicular fluid detected periodontitis patient may have come from mandibular osteoblasts or osteoclasts even in the milieu concentration.

This study demonstrated that there was a difference in HMGB1 expression between osteoblasts and osteoclasts in experimental periodontitis and control groups. In the control group, expression of HMGB1 in mandibular osteoblast was lower than in mandibular osteoclast. In contrast, in the

periodontitis group expression of HMGB1 in osteoblast was higher than osteoclast. This result showed that HMGB1 may have a different rule on osteoblasts and osteoclasts during the development and progression of periodontitis. The function of extracellular HMGB1 in periodontal tissue has been explored. Extracellular HMGB1 can act as cytokines or chemokines that involved in inflammation, immunity, cell growth, cell proliferation, and cell death.^[2,3] HMGB1 increased cytokine IL-1 β , interferon-gamma, or TNF- α production by macrophages.^[21] HMGB1 has been reported to stimulate the proliferation of gingival fibroblasts and the migration of gingival and periodontal ligament fibroblasts.^[22] Study Wolf *et al.*^[23] also found that HMGB1 increased the proliferation and migration of periodontal ligament cells. Osteogenic differentiation of periodontal ligament cell also increased by HMGB1 which was proven by increased of alkaline phosphatase specific activity and osteopontin expression.^[23] HMGB1 also can act as carrier protein for cytokines that have capability to activate the cell to release other cytokines.^[21] HMGB1 was secreted actively by chondrocytes acts as chemotactic factor for osteoblasts and osteoclasts and regulates endochondral ossification.^[17] HMGB1 promotes the migration of osteoblasts by TLR2/4-dependent signaling pathways that drive the activation of NF- κ B. The migration rate of osteoblasts increases 2.3-fold after HMGB1 treatment.^[24] The previous study has been demonstrated that HMGB1 molecules have a synergistic effect with RANKL to regulate osteoclastogenesis.^[25] Based on previous study, the HMGB1 alters osteoblast expression of RANKL or OPG^[26] and participates in osteoclastogenesis process.^[25] HMGB1 induced inflammatory bone loss through the release of RANKL, IL-6, and TNF α by osteoblast.^[12] RANKL induces HMGB1 release and it is required for RANKL-induced osteoclastogenesis *in vitro* and *in vivo*.^[25] In bone fractures, HMGB1 enhances mesenchymal stem cells in bone fracture area to secrete various cytokines and promotes osteogenic differentiation.^[27] Systemic administration of anti-HMGB1 neutralizing antibody significantly inhibited periodontal inflammation and bone resorption.^[28] However, there was no study reported the function of HMGB1 in mandibular osteoblast and osteoclast of periodontitis.

This finding HMGB1 expression in mandibular bone cells in periodontitis was very meaningful. This would be open the chance of studies to investigate the potential role of HMGB1 in the mechanism of pathogenesis and severity of periodontitis, especially bone resorption. HMGB1 in mandibular bone cells may be a critical biomarker of bone destruction in periodontitis, which can be used for the detection and diagnosis of disease, prediction of response to therapeutic interventions, or prognosis of the outcome.

Conclusions

HMGB1 was expressed at mandibular bone cells, and it increased in experimental periodontitis. It suggested that

HMGB1 may be a critical biomarker of periodontitis, especially in bone loss in periodontitis. HMGB1 on mandibular osteoblast and osteoclast may have a different rule in the development and progression of periodontitis. Further studies are necessary to investigate the potential role of HMGB1 in the mechanism of pathogenesis and severity of bone destruction in periodontitis.

Acknowledgment

This study was supported by the Directorate of Research and Community Service, Directorate General of Strengthening for Research and Development, Ministry of Research, Technology and Higher Education of the Republic of Indonesia (Research Contract Number: 058/SP2H/LT/DRPM/2018).

Financial support and sponsorship

Nil.

Conflicts of interest

There are no conflicts of interest.

References

- Musumeci D, Roviello GN, Montesarchio D. An overview on HMGB1 inhibitors as potential therapeutic agents in HMGB1-related pathologies. *Pharmacol Ther* 2014;141:347-57.
- Kang R, Chen R, Zhang Q, Hou W, Wu S, Cao L, *et al.* HMGB1 in health and disease. *Mol Aspects Med* 2014;40:1-16.
- Naglova H, Bucova M. HMGB1 and its physiological and pathological roles. *Bratisl Lek Listy* 2012;113:163-71.
- Luo L, Xie P, Gong P, Tang XH, Ding Y, Deng LX. Expression of HMGB1 and HMGN2 in gingival tissues, GCF and PICF of periodontitis patients and peri-implantitis. *Arch Oral Biol* 2011;56:1106-11.
- Paknejad M, Sattari M, Akbari S, Mehrfard A, Aslroosta H. Effect of periodontal treatment on the crevicular level of high-mobility group box1 and soluble triggering receptor expressed on myeloid cells 1 in patients with chronic periodontitis. *Iran J Allergy Asthma Immunol* 2017;16:554-60.
- Lin YC, Wu CY, Chang LY, Chen CC, Chen HH, Lai YL, *et al.* Levels of high-mobility group box-1 in gingival crevicular fluid in nonsmokers and smokers with chronic periodontitis. *J Formos Med Assoc* 2017;116:933-9.
- Domisch H, Kerschull M. Chronic Periodontitis. In: Newman MG, Takei HH, Klokkevold PR, Carranza FA, editors. *Carranza's Clinical Periodontology*. 12th ed. Philadelphia: Elsevier Saunders; 2015. p. 309-20.
- How KY, Song KP, Chan KG. *Porphyromonas gingivalis*: An overview of periodontopathic pathogen below the gum line. *Front Microbiol* 2016;7:53.
- Mysak J, Podzimek S, Sommerova P, Lyuya-Mi Y, Bartova J, Janatova T, *et al.* *Porphyromonas gingivalis*: Major periodontopathic pathogen overview. *J Immunol Res* 2014;2014:8. Doi: 10.1155/2014/476068.
- Han X, Lin X, Yu X, Lin J, Kawai T, LaRosa KB, *et al.* *Porphyromonas gingivalis* infection-associated periodontal bone resorption is dependent on receptor activator of NF- κ B ligand. *Infect Immun* 2013;81:1502-9.
- Di Benedetto A, Gigante I, Colucci S, Grano M. Periodontal disease: Linking the primary inflammation to bone loss. *Clin*

- Dev Immunol 2013;2013:7. Doi:10.1155/2013/503754
12. Yang J, Shah R, Robling AG, Templeton E, Yang H, Tracey KJ, *et al.* HMGB1 is a bone-active cytokine. *J Cell Physiol* 2008;214:730-9.
 13. Charoonpatrapong K, Shah R, Robling AG, Alvarez M, Clapp DW, Chen S, *et al.* HMGB1 expression and release by bone cells. *J Cell Physiol* 2006;207:480-90.
 14. Wolf M, Lossdörfer S, Küpper K, Jäger A. Regulation of high mobility group box protein 1 expression following mechanical loading by orthodontic forces *in vitro* and *in vivo*. *Eur J Orthod* 2014;36:624-31.
 15. Nogueira AV, de Souza JA, de Molon RS, Pereira Eda S, de Aquino SG, Giannobile WV, *et al.* HMGB1 localization during experimental periodontitis. *Mediators Inflamm* 2014;2014:10. doi:10.1155/2014/816320
 16. Hienz SA, Paliwal S, Ivanovski S. Mechanisms of bone resorption in periodontitis. *J Immunol Res* 2015;2015:615486.
 17. Taniguchi N, Yoshida K, Ito T, Tsuda M, Mishima Y, Furumatsu T, *et al.* Stage-specific secretion of HMGB1 in cartilage regulates endochondral ossification. *Mol Cell Biol* 2007;27:5650-63.
 18. Morimoto Y, Kawahara KI, Tanchaen S, Kikuchi K, Matsuyama T, Hashiguchi T, *et al.* Tumor necrosis factor- α stimulates gingival epithelial cells to release high mobility-group box-1. *J Periodontol Res* 2008;43:76-83.
 19. Feghali K, Iwasaki K, Tanaka K, Komaki M, Machigashira M, Ishikawa I, *et al.* Human gingival fibroblasts release high-mobility group box-1 protein through active and passive pathways. *Oral Microbiol Immunol* 2009;24:292-8.
 20. Johnson L, Atanasova KR, Bui PQ, Lee J, Hung SC, Yilmaz Ö, *et al.* *Porphyromonas gingivalis* attenuates ATP-mediated inflammasome activation and HMGB1 release through expression of a nucleoside-diphosphate kinase. *Microbes Infect* 2015;17:369-77.
 21. Sha Y, Zmijewski J, Xu Z, Abraham E. HMGB1 develops enhanced proinflammatory activity by binding to cytokines. *J Immunol* 2008;180:2531-7.
 22. Chitanuwat A, Laosrisin N, Dhanesuan N. Role of HMGB1 in proliferation and migration of human gingival and periodontal ligament fibroblasts. *J Oral Sci* 2013;55:45-50.
 23. Wolf M, Lossdörfer S, Römer P, Craveiro RB, Deschner J, Jäger A. Anabolic properties of high mobility group box protein-1 in human periodontal ligament cells *in vitro*. *Mediators Inflamm* 2014;2014:347585.
 24. Li MJ, Li F, Xu J, Liu YD, Hu T, Chen JT. Rhhmgbl drives osteoblast migration in a TLR2/TLR4-and NF- κ B-dependent manner. *Biosci Rep* 2016;36:e00300.
 25. Zhou Z, Han JY, Xi CX, Xie JX, Feng X, Wang CY, *et al.* HMGB1 regulates RANKL-induced osteoclastogenesis in a manner dependent on RAGE. *J Bone Miner Res* 2008;23:1084-96.
 26. Meng E, Guo Z, Wang H, Jin J, Wang J, Wang H, *et al.* High mobility group box1 protein inhibits the proliferation of human mesenchymal stem cells and promotes their migration and differentiation along osteoblastic pathway. *Stem Cells Dev* 2008;17:805-13.
 27. Feng L, Xue D, Chen E, Zhang W, Gao X, Yu J, *et al.* HMGB1 promotes the secretion of multiple cytokines and potentiates the osteogenic differentiation of mesenchymal stem cells through the Ras/MAPK signaling pathway. *Exp Ther Med* 2016;12:3941-7.
 28. Yoshihara-Hirata C, Yamashiro K, Yamamoto T, Aoyagi H, Ideguchi H, Kawamura M, *et al.* Anti-HMGB1 neutralizing antibody attenuates periodontal inflammation and bone resorption in a murine periodontitis model. *Infect Immun* 2018;86. pii: e00111-18.

Lampiran 1. Setifikat Layak Etik

UNIVERSITAS AIRLANGGA FACULTY OF DENTAL MEDICINE
HEALTH RESEARCH ETHICAL CLEARANCE COMMISSION

ETHICAL CLEARANCE CERTIFICATE
Number : 017/HRECC.FODM/II/2017

Universitas Airlangga Faculty Of Dental Medicine Health Research Ethical Clearance Commission has studied the proposed research design carefully, and therefore, shall herewith certify that the research entitled :

"MEKANISME GANGGUAN PROLIFERASI DAN DIFFERENSIASI OSTEOBLAS TERHADAP PENURUNAN KEPADATAN TULANG MANDIBULA PADA PERIODONTITIS KRONIS YANG DIINDUKSI BAKTERI *PORPHYROMONAS GINGIVALIS*"

Principal Researcher : YULIANA MAHDIYAH DA'AT ARINA
Unit/Institution/Place of Research : - Universitas Jember

CERTIFIED TO BE ETHICALLY CLEARED

February 20th, 2017
Chairman,
Prof. N. M. Bianto, Dr. drg. MS. Sp.Perio(K)
Official No.195009081978021001