

PAPER • OPEN ACCESS

Gill and skin pathology of hybrid grouper (*E. fuscoguttatus* x *E. lanceolatus*) infested *Zeylanicobdella arugamensis* worms in different infestations degree

To cite this article: M Nisa *et al* 2021 *IOP Conf. Ser.: Earth Environ. Sci.* **679** 012006

View the [article online](#) for updates and enhancements.



240th ECS Meeting ORLANDO, FL

Orange County Convention Center **Oct 10-14, 2021**



Abstract submission due: April 9

SUBMIT NOW

Gill and skin pathology of hybrid grouper (*E. fuscoguttatus* x *E. lanceolatus*) infested *Zeylanicobdella arugamensis* worms in different infestations degree

M Nisa¹, G Mahasri^{2*}, L Sulmartiwi³

¹Program Study of Fisheries and Marine Biotechnology, Faculty of Fisheries and Marine, Universitas Airlangga, Kampus C Jalan Mulyorejo, Surabaya 60115 East Java, Indonesia

²Department of Fish Health Management and Aquaculture, Faculty of Fisheries and Marine, Universitas Airlangga, Kampus C Jalan Mulyorejo, Surabaya 60115 East Java, Indonesia

³Department of Marine, Faculty of Fisheries and Marine, Universitas Airlangga, Kampus C Jalan Mulyorejo, Surabaya 60115 East Java, Indonesia

*Corresponding author: mahasritot@gmail.com

Abstract. *Zeylanicobdella arugamensis* is one of the marine parasites that attacks Hybrid grouper fish (*E. fuscoguttatus* x *E. lanceolatus*) rearing. Death of infested fish occurs in a period of 3 days after infestation due to secondary infections caused by pathogenic bacteria such as *Vibrio alginolyticus*. Severe infestation of *Zeylanicobdella arugamensis* occurs in Pacific salmon (*Oncorhynchus* spp.) and in hybrid groupers the prevalence is 59%. This research used survey method by sampling 50 hybrid groupers. The study aimed to determine the anatomic and histopathological pathology of the gills and skin of the hybrid grouper at different degrees of infestation. The pathology of gill and skin anatomy of the hybrid grouper infested by *Zeylanicobdella arugamensis* are red, thickening and pale. The highest histopathological damage of the skin at severe infestations of $2.4^a \pm 0.87$ results in erosion, inflammation, congestion and hemorrhage. The highest histopathological damage to the gills at the degree of severe infestation $2.8^a \pm 0.87$ had fusion, telangeactasis and hyperplasia. The Kruskal Wallis test showed a significant degree of infestation on the severity of histopathological changes in the gills and skin of the grouper that is 0.00 ($p \leq 0.05$).

1. Introduction

Hybrid grouper (*E. fuscoguttatus* x *E. lanceolatus*) is a type of marine fish with high economic value and is in great demand by consumers in foreign markets [1]. The productions of grouper fish in Indonesia according to the [2] in 2012 to 2017 were 11,950 tons, 18,864 tons, 13,346 tons, 16,795 tons, 11,504 tons, and 70,294 tons. In 2010, it was the first time in Indonesia to successfully produce grouper fish from hybridization between female tiger grouper (*Epinephelus fuscoguttatus*) and male kertang grouper (*Epinephelus lanceolatus*) [3]. The limiting factor in aquaculture was disease attack. Diseases in fish could be caused by several agents, including parasites, fungi, bacteria and viruses [4]. *Zeylanicobdella arugamensis* was a parasite from sea worms that threatens the aquaculture industry. Infested fish showed clinical symptoms, namely swimming weakly in the column or in the air surface. Fish that are heavily infested show signs of staying at the bottom of the nets or rearing tanks with a very weak condition and



look like thick hair. This worm infestation caused the fish's fins to become thin, reddish, and swelling of the fish skin [5]. [5], *Z. arugamensis* infested fish on the surface of the body, eyes, mouth, respiratory cavity and fins. Subsequent research revealed that *Z. arugamensis* specimens were found in gills and oral fish [6]. The area attached to *Zeylanicobdella arugamensis* would be hemorrhage and swelling of the skin, while the fins would be gravel [5]. According to [7], worm ectoparasite infestation of gills resulted in hyperplasia and fusion of gill lamellae. The infested fish host would be thickening / swelling and pale red in color.

The mortality of fish infested with worm generally occurs within a period of 3 days after infestation because it was followed by secondary infection with pathogenic bacteria such as *Vibrio alginolyticus* [8]. Heavy infestation of *Zeylanicobdella arugamensis* occurred in pacific salmon (*Oncorhynchus* spp.) [9] and became the ectoparasite with the largest infestation in pomfret with a prevalence of 30% and an intensity of 5.6 [10], while in hybrid grouper prevalence was 59% with an average intensity of 6.9 [11].

Based on the many findings of *Zeylanicobdella arugamensis* ectoparasites during cultivation, it was necessary to pathology observation of ectoparasite infested organs so that they could know the pathology changes that occur in the tissue more clearly and precisely. [12], histopathological observations would obtain a picture of infested cells, tissues and organs so that it could be seen the difference between infested and non-infested cells, tissues and organs. Histopathological preparations could also be used to detect disease symptoms early because the fish disease often did not show clinical symptoms. Based on the above problems, this study aims to (1) determine the category of *Zeylanicobdella arugamensis* infestation in the skin and gills of hybrid grouper, (2) Know the anatomical pathology of grouper infested with *Zeylanicobdella arugamensis* with different degrees of infestation, (3) Know the histopathological features gills and skin of grouper fish infected with *Zeylanicobdella arugamensis* with different degrees of infestation. The benefits of the research are (1) Providing scientific information as a consideration in monitoring the health of grouper hybrid so that it can minimize mortality and (2) the results of this research can also be used as a reference for academics.

2. Materials and methods

The research was carried out from October 2019 to February 2020. The research was carried out at the Anatomy and Fish Farming Laboratory and Microbiology Laboratory of the Faculty of Fisheries and Marine Affairs, Airlangga University. This study used a survey method to determine changes in the skin and gill pathology of grouper fish infested with *Zeylanicobdella arugamensis*. Grouper fish measuring 10-20 cm were taken from a concrete pond in Situbondo and then observed the anatomical pathology and infestation of *Zeylanicobdella arugamensis*. Infestations of *Zeylanicobdella arugamensis* were grouped based on the degree of infestation, then the gills and skin that were infested were processed histopathologically. Histopathological analysis and scoring using a 400x magnification camera microscope. Data analysis used IBM SPSS Statistics Base 20 Kruskal Wallis test and Z-Advanced Test. The basis of histopathological scoring could be seen in table 1.

Table 1. Basis of Histopathological Scoring

Scoring	Information
Value 0	If there has been no damage to one visual field (there has been no change in pathology)
Value 1	If there is a histopathological change less than or equal to 25% in one field of view, is a minor level of damage
Value 2	Jika terdapat perubahan histopatologi lebih dari atau sama dengan 26-50% pada satu lapang pandang, merupakan tingkat kerusakan sedang
Value 3	If there is a histopathological change of more than or equal to 51-75% in one field of view, this is the degree of serious damage
Value 4	If there is a histopathological change of more than or equal to 76% in one field of view, it is a very serious degree of damage

Source: Mahasri (2007)

3. Research and discussion

Observation of the anatomical pathology of fish began with the observation of clinical symptoms of fish infected with *Zeylanicobdella arugamensis*, namely swimming weakly in the column or on the surface of the water and staying at the bottom of the rearing tub. Anatomical pathology of gills and skin of grouper fish infected with *Zeylanicobdella arugamensis*, namely redness, swelling, and thickening could be seen in Figure 1.

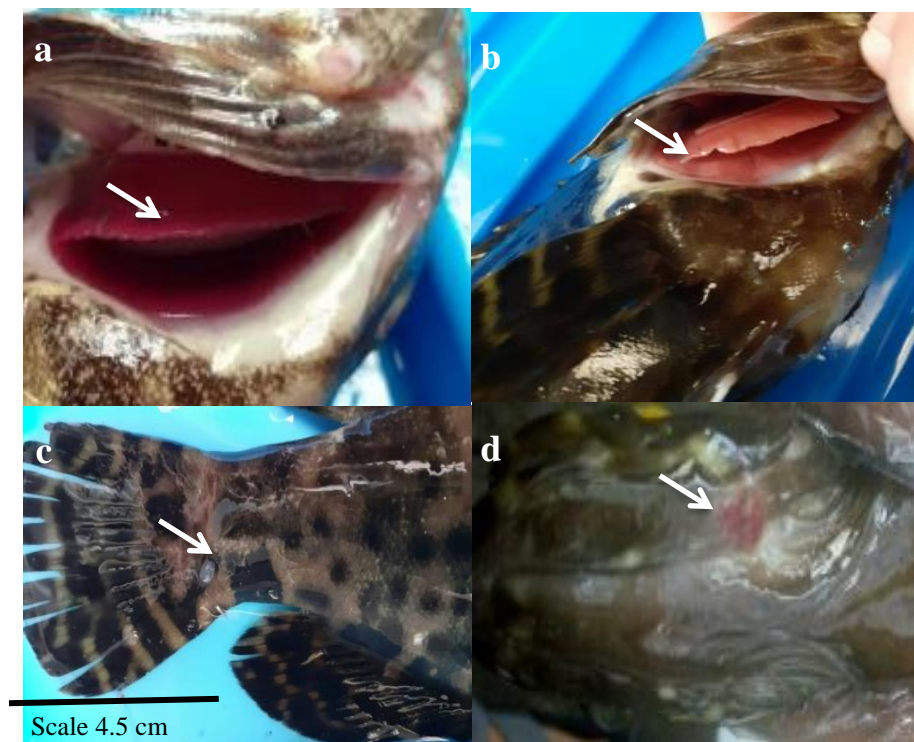

Figure 1. Anatomical pathology of grouper with *Zeylanicobdella arugamensis* infestation. Information: a. thickening of the gill lamellae; b. Sticky and irregular gills; c. Pale skin; d. red and swollen.

The gills of grouper fish infested with *Zeylanicobdella arugamensis* in Figure 1a (20% damage) were thickened because parasite infestation stimulated the growth of lamellar epithelial cells which were very fast (hyperplasia). Hyperplasia resulted epithelial tissue thickening of the filament or near the lamellae base [13]. The gills in Figure 1b (15% damage) became sticky and irregular. The fusion caused the size of the cavity (capillary lumen) to narrow and the cells in the middle of the secondary lamellae shift to the other end of the secondary lamella, causing a sticking [14].

The skin in Figure 1c (25% damage) was pale because these worms sucked red blood cells in the host. Figure 1d (40% damage) skin turning red due to excessive phagocytosis of leukocytes at the area of attachment. Excessive phagocytosis would increase inflammation which was characterized by redness, swelling, heat, pain and loss of function [15].

Histopathological scoring was assessed according to [16], that scoring 1 was mild with a percentage change of less than or equal to 25%, scoring 2 was moderate with a percentage change in histopathology of more than or equal to 26% - 50%, while scoring 3 was severe with a percentage greater than or equal to 51% - 75% of the field of view. The results of the histopathological scoring could be seen in table 2.

Table 2. *Zeylanicobella arugamensis* infestation and the scoring value of tissue damage in gills.

Infestation degree	Skin	Gill
Heavy	2.4 ^a ± 0.87	2.8 ^a ± 0.87
Moderate	1 ^b ± 0.87	2 ^a ± 0.87
Mild	1 ^b ± 0.87	1 ^b ± 0.87

Note: a, b different superscripts show significantly different values ($p < 0.05$)

The Kruskal Wallis test results showed a significant difference of 0.00 ($p \leq 0.05$), meaning that the degree of infestation had a significant effect on the level of histopathological tissue damage to the gill organs and skin of the grouper fish. Based on the Z further test, the skin with heavy infestation of $2.4^a \pm 0.87$ *Zeylanicobdella arugamensis* was significantly different from moderate infestation of $1^b \pm 0.87$ and light $1^b \pm 0.8769$. The histopathological changes of the skin infected with *Zeylanicobdella arugamensis* could be seen in Figure 2.

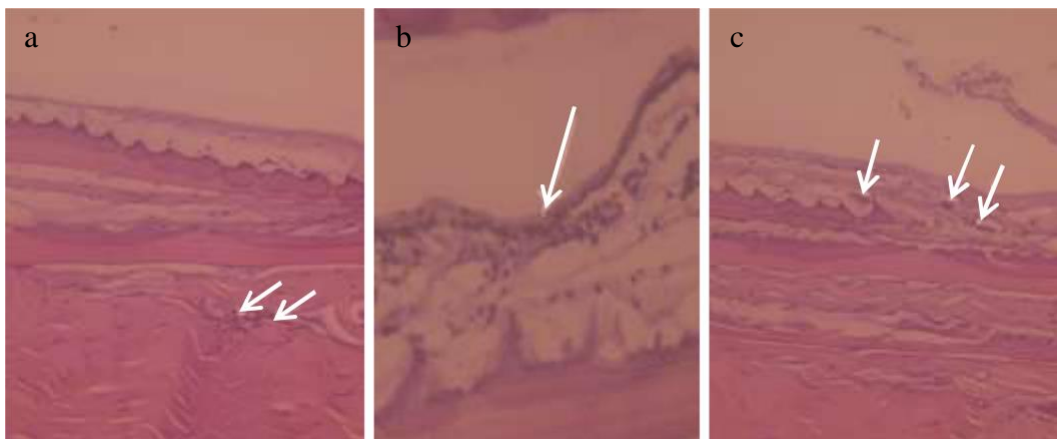


Figure 2. Histopathology of grouper skin. Information; a. Inflammation (i) and Hemorrhage (h) 400x, b. Inflammation (i) 400x, c. Congestion (k)

Histopathological damage to the skin infected with *Zeylanicobdella arugamensis*, namely erosion, inflammation, congestion and hemorrhage. According to [18], the occurrence of the inflammatory process began with tissue damage due to a stimulus that caused the rupture of mast cells (cells containing granules rich in histamine) followed by the release of inflammatory mediators, followed by vasodilation, which caused migration of leukocytes. According to [17] Hemorrhage occurred when the congestion was very severe, the blood vessels would burst and the blood was in an inappropriate place (bleeding). According to [19], the presence of hemorrhage could be caused by damage to blood vessels due to infectious agents circulating in the blood vessels. According to [14] congestion was the presence of blood clots (erythrocytes) in organs. This was in accordance with [20] congestion (blocking) in blood vessels, which was an increase in the amount of blood in the blood vessels, which was indicated by dilated blood capillaries filled with erythrocytes in the vacuolated cranial vessels due to cell damage (necrosis).

The scoring values for tissue damage at the gills in Table 1 indicated that the degree of severe infestation was $2.8^a \pm 0.87$ and $2^a \pm 0.87$ was significantly different from the degree of mild infestation $1^b \pm 0.87$. The histopathological damage of gills infested with *Zeylanicobdella arugamensis* were fusion, telangeactasis and hyperplasia. The histopathological changes of grouper gills infested with *Zeylanicobdella arugamensis* could be seen in Figure 3.

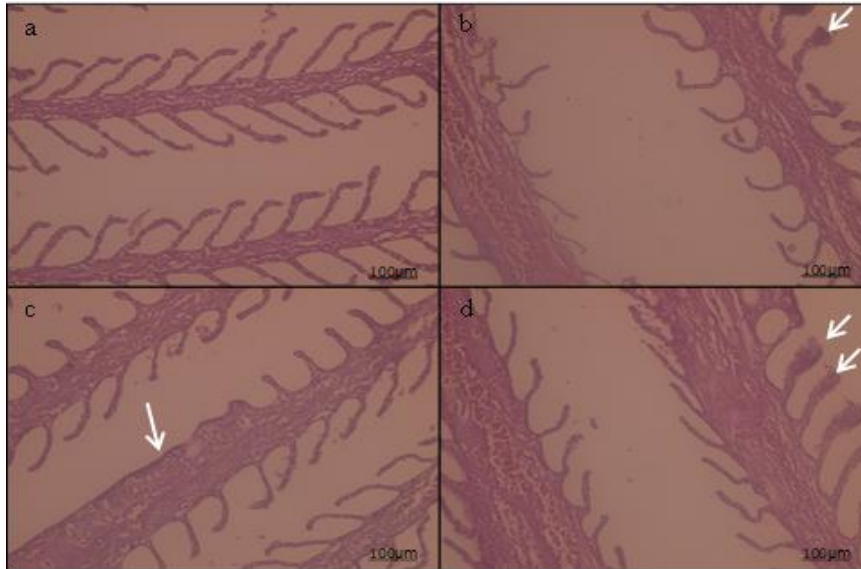


Figure 3. Histopathology of Hybrid grouper gills. Information; a. 400x normal gills, b. Telangeactasis (t) 400x, c. Lamella Fusion (f) 400x, d. Hyperplasia (h) 400x.

Hyperplasia occurred with an increase in the number of secondary lamellar epithelium so that the secondary lamellae were getting bigger and squeezed together, as a result of which the secondary lamellae stick together and fuse [21]. According to Alifia [22] fusion occurred due to reduced elasticity of the epithelium in supporting the organelles in it and caused fractures in the lamellae. Secondary lamella compressions could occur due to hyperplasia of the secondary lamellae that continued to occur, causing mucus cell proliferation [23]. Telangeactasis could occur due to the blocking of the secondary lamellae and there was an enlargement of the secondary lamellae which was permanent so that it looked like a balloon bubble. This typical event usually occurred in fish gills that were in poor water quality, the presence of parasites, accumulation of metabolic waste and chemical pollutants [24].

Measurement of water quality was carried out 2 times, namely when taking hybrid grouper fish samples and maintaining/ acclimatizing them in the aquarium. Table 3 showed the results of water quality measurements.

Table 3. Results of measurement of water quality in Hybrid grouper ponds

Water Quality	Temperature °C	DO mg/L	pH	Salinity g/L	Ammonia (NH ₃) mg/L
Survey 1	31	7	7	31	0.5
Survey 2	28.7	5.67	8	30	1.2
[24]	28-32	min 4	7.5-8.5	24- 33	<0.01

The results of water quality measurements in the Hybrid grouper aquaculture ponds showed that ammonia was quite high for Hybrid grouper culture, namely 1.2. This could be attributed to the feeding of trash fish because the incomplete decomposition of the trash fish feed had the potential to be a disease carrier [25], thereby increasing high waste products, one of which was ammonia.

4. Conclusion

The categories of *Zeylanicobdella arugamensis* infestation on the skin and gills of grouper fish were mild, moderate and severe. Changes in the anatomical pathology of the gills and skin of grouper with *Zeylanicobdella arugamensis* were swollen, red, thickened and pale. Histopathology of the skin of Hybrid grouper with a score of $2.4^a \pm 0.87$ damage with the category of severe infestation resulting in erosion, inflammation, congestion and hemorrhage. The gill histopathology score was $2.8^a \pm 0.87$ with the category of severe infestation resulting in fusion, telangeactasis and hyperplasia.

5. References

- [1] Lopez V G dan Orvay F C 2003 *Hidrobiologica*. 13 321-327.
- [2] Kementerian Kelautan dan Perikanan 2017 *Data Produksi Nasional*. (Jakarta: KKP)
- [3] Nurhayati K , Endang S dan Rahayu E 2014. *Identifikasi dan Prevalensi Ektoparasit Pada Ikan Kerapu Hybrid (Ephinephelus fuscoguttatus-lanceolatus) Hasil Budidaya Keramba Jaring Apung (Kja) Di BPBAP Situbondo dan Gundil Situbondo*, (skripsi). (Malang: Universitas Negeri Malang).
- [4] Kordi, M. 2004. *Penanggulangan Hama dan Penyakit Ikan*. (Jakarta: Rineka Cipta Bina Adiaksara) p 194.
- [5] Cruz-Lacierda E, Toledo J, Tan J and Burreson E 2000 *Aquaculture*. 1 191-196.
- [6] Nagasawa K dan Uyeno D 2009 *J of Biogeography*. 1 125-127.
- [7] Roberts, L. J., dan J. D Morrow. 2001. *Senyawa Analgesik-Antipiretik dan Antiradang serta Obat-Obat Yang Digunakan Dalam Penanganan Pirai, dalam Goodman & Gilman, Dasar Farmakologi Terapi, 10th Edition*. (Bandung : Penerbit Buku Kedokteran). Pp 666- 709.
- [8] Ravi R dan Yahaya Z 2017 *Asian Pacific J of Tropical Biomedicine*. 1 473-477.
- [9] Khan R.A 1982 *Washington* . 1 266–278.
- [10] Azuar A, Raza'i T dan Miranti S 2019 *Intek Akuakultur*. 3 66-79.
- [11] Murwantoko M, Sri L, Condro N 2018 *Biodiversitas J*. 19 1798-1804.
- [12] Mahasri G 2010 *JIPK*. 2 123-124.
- [13] Setyawan N 2013 *Gambaran Mikroanatomi Pada Insang Ikan sebagai indicator Pencemaran Logam Berat di Perairan Kaligarang Semarang*, Skripsi. (Semarang; Universitas Negeri Semarang).
- [14] Asnita, A. 2011. *Identifikasi cacing parasitik dan perubahan histopatologi pada ikan bunglon batik jepara (Cryptocentrus leptoccephalus) dari kepulauan seribu*, Skripsi. (Bogor: Institut Pertanian Bogor).
- [15] Priyanto 2008 *Farmakoterapi Dasar untuk Mahasiswa Keperawatan dan Farmasi*.(Jakarta: Leskonfi).
- [16] Mahasri G 2007 *Protein Membran Immunogenik Zoothamnium penaei sebagai Bahan Pengembangan Immunostimulan pada Udang Windu (Penaeus monodon fabricus) terhadap Zoothamniosis*. Disertasi. (Surabaya: Program Pascasarjana. Universitas Airlangga). P 284.
- [17] Jamin dan Erlangga. 2016 *Acta Aquatica*. 3 46-53.
- [18] Rohman A 2009 *Kromatografi untuk Analisis Obat*, Edisi I. (Yogyakarta: Graha Ilmu).
- [19] Susanti W, Indrawati A dan Pasaribu F 2016 *Jurnal Akuakultur Indonesia*. 15 99- 107.
- [20] Hardi E, Sukenda H, Harris E dan Lusiastuti M 2011 *Jurnal Natur Indonesia*. 13 187-199.
- [21] Yuniar V 2009 *Toksistas Merkuri (Hg) Terhadap Kelangsungan Hidup, Pertumbuhan, Gambaran Darah Dan Kerusakan Organ pada Ikan Nila Oreochromis Niloticus*, Skripsi. (Bogor: Fakultas Perikanan dan Ilmu Kelautan IPB).
- [22] Alifia F 2013 *Jurnal Balik Dewa*. 4 38-45.
- [23] Strzyzewska E, Szarek J, dan Babinska I 2016 *Veterinarni Medicina*. 61 123-132.
- [24] Standar Nasional Indonesia 2014 *Ikan kerapu cantang (Epinephelus fuscoguttatus, Forsskal 1775 >< Epinephelus lanceolatus, Bloch 1790) Bagian 2: Produksi Benih Hibrida*.(Jakarta: BSN). pp 9-10.

[25] Fauzi A, Mokoginta I dan Yaniharto D 2008 *Jurnal Akuakultur Indonesia*. 7 65–70.

6. Acknowledgments

We wish to express our thanks to Brackishwater Aquaculture Development Centre, Situbondo, East Java, Indonesia, for kindly providing fish samples and amenities for this experiment.