

GRAPE SEED EXTRACT INCREASE OSTEOLAST NUMBER IN THE POST- EXTRACTION SOCKET HEALING IN RATS

by Ni Putu Mira Sumarta

Submission date: 28-Apr-2021 09:57AM (UTC+0800)

Submission ID: 1571938250

File name: 6_4877-4881.pdf (173.21K)

Word count: 2783

Character count: 15001

GRAPE SEED EXTRACT INCREASE OSTEOBLAST NUMBER IN THE POST-EXTRACTION SOCKET HEALING IN RATS

Olivia Jennifer Gunardi¹, A. Agustina Putri Kintan², R. Soesanto³ and Ni Putu Mira Sumarta^{3*}

*e-mail : niputu.mira@fkg.unair.ac.id

(Received 11 August 2019, Revised 17 October 2019, Accepted 25 October 2019)

ABSTRACT: Delayed wound healing after tooth extraction causes infections and pains. According to previous studies, grape seed extract accelerates surgical wounds healing process due to its anti-oxidant properties, which triggers the release of vascular endothelial growth factor along with the promotion of fibroblasts to produce more collagen fibres. Furthermore, its anti-inflammatory and anti-microbial properties are effective in wound healing. This study aimed to examine the increased osteoblast as a bone healing indicator in post-extraction socket in wistar rat after the application of grape seed. An experimental study was conducted on four groups of wistar rat, each of which consisted of 6 rats whose lower left first incisor were extracted. The first and second groups which served as the control groups (C) without the application of grape seed extract after tooth extraction was evaluated for 7 (C1) and 14 days (C2). The third and fourth group were the experimental groups (E) with 0.1 ml of 2% grape seed extract administered and evaluated for 7 (E1) and 14 days (E2) respectively. Osteoblast numbers were evaluated using histological examinations with hematoxylin-eosin stains which were observed under light microscope. Furthermore, statistical analysis were carried out using Independent T-test with SPSS 16th version, with a significance level of $p < 0.005$. The results showed that there were significant difference between the control and experiment groups with $p = 0.000$, with a comparative test between the experimental E1 and E2 groups showing a significant difference of $p = 0.002$. Grape seed extract tends to increase osteoblast proliferation in post extraction socket.

Key words : Wound healing, osteoblast induction factor, tooth extractions, grape seed extract.

INTRODUCTION

Bone healing in post extraction sockets involve osteoblastic activity (Todorovic *et al*, 2017), which are bone matrix capable of forming cells, that play important roles in bone healing, enzymes secretion, growth factors and osteoclast regulation. Osteoblasts secrete products such as collagen type I and V, proteoglycans and non-collagen proteins such as sialoprotein and osteopontin. The enzymes secreted by osteoblasts are alkaline phosphatase, pyrophosphatase, etc. The interaction between osteoblasts and hormones plays an important role in the formation and inhibition of osteoclasts (Veni, 2015).

Furthermore, delay in the bone healing after tooth extraction causes late forming of young trabecular bone due to oral bacteria contamination of granulation tissue in the socket, which later increased the risk of wound infection (Khullar *et al*, 2012; Politis *et al*, 2016; Cohen and Cohen-Lévy, 2014). Some therapeutic materials have been used in the bone formation process to restore tissue function after tooth extraction such as include rhBMP-2

(recombinant human bone morphogenetic protein-2), in which creates numerous side effects such as swelling, seroma, and risk of cancer when applied in high doses (Arai *et al*, 2016).

In many countries, herbal plants potensial are used as an alternative treatment which posses more advantages such as lower side effects, variety of useful ingredients, cheaper and used by all society's group compared to modern drugs. One of such medicinal plants which contains flavonoid and proanthocyanidin is red grape (*Vitis vinera*) (Suryaningsih *et al*, 2017).

Grape seed extract (GSE) has an anti-inflammatory effect associated with bone damage by stimulates its formation through osteoblast differentiation activities and inhibiting osteoclast differentiation. GSE produces anti-inflammatory effects by regulating the balance between pro-inflammatory and anti-inflammatory cytokines. GSE prevents collagen damage with a bacteriostatic effect on anaerobic conditions, which tends to significantly reduce the activity of dental biofilms. In addition, GSE acts as an immunomodulator because it contains proanthocyanidin

and flavonoids which functions as antioxidants and anti-cancer (Ozden *et al*, 2017).

Grape seed extract has been widely used in health institutions. According to Park *et al* (2012), it reduces bone damage in rheumatoid arthritis (RA) due to its proanthocyanidin content, which reduces osteoclast activity and increases the differentiation of mature osteoblasts. According to Ozden *et al* (2017) grape seed extract is also used for the treatment of periodontal diseases due to its anti-inflammatory effect, which shortens the inflammatory process and accelerates wound healing (Ozden *et al*, 2017). Another study conducted by Hemmati *et al* (2015) grape seed extract cream with a concentration of 2% has the ability to accelerate the wound healing process on human skin due to the presence of proanthocyanidin in seed extract which triggers the release of vascular endothelial growth factor.

Based on the above reasons, this study was conducted to evaluate the effect of grape seed extract in osteoblast number increase on post extraction socket healing, with the hypotheses that it extract might increase the osteoblast number in post extraction socket healing.

MATERIALS AND METHODS

This was a laboratory experimental study method in post extraction socket of lower left first incisor tooth using wistar rats with a post-test control only study design. The study was approved by the Health Research Ethical Clearance Commission, Universitas Airlangga, Faculty of Dental Medicine. A total of 24 wistar rats (*Rattus norvegicus*), with the age bracket of 2-3 months weighing 150-200 grams, were divided into 4 groups of 2 control and 2 experimental groups with each evaluated on the 7th and 14th day. The samples were then divided into 4 groups, each consisting of 6 wistar rats.

Extract fabrication

Grape seeds were compressed, washed with water, dried in a rotating oven, and isolated. Approximately 1 kg of grape seed was pulverized and extracted using 500 mL of acetone / water solution (with ratio acetone / water = 8/2). The extraction was repeated three times, collected and filtered. The filtrate was concentrated under reduced pressure to remove acetone and extracted three times using 250 mL of ethyl acetate. It was further dehydrated using anhydrous sodium sulfate and the extract concentrated at low pressure to remove the ethyl acetate. The concentrate was dissolved in 500 mL of water and the solution dried with spray to obtain 20 g extract powder. The first and second extracts were mixed to obtain 35 g grape seed extract, which was hydrolyzed by heating in a diluted acid solution (Park *et al*, 2012).

Experimental procedure

A total of 24 wistar rats were divided into 4 groups each consisting of 6 rats an extracted lower left first incisor. The first and second groups served as control groups (C group) without the administration of grape seed extract after tooth extraction. The third and fourth groups were experimental groups (E group) with 0.1 ml of 2% grape seed extract administered.

The rats from every group were first anesthetized with a combination of ketamine and xylazine, with the lower first incisive tooth extracted using klem. After tooth extraction, the C group was evaluated for 7 (C1 group) and 14 days (C2 group), while the E group whose socket was administered 0.1 ml of 2% grape seed extract with syringe was evaluated for 7 (E1 group) and 14 days (E2 group). The socket was also sutured after the application of grape seed extract gel with the wistar rats sacrificed using an over dosage of ether. The specimens were sent for histopathologic tests in a 10% neutral buffered Formalin (Surgipath, USA), processed and embedded in paraffin blocks. In addition, after deparaffinization, these sections were stained with haematoxylin and eosin (HE) for histological examination using light microscope (Nikon Eclipse E200, Japan) with 400x magnification. Finally, the osteoblast number was manually counted per fields of view.

Statistical analysis

Statistical analysis was performed using SPSS 16 version. The data were expressed as mean \pm standard deviation with normality Test performed using Kolmogorov Smirnov, as well as Homogeneity Levene's Test. Assuming the average osteoblast result data was normally distributed and homogeneous, parametric test is performed using Independent T-test with a level of significance set at $p < 0.05$.

RESULTS

Histopathology examination

The osteoblast number in E1 group was higher compared to the C1 and E2 groups. The osteoblast number in E2 group was higher than in the C2 group, while C2 was higher C1. The black arrow in Fig. 1 shows osteoblast cells.

Statistical analysis

This study was performed using 24 wistar rats (*Rattus norvegicus*), which showed that the average osteoblast number in E1 group was 26.8 ± 1.2 and 22.4 ± 2.4 in E2, while in C1 group, it was 14 ± 0.9 and 16 ± 1.0 in C2. The result is shown in Fig. 2.

The research data were evaluated with normality

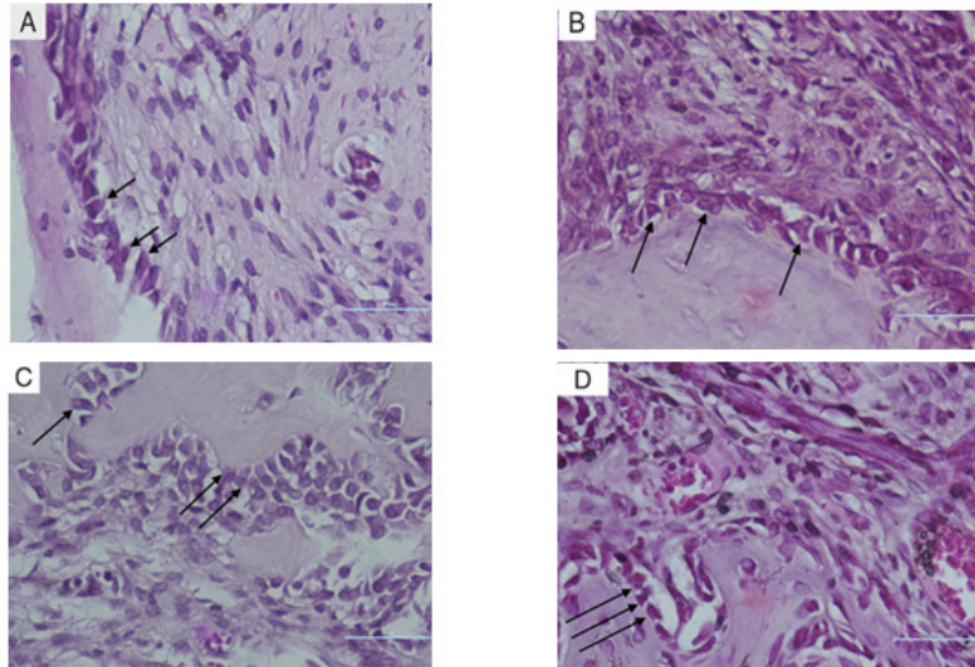


Fig. 1 : Histopathology examination illustration of post extraction socket. (A) After 7 days observation in C1 group, (B) after 7 days observation in E1 group, (C) after 14 days observation in C2 group, (D) after 14 days observation in E2 group (Black arrow showed osteoblast cells with HE staining and evaluated using light microscope 400x magnification).

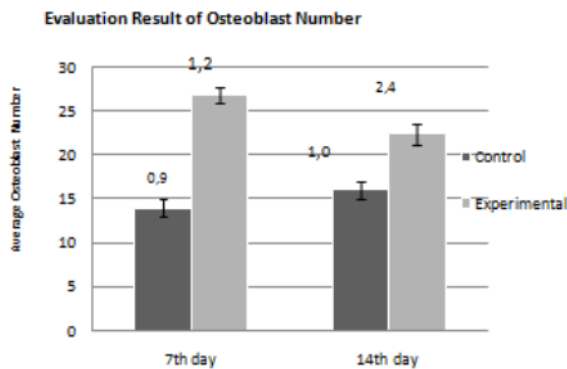


Fig. 2 : Column chart showed mean and standard deviation of osteoblast number.

test using One Sample Kolmogorov-Smirnov to determine the normal data distribution in each group. Based on that test, the research data distribution considered normal. The homogeneity test was then performed using Levene's Test. The obtained results were 0.526 and 0.088, above $p > \alpha$ ($\alpha = 0.05$), with a homogeneous data. Independent T-test was then conducted to compare the osteoblast number between groups C and E, and between E1 and E2. The obtained results were 0.002 with $p < \alpha$ ($\alpha = 0.05$), which showed the significant difference between E1 and E2. The results are presented in Table 1.

DISCUSSION

Significant difference between groups E and C in this study showed that the osteoblast number of E group was higher than C group with an increase of osteoblast number in the experimental group. This increase was due to the inhibitory effect of grape seed extract on osteoclasts and its stimulating effect on osteoblast (Gurger *et al*, 2019). According to Toker's study, grape seed extract prevented alveolar bone loss and this improvement was due to the increase in osteoblast cell counts and mineralization (Toker *et al*, 2018).

Grape seed extract is a strong antioxidant (*Vitis vinifera*) with a polyphenolic structure with a wide range of biological activity (Toker *et al*, 2018), used to stabilize free radicals in the environment and capable of inducing calcium absorption and fracture healing (Gurger *et al*, 2019). The main content of grape seeds (*Vitis vinifera*) is proanthocyanidin and flavonoid, which act as antioxidant and anti-inflammatory (Baldim *et al*, 2017).

Proanthocyanidins protects against oxidant injury during ischemia/ reperfusion in the heart, to scavenge oxygen free radicals *in vitro* or *in vivo*. Besides the antioxidant activity, proanthocyanidins exhibit immunostimulating, anticarcinogenic, antiallergic, anti-inflammatory, anti-bacterial or viral and cardioprotective

Table 1 : The result of statistical analysis.

Group	Mean	Standard Deviation	One-Sample Kolmogorov-Smirnov Test (P)	Levene Test (P)	Independent T-Test (C:E)	Independent T-Test (E1 : E2)
C1	14	0.9	0,968	-	-	-
E1	26,8	1,2	0,810	-	-	-
C2	16	1,0	0,926	-	-	-
E2	22,4	2,4	0,983	-	-	-
7 th day	-	-	0,273	0,526	,000	,000
14 th day	-	-	0,410	0,088	,000	,002

effects. It also inhibits platelet aggregation, capillary permeability and fragility and to modulate the activity of some enzymes systems including cyclooxygenase and lipoxygenase (Zhang *et al*, 2014). Proanthocyanidin (PA) in grape seed extract demonstrated its anti-inflammatory by inhibiting TNF- α (Tumor Necrosis Factor Alpha), IL-1 β (interleukin 1 beta), reduce TH-1, (T Helper Cell 1) and TH-17A levels (T Helper Cell 17 A), while increasing the TH-2 levels (T Helper Cell 2) by regulating the releases of pro- and anti-inflammatory cytokines in the inflammatory region surrounding the mRNA expressions of IL-10 and TGF- β (Ozden *et al*, 2017). This biological activity helps to accelerate the proliferation process to hasten the wound healing process. This is consistent with Park's study, which states that proanthocyanidin reduces bone damage and osteoclast cell activity due to rheumatoid arthritis (RA), with increase in osteoblast activity (Park *et al*, 2012).

Flavonoid stimulates bone healing due to its phytoestrogenic effect. It is known that calcium intake with flavonoids, inhibits bone resorption with an important effect on bone formation (Gurger *et al*, 2019). Flavonoids tend to prevent damage caused by free radicals by reducing ROS (reactive oxygen species) and activating antioxidant enzymes. The antioxidant enzymes activated include glutathione-S-transferase (GST), glutathione reductase (GSR), superoxide dismutase (SOD) and glutathione peroxidase (GHSpx). In addition flavonoids are also able to reduce ROS through MCA (metal chelating activity), oxidase inhibition, and migration of oxidative stress caused by Nitric Oxide (NO) (Baldim *et al*, 2017).

Furthermore, it reduces the osteoblast number at the E2 group when compared to E1 due to the possibility of seeing osteocytes on the 10th day. The maturation process from osteoblasts to osteocytes usually occurs for 19 days (Tamara *et al*, 2006) and according to Toker *et al* (2018) grape seed extract significantly reduced alveolar bone loss by decreasing the inflammatory cell infiltration. Furthermore, the MMP-8 expression, osteoblast counts

and bone mineralization are increased (Toker *et al*, 2018).

CONCLUSION

The results from the present study showed that application of 2% grape seed extract in post extraction socket failed to increase the osteoblast number. Further studies are required to evaluate the effect of different dosages and application times of grape seed extract to establish safety in its clinical use.

REFERENCES

- Arai Y, Aoki K, Shimizu Y, Tabata Y, Ono T, Murali R, Omata S M and Wakabayashi N (2016) Peptide-induced de Novo Bone Formation after Tooth Extraction Prevents Alveolar Bone Loss in a Murine Tooth Extraction Model. *Journal of Pharmacology* 783(5), 89.
- Baldim J L, Alcântara B G V D, Domingos O D S, Soares M G, Caldas I S, Novaes R D, Oliveira T B, Lago J H G and Chagas-Paula D A (2017) The Correlation between Chemical Structures and Antioxidant, Prooxidant, and Antitrypanosomatid Properties of Flavonoids. *Oxidative medicine and Cellular Longevity* p. 1-12.
- Cohen N and Cohen-Lévy J (2014) Healing Processes Following Tooth Extraction in Orthodontic Cases. *J Dentofacial Anom Orthod*. 17(304), 7.
- Gurger M, Yilmaz E, Yilmaz S, Once G, Konuk M, Kaya E, Say Y, Artas G and Artas H (2019) Grape Seed Extract Supplement Increases Bone Callus Formation and Mechanical Strength: An Animal Study. *Journal of Orthopaedic Surgery and Research* 14(206), 7.
- Hemmati A A, Bahadoram M and Houshmand G (2015) The Topical Effect of Grape Seed Extract 2% Cream on Surgery Wound Healing. *Global Journal of Health Science* 7(3), 52-57.
- Khullar S, Mittal A and Datta P (2012) Healing of Tooth Extraction Socket. *Heal Talk*. 4(5), 38.
- Ozden F O, Sakallioslu E E, Sakallioslu U, Ayas B and Erisgi Z (2017) Effect of Grape Seed Extract on Periodontal Disease: An Experimental Study in Rats. *Journal of Applied Oral Science* 25(2), 122.
- Park J S, Park M K, Oh H J, Woo Y J, Lim M A, Lee J H, Ju J H, Jung Y O, Lee Z H, Park S H, Kim H Y, Cho M L and Min J K (2012) Grape-Seed Proanthocyanidin Extract as Suppressors of Bone Destruction in Inflammatory Autoimmune Arthritis. *PLoS One* 7(12), 2, 8.
- Politis C, Schoenaers J, Jacobs R and Agbaje J O (2016) Wound Healing Problems in the Mouth. *Frontiers in Physiology* 7(507),

- 5,7.
- Suryaningsih A, Chumaeroh S and Benyamin B (2017) Uji Efektifitas Ekstrak Biji Anggur (*Vitis Vinifera*) Terhadap Pertumbuhan *Candida albicans* Secara *In Vitro*. *Medali Journal* **2**(1), 6.
- Tamara A, Brian K and Eckhard P (2006) Buried Alive : How Osteoblast Become Osteocytes. *Wiley-Lies Inc.* **235**, 184.
- Todorovic K, Javanovic G, Todorovic A, Mitic A, Stojiljkovic N, Llic S, Stojanovic N and Stojnev S (2017) Effects of Coenzyme Q10 Encapsulated in Nanoliposomes on Wound Healing Processes after Tooth Extraction. *Journal of Dental Science* p. 2.
- Toker H, Yuce H B, Alpan A L, Gevrek F and Elmastas M (2018) Morphometric and Histopathological Evaluation of the Effect of Grape Seed Proanthocyanidin on Alveolar Bone Loss in Experimental Diabetes and Periodontitis. *Journal of Periodontal Research* p. 1,6.
- Veni M A C (2015) Interaction between Bone Cells in Bone Remodelling. *Journal of Academy of Dental Education* **2**, 1-6.
- Zhang Z, Zheng L, Zhao Z, Shi J, Wang X and Huang J (2014) Grape Seed Proanthocyanidins Inhibit H₂O₂-induced Osteoblastic MC3T3-E1 Cell Apoptosis via Ameliorating H₂O₂-induced Mitochondrial Dysfunction. *The Journal of Toxicological Sciences* **39**(5), 804.

GRAPE SEED EXTRACT INCREASE OSTEOBLAST NUMBER IN THE POST-EXTRACTION SOCKET HEALING IN RATS

ORIGINALITY REPORT

18%

SIMILARITY INDEX

10%

INTERNET SOURCES

17%

PUBLICATIONS

0%

STUDENT PAPERS

PRIMARY SOURCES

1

www.jstage.jst.go.jp

Internet Source

2%

2

H. Toker, H. Balci Yuce, A. Lektemur Alpan, F. Gevrek, M. Elmastas. "Morphometric and histopathological evaluation of the effect of grape seed proanthocyanidin on alveolar bone loss in experimental diabetes and periodontitis", Journal of Periodontal Research, 2018

Publication

2%

3

Hemmati, Ali Asghar, Maryam Foroozan, Gholamreza Houshmand, Zahra Beigom Moosavi, Mohammad Bahadoram, and Nader Shakiba Maram. "The Topical Effect of Grape Seed Extract 2% Cream on Surgery Wound Healing", Global Journal of Health Science, 2014.

Publication

2%

4

M. Ashwin Chandra Veni, P. Rajathi. "Interaction between Bone Cells in Bone

1%

Remodelling", Journal of Academy of Dental Education, 2017

Publication

-
- | | | |
|---|---|-----|
| 5 | josr-online.biomedcentral.com
Internet Source | 1 % |
| 6 | worldwidescience.org
Internet Source | 1 % |
| 7 | Eric Priyo Prasetyo, Ira Widjiastuti, Febriastuti Cahyani, Mefina Kuntjoro et al. "Cytotoxicity of Calcium Hydroxide on Human Umbilical Cord Mesenchymal Stem Cells", Pesquisa Brasileira em Odontopediatria e Clínica Integrada, 2020
Publication | 1 % |
| 8 | Yuki Arai, Kazuhiro Aoki, Yasuhiro Shimizu, Yasuhiko Tabata et al. "Peptide-induced de novo bone formation after tooth extraction prevents alveolar bone loss in a murine tooth extraction model", European Journal of Pharmacology, 2016
Publication | 1 % |
| 9 | Tjuk Risantoso, Syaifullah Asmiragani, Tresna Angga Basunanda, Marvin Anthony Putera, Andhika Yudistira. "Combination of Chondroitin Sulfate and Hyaluronic Acid Increases Amount of Fibroblast, Collagen and Decreases Adhesion of Achilles Tendon after Repair", Journal of Arthroscopy and Joint | 1 % |

Surgery, 2020

Publication

10 pesquisa.bvsalud.org 1 %
Internet Source

11 ijpsr.com <1 %
Internet Source

12 kclpure.kcl.ac.uk <1 %
Internet Source

13 M.I. Yousef, A.A. Saad, L.K. El-Shennawy.
"Protective effect of grape seed
proanthocyanidin extract against oxidative
stress induced by cisplatin in rats", Food and
Chemical Toxicology, 2009 <1 %
Publication

14 Submitted to Universitas Airlangga <1 %
Student Paper

15 www.mysciencework.com <1 %
Internet Source

16 Alimohammad Izadpanah, Sima Soorgi, Neda
Geraminejad, Mahdi hosseini. "Effect of grape
seed extract ointment on cesarean section
wound healing: A double-blind, randomized,
controlled clinical trial", Complementary
Therapies in Clinical Practice, 2019 <1 %
Publication

17 www.scielo.br
Internet Source

<1 %

18

www.science.gov

Internet Source

<1 %

19

"Natural Oral Care in Dental Therapy", Wiley, 2020

Publication

<1 %

20

Ahmed Zayed, Marwa T. Badawy, Mohamed A. Farag. "Valorization and extraction optimization of Citrus seeds for food and functional food applications", Food Chemistry, 2021

Publication

<1 %

21

Aysan Lektemur Alpan, Alper Kızıldağ, Melih Özdede, Nebi Cansın Karakan, Özlem Özmen. "The effects of taxifolin on alveolar bone in experimental periodontitis in rats", Archives of Oral Biology, 2020

Publication

<1 %

22

Juminten Saimin, Hendy Hendarto, Soetjipto Soetjipto. "The Effect of Tomato Juice in Increasing Ki-67 Expression and Epithelial Thickness on The Vaginal Wall of Menopausal Rats", The Indonesian Biomedical Journal, 2019

Publication

<1 %

23 Thalia del Rosario Loyo Casao, Camila Graça Pinheiro, Mariáurea Matias Sarandy, Ana Caroline Zanatta et al. "Croton urucurana Baillon stem bark ointment accelerates the closure of cutaneous wounds in knockout IL-10 mice", Journal of Ethnopharmacology, 2020
Publication <1 %

24 link.springer.com
Internet Source <1 %

25 www.mdpi.com
Internet Source <1 %

26 www.tandfonline.com
Internet Source <1 %

27 Grapes and Health, 2016.
Publication <1 %

28 Zhifeng Zhang, Leigang Zheng, Zhenqun Zhao, Jun Shi, Xing Wang, Jian Huang. "Grape seed proanthocyanidins inhibit H2O2-induced osteoblastic MC3T3-E1 cell apoptosis via ameliorating H2O2-induced mitochondrial dysfunction", The Journal of Toxicological Sciences, 2014
Publication <1 %

Exclude bibliography On

GRAPE SEED EXTRACT INCREASE OSTEOBLAST NUMBER IN THE POST-EXTRACTION SOCKET HEALING IN RATS

GRADEMARK REPORT

FINAL GRADE

/0

GENERAL COMMENTS

Instructor

PAGE 1

PAGE 2

PAGE 3

PAGE 4

PAGE 5
