

Closed reduction in the  
treatment of neglected  
mandibular fractures at the  
Department of Oral and  
Maxillofacial Surgery,  
Universitas Airlangga

*by Ni Putu Mira Sumarta*

---

**Submission date:** 28-Apr-2021 01:09PM (UTC+0800)

**Submission ID:** 1572111329

**File name:** 16.\_Artikel\_Closed\_reduction\_MRA.pdf (932.54K)

**Word count:** 3847

**Character count:** 21489

## Closed reduction in the treatment of neglected mandibular fractures at the Department of Oral and Maxillofacial Surgery, Universitas Airlangga

Olivia Jennifer Gunardi, Riska Diana, David Buntoro Kamadjaja and Ni Putu Mira Sumarta

### ABSTRACT

**Background:** The mandible is one of the bones most affected by facial fractures commonly resulting from trauma to the face. The ultimate goal of treatment is to re-establish the pre-injury dental occlusion (bite), mandibular anatomy and jaw function of the patient. Treatment approaches range from conservative non-invasive management by 'closed' reduction and immobilization using intermaxillary fixation (IMF) to the more invasive surgery-based 'open' reduction incorporating an internal fixation approach. **Purpose:** The purpose of this case series was to describe the closed reduction method as a form of treatment in cases of neglected mandibular fracture. **Cases:** Four cases of single or multiple mandibular fracture were presented. **Case management:** All of the cases were managed using a closed reduction method and IMF. **Conclusion:** A closed reduction method in this case series produced encouraging results and could be considered an alternative in the treatment of neglected mandibular fractures with displacement.

**Keywords:** closed reduction; mandibular fracture; neglected mandibular fracture

**Correspondence:** Ni Putu Mira Sumarta,  
E-mail address: [niputu.mira@fkg.unair.ac.id](mailto:niputu.mira@fkg.unair.ac.id)

### INTRODUCTION

The mandible, despite being the largest and strongest facial bone, is one of the most affected by fractures with an incidence rate of 36-70%. These occur most frequently to males in their thirties as a result of a facial trauma.<sup>1-3</sup> Assault constitutes the most common cause of mandibular (jaw) fractures at 48-65%, followed by motor vehicle accidents, falls and gunshot wounds.<sup>1,4</sup> This high rate of fractures can be explained by the unique characteristics of the mandible such as its prominence, unprotected facial position, mobility and limited bone support when compared to other facial bones.<sup>3,5,6</sup> The mandible is the only mobile facial bone and in cases of injury to the maxillofacial region it is more vulnerable than the mid-face to fractures.<sup>7</sup>

Depending on the direction and force of the trauma, fractures of the mandible frequently occur at different sites.<sup>7</sup> The most commonly fractured areas are the body (29%), followed by the condyle (26%), angle (25%), and symphysis

(17%), while the ramus (4%) and coronoid process (1%) are rarely fractured. The most common causes of fractures to the condyle, symphysis and angle include car accidents, motorcycle accidents, and physical assault respectively.<sup>8</sup> Mandible fractures can be complete or incomplete, open or closed, single, double, or comminuted and the result of direct or indirect mechanisms.<sup>4</sup> Depending on the location of the fracture, the patient can present with pain exacerbated by jaw movement, trismus, dental malocclusion, swelling, bleeding, external and intraoral tenderness, dysphagia, and step deformity at the fracture site.<sup>2,8</sup> Damage to the inferior alveolar nerve may induce anesthesia in the lower lip.<sup>8</sup> Furthermore, mandibular fractures can cause a variety of impairments, including temporomandibular joint syndrome, poor mastication, malocclusion, and chronic pain.<sup>6</sup>

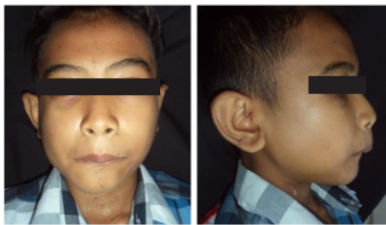The ultimate goal of treatment is to re-establish the preinjury dental occlusion (bite), mandibular anatomy and jaw function of the patient.<sup>2,9</sup> Reduction techniques in mandibular fracture treatment may be classified as open

or closed depending on the presence or absence of direct visual access to the fracture site. Closed reduction allows manipulation of the fracture segments taking advantage of dental occlusion without direct visual access, whereas open reduction involves direct visual access to the fracture site through a surgical incision. Closed reduction and maxillomandibular fixation may be performed using splints in the form of bonded orthodontic brackets, arch bars, direct wires or eyelet wires. Open reduction and internal fixation involves the use of wires, plates and other hard-wares placed directly across the fractured site by means of surgical access.<sup>10</sup> Treatment of mandible fractures with a closed reduction method is referred to as non-surgical treatment, while the fracture treatment performed without surgical procedures by manual repositioning of the fragment, gradual repositioning of the teeth and immobilization of the jaw using intermaxillary fixation (IMF), is commonly termed maxillomandibular fixation (MMF).<sup>11</sup>

In order to achieve optimum results, the management of neglected mandible fractures with large displacement is ideally performed using open reduction internal fixation (ORIF). However, if the patient refuses to be treated with the ORIF method due, for example, to socio-economic reasons, or limitations on general anesthesia facilities exist, then the close reduction method could represent an alternative treatment option. Conservative treatment, when properly indicated, allows for appropriate patient recovery, while reducing both surgery-related morbidity and the cost of resources.<sup>3</sup> This case series aims to provide information on successful treatment involving the use of the close reduction method in four cases of neglected mandibular fracture.

## CASES

Case 1: a 13-year-old male attended the Dental Hospital of the Faculty of Dental Medicine at Universitas Airlangga complaining chiefly of difficulty in chewing and closing his mouth as the result of a traffic accident 11 days earlier. The patient had been thrown off a moving motorcycle, his chin subsequently making hard contact with the asphalt. The patient was examined in hospital shortly after the accident without any treatment having been initiated. The individual in question had a history of fainting during the



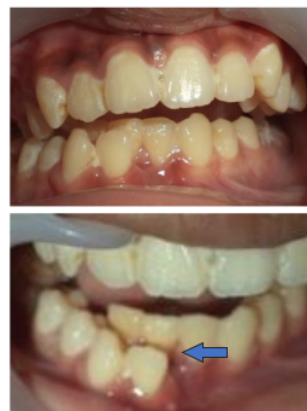**Figure 1.** Extraoral clinical examination showing facial asymmetry.

incident, although this was not accompanied by resulting nausea or vomiting. Moreover, he had no history of diabetes or drug allergies.

Extraoral examination confirmed facial asymmetry and swelling of the mandibular region, right superior palpebral hematoma and the right maxillary region, mandibular retrusion, limited mouth opening, step-off deformities and tenderness on palpation in the right mandibular parasymphysis region (Figure 1). Intraoral examination confirmed ecchymosis in the anterior region of the mandible, malocclusion, anterior and posterior open bite, right posterior scissor bite, displacement in the 41 and 42 regions, 10 mm overlapping, tooth mobility in the 41 region and tenderness on palpation in the mandibular symphysis region (Figure 2). A panoramic radiograph indicated a vertical fracture line to the inferior border of the mandible between regions 41 and 42. Symphysis appeared separate and there was overlap of teeth 41, 31 with teeth 42, 43 (Figure 3). On the basis of the clinical and radiological examination, this case was diagnosed as a mandibular symphysis fracture with displacement.

Case 2: A 15-year-old male attended the Dental Hospital in the Faculty of Dental Medicine of Universitas Airlangga complaining chiefly of difficulty in closing his mouth for the previous three days due to being hit on his left cheek in a school fight. No history of fainting, nausea or vomiting was reported.

Extraoral clinical examination showed facial asymmetry, minimal swelling in the left buccal region and crepitation and tenderness in the left mandibular condyle region (Figure 4). Intraoral clinical examination showed limited mouth opening, malocclusion, anterior open bite, redness and minimal swelling, instability in the posterior mandibular region and step off deformity in the angle of the mandible region. A panoramic radiograph showed a fracture line in the left posterior mandible region distally from tooth 38 and



**Figure 2.** Intraoral clinical examination demonstrating anterior and posterior open bite, in addition to fracture with displacement in regions 41 and 42 and two overlapping mandibular incisors (blue arrow).

in the left mandibular condyle region. Following clinical and radiological examination, this case was diagnosed as fractures to the left mandibular angle and condyle.

Case 3: A 41-year-old male came to dental hospital of the Faculty of Dental Medicine at Universitas Airlangga with the chief complaints of difficulty in closing the mouth and gingival injury due to being hit on his chin and cheek by a stranger since three days prior to attending the hospital.

Extraoral clinical examination showed facial asymmetry, swelling in the left parasymphysis and mandibular ramus region, deviation of the mandible to the right during mouth opening, as well as step off deformity in the parasymphysis and left mandibular ramus region with tenderness on palpation (Figure 5). Intraoral clinical examination confirmed limited mouth opening, laceration to the gingival mucosa of the anterior labial mandible, malocclusion,

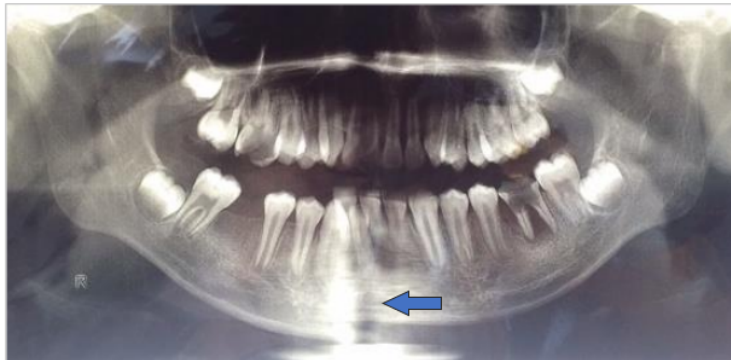

Figure 3. Panoramic radiograph indicating vertical fracture line (blue arrow).

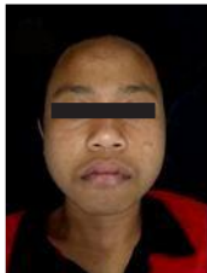

Figure 4. Extraoral clinical examination showing minimal facial asymmetry and submental swelling.

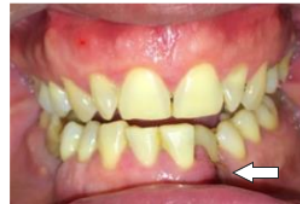

Figure 5. Intraoral clinical examination showed laceration on the anterior left lower gingival mucosa (white arrow), right edge-to-edge occlusion, laceration with displacement in the 31 and 33 regions and step off deformity  $\pm$  3 mm inferiorly (white arrow).

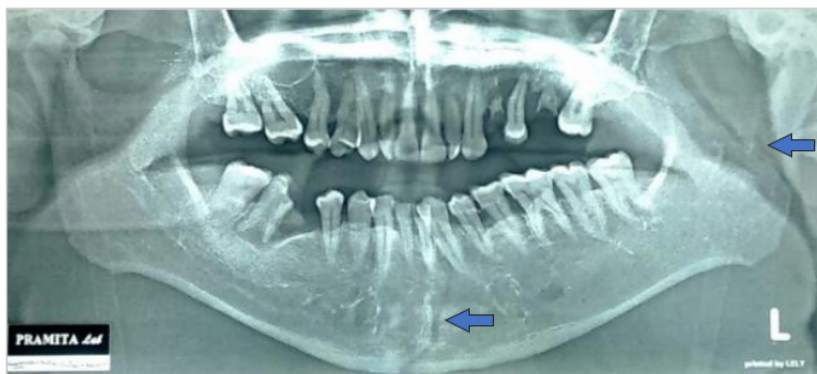
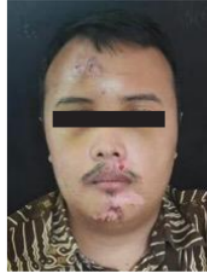
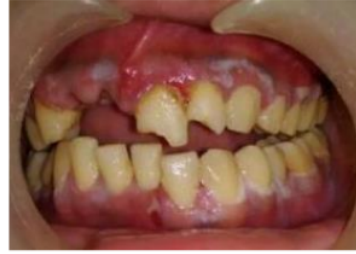
Figure 6. Panoramic radiograph showed fracture line in the left parasymphyseal mandible region mesial to tooth 33, and in the ascending ramus of the left mandible region to the left of the mandibular coronoid process (blue arrow).

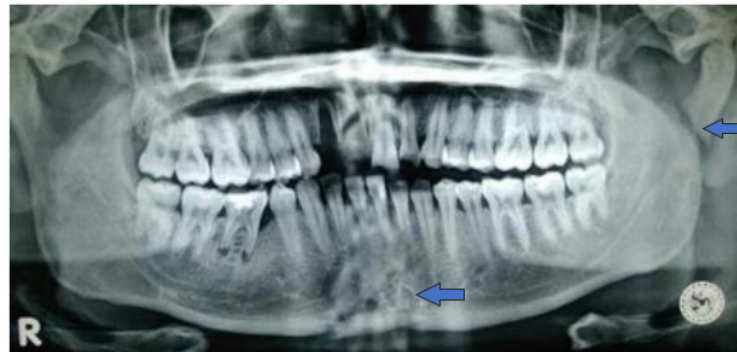anterior and posterior open bite, fracture with displacement in the 31 and 33 regions, step off deformity of  $\pm 3$  mm, and instability in the left posterior mandibular region. A panoramic radiograph showed a fracture line stretching mesially in the left parasymphysis mandible from tooth 33, and in the region of the ascending ramus of the left mandible to the left mandibular coronoid process (Figure 6). Following clinical and radiological examination, this case was diagnosed as left parasymphysis and ascending ramus of the mandible fracture.



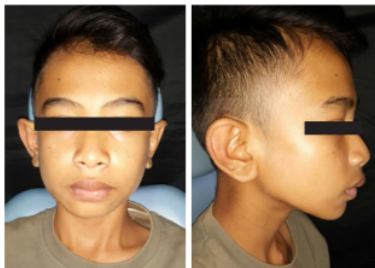**Figure 7.** Extraoral clinical examination indicating minimal facial asymmetry, laceration on and swelling in the submental region.



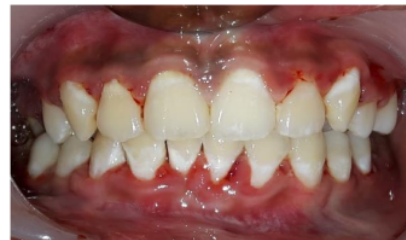**Figure 8.** Intraoral clinical examination indicating laceration to the anterior lower gingival mucosa and  $\pm 1$  mm inferior displacement in the 32 region, malocclusion, anterior and posterior open bite.



**Figure 9.** Panoramic radiograph showed oblique fracture line in the left parasymphysis mandible region to the distal tooth 31 region, and left condyle region (blue arrow).



**Figure 10.** Extraoral clinical examination on 86<sup>th</sup> day showed no facial asymmetry.



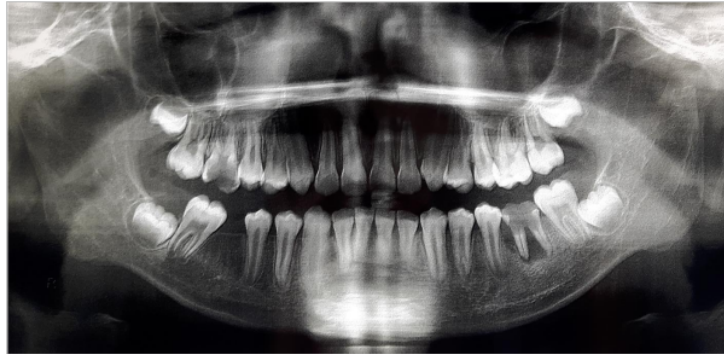**Figure 11.** Intraoral clinical examination on 86<sup>th</sup> day showed normal occlusion without anterior and posterior open bite.

and radiological examination, this case was diagnosed as one of mandibular symphysis fracture, comminuted anterior mandible fracture, and left subcondylar fracture.

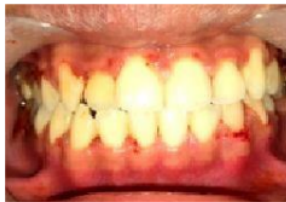**CASE MANAGEMENT**

Case 1: closed reduction was performed using an arch bar in the teeth 15 to 26, 35 to 41 and 42 to 45 regions, while elastic bands were employed to reposition bone fragment.

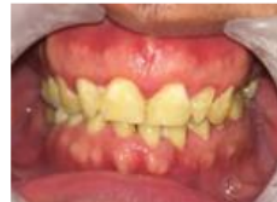During the first three days, elastic band application was performed laterally to reposition two separate bone fragments. During the subsequent three days, the traction direction was changed first to anterior and then to medial until the 20<sup>th</sup> day. The IMF was subsequently changed using wire in the anterior and posterior region up to the 34<sup>th</sup> day, which was then replaced by elastic bands up to the 48<sup>th</sup> day. At that point, the IMF was removed, and the patient instructed to perform mouth opening and closing exercises in addition to following a soft diet for the ensuing



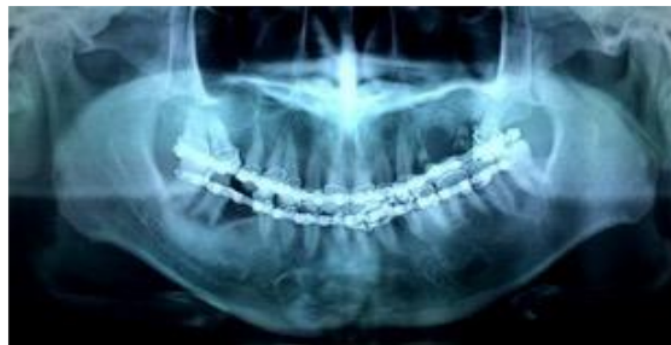**Figure 12.** Panoramic radiograph after treatment showed union of symphysis mandible without fracture line.



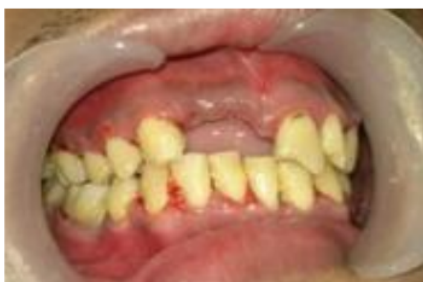**Figure 13.** Intraoral clinical examination on 6<sup>th</sup> week showed normal occlusion without anterior and posterior open bite.



**Figure 14.** Intraoral clinical examination on 12<sup>th</sup> week showed normal occlusion without anterior and posterior open bite, and no step off deformity in the 33 region.



**Figure 15.** Panoramic radiograph after treatment showed no fracture line in the parasymphysis and left ascending ramus of the mandible region.



**Figure 16.** Intraoral clinical examination on 8<sup>th</sup> week showed normal occlusion without anterior and posterior open bite.

two weeks. On the 86<sup>th</sup> day, the subject presented no facial asymmetry (Figure 10) and normal occlusion (Figure 11 and 12).

Case 2: closed reduction was performed using an arch bar on the teeth 16 to 26 and 37 to 46. After direct repositioning, fracture fragment stabilization was performed with IMF by means of elastic bands. Facial asymmetry was corrected on the third day, there was no open bite on the tenth day, centric occlusion was achieved on the 17<sup>th</sup> day, and step off deformity or crepitation in the angle and condyle mandible was absent on the 28<sup>th</sup> day. Following removal of the IMF, the patient was instructed to perform mouth opening and closing exercises. On the 45<sup>th</sup> day, he did not report any pain and demonstrated a normal ability to close his mouth and masticate (Figure 13).

Case 3: debridement and suturing of wound laceration were first performed followed by closed reduction using an arch bar in the teeth 17 to 27 region, and 37 to 47 region. After direct repositioning, fracture fragment stabilization was performed with IMF using elastic bands. Facial asymmetry was corrected during the 1<sup>st</sup> week, while no anterior or posterior open bite was evident during the 4<sup>th</sup> week. Following removal of the IMF during the 8<sup>th</sup> week, the patient was instructed to perform mouth opening and closing exercises for a period of four weeks. During the 12<sup>th</sup> week, he demonstrated the ability to open and close his mouth normally (Figure 14). Moreover, a panoramic radiograph failed to detect a fracture line (Figure 15).

Case 4: closed reduction by means of an arch bar was performed for six weeks and IMF for four weeks. A two-week regime of mandible movement exercises was prescribed for the patient. The aim of this treatment included pain alleviation, accepted occlusion, maximum intercuspation (35-40 mm), and facial symmetry. On the 40<sup>th</sup> day, no anterior or posterior open bite was observable, while the subject demonstrated the ability to open and close mouth his normally during the 8<sup>th</sup> week (Figure 16). Evaluations conducted over a period of three months confirmed no post-treatment complications.

## DISCUSSION

Regardless of age, the pre-injury skeletal and dentoalveolar anatomy and function have to be re-established by anatomic reduction of fractures due to occlusion.<sup>12</sup> Treatment approaches range from conservative non-invasive management by 'closed' reduction and immobilization using intermaxillary fixation (IMF), to the more invasive surgical 'open' reduction with internal fixation approach.<sup>2</sup> Mandibular fracture without displacement and malocclusion are managed by close observation, a liquid to soft diet, avoidance of physical activities and analgesics.<sup>12</sup> Intermaxillary mandibular fixation (IMF) reestablishes the patient's pre-surgery occlusion and, in certain cases, can stabilize the bone sufficiently to enable healing to take place. This technique can be performed in cases such as those involving favorable fractures, stable occlusion with sufficient dentition, and multiple small comminuted fractures.<sup>13</sup>

This case series report discusses complex neglected mandible fractures. All four patients agreed to be treated with the closed reduction technique, although ideally an open reduction method using ORIF was adopted to obtain maximum results. In these cases, the closed method was suitable as an alternative treatment choice.

In the first and second cases, the mandible fracture occurred in adolescence which constitutes an ongoing development period. The management of pediatric mandibular fractures differs from those occurring in adults because of the need to consider ongoing growth and developing dentition.<sup>13</sup> In children, not every fracture needs an open reduction and internal fixation. Moreover, the surgeon must contemplate the interplay between fracture location and both bony growth and dental development in order to choose an intervention that reduces the potential for long-term impairment and deformity.<sup>14</sup> Growth can support the objective of restoring form and function, especially in children. Treatment should be designed to support, rather than interfere with, this biological process.<sup>13</sup> Children have greater osteogenic potential and demonstrate more rapid healing rates than adults. Therefore, anatomic reduction must be accomplished earlier and immobilization time should be shorter (2 weeks versus 4–6 weeks in adults).<sup>12</sup> This is consistent with the opinion of Chrcanovic who said that, for many authors, conservative treatment of pediatric facial fractures has been the standard care due to the high osteogenic potential of facial bones in children. The early healing of fractures occurs with significant subsequent remodeling under the influence of the forces of mastication.<sup>15</sup> According to Goodday,<sup>13</sup> because of the high elasticity of the pediatric mandible, there is typically minimal displacement of the fracture fragments, rendering the injury amenable to a closed reduction. In contrast to adults, many pediatric mandibular fractures can be treated with conservative measures such as a soft diet alone.<sup>14</sup>

According to Goth,<sup>16</sup> a period of two to three weeks of MMF in children younger than 12 years is sufficient. After the age of 10, the development of permanent teeth provides for safer wire anchors. However, because children develop at different rates, the strength of the teeth should be carefully evaluated before any type of wire placement is installed.

However, according to Der-Martirosian,<sup>1</sup> patients frequently reject the treatment recommended by the clinician, either because they do not view positively the benefits of the treatment or because the risk and potential harmful side effects are perceived to be more serious than anticipated by clinicians. Occasionally, a residual facial scar was the most frequently expressed concern with regard to surgical treatment as observable in the third and fourth cases. Standard treatments that were used to repair mandibular fractures in this cases were non-surgical and referred to as MMF, and in most adults mandibular fractures require 4 to 6 weeks of stabilization by means of jaw wiring.<sup>1,13</sup> In general, patients with non-displaced or minimally displaced fractures may be managed conservatively through a combination of close observation, soft diet, analgesics, and activity precautions.<sup>9,17</sup> The adoption of a simple method would reduce complications related to the treating of mandible fractures because open reduction increases the risk of morbidity.

Patients who chose the closed reduction method treatment had to be capable of cooperating on the basis of a regular follow-up schedule and to evaluate previous treatment results to ensure that no unintended movement changes occurred. Closed reduction method in this series of cases produced encouraging results and it could be considered as an alternative to the treatment of neglected mandibular fracture with displacement.

## REFERENCES

1. Der-Martirosian C, Gironda MW, Black EE, Belin TR, Atchison KA. Predictors of treatment preference for mandibular fracture. *J Public Health Dent.* 2010; 70(1): 13–8.
2. Nasser M, Pandis N, Fleming PS, Fedorowicz Z, Ellis E, Ali K. Interventions for the management of mandibular fractures. *Cochrane Database Syst Rev.* 2013; 2013(7): CD006087.
3. Munante-Cardenas JL, Nunes PHF, Passeri LA. Etiology, treatment, and complications of mandibular fractures. *J Craniofac Surg.* 2015; 26(3): 61–5.
4. Niedzielska I, Puszczewicz Z, Mertas A, Niedzielski D, Rózanowski B, Baron S, Konopka T, Machorowska-Pieniązek A, Skucha-Nowak M, Tanasiewicz M, Paluch J, Markowski J, Orzechowska-Wylegala B, Król W, Morawiec T. The influence of ethanolic extract of Brazilian ree propolis gel on hygiene and oral microbiota in patients after mandible fractures. *Biomed Res Int.* 2016; 2016: 1–11.
5. Anyanechi CE, Saheeb BD. Mandibular sites prone to fracture: analysis of 174 cases in a Nigerian tertiary hospital. *Ghana Med J.* 2011; 45(3): 111–4.
6. Boffano P, Kommers SC, Karagozoglu KH, Gallesio C, Forouzanfar T. Mandibular trauma: A two-centre study. *Int J Oral Maxillofac Surg.* 2015; 44(8): 998–1004.
7. Namdev R, Jindal A, Bhargava S, Dutta S, Singhal P, Grewal P. Patterns of mandible fracture in children under 12 years in a district trauma center in India. *Dent Traumatol.* 2016; 32(1): 32–6.
8. Yuen H-W, Mazzoni T. Mandible fracture. *StatPearls.* 2019; 2019: 1–4.
9. Pickrell BB, Serebrakian AT, Maricevich RS. Mandible Fractures. *Semin Plast Surg.* 2017; 31(2): 100–7.
10. Omeje KU, Rana M, Adebola AR, Efunkoya AA, Olosoji HO, Purcz N, Gellrich NC, Rana M. Quality of life in treatment of mandibular fractures using closed reduction and maxillomandibular fixation in comparison with open reduction and internal fixation - A randomized prospective study. *J Cranio-Maxillofacial Surg.* 2014; 42(8): 1821–6.
11. Fonseca R, Barber HD, Powers M, Frost DE. *Oral and maxillofacial trauma.* 4th ed. Philadelphia: Saunders; 2013. p. 912.
12. Glazer M, Joshua BZ, Woldenberg Y, Bodner L. Mandibular fractures in children: Analysis of 61 cases and review of the literature. *Int J Pediatr Otorhinolaryngol.* 2011; 75(1): 62–4.
13. Goodday RHB. Management of fractures of the mandibular body and symphysis. *Oral Maxillofac Surg Clin North Am.* 2013; 25(4): 601–16.
14. Boyette JR. Facial fractures in children. *Otolaryngol Clin North Am.* 2014; 47(5): 747–61.
15. Chrcanovic BR, Abreu MHNG, Freire-Maia B, Souza LN. Facial fractures in children and adolescents: A retrospective study of 3 years in a hospital in Belo Horizonte, Brazil. *Dent Traumatol.* 2010; 26(3): 262–70.
16. Goth S, Sawatari Y, Peleg M. Management of pediatric mandible fractures. *J Craniofac Surg.* 2012; 23(1): 47–56.
17. Wolfswinkel EM, Weathers WM, Wirthlin JO, Monson LA, Hollier LH, Khechyan DY. Management of pediatric mandible fractures. *Otolaryngol Clin North Am.* 2013; 46(5): 791–806.



# Closed reduction in the treatment of neglected mandibular fractures at the Department of Oral and Maxillofacial Surgery, Universitas Airlangga

---

## ORIGINALITY REPORT

---

**23%**  
SIMILARITY INDEX

**8%**  
INTERNET SOURCES

**22%**  
PUBLICATIONS

**0%**  
STUDENT PAPERS

---

## PRIMARY SOURCES

---

- 1** Kevin U. Omeje, Majeed Rana, Adetokunbo R. Adebola, Akinwale A. Efunkoya et al. "Quality of life in treatment of mandibular fractures using closed reduction and maxillomandibular fixation in comparison with open reduction and internal fixation – A randomized prospective study", *Journal of Cranio-Maxillofacial Surgery*, 2014  
Publication **3%**
  - 2** Reginald H.B. Goodday. "Management of Fractures of the Mandibular Body and Symphysis", *Oral and Maxillofacial Surgery Clinics of North America*, 2013  
Publication **3%**
  - 3** Glazer, M.. "Mandibular fractures in children: Analysis of 61 cases and review of the literature", *International Journal of Pediatric Otorhinolaryngology*, 201101  
Publication **2%**
-

4

Jennings R. Boyette. "Facial Fractures in Children", Otolaryngologic Clinics of North America, 2014

Publication

2%

5

Nasser, Mona, Nikolaos Pandis, Padhraig S Fleming, Zbys Fedorowicz, Edward Ellis, Kamran Ali, and Mona Nasser. "Interventions for the management of mandibular fractures", Cochrane Database of Systematic Reviews Reviews, 2013.

Publication

1%

6

Claudia Der-Martirosian, Melanie W. Girona, Edward E. Black, Thomas R. Belin, Kathryn A. Atchison. "Predictors of treatment preference for mandibular fracture", Journal of Public Health Dentistry, 2010

Publication

1%

7

Stephen Goth, Yoh Sawatari, Michael Peleg. "Management of Pediatric Mandible Fractures", Journal of Craniofacial Surgery, 2012

Publication

1%

8

Bruno Ramos Chrcanovic. "Facial fractures in children and adolescents: a retrospective study of 3 years in a hospital in Belo Horizonte, Brazil : Facial fractures in children and adolescents", Dental Traumatology, 04/23/2010

1%

---

9	<a href="http://www.cosecsa.org">www.cosecsa.org</a> Internet Source	1 %
10	<a href="http://www.ncbi.nlm.nih.gov">www.ncbi.nlm.nih.gov</a> Internet Source	1 %
11	P. Boffano, S.C. Kommers, K.H. Karagozoglu, C. Gallesio, T. Forouzanfar. "Mandibular trauma: a two-centre study", International Journal of Oral and Maxillofacial Surgery, 2015 Publication	1 %
12	Munante-Cardenas, Jose Luis, Paulo Henrique Facchina Nunes, and Luis Augusto Passeri. "Etiology, Treatment, and Complications of Mandibular Fractures :", Journal of Craniofacial Surgery, 2015. Publication	1 %
13	<a href="http://thieme-connect.de">thieme-connect.de</a> Internet Source	1 %
14	Thalita Regina Vieira e Oliveira, Daniel Takanori Kemmoku, Jorge Vicente Lopes da Silva, Pedro Yoshito Noritomi et al. "Finite Element Evaluation of Stable Fixation in Combined Mandibular Fractures", Journal of Oral and Maxillofacial Surgery, 2017 Publication	1 %
15	<a href="http://www.scribd.com">www.scribd.com</a> Internet Source	1 %

---

16

Hiram Daniel López-Santacruz, Joselin Flores-Velázquez, Miguel Ángel Rosales-Berber.

"Mandibular greenstick fracture healing: A conservative approach", *Pediatric Dental Journal*, 2019

Publication

<1 %

17

"The Pediatric Upper Extremity", Springer Nature, 2015

Publication

<1 %

18

doi.org

Internet Source

<1 %

19

Ferraro s Fundamentals of Maxillofacial Surgery, 2015.

Publication

<1 %

20

Jose Luis Munante-Cardenas, Paulo Henrique Facchina Nunes, Luis Augusto Passeri.

"Etiology, Treatment, and Complications of Mandibular Fractures", *Journal of Craniofacial Surgery*, 2015

Publication

<1 %

21

Sabit Demircan, Sabri Cemil İşler, Aydın Gümüşdal, Begüm Genç. "Orthognathic Surgery after Mandibular Large-Volume Osteoma Treatment", *Case Reports in Dentistry*, 2020

Publication

<1 %

22

www.thieme-connect.com

Internet Source

<1 %

23

Hugh L. Vu, Jayesh Panchal, Norman Levine. "Combined Simultaneous Distraction Osteogenesis of the Maxilla and Mandible Using a Single Distraction Device in Hemifacial Microsomia", Journal of Craniofacial Surgery, 2001

Publication

<1 %

24

Ni Putu Mira Sumarta, David Buntoro Kamadjaja, Nike Hendrijantini, Coen Pramono Danudiningrat, Fedik Abdul Rantam. "Human Umbilical Cord Mesenchymal Stem Cells Over Platelet Rich Fibrin Scaffold for Mandibular Cartilage Defects Regenerative Medicine", Pesquisa Brasileira em Odontopediatria e Clínica Integrada, 2021

Publication

<1 %

25

Osasuyi Anslem, Okoturo Eyituoyo, Ogunbanjo V. Olabode, Olaitan A. Ademola, Ayodele O Adesina. "A comparative study of intermaxillary fixation screws and noncompression miniplates in the treatment of mandibular fractures: a prospective clinical study", Oral and Maxillofacial Surgery, 2017

Publication

<1 %

26

Ritu Namdev, Ayushi Jindal, Smriti Bhargava, Samir Dutta, Parul Singhal, Priyanka Grewal.

<1 %

# "Patterns of mandible fracture in children under 12 years in a district trauma center in India", Dental Traumatology, 2016

Publication

---

---

Exclude quotes      Off

Exclude matches      < 7 words

Exclude bibliography      On

# Closed reduction in the treatment of neglected mandibular fractures at the Department of Oral and Maxillofacial Surgery, Universitas Airlangga

---

GRADEMARK REPORT

---

FINAL GRADE

**/0**

GENERAL COMMENTS

**Instructor**

---

PAGE 1

---

PAGE 2

---

PAGE 3

---

PAGE 4

---

PAGE 5

---

PAGE 6

---

PAGE 7

---