

Cardiologia Croatica. 2021;16(7-8):237-284.

Objavljeno: 9. lipnja 2021

▼ Sažetak/Summary



Ljetni dvobroj časopisa *Cardiologia Croatica* za 2021. godinu izašao je na 48 stranica. U ovom broju čak četiri od pet priloga napisali su autori izvan Hrvatske. Teme priloga su dijabetička kardiomiopatija, infektivni endokarditis, akutna plućna tromboembolija i kronična bubrežna bolest. Slijedi aktualna inačica upute autorima. Na kraju broja je sponzorirani članak čija je tema primjena antitrombotičkih lijekova – prasugrela i tikagrelora u bolesnika s akutnim koronarnim sindromom.

Pozivamo članove Hrvatskog kardiološkog društva da ažuriraju svoje podatke za pretplatu na časopis – molimo poslati aktualnu poštansku adresu na adresu elektroničke pošte kardio@kardio.hr (<mailto:kardio@kardio.hr>) na koju zaprimamo i buduće članke.

Urednički odbor *Cardiologia Croatica*

Cardiologia Croatica. 2021;16(7-8):237-284.

Naslovnica / Cover.

Cardiol Croat. 2021;16(7-8):237.

Sadržaj / Table of Contents.

Cardiol Croat. 2021;16(7-8):238.

Hassan Mohamed Ebeid (<mailto:hassanebeid@yahoo.com>), Khaled Ahmed Elkhashab
Mohamed Zaki Hussain, Marwa Salah Said Mohammad

Prevalencija i kardiovaskularni ishodi kod dijabetičke kardiomiopatije u egipatskih bolesnika s dijabetesom tipa 2: presječna multicentrična studija u bolničkom okružju.

Prevalence and Cardiovascular Outcomes of Diabetic Cardiomyopathy in an Egyptian Type II Diabetic Patient Population: A Cross-sectional Hospital-based Multicenter Study.

Cardiol Croat. 2021;(7-8):239-245.

<https://doi.org/10.15836/ccar2021.239> xml


▼ Sažetak/Summary

Ivana Purnama Dewi , Ismail Damanik , Kristin Purnama Dewi , Mohammad Yogiarto ,
Andrianto ✉ (mailto:andrianto@fk.unair.ac.id).

Infektivni endokarditis uzrokovan bakterijama i s teškom trombocitopenijom kao komplikacijom: prikaz rijetkog slučaja.

Infective Endocarditis Caused by and Complicated with Severe Thrombocytopenia: A Rare Case.

Cardiol Croat. 2021;(7-8):246-251.


<https://doi.org/10.15836/ccar2021.246>  xml

Enes Jashari ✉ (mailto:enesjashari@hotmail.com), Hayber Taravari , Ardiana Beqiri .

Akutna plućna tromboembolija – primjena fibrinolitičke terapije u liječenju hemodinamski nestabilnog bolesnika u doba pandemije bolesti COVID-19: prikaz slučaja.

Acute Pulmonary Thromboembolism – Use of Fibrinolysis to Treat a Hemodynamically Unstable Patient in the Era of the COVID-19 Pandemic: A Case Report.

Cardiol Croat. 2021;(7-8):252-256.

<https://doi.org/10.15836/ccar2021.252>  xml

Damir Šečić ✉ (mailto:damir.secic@mf.unsa.ba), Adnan Turohan , Edin Begić ,
Šekib Sokolović , Damir Rebić , Ehlimana Mušija , Jasna Kusturica , Aida Kulo Ćesić ,
Esad Pepić , Jasmin Mušanović , Azra Metović .


Vrijednosti serumskog kreatinina, i jednadžbi u bolesnika s arterijskom hipertenzijom.

Performance of Serum Creatinine, Cockcroft-Gault and Modification of Diet in Renal Disease Study Equations in Assessment of Kidney Function in Patients with Arterial Hypertension.

Cardiol Croat. 2021;(7-8):257-263.

<https://doi.org/10.15836/ccar2021.257>  xml

Uputa autorima / Guidelines for authors.

Cardiol Croat. 2021;16(7-8):264-7. 


STRANICA SPONZORA / SPONSOR'S PAGE

Zvonimir Ostojić  (mailto:ostojiczvonimir@gmail.com).

Antiagregacijska terapija prasugrelom i tikagrelorom u liječenju bolesnika s akutnim koronarnim sindromom.

Antiplatelet Therapy with Prasugrel and Ticagrelor in the Treatment of Patients with Acute Coronary Syndrome.

Cardiol Croat. 2021;(7-8):269-275.

<https://doi.org/10.15836/ccar2021.269>  xml

Infektivni endokarditis uzrokovan bakterijama *Streptococcus alactolyticus* i *Kocuria kristinae* s teškom trombocitopenijom kao komplikacijom: prikaz rijetkog slučaja

Infective Endocarditis Caused by *Streptococcus alactolyticus* and *Kocuria kristinae* Complicated with Severe Thrombocytopenia: A Rare Case

Ivana Purnama Dewi^{1,2,3},
Ismail Damanik^{1,3},
Kristin Purnama Dewi¹,
Mohammad Yogiarto^{1,3},
Andrianto^{1,3*}

¹Faculty of Medicine, Universitas Airlangga, Surabaya, Indonesia

²Faculty of Medicine, Duta Wacana Christian University, Yogyakarta, Indonesia

³Department of Cardiology and Vascular Medicine, Dr. Soetomo General Hospital, Surabaya, Indonesia

RECEIVED:
February 22, 2021
UPDATED:
February 24, 2021
ACCEPTED:
March 29, 2021



Cardiologia Croatica
2021;16(7-8):246.

SAŽETAK: Uvod: Infektivni endokarditis (IE) fokalna je infekcija uzrokovana bakterijskim, virusnim ili gljivičnim mikroorganizmima, koja unutar srca zahvaća endokard i zalistke. *Streptococcus alactolyticus*, klasificiran po IV DNA klasterom *S. bovis* / *S. equinus* kompleksa, bakterija je koja se rijetko nalazi u izolatu te koja malokad uzrokuje IE u ljudi. *Kocuria kristinae* je gram-pozitivna bakterija. Dosad je objavljeno samo šest slučajeva IE-a uzrokovanih infekcijom bakterijom *K. kristinae*. Trombocitopenija i disfunkcija trombocita mogu se pojaviti u IE-u te su povezani s kliničkim ishodom. Postoje različite hipoteze o mehanizmima kojima se objašnjava trombocitopenija u IE-u.

Prikaz slučaja: Predstavljamo slučaj dvadesetpetogodišnje bolesnice koja se žalila na palpitacije dva tjedna prije primitka u bolnicu. Prvi je simptom bila povišena temperatura šest mjeseci prije primitka. Hemokulture su utvrdile *S. alactolyticus* i *K. kristinae*. Ehokardiografskom su pretragom pronađene vegetacije na anteriornom i posteriornom listiću mitralnog zalistka uz tešku mitralnu regurgitaciju. Bolesnica je tijekom hospitalizacije imala tešku trombocitopeniju bez znakova krvarenja. Šesnaestog dana hospitalizacije naglo se počela žaliti na abdominalnu bol i zaduhu. Bolesnica je umrla, a uzrok smrti bili su septički emboli.

Zaključak: Prikazan je slučaj IE-a uzrokovana rijetkim bakterijskim patogenima (*S. alactolyticus* i *K. kristinae*) koji je pogoršala trombocitopenija. Liječenje IE-a s trombocitopenijom zahtijeva oprez jer je to stanje povezano s lošim ishodima. U ovom se slučaju loši ishodi mogu povezati s trombocitopenijom uz prisutnost specifične bakterije, *S. alactolyticus*, koja je poznata kao bakterija koja često uzrokuje septičku emboliju.

SUMMARY: **Introduction:** Infective endocarditis (IE) is a focus infection caused by bacterial, viral, or fungal microorganisms within the heart that involves the endocardium and heart valves. *Streptococcus alactolyticus*, classified under DNA cluster IV of the *S. bovis*/*S. equinus* complex, is a sparse isolated bacterium that rarely cause IE in humans. *Kocuria kristinae* is a gram-positive bacteria. Until now, there have been only six IE cases caused by *K. kristinae* infections reported in the literature. Thrombocytopenia and platelet dysfunction can manifest in IE cases and are related to the clinical outcome. Different mechanisms have been hypothesized to explain thrombocytopenia in IE.

Case report: We report the case of a 25-year-old female patient who complained of palpitation two weeks before admission. Initially, the patient complained of fever arising six months before admission. Blood cultures showed *S. alactolyticus* and *K. kristinae*. Echocardiography examination showed vegetation on anterior and posterior mitral valves with severe mitral regurgitation. During hospitalization, the patient also suffered from severe thrombocytopenia without bleeding signs. On day 16 after hospitalization, the patient suddenly complained of abdominal pain and dyspnea. The patient was declared deceased with cause of death due to septic emboli.

Conclusion: We reported a case of IE caused by rare bacterial pathogens, *S. alactolyticus* and *K. kristinae*, which were aggravated by thrombocytopenia. Management of IE with thrombocytopenia requires caution because it is associated with poor outcomes. In this case, poor outcomes can be connected to thrombocytopenia coupled with the presence of specific bacteria, *S. alactolyticus*, which is known as a bacterium that often causes septic embolism.

KLJUČNE RIJEČI: infektivni endokarditis, valvularna bolest, *Streptococcus alactolyticus*, *Kocuria kristinae*, trombocitopenija.

KEYWORDS: infective endocarditis, valve disease, *Streptococcus alactolyticus*, *Kocuria kristinae*, thrombocytopenia.

CITATION: *Cardiol Croat.* 2021;16(7-8):246-51. | <https://doi.org/10.15836/ccar2021.246>

***ADDRESS FOR CORRESPONDENCE:** Andrianto, Department of Cardiology and Vascular Medicine, Faculty of Medicine, Universitas Airlangga - Dr. Soetomo General Hospital, Surabaya Jl. Mayjen Prof. Dr. Moestopo No.6-8, Surabaya 60286, Indonesia. / Phone: +62 812 3300 0705 / E-mail: andrianto@fk.unair.ac.id

ORCID: Ivana Purnama Dewi, <https://orcid.org/0000-0002-1602-3384> • Ismail Damanik, <https://orcid.org/0000-0003-1473-3355> • Kristin Purnama Dewi, <https://orcid.org/0000-0001-9328-6690> • Muhammad Yogiarto, <https://orcid.org/0000-0003-4372-6875> • Andrianto, <https://orcid.org/0000-0001-7834-344X>

TO CITE THIS ARTICLE: Dewi IP, Damanik I, Dewi KP, Yogiarto M, Andrianto. Infective Endocarditis Caused by *Streptococcus alactolyticus* and *Kocuria kristinae* Complicated with Severe Thrombocytopenia: A Rare Case. *Cardiol Croat.* 2021;16(7-8):246-51. | <https://doi.org/10.15836/ccar2021.246>

TO LINK TO THIS ARTICLE: <https://doi.org/10.15836/ccar2021.246>

Uvod

Infektivni endokarditis (IE) infekcija je mikroorganizmi- ma u srčanom endotelu (zalistci i endokardijalna mem- brana). Karakteriziraju ga tipične lezije – vegetacije koje su fibrinska masa s trombocitima različitih oblika i veličina. *Streptococcus alactolyticus* je podvrsta *S. bovis* / *S. equinus* kompleksa (SBSEK). Taj kompleks sadržava nebata-hemo- litičke streptokoke i streptokoke Lancefieldove grupe D, koji su oportunistički bakterijski patogeni ljudskih i životinjskih probavnih sustava.¹ Infekcije koje uzrokuje *S. alactolyticus* sporadične su u ljudi. *Kocuria* je gram-pozitivna bakterija, aktinobakterija u kokoidnim tetradama iz porodice *Micrococca- ceae*, podred *Micrococcineae*, red *Actinomycetales*.² *Kocuria* se u ljudi i drugih sisavaca često može naći u usnoj šupljini i na normalnoj koži. *K. kristinae* može uzrokovati bakterijemiju i infektivni endokarditis koji se mogu povezati s ulaznim mje- stom postavljenog katetera.

Trombociti imaju ključnu ulogu u patogenezi endokardi- tisa te su osjetljiv biljeg sistemskog odgovora organizma na sepsu.³ Oko 20 – 25 % bolesnika s bakterijskim endokardi- tisom ima trombocitopeniju, iako je ona najčešće blaga do umjerena.⁴ No moguća je i vrlo teška trombocitopenija, koja je u nekim slučajevima povezana s reaktivnim protutijelima protiv trombocita ili sindromima koji nalikuju na trombotič- ku trombocitopeničnu purpuru (TTP). Trombocitopenija je jedan od kriterija kojima se Svjetska zdravstvena organizaci- ja koristi u svojim smjernicama kao potencijalnim pokazate- ljem težine kliničke slike.

Prikaz slučaja

Prikazat ćemo slučaj dvadesetpetogodišnje bolesnice koja se javila u bolnicu žaleći se na palpitacije posljednja dva tjed- na prije primitka u bolnicu. Bolesnica je bila upućena iz pri- vatne bolnice sa sumnjom na IE. Prvi je simptom bila poviše- na temperatura šest mjeseci prije primitka, no do poboljšanja je došlo bez primjene lijekova. Bolesnica se tijekom iduća dva mjeseca žalila na povišenu temperaturu uz mučninu i povra- ćanje te je obrađena u primarnoj zdravstvenoj zaštiti i liječe- na paracetamolom. Simptomi su se zatim navodno pogoršali te je dijagnosticirana alergija na paracetamol. Bolesnica je nakon toga otišla u privatnu bolnicu žaleći se na povišenu temperaturu uz palpitacije i bol u prsnom košu.

Kliničkim je pregledom utvrđeno dobro opće stanje, s Glasgowskom ljestvicom kome O4V5M6. Pregled vitalnih znakova utvrdio je: arterijski tlak 90/70 mmHg, pravilnu fre- kvenciju srca od 72/min, respiraciju 20/min i temperaturu 37,7 °C. Pregled glave i vrata upućivao je na blagu anemiju te odsutnost ikterusa, cijanoze i zaduhe, a jugularni venski tlak nije bio povišen. Auskultacijom je utvrđen sistolički šum na apeksu srca stupnja 3/6, bez galopa i ekstrasistola. Pregled pluća, abdomena i udova bio je uredan. Elektrokardiografskim je pregledom pronađena sinusna tahikardija normalne osi (slika 1, A). Laboratorijske su pretrage pokazale ove vrijed- nosti: hemoglobin 9,1; leukociti 9300; trombociti 50 000; ureja u serumu 9,8; serumski kreatinin 0,9; glukoza 238; kalij 3,4; natrij 136; Cl 95; C3 16,4; C4 <6; IgG anti-dengue 4,3; IgM anti- dengue 0,9. U analizi urina utvrđeni su nitriti+, proteini 3+; le- ukociti 2+. Radiografija prsnog koša utvrdila je kardiomegaliju s kardiorakalnim omjerom od 70 %, a pluća su bila uredna (slika 1, B). Transtorakalnom ehokardiografijom (TTE) (slika 2) utvrđeno je sljedeće.

Introduction

Infective endocarditis (IE) is a microorganism infection of the heart endothelium (heart valves and endocardial mem- brane). Infective endocarditis is characterized by a typical lesion called vegetation, a mass of fibrin, and platelets with various shapes and sizes. *Streptococcus alactolyticus* is a subspecies of *S. bovis* / *Streptococcal equinus complex* (SB- SEC). This complex contains non-beta hemolytic streptococci and Lancefield group D streptococci, which are opportunistic pathogenic bacterial pathogens of human and animal diges- tive tracts.¹ Human infections caused by *S. alactolyticus* are sporadic. *Kocuria* is a gram-positive bacteria, actinobacteria in coccoid tetrads from the *Micrococcaceae* family, suborder *Micrococcineae*, order *Actinomycetales*.² *Kocuria* is often found in the oral cavity and normal skin in humans and other mammals. *K. kristinae* is known to cause catheter-related bacteremia and infection endocarditis.

Platelets have an essential role in the pathogenesis of en- docarditis and are a sensitive monitor of systemic host re- sponses to sepsis.³ About 20-25% of patients with bacterial endocarditis have thrombocytopenia, even though it is usu- ally mild to moderate.⁴ However, very severe thrombocytope- nia can be observed, which in some cases is associated with reactive platelet autoantibodies or syndromes that resemble thrombocytopenia purpura (TTP). Thrombocytopenia is one of the guideline criteria used by WHO as a potential indicator of clinical severity.

Case report

We report the case a 25-year-old female patient presenting with complaints of palpitation two weeks before admission. The patient was referred from a private hospital with a suspi- cion of IE. Initially, the patient had complained of fever arising six months ago, but it improved without medication. The pa- tient complained of fever accompanied by nausea and vomit- ing during the next two months. At the time, the patient was admitted by a primary health care center and received par- acetamol as medication. Reportedly, the patient's complaints increased and the patient was diagnosed as allergic to paracet- amol. The patient then went to a private hospital due to com- plaints of fever accompanied by palpitations and chest pain.

Physical examination showed that the general condition was good, with Glasgow comma scale (GCS) E4V5M6. Vi- tal sign examination showed the following: blood pressure 90/70 mmHg, pulse 72 bpm regular, breathing frequency 20 x/minutes, and temperature 37.7 °C. Head and neck examina- tion indicated there was slight anemia, no icterus, cyanosis, or dyspnea, and jugular venous pressure was not increased. Heart examination showed that there were apex grade III/VI systolic murmurs without gallop and extrasystole. Examina- tion of the lungs, abdomen, and extremities were within nor- mal limits. Electrocardiographic (ECG) examination found sinus tachycardia 119 bpm, normoaxis (Figure 1, A). Labora- tory results showed Hb 9.1, leucocytes 9300, platelets 50,000, blood urea nitrogen 9.8, creatinine serum 0.9, glucose 238, K 3.4, Na 136, Cl 95, C3 16.4, C4 <6, IgG anti-dengue 4.3, and IgM anti-dengue 0.9. Urinalysis results showed nitrite+, protein 3+, leukocyte 2+. Chest radiography for cardiomegaly with 70% a cardio-thoracic ratio, and the lungs were within normal limits (Figure 1, B). From the results of the transthoracic echocardi- ography (TTE) (Figure 2):

Infective Endocarditis Caused by *Streptococcus alactolyticus* and *Kocuria kristinae* Complicated with Severe Thrombocytopenia: A Rare Case

1. Zalistci: flail prednjeg listića mitralnog zalistka s umjerenom mitralnom regurgitacijom (MR) (MR ERC 0,3 cm²; MR RV 29 mL), CARPENTIER tipa II. Blaga trikuspidna regurgitacija (TR) (TR maks. PG 46,92 mmHg). Trivijalna aortna regurgitacija (AR).
2. Dimenzije srčanih šupljina: dilatirana lijeva pretklijetka (LA 6,4 x 4,5 cm), uredna veličina lijeve klijetke (LV) (LVIDd 4,8 cm), normalna veličina desnog atrija i desne klijetke (RV 2,2 cm). Postojala je vegetacija na prednjem listiću mitralnog zalistka (2,0 cm x 1,0 cm) bez prisutnog tromba.
3. Normalna sistolička funkcija LV-a (LVEF 67 %). Normalna sistolička funkcija RV-a (TAPSE 1,8 cm).
4. Bez segmentalnih poremećaja kontraktilnosti.
5. Koncentrična hipertrofija LV-a.

1. Valves: flail of anterior mitral valve leaflets (AML) with moderate mitral regurgitation (MR) (MR ERO 0.3 cm²; MR RV 29 mL), CARPENTIER type II. Mild tricuspid regurgitation (TR) (TRmaxPG 46.92 mmHg). Trivial aortic regurgitation (AR).
2. Cardiac chamber dimension: dilated left atrium (LA) (LA major 6.4 cm; LA minor 4.5 cm), normal left ventricle (LV) (LV internal dimension (LVIDd) 4.8 cm), normal right atrium (RA) and right ventricle (RV) (RVDB 2.2 cm). There is vegetation at the AML valve (2.0 cm x 1.0 cm) without thrombus.
3. Normal systolic LV function (EF by Teich 67%). Normal RV systolic function (tricuspid annular plane systolic excursion (TAPSE) 1.8 cm).
4. Normokinetic segmental analysis.
5. Concentric LV.

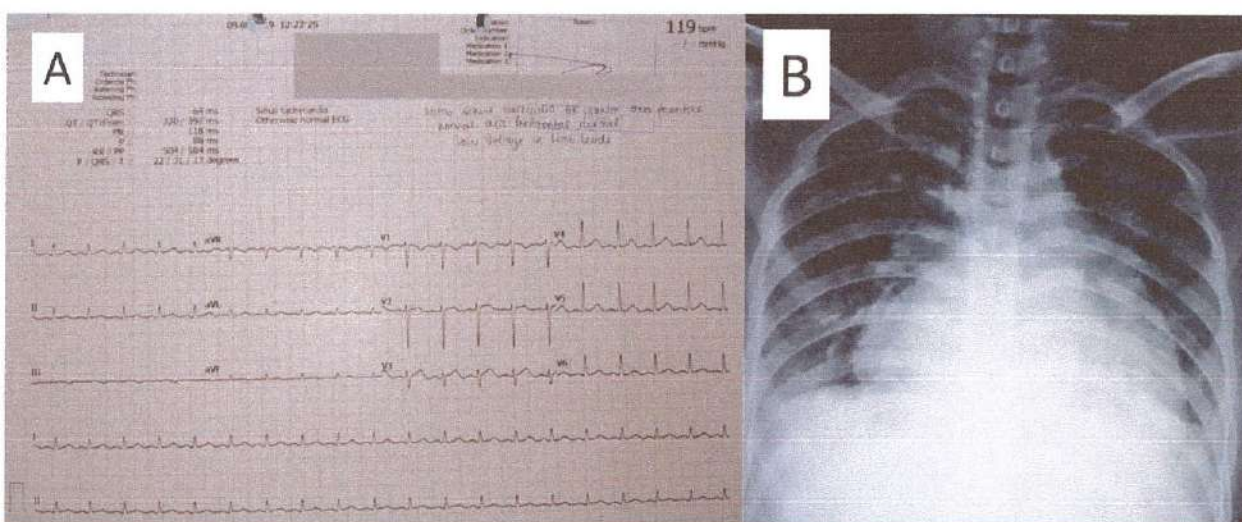


FIGURE 1. (A) Electrocardiography showed sinus tachycardia 119 bpm and normoaxis (B) Chest X-ray showed cardiomegaly with a cardio-thoracic ratio of 70% and mitral heart configuration.

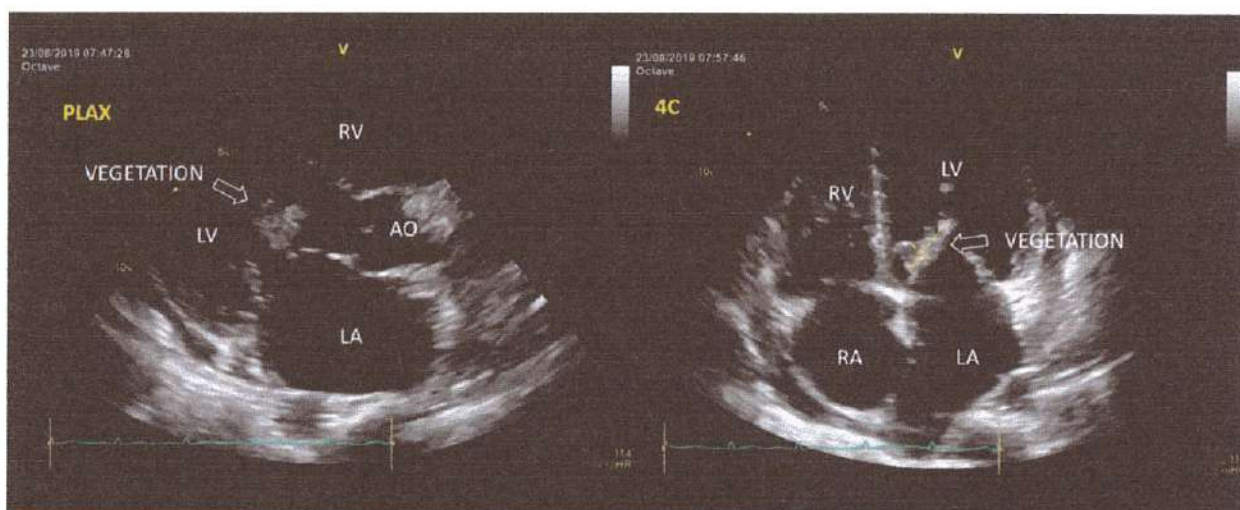


FIGURE 2. The transthoracic echocardiography view of parasternal long axis and 4-chamber view shows the presence of left atrial dilatation and vegetation in anterior mitral valve leaflets.

Bolesnici je dijagnosticiran mogući IE, umjerena MR, blaga TR, trombocitopenija, normokromna normocitna anemija i sumnja na sistemski eritemski lupus (SLE). Kao početnu terapiju uveli smo infuziju fiziološke otopine 500 mL / 24 sata, cefotaksim 3 × 1 g intravenski (iv), gentamicin 1 × 150 mg iv., furosemid 2 × 20 mg iv. te peroralno spironolakton 1 × 25 mg, lizinopril 1 × 5 mg i bisoprolol 1 × 1,25 mg.

Analiza hemokultura provedena je s triju mjesta i bila je pozitivna na *K. kristinae* i *S. alactolyticus*, što nas je dovelo do zaključka da su izolirane spomenute bakterije infektivni uzročnici te da je riječ o pravoj bakteriemiji. Hemokulture su također pokazale osjetljivost na levofloksacin. Bolesnici je definitivno dijagnosticiran IE te joj je ordiniran levofloksacin 1 × 750 mg iv. kao zamjena za cefotaksim. Tri dana poslije trombociti su pali na 20 000, a primijećena je hipokaliemija (kalij 2,6 mg/dL), pa je dodan kalijev klorid 3 × 600 mg.

Učinjena je transezofagealna ehokardiografija (TEE) (slika 3) i utvrđeno je sljedeće.

1. Zalisici: flail anteriornog listića mitralnog zalistka (A2) s teškom MR (MR ERO 0,8 cm²; MR RV 71 mL), CARPENTIER tipa II, trivijalna TR.
2. Nema tromba u LA ni u aurikuli LA, nema spontanog ehokontrasta u LA
3. Intaktan interatrijski septum.
4. Postojala je vegetacija na anteriornom (A2) (1,3 cm × 0,6 cm) i posteriornom listiću mitralnog zalistka (P3) (1,8 cm × 0,8 cm).

The patient was diagnosed with possible IE, moderate MR, mild TR, thrombocytopenia pro-evaluation, normochromic normocytic anemia, and systemic lupus erythematosus (SLE) suspicion. As the initial therapy, we administered an intravenous (IV) infusion of saline 500 mL/24 hours, cefotaxime 3×1 g IV, gentamicin 1×150 mg IV, furosemide 2×20 mg IV, spironolactone 1×25 mg per oral (p.o.), lisinopril 1×5 mg p.o., bisoprolol 1×1,25 mg p.o.

The blood culture examination carried out at 3 locations with showed results positive for *K. kristinae* and *S. alactolyticus*, leading to the conclusion that they were bacteria isolated from 3 significant blood sample as infectious agents and true bacteremia. The blood cultures showed sensitivity to levofloxacin. The patient was diagnosed with definite IE and given levofloxacin 1×750 mg IV as a substitute for cefotaxime. Three days later, the platelets decreased to 20,000, and hypokalemia (potassium 2.6 mg/dL) was observed, and the patient was given additional therapy comprising potassium chloride 3×600 mg.

Transesophageal echocardiography (TEE) was performed (Figure 3), with the following results:

1. Valves: There is flail AML (A2) valves with severe MR (MR ERO 0.8 cm²; MR RV 71 ml), CARPENTIER type II, trivial TR.
2. No thrombus in the left atrium (LA), left atrial appendage (LAA), LASEC (-).
3. Interatrial septum (IAS) intact.
4. There was vegetation in the AML (A2) valve (1.3 cm × 0.6 cm) and posterior mitral valve leaflets (PML) (P3) valve (1.8 cm × 0.8 cm).

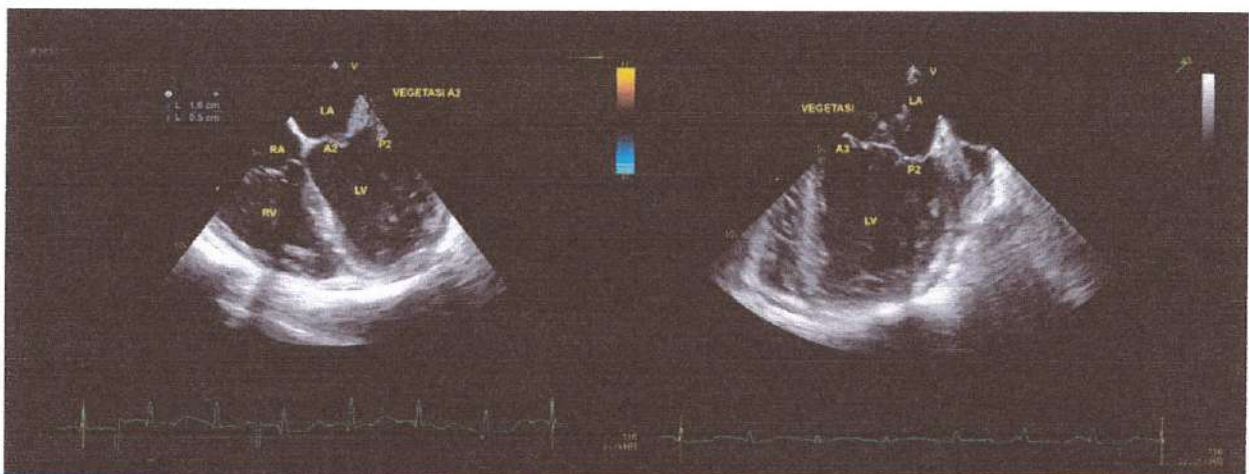


FIGURE 3. Transesophageal echocardiography showed there was vegetation in the anterior mitral valve leaflets (A2) and posterior mitral valve leaflets (P3).

Bolesnici je liječena antibiotskom terapijom i bila je hemodinamski stabilna tijekom dva tjedna dok je čekala na kardiokirurški zahvat. Šesnaestog dana hospitalizacije naglo se počela žaliti na abdominalnu bol i zaduhu. Sistolički je tlak pao na 60 – 70 mmHg te su registrirani tahikardija, hladnoća u udovima, poremećaj svijesti i desnostrana lateralizacija. Hemodinamska podrška osigurana je s pomoću norepinefrina 100 ng/kg tjelesne težine/minutu i dopamina mcg/kg tje-

The patient was given an antibiotic and had a stable hemodynamic for two weeks while waiting for the scheduled surgery. On day 16 of hospitalization, the patient suddenly complained of abdominal pain and dyspnea. Systolic blood pressure decreased to 60-70 mmHg, and tachycardia, cold extremities, decreased consciousness, and lateralization to the right were observed. We provided hemodynamic support with norepinephrine 100 ng/kg BW/minutes and dopamine 5 mcg/

lesne težine/minutu uz povećanje doze prema kliničkoj slici. Pripremili smo je za intubaciju, no bolesnično se stanje naglo pogoršalo te je nastupio zastoj srca. Proveli smo kardiopulmonalnu reanimaciju te je dvaput uspješno postignut povratak u spontanu cirkulaciju, no bolesnica je umrla u iduća dva sata, a uzrok smrti bili su septički embolusi.

Rasprava

Infektivni se endokarditis definira kao infekcija uzrokovana bakterijskim, virusnim ili gljivičnim mikroorganizmima na endokardu srca, koja može uključivati jedan ili više zalistaka, stijenku ili septalne defekte. Najčešći infektivni agensi koji uzrokuju infektivni endokarditis zalistka jesu gram-pozitivne bakterije, koje uključuju *S. aureus*, *S. viridans* i enterokoke.

Podatci upućuju na to da je *Staphylococcus aureus* i dalje najčešća bakterijska infekcija u svim slučajevima IE-a u razvijenim zemljama (31%), a potom slijedi skupina *Streptococcus viridans* (17%), koagulaza negativni stafilocoki (11%), enterokoki (10%) i *S. bovis* / *S. equinus* kompleks (6%).¹ Streptokoki su još uvijek dominantni u zemljama u razvoju. Publikacije o slučajevima infekcija u ljudi koje uzrokuje *S. alactolyticus* i dalje su rijetke. *S. alactolyticus* se smatra uzročnim agensom za IE sa septičkom embolijom kao komplikacijom. Cekmen *i sur.* prikazali su slučaj bolesnika s endokarditisom aortalnog zalistka te su utvrdili prisutnost *S. alactolyticus* bakteriemijske iz kulture.⁴ S druge strane, bakterije *S. bovis* / *S. equinus* kompleksa imaju tendenciju zahvaćanja nekoliko srčanih zalistaka, uključujući umjetne i mitralne zalistke. Embolijski događaji za *S. bovis* / *S. equinus* kompleks u IE-u prisutni su u rasponu od 9 do 55%.⁴

K. kristinae je gram-pozitivna bakterija te je dio normalne flore usne šupljine i ljudske kože. *Kocuria* bakterije široko su rasprostranjene u prirodi. Taj rod bakterija ima više od 18 vrsta, a samo pet smo identifikirali kao oportunističke patogene.⁵ Postoji samo šest prikaza slučajeva u kojima je IE uzrokovala bakterija *K. kristinae*. Studije koje istražuju *K. kristinae* i IE također su vrlo rijetke. Najnoviji prikaz slučaja dali su Arif *i sur.* koji su opisali rijedak slučaj IE-a na desnoj strani srca zbog infekcije bakterijama *K. kristinae* koja se manifestirala kao nedijagnosticirana povišena temperatura u trajanju od 1 godine.⁶ U našem je slučaju bolesnica također imala anamnestičke podatke o dugotrajnoj povišenoj temperaturi, što povećava sumnju na infekciju čiji je uzročnik bila *K. kristinae*. IE je mogući uzrok dugotrajno povišene temperature, pogotovo uz prisutnost prirodne bolesti srca. Osjetljivost na antibiotike nužna je za primjerenu terapiju u slučaju infekcije bakterijama *Kocuria*. Zasad ne postoje međunarodno prihvaćene smjernice za antibiotsko liječenje IE-a uzrokovana infekcijom bakterijom *K. kristinae*.⁷

Trombociti su ključna sastavnica u patogenezi endokarditisa. Međutim, nije sigurno ubrzavaju li trombociti progresiju bolesti ili je ograničavaju. Trombocitopenija ima tendenciju biti specifičan prognostički biljeg za endokarditis, a ne samo surogatni biljeg za reakcije akutne faze.³ Trombociti imaju ključnu ulogu u lokalnoj obrani od endovaskularnih infekcija.³ Prema istraživanju koje su objavili Duran *i sur.*, trombocitopenija je nezavisni prediktor smrti kod IE-a tijekom prvom i osmog dana bolesti.⁸ Trombocitopenija u bolesnika s IE-om ima ključne kliničke implikacije. Kao prvo, bolesnici s trombocitopenijom moraju primati empirijsku terapiju protiv stafilokoka zbog snažne povezanosti između rane trombocitopenije

kg BW/minutes up-titration, according to the hemodynamics. We prepare for intubation, but the condition worsened rapidly and the patient experienced cardiac arrest. We performed cardiopulmonary resuscitation, and the patient successfully return to spontaneously circulation two times, but she died during next two hours, with cause of death due to septic emboli.

Discussion

Infective endocarditis is defined as bacterial, viral, or fungal microorganism infection on the endocardium, which can include one or more heart valves, endocardial murals, or septal defects. The most common infectious agents that cause infective valve endocarditis are gram-positive bacteria, including *S. aureus*, *S. viridans*, and enterococci.

Data indicate that *Staphylococcus aureus* is still the most common bacterial infection for all IE cases in developed countries (31%), followed by the *Streptococcus viridans* group (17%), staphylococci negative coagulase (11%), enterococci (10%), and SBSEC (6%).¹ Streptococcus still dominates in developing countries. Reports of cases of *S. alactolyticus* infection in humans are still infrequent. *S. alactolyticus* is reported to be a causative agent for IE complicated by septic embolism. Cekmen *et al.* reported a patient with aortic valve endocarditis obtained the presence of *S. alactolyticus* bacteremia from the culture.⁴ On the other hand, there is a tendency for SBSEC bacteria to affect several heart valves, including prosthetic and mitral valves. The embolic events of SBSEC in IE range from 9% to 55%.⁴

K. kristinae is a gram-positive bacteria and is part of the normal flora of the oral cavity and human skin. *Kocuria* are widely distributed in nature. The genus has more than 18 species, but only five are known to be opportunistic pathogens.⁵ There have been only six case reports of IE caused by *K. kristinae*. Studies that examine *K. kristinae* and IE are also very rare. The newest case report by Arif *et al.* reported a rare case of right-sided IE due to *K. kristinae* presenting with undiagnosed fever for 1 year.⁶ In our case, the patient also had a history of prolonged fever that increase suspicion for *K. kristinae* infection. IE is a possible cause of a prolonged fever, especially in the presence of congenital heart disease. Antibiotic susceptibility is required for adequate therapy for *Kocuria* infection. Until now, there have been no internationally accepted guidelines for antibiotic treatment of IE caused by *K. kristinae* infection.⁷

Platelets are an essential component in pathogenesis of endocarditis. However, it is uncertain whether platelets may increase or limit disease progression. Thrombocytopenia tends to be a specific prognostic marker in endocarditis, rather than just a surrogate marker for acute phase reactions.³ Platelets play an essential role in local defense against endovascular infections.³ According to a study by Duran *et al.*, thrombocytopenia is an independent predictor of death on days 1 and 8 of IE.⁸ Thrombocytopenia in patients with IE has an essential clinical implication. Firstly, patients with thrombocytopenia must receive empirical anti-staphylococcal therapy because of the strong relationship between early thrombocytopenia and *Staphylococcus aureus* infection.³ Secondly, thrombocytopenia can increase the risk of bleeding if anti-platelet agents are considered as adjunctive therapy. Thirdly, thrombocytopenia on day 8 indicates an impaired defense response to sepsis and predicts increased mortality.³ Therefore, patients with thrombocytopenia may require more intensive monitoring, specific treatment, and, if relevant, surgical considerations.

i infekcije bakterijama *Staphylococcus aureus*.³ Kao drugo, trombocitopenija može povećati rizik od krvarenja ako se antitrombocitni lijekovi uzmu u obzir kao dodatna terapija. Kao treće, prisutnost trombocitopenije u osmom danu upućuje na oslabljeni obrambeni odgovor organizma na sepsu i predviđa povišenu smrtnost.³ Stoga bi bolesnicima s trombocitopenijom mogao biti potreban intenzivniji nadzor, specifično liječenje te, ako je relevantno, uzimanje kirurških zahvata u obzir.

Predstavili smo slučaj IE-a s bakterijemijom u kojem su u kulturi identificirane bakterije *S. alactolyticus* i *K. kristinae*. Objekte bakterije rijetki bakterijski patogeni u IE-u. *S. alactolyticus* je bakterija koja može uzrokovati septičku emboliju, koja je se u ovom slučaju može povezati s lošim ishodom. *K. kristinae* je dio normalne flore na ljudskoj koži, no može biti patogena bakterija. *K. kristinae* je povezana sa stanjem bolesnika koji su imunokompromitirani te s infekcijama urinarnog trakta u bolesnika s urinarnim kateterima. U prikazane bolesnice rezultati analize urina bili su pozitivni na bakterijsku infekciju. Trombocitopenija je povezana s lošom prognozom u bolesnika s IE-om. Dosad u literaturi nije opisana patogeneza tih dviju patogenih bakterija pronađenih u našem slučaju zajedno sa manjkom trombocita. Početna terapija u bolesnika koji su suspekti na infekciju koju uzrokuje *Staphylococcus aureus* i kakvu smo primijenili i u ovom slučaju, daje se u obliku antibiotika širokoga spektra, cefotaksima i gentamicina.

Zaključak

Predstavili smo slučaj IE-a uzrokovana rijetkim bakterijskih patogenima, *S. alactolyticus* i *K. kristinae*, koji je bio pogoršan trombocitopenijom. Potrebna su daljnja istraživanja o liječenju IE-a uzrokovana bakterijama *S. alactolyticus* i *K. kristinae*. Liječenje IE-a uz trombocitopeniju zahtijeva oprez jer je povezano s lošim ishodima. U prikazane se bolesnice loš ishod može povezati s trombocitopenijom u kombinaciji s prisutnošću određene bakterije, *S. alactolyticus*, za koju se zna da često uzrokuje septičku emboliju.

In this case, we reported IE with bacteremia which resulted in culture showing *S. alactolyticus* and *K. kristinae*. Both are rare bacterial pathogens in IE. *S. alactolyticus* is a bacterium that can cause septic embolism, which can be associated with the poor outcome in this case. *K. kristinae* is a normal flora of flora on human skin but can be a pathogenic bacterium. *K. kristinae* is related to the condition of patients who are immunocompromised and to urinary tract infections in patients using urine catheters. However, urinalysis results were positive for bacterial infection. Thrombocytopenia is associated with a poor prognosis in patients with IE. So far there have been no descriptions in the literature the pathogenesis of the two pathogenic bacteria in this case with platelets depletion. Initial therapy in patients that are usually suspected of *Staphylococcus aureus*, as we administered in our case as well, is in the form of a broad-spectrum antibiotic, cefotaxime and gentamicin.

Conclusion

We reported a case of IE caused by rare bacterial pathogens, *S. alactolyticus* and *K. kristinae*, which were aggravated by the condition of thrombocytopenia. Further studies are needed in the management of IE relating to *S. alactolyticus* and *K. kristinae* as causative agents. Management of IE with thrombocytopenia requires caution since it is associated with poor outcomes. In this case, poor outcomes can be connected to the condition of thrombocytopenia coupled with the presence of specific bacteria, *S. alactolyticus*, which is known as bacteria that often causes septic embolism.

LITERATURE

1. Cekmen N, Baysan O, Disbudak E, Gunt C. A rare case of bacterial infective endocarditis caused by *Streptococcus alactolyticus*. *Heart Vessel Transplant*. 2019;3(3):109-13. <https://doi.org/10.24969/hvt.2019.133>
2. Steckebandt E, Koch C, Gvozdiak O, Schumann P. Taxonomic dissection of the genus *Micrococcus*: *Kocuria* gen. nov., *Nesterenkonia* gen. nov., *Kytococcus* gen. nov., *Dermacoccus* gen. nov., and *Micrococcus* Cohn 1872 gen. emend. *Int J Syst Bacteriol*. 1995 Oct;45(4):682-92. <https://doi.org/10.1099/00207713-45-4-682>
3. Sy RW, Chawantanipat C, Richmond DR, Kritharides L. Thrombocytopenia and mortality in infective endocarditis. *J Am Coll Cardiol*. 2008 May 6;51(18):1824-5. <https://doi.org/10.1016/j.jacc.2008.01.034>
4. Selleng K, Warkentin TE, Greinacher A, Morris AM, Walker IR, Heggtveit HA, et al. Very severe thrombocytopenia and fragmentation hemolysis mimicking thrombotic thrombocytopenic purpura associated with a giant intracardiac vegetation infected with *Staphylococcus epidermidis*: role of monocyte procoagulant activity induced by bacterial supernatant. *Am J Hematol*. 2007 Aug;82(8):766-71. <https://doi.org/10.1002/ajh.20821>
5. Kandi V, Palange P, Vaish R, Bhatti AB, Kale V, Kandi MR, Bhoomagiri MR. Emerging Bacterial Infection: Identification and Clinical Significance of *Kocuria* Species. *Cureus*. 2016 Aug 10;8(8):e731. <https://doi.org/10.7759/cureus.731>
6. Ali AM, Waseem GR, Arif S. Rare case report of infective endocarditis due to *Kocuria kristinae* in a patient with ventricular septal defect. *Access Microbiol*. 2019 Nov 1;2(1):acmi000076. <https://doi.org/10.1099/acmi.0.000076>
7. Savini V, Catavittello C, Masciarelli G, Astolfi D, Balbinot A, Bianco A, et al. Drug sensitivity and clinical impact of members of the genus *Kocuria*. *J Med Microbiol*. 2010 Dec;59(Pt 12):1395-1402. <https://doi.org/10.1099/jmm.0.021709-0>
8. Ferrera Duran C, Vllacosta I, Olmos C, Fernandez C, Lopez J, Sarría C, et al. Thrombocytopenia, a new marker of bad prognosis in patients with infective endocarditis. *Eur Heart J*. 2013 Aug;34(suppl 1):P4773-P4773. <https://doi.org/10.1093/eurheartj/ehs310.P4773>