
[PBOCI] Journal Registration

1 pesan

Alessandro Leite Cavalcanti, Ph.D. <alessandrouepb@gmail.com>
Kepada: Dr Muhammad Luthfi <m.luthfi@fkg.unair.ac.id>

19 Juli 2019 pukul 08.17

Dr Muhammad Luthfi

You have now been registered as a user with Pesquisa Brasileira em Odontopediatria e Clinica Integrada. We have included your username and password in this email, which are needed for all work with this journal through its website. At any point, you can ask to be removed from the journal's list of users by contacting me.

Username: m-luthfi7
Password: Stovit1928

Thank you,
Alessandro Leite Cavalcanti, Ph.D.
Prof. Dr. Alessandro Leite Cavalcanti
Prof. Dr. Wilton Wilney Nascimento Padilha
Editors
Pesquisa Brasileira em Odontopediatria e Clinica Integrada
<http://revista.uepb.edu.br/index.php/pboci>



MUHAMMAD LUTHFI <m.luthfi@fkg.unair.ac.id>

[PBOCI] Angiogenesis of extracted tooth wound on Wistar rats after application of Okra (Abelmoschus esculentus) gel extract

1 pesan

Dr Muhammad Luthfi <m.luthfi@fkg.unair.ac.id>
Kepada: Alessandro Cavalcanti <alessandrouepb@gmail.com>

21 Januari 2020 pukul 10.42

Dear Prof Cavalcanti,

I am writing to ask about the status of our manuscript, titled "Angiogenesis of extracted tooth wound on Wistar rats after application of Okra (Abelmoschus esculentus) gel extract" which was submitted on July 19th, 2019.

The system stated that our manuscript is currently in review. Would you please inform us how long does the process take?

I am looking forward hearing from you soon

Best regards,

Muhammad Luthfi

Prof. Dr. Alessandro Leite Cavalcanti

Prof. Dr. Wilton Wilney Nascimento Padilha

Editors

Pesquisa Brasileira em Odontopediatria e Clinica Integrada

<http://revista.uepb.edu.br/index.php/pboci>



MUHAMMAD LUTHFI <m.luthfi@fkg.unair.ac.id>

[PBOCI] Submission Acknowledgement

2 pesan

Alessandro Leite Cavalcanti, Ph.D. <alessandrouepb@gmail.com>

19 Juli 2019 pukul 13.36

Kepada: Dr Muhammad Luthfi <m.luthfi@fkg.unair.ac.id>

Dr Muhammad Luthfi:

Thank you for submitting the manuscript, "Angiogenesis of extracted tooth wound on Wistar rats after application of Okra (*Abelmoschus esculentus*) gel extract" to Pesquisa Brasileira em Odontopediatria e Clinica Integrada. With the online journal management system that we are using, you will be able to track its progress through the editorial process by logging in to the journal web site:

Manuscript URL:

<http://revista.uepb.edu.br/index.php/pboci/author/submission/5087>

Username: m-luthfi7

If you have any questions, please contact me. Thank you for considering this journal as a venue for your work.

Alessandro Leite Cavalcanti, Ph.D.
Pesquisa Brasileira em Odontopediatria e Clinica Integrada
Prof. Dr. Alessandro Leite Cavalcanti
Prof. Dr. Wilton Wilney Nascimento Padilha
Editors
Pesquisa Brasileira em Odontopediatria e Clinica Integrada
<http://revista.uepb.edu.br/index.php/pboci>

MUHAMMAD LUTHFI <m.luthfi@fkg.unair.ac.id>

25 Juli 2019 pukul 20.31

Kepada: "Alessandro Leite Cavalcanti, Ph.D." <alessandrouepb@gmail.com>

thanks a lot

Pada tanggal Jum, 19 Jul 2019 pukul 13.36 Alessandro Leite Cavalcanti, Ph.D. <alessandrouepb@gmail.com> menulis:

Dr Muhammad Luthfi:

Thank you for submitting the manuscript, "Angiogenesis of extracted tooth wound on Wistar rats after application of Okra (*Abelmoschus esculentus*) gel extract" to Pesquisa Brasileira em Odontopediatria e Clinica Integrada. With the online journal management system that we are using, you will be able to track its progress through the editorial process by logging in to the journal web site:

Manuscript URL:

<http://revista.uepb.edu.br/index.php/pboci/author/submission/5087>

Username: m-luthfi7

If you have any questions, please contact me. Thank you for considering this journal as a venue for your work.

Alessandro Leite Cavalcanti, Ph.D.

Pesquisa Brasileira em Odontopediatria e Clinica Integrada
Prof. Dr. Alessandro Leite Cavalcanti
Prof. Dr. Wilton Wilney Nascimento Padilha
Editors
Pesquisa Brasileira em Odontopediatria e Clinica Integrada
<http://revista.uepb.edu.br/index.php/pboci>



MUHAMMAD LUTHFI <m.luthfi@fkg.unair.ac.id>

Manuscript Status ID #5087 Pesqui Bras Odontopediatria Clin Integr

2 pesan

Alessandro Cavalcanti <alessandrouepb@gmail.com>
Kepada: Dr Muhammad Luthfi <m.luthfi@fkg.unair.ac.id>

23 Januari 2020 pukul 18.26



Dear Professor Luthfi,

Greetings!

Don't worry about the status of your manuscript as we are in a transition period as described on the website to adopt the ScholarOne system. Therefore, some information was not up to date.

With respect to your manuscript, it has been accepted for publication as presented. In the coming days, our team will send for editing.

Best Regards,

Alessandro Cavalcanti

MUHAMMAD LUTHFI <m.luthfi@fkg.unair.ac.id>
Kepada: Alessandro Cavalcanti <alessandrouepb@gmail.com>

12 Februari 2020 pukul 12.35

Received, thank you.

Pada tanggal Kam, 23 Jan 2020 pukul 18.26 Alessandro Cavalcanti <alessandrouepb@gmail.com> menulis:



Dear Professor Luthfi,

Greetings!

Don't worry about the status of your manuscript as we are in a transition period as described on the website to adopt the ScholarOne system. Therefore, some information was not up to date.

With respect to your manuscript, it has been accepted for publication as presented. In the coming days, our team will send for editing.

Best Regards,

Alessandro Cavalcanti



MUHAMMAD LUTHFI <m.luthfi@fkg.unair.ac.id>

PDF Proof and Copyright Statement Article ID #5087 Pesqui Bras Odontopediatria Clin Integr

4 pesan

Alessandro Cavalcanti <alessandrouepb@gmail.com>
Kepada: Dr Muhammad Luthfi <m.luthfi@fkg.unair.ac.id>

17 Februari 2020 pukul 04.20



Dear Dr. Luthfi,

The proof of your article (**Angiogenesis of Extracted Tooth Wound on Wistar rats After Application of Okra (Abelmoschus esculentus) Gel Extract**), to be published in Pesquisa Brasileira em Odontopediatria e Clínica Integrada is attached to this e-mail. Return the corrected proof as an e-mail attachment within 5 days and underline the corrections in red. Please use this proof for checking the typesetting, editing, completeness and correctness of the text, tables and figures. Corrections can be made in word file.

1) ORCID number of all authors

For publication you will need to send us by email the **Copyright Statement**. Once we receive this document, we will publish your article.

Best Regards,

Alessandro Cavalcanti

2 lampiran

 **Copyright Form PBOCI 2020.docx**
55K

 **PDF PROOF Angiogenesis of Extracted Tooth.pdf**
958K

MUHAMMAD LUTHFI <m.luthfi@fkg.unair.ac.id>
Kepada: Alessandro Cavalcanti <alessandrouepb@gmail.com>

17 Februari 2020 pukul 05.51

Thanks a lot.
Best regard

Luthfi

Pada tanggal Sen, 17 Feb 2020 4:20 AM, Alessandro Cavalcanti <alessandrouepb@gmail.com> menulis:



Dear Dr. Luthfi,

The proof of your article (**Angiogenesis of Extracted Tooth Wound on Wistar rats After Application of Okra (Abelmoschus esculentus) Gel Extract**), to be published in Pesquisa Brasileira em Odontopediatria e Clínica Integrada is attached to this e-mail. Return the corrected proof as an e-mail attachment within 5 days and underline the corrections in red. Please use this proof for checking the typesetting, editing, completeness and correctness of the text, tables and figures. Corrections can be made in word file.

1) **ORCID number of all authors**

For publication you will need to send us by email the **Copyright Statement**. Once we receive this document, we will publish your article.

Best Regards,

Alessandro Cavalcanti

MUHAMMAD LUTHFI <m.luthfi@fkg.unair.ac.id>
Kepada: andikacreative234@gmail.com

18 Februari 2020 pukul 13.29

----- Forwarded message -----

Dari: **Alessandro Cavalcanti** <alessandrouepb@gmail.com>

Date: Sen, 17 Feb 2020 12:20 AM

Subject: PDF Proof and Copyright Statement Article ID #5087 Pesqui Bras Odontopediatria Clin Integr

To: Dr Muhammad Luthfi <m.luthfi@fkg.unair.ac.id>



Dear Dr. Luthfi,

The proof of your article (**Angiogenesis of Extracted Tooth Wound on Wistar rats After Application of Okra**

(Abelmoschus esculentus) Gel Extract), to be published in Pesquisa Brasileira em Odontopediatria e Clínica Integrada is attached to this e-mail. Return the corrected proof as an e-mail attachment within 5 days and underline the corrections in red. Please use this proof for checking the typesetting, editing, completeness and correctness of the text, tables and figures. Corrections can be made in word file.

1) ORCID number of all authors

For publication you will need to send us by email the **Copyright Statement**. Once we receive this document, we will publish your article.

Best Regards,

Alessandro Cavalcanti

2 lampiran

 **Copyright Form PBOCI 2020.docx**
55K

 **PDF PROOF Angiogenesis of Extracted Tooth.pdf**
958K

MUHAMMAD LUTHFI <m.luthfi@fkg.unair.ac.id>
Kepada: MUHAMMAD LUTHFI <m.luthfi@fkg.unair.ac.id>

19 Februari 2020 pukul 13.32

Copyright Form

Pada tanggal Sel, 18 Feb 2020 pukul 13.29 MUHAMMAD LUTHFI <m.luthfi@fkg.unair.ac.id> menulis:

----- Forwarded message -----

Dari: **Alessandro Cavalcanti** <alessandrouepb@gmail.com>

Date: Sen, 17 Feb 2020 12:20 AM

Subject: PDF Proof and Copyright Statement Article ID #5087 Pesqui Bras Odontopediatria Clin Integr

To: Dr Muhammad Luthfi <m.luthfi@fkg.unair.ac.id>



Dear Dr. Luthfi,

The proof of your article (**Angiogenesis of Extracted Tooth Wound on Wistar rats After Application of Okra (Abelmoschus esculentus) Gel Extract**), to be published in Pesquisa Brasileira em Odontopediatria e Clínica Integrada is attached to this e-mail. Return the corrected proof as an e-mail attachment within 5 days and underline the corrections in red. Please use this proof for checking the typesetting, editing, completeness and correctness of the text, tables and figures. Corrections can be made in word file.

1) **ORCID number of all authors**

For publication you will need to send us by email the **Copyright Statement**. Once we receive this document, we will publish your article.

Best Regards,

Alessandro Cavalcanti

 **Copyright Form.pdf**
529K



COPYRIGHT FORM

I hereby transfer the Copyright of the paper (Title of the manuscript): Angiogenesis of Extracted Tooth Wound on Wistar rats After Application of Okra (*Abelmoschus esculentus*) Gel Extract

By (Authors): Muhammad Luthfi¹ , Wisnu Setyari Juliastuti¹ , Yuniar Aliyah Risky²

Manuscript ID : #5087

I hereby transfer the Copyright to the publisher.

The author(s) reserve(s) all proprietary rights such as patent rights and the right to use all or part of the article in future works of their own such as lectures, press releases, and reviews of textbooks. In case of republication of the whole, part, or parts thereof, in periodicals or reprint publications by a third party, written permission must be obtained from the Publisher.

I hereby declare that the material being presented by me/us in this paper is our original work, and does not contain nor include material taken from other copyrighted sources. Wherever such material has been included, it has been clearly indented or/and identified by quotation marks and due and proper acknowledgements given by citing the source at appropriate places.




The paper, the final version of which I enclose, is not substantially the same as any that I/we have already published elsewhere.

I/we have not sent the paper or any paper substantially the same as the enclosed one, for publication anywhere else.




All papers will be acknowledged and refereed. They will not be returned.

I understand and agree to adhere to APESB publishing exclusivity and republishing requirements, as set out in the editorial guidelines. The Publisher can use the material for publication and/or translation in other publications, in Brazil or worldwide and online.

If any plagiarism is found in the present manuscript after publication, I am wholly responsible and not the publisher nor the journal's Board members.

NAME	SIGNATURE	DATE
1 Muhammad Luthfi		<u>19/2 2020</u>
2 Wisnu Setyari Juliastuti		<u>19/2 2020</u>
3 Yuniar Aliyah Risky		<u>19/2 2020</u>

Angiogenesis of Extracted Tooth Wound on Wistar rats After Application of Okra (*Abelmoschus esculentus*) Gel Extract

Muhammad Luthfi¹, Wisnu Setyari Juliastuti¹, Yuniar Aliyah Risky²

¹Department of Oral Biology, Faculty of Dental Medicine, Universitas Airlangga, JSurabaya, Indonesia.

²Undergraduate Program, Faculty of Dental Medicine, Universitas Airlangga, Surabaya, Indonesia.

Author to whom correspondence should be addressed: Muhammad Luthfi, Department of Oral Biology, Faculty of Dental Medicine, Universitas Airlangga, Jalan Prof. Dr. Moestopo 47, Surabaya, Indonesia. Phone: (+62 31) 5030255. E-mail: m.luthfi@fkg.unair.ac.id.

Academic Editors: Alessandro Leite Cavalcanti and Wilton Wilney Nascimento Padilha

Received: 19 August 2019 / Accepted: 13 January 2020 / Published: XX February 2020

How to cite this article: Luthfi M, Juliastuti WS, Risky YA. Angiogenesis of extracted tooth wound on wistar rats after application of okra (*Abelmoschus esculentus*) gel extract. *Pesqui Bras Odontopediatria Cln Integr*. 2020; 20:e5087. <https://doi.org/10.1590/pboci.2020.036>

Abstract

Objective: To analyze angiogenesis in the post-extracted tooth of Wistar rats after application of okra (*Abelmoschus esculentus*) extract. **Material and Methods:** A total of 18 rats were divided into two groups (control and treatment). Okra extract with a concentration of 30% in gel form was applied on the post-extraction socket of the treatment group. The rats were sacrificed on day-3, day-5, and day-7 after tooth extraction. The newly-formed blood vessels were counted and statistically analyzed by means of One Way ANOVA and Tukey HSD with a significance level set at 5%. **Results:** The newly-formed capillaries of the control group (4.67 ± 1.53) on day-3 were lower than the treatment group (9.00 ± 1.00). The newly-formed capillaries recorded from the control group, both in day-5 (9.33 ± 1.53) and day-7 (8.67 ± 1.53) were lower than the treatment group, which started to decreased from day-5 (13.67 ± 1.53) to day-7 (12.33 ± 0.58). Significant differences were found in treatment group, on day-3 compared to day-5 ($p=0.005$), and on day-3 to day-7 ($p=0.024$). **Conclusion:** Okra extract in gel form at 30% concentration can increase the angiogenesis during the wound healing process of the extracted tooth on Wistar rats.

Keywords: Tooth Extraction; Wound Healing; Angiogenesis Inducing Agents.

Introduction

Angiogenesis constitutes the new blood vessels formation from the pre-existing blood vessels, which is required in the wound healing process. This physiological response initiated by the activation of endothelial cells in the inner lining of blood vessels mediated by proangiogenic factors and hypoxic environment. The endothelial cells will subsequently breakdown the surrounding extracellular matrix to begin migration and cell proliferation, creating the new capillaries [1].

Tooth extraction is a procedure of removing a tooth from its socket. The process may cause damage, both the hard and soft tissues, thus trigger the physiological response of the wound healing process [2]. An ideal tooth extraction should be able to remove the whole tooth without pain and with minimal trauma of the adjacent tissues to allow the normal wound healing without any complication. In some cases, complications of tooth extraction may appear, such as pain, infection, severe bleeding, and dry socket [3].

The process of wound healing plays a key role in preventing complications post tooth extraction. There are several commercially available medications to promote wound healing; however, mostly unaffordable and takes a long time [4]. Those backgrounds give rise to several studies on natural medicine to promote wound healing or to stop bleeding post tooth extraction. The rapid development of the current pharmaceutical technology gives more focus on natural resources for numerous medications, including to promote wound healing. Natural resources are considered less toxic compared to the drugs made from chemicals, thus become a more interesting field of study [5].

One of the herbs that can be used as an alternative medicine to promote wound healing is okra (*Abelmoschus esculentus*) extract that has beneficial properties, such as anti-diabetes, antioxidant, anti-plasmodia, anti-bacteria, anti-cancer, analgesia, anti-diarrhea, and anti-inflammation [6]. The active ingredients contained in okra fruit extract are saponin, tannin, flavonoid, and alkaloid [7]. Besides, Okra fruit also contains quercetin, which has antioxidant properties that protect the body from degenerative diseases. Saponin contained in Okra fruit act as an anti-bacterial agent, and also stimulate angiogenesis. A previous study proved the efficacy of flavonoid as an anti-inflammatory agent, the moderator of collagen type III synthesis, and also phospholipase inhibitor [8]. Besides, flavonoid also modulates the oxidative burst in neutrophils, which may reduce the reactive oxygen species (ROS); therefore, promote wound healing [9].

Based on these backgrounds, this study is aiming to analyze the efficacy of okra fruit extract in gel form toward the angiogenesis of post-extraction socket of Wistar rats.

Material and Methods

Study Design and Sample

This laboratory experimental study was conducted in vivo, by means of post-test only control group design. Eighteen male Wistar rats were used, with inclusion criteria as follows: 1) male rats 2-3 months old, 2) weighing 100-150 grams, 3) healthy. Rats showing symptoms such as inactive, have a low appetite, and diarrhea were excluded from this study. The samples were acquired from Experimental Animal Unit, Biochemical Laboratory, Faculty of Veterinary Medicine, Universitas Airlangga.

Rats were randomly divided into 2 groups, namely the control group and treatment group. An amount of 0.1ml okra fruit extract in gel form at 30% concentration was applied to the socket of the treatment group, while the control group received no treatment.

Okra (*Abelmoschus esculentus*) Extract Preparation

The fresh okra fruit acquired from Materia Medica Farm (Batu, Indonesia) were rinsed using tap water, and grinded by means of blender (Phillips, Jakarta, Indonesia), and stored in a closed glass jar for 24 hours. The mixture was shaken at 50 rpm, filtered using clothes, and collected into an Erlenmeyer tube subsequently. The liquid extract was evaporated using the rotary evaporator for 90 minutes and stored.

Carboxy Methyl Cellulose Natrium Gel

The basic ingredients to make gel were Carboxyl Methyl Cellulose Natrium – CMC-Na 3% (Fochem, Shanghai, China). The powder of CMC-Na 3% was diluted in 100 ml warm water in mortar. The powder was added evenly gradually to the water to make it easy to disperse. The mixture was left for 10-15 minutes until form a gentle transparent gel. The was subsequently mixed by means of stamper until homogeneous, by adding water slowly to get 100 ml volume.

Okra Extract 30% in Gel Form Preparation

In order to get okra fruit in gel form at 30% concentration, as much as 3 ml extract were mixed with 7 ml CMC-Na 3%.

Animal Care

Male Wistar rats aged 2-3 months old, weighing 100-150 mg were acclimatized for 7 days prior to the experiment. The rats were put in room temperature $25 \pm 2^{\circ}\text{C}$ with a 12 hour light dark cycle. The rats were given standard rodent chow and tap water ad libitum [10]. This is intended to minimize the animals' stress and also to get a homogenous condition of the rats.

Experimental Animals

Rats from both groups (treatment and control) were anesthetized using a peritoneal injection of 0.1 ml ketamine. Following 1-1.5 hours after injection, the lower-left central incisive were extracted utilizing scalpel and needle holder, and no remaining roots in the socket confirmed. The socket was subsequently irrigated using a saline solution [11]. The control group was let heal without treatment, as the normal wound heals. As for the treatment group, 30% okra extract in gel form were applied in the socket as much as 0.1 ml.

Tissue Collection

The rats were sacrificed on day-3, day-5, and day-7 after tooth extraction through intraperitoneal injection of ketamine at a lethal dose (four times of anesthesia dose, or 0.4ml/kg b. w.). The whole mandibles were collected, including the temporomandibular joint. The rats were buried according to experimental animal guidance. The mandible in the incisive region were cut vertically, and made into a paraffin block [12].

Histological Examination

The mandibles were cut and fixated using 10% formaldehyde at room temperature for 24 hours. The tissues were then dehydrated using gradated ethanol, cleansed using xylene, and made into a paraffin block. The paraffin blocks were cut with 6 μm thickness, put into slides, and the paraffin was removed. The slides were subsequently stained using hematoxylin and eosin (HE). The angiogenesis rate was observed under a light microscope at 400x magnification [12].

Data Analysis

The acquired data were statistically analyzed. Kolmogorov-Smirnov test was used to find if the data was normally distributed. Levene test was subsequently done to confirm the data homogeneity. Hereafter, the differences among groups were analyzed using one-way Anova, and Tukey HSD with a significance level set at 5%. If the data were not normally distributed and not homogeny, Kruskal-Wallis, followed by Mann-Whitney, were performed to find any differences.

Ethical Clearance

All the procedures contained in this study have passed an ethical review by Universitas Airlangga Faculty of Dental Medicine Health Research Ethical Clearance Commission, with certificate number: 155/HRECC.FODM/VII/2018.

Results

The histopathological observation of Wistar rats tooth socket was carried out on day-3, day-5, and day-7 post tooth extraction. The mean and standard deviation of the angiogenesis rate, both from the control and treatment group were tabulated and presented in Table 1. This study is aiming to analyze the efficacy of okra fruit extract in gel form at 30% concentration toward the post-extraction wound healing process.

Table 1. Mean and standard deviation of angiogenesis of post tooth extraction wound at different times of evaluation.

Group	N	Mean (SD)		
		Day-3	Day-5	Day-7
Control	9	4.67 ± 1.53	9.33 ± 1.53	8.67 ± 1.53
Treatment	9	9.00 ± 1.00	13.67 ± 1.53	12.33 ± 0.58

There were increased of newly-formed capillaries in both experimental groups from day-3 to day-5. Further observation on both groups also showed a decrease of angiogenesis from day-5 to day-7. The fluctuation is described in Figure 1.

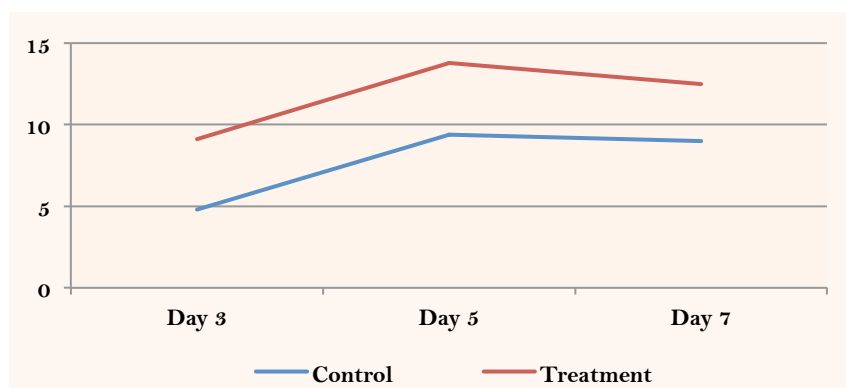


Figure 1. Angiogenesis at different times of evaluation.

The observation revealed the newly-formed capillaries of the control group (4.67 ± 1.53) on day-3 were lower than the treatment group (9.00 ± 1.00). Continuous observation also resulted in the same manner, the newly-formed capillaries recorded from the control group, both in day-5 (9.33 ± 1.53) and day-7 (8.67 ± 1.53) were lower than the treatment group, which started to decreased from day-5 (13.67 ± 1.53) to day-7 (12.33 ± 0.58).

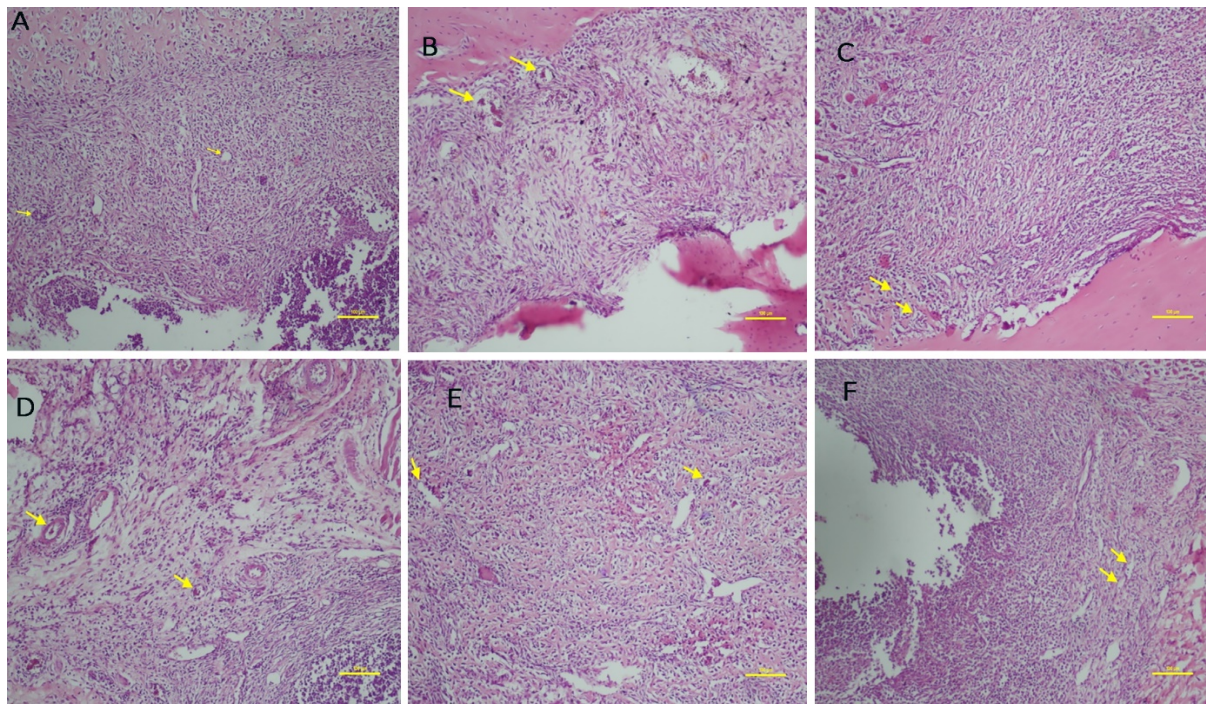


Figure 2. Histopathological image of angiogenesis of post-tooth-extraction socket of control group on day-3 (A), day-5 (B), day-7 (C), and treatment group on day-3 (D), day-5 (E), day-7 (F). Yellow arrows are indicating the newly-formed capillaries, using HE staining with 400x magnification.

Anova test result revealed that there was a significant difference of newly-formed capillaries among the groups ($p=0.005$). HSD Tukey recorded significant differences of angiogenesis rate between control group and treatment group throughout the observation days, day-3, day-5, and day-7 (Table 2). HSD Tukey test (Table 3) also revealed a significant difference of newly-formed capillaries of the treatment group between day-3 and day-5; also between day-3 and day-7, however, there was any differences found between day-5 and day-7.

Table 3. HSD Tukey test results at different times of evaluation.

Control Group	Day	Angiogenesis of Treatment Group		
		3	5	7
	3	0.015*	-	-
	5	-	0.025*	-
	7	-	-	0.018*

Table 4. HSD Tukey of angiogenesis at different times of evaluation.

Day	Angiogenesis of treatment group		
	3	5	7
3	-	0.005*	0.024*
5	-	-	0.365
7	-	-	-

Discussion

The antioxidant properties of substrates contained in okra fruit extract may promote wound healing by means of eliminating the effect of reactive oxygen species (ROS), specifically donate an antioxidant electron to prevent ROS catching electron from the other important molecule, such as DNA, protein, and lipid [13]. Therefore, the inflammatory process will take place normally, followed by the subsequent phase, proliferation. Angiogenesis will arise following the inflammation process, which is essential in wound healing.

The proliferation phase comprises re-epithelization, angiogenesis, granulated tissue formation, collagen deposition, which will start on day-4 until 2 weeks after injury. The proliferation phase denotes the earlier-formed matrices formation during the hemostasis, which will be replaced by granulated tissue, which mostly consists of fibroblast, granulocyte, macrophage, and the newly-formed capillaries. The migration and proliferation of fibroblast cells constitute a response toward the growth factors, namely platelet derivate growth factor (PDGF), tumor growth factor- β (TGF- β), b fibroblast growth factor (bFGF), which are secreted by platelets and macrophages. Subsequent to migration, fibroblast will proliferate and secrete proteinase, such as matrix metalloproteinase (MMP) to degrade the surrounding matrices and replace it with collagen and extracellular matrices (ECM) [14,15]. Fibroblast growth factors (FGF) denotes a pleiotropic factor involved in controlling several basic processes, namely cell proliferation, differentiation, and survival; also angiogenesis [16]. FGF may stimulate receptors in endothelial cells (EC) or induce the release of proangiogenic factors from the other cells [17].

During the wound healing process, fibroblasts come from the healthy adjacent tissues that migrate to the injury area through the cross-linking fibers and subsequently secrete bFGF or FGF-7, VEGF-A, and IGF-1 which act as the signal transducer toward the contiguous keratinocyte. The wound healing process may take place well if there are continuous increase of keratinocyte proliferation [17,18]. This is in line with the result of this study, which revealed that angiogenesis in the treatment group was higher than the control group throughout the observation days.

Fibroblast secretes angiogenetic factors. One of the growth factors that plays role in angiogenesis is PDGF, which is a growth factor that mainly secreted by platelet during the inflammatory stage, macrophage during the proliferative stage, endothelial cells, and keratinocyte cells. Aside from initiating angiogenesis by stimulating the maturation of newly-formed capillaries, PDGF also denotes one of the important growth factors with several functions in wound healing process. Those functions are, stimulates neutrophils and macrophages migration to the wound area, stimulates fibroblasts migration and proliferation for collagen synthesis [19].

Angiogenesis will be activated by the angiogenetic factors such as VEGF, PDGF, FGF and serin thrombin protease [20] in which are secreted by fibroblast cells [14,15]. Angiogenesis plays role in the initiating proliferation process during wound healing mechanism [20]. Angiogenesis denotes a crucial process during wound healing since it produces new capillaries to provide nutrition and oxygen, also dispose of the metabolism remnants [1]. VEGF denotes an angiogenetic factor that plays important role in new capillaries formation after injury, which can be observed during the angiogenesis process along the proliferative stage of wound healing [18]. VEGF constitutes one of specific cytokine that secreted after the injury and also a vascular permeability factor that may increase the capillary permeability [15].

Those aforementioned factors are the possible causes of the significant differences found between the treatment group and the control group in the same day. Besides, it also explains the notable increase of angiogenesis from day-3 to day-5. This result is in line with previous study, which stated that angiogenesis constitutes new blood vessels formation process to promote tissue regeneration, thus allow a normal wound healing. Angiogenesis takes place on day-3 to day-5 after injury [21].

Okra fruit contains other substances, such as quercetin, which beside act as an antioxidant, also has anti-tumor properties. Anti-tumor properties of quercetin relate to its ability to prevent tumor vascularization by inhibiting the growth and migration of endothelial cells [22]. Previous study discovered that quercetin is able to inhibit several key step in angiogenesis, including endothelial proliferation, migration, and also

formation by means of inhibit the VEGF-induced phosphorylation, and upstream kinase phosphorylation of protein kinase B (AKT), and also ribosomal protein s6 kinase [23]. This may explain the increase of angiogenesis until day-5, and decrease on day-7, although not a significant one.




Conclusion

The rate of angiogenesis in the group treated with okra fruit extract at 30% concentration is higher than the control group. Therefore, okra fruit extract at 30% concentration is able to promote angiogenesis in post-extracted tooth socket of Wistar rats.

Acknowledgement

The authors would like to thank Yuniar Aliyah Risky for the help in conducting this research.

Authors' Contributions

ML	 XXXX-XXXX-XXXX-XXX	Conceptualization, Methodology, Investigation, Formal Analysis, Writing – Original Draft Preparation and Writing – Review and Editing.
WSJ	 XXXX-XXXX-XXXX-XXX	Conceptualization, Methodology, Investigation, Formal Analysis, Writing – Original Draft Preparation and Writing – Review and Editing.
YAR	 XXXX-XXXX-XXXX-XXX	Conceptualization, Methodology, Investigation, Formal Analysis, Writing – Original Draft Preparation and Writing – Review and Editing.

All authors declare that they contributed to critical review of intellectual content and approval of the final version to be published.

Financial Support

None.

Conflict of Interest

The authors declare no conflicts of interest.

References

- [1] Demidova-Rice TN, Durham JT, Herman IM. Wound healing angiogenesis: innovations and challenges in acute and chronic wound healing. *Adv Wound Care* 2012; 1(1):17-22. <https://doi.org/10.1089/wound.2011.0308>
- [2] Ngangi RS. Gambaran Pencabutan Gigi Di Balai Pengobatan Rumah Sakit Gigi Dan Mulut Universitas Sam Ratulangi Tahun 2012. *e-GIGI* 2013; 1(2):1-7. <https://doi.org/10.35790/eg.1.2.2013.3211> [In Indonesian]
- [3] Khoswanto C. The effect of mengkudu gel (*Morinda citrifolia* Linn.) in accelerating the escalation of fibroblastpost extraction. *Dent J* 2010; 43(1):31-4. <https://doi.org/10.20473/j.djmk.v43.i1.p31-34>
- [4] Ferreira E, Lucas R, Rossi LA, Andrade D. Dressing of burned patients' wounds: a literature review. *Rev Esc Enferm USP* 2003; 37(10):44-51. <https://doi.org/10.1590/S0080-62342003000100006>
- [5] Agus P, Rizqiwani A, Auliyah NS. The effect of sand sea cucumber (*holothuria scabra*) extract on the amount of fibroblast on tooth socket after tooth extraction on cavia cobaya. *Oral Maxillofac Surg J* 2015; 4(2):1-6.
- [6] Nesa M, Islam M, Alam B, Munira S, Mollika S, Naher N, et al. Analgesic, anti-inflammatory and CNS depressant activities of the methanolic extract of *Abelmoschus esculentus* Linn. seed in mice. *Br J Pharm Res* 2014; 4(7):849-60. <https://doi.org/10.9734/BJPR/2014/7845>
- [7] Bello HS, Mustapha A, Isa MA, Rahila TC. The in vitro antibacterial activity of okra (*Abelmoschus esculentus*) against some selected bacteria from Maiduguri, North Eastern Nigeria. *Int J Biosci Nanosci* 2015; 2(4):84-8.
- [8] Kumar DS, Tony DE, Kumar AP, Kumar KA, Rao DBS, Nadendla R. A review on: *Abelmoschus esculentus* (Okra). *Int Res J Pharm App Sci* 2013; 3(4):129-32.
- [9] Soemarie YB. Uji aktivitas antiinflamasi kuersetin kulit bawang merah (*Allium cepa* L.) pada mencit putih jantan (*Mus musculus*). *J Ilmiah Ibnu Sina* 2016; 1(2):163-72. <https://doi.org/10.36387/jiis.v1i2.46> [In Indonesian]
- [10] Talubmook C, Buddhakala N. Bioactivities of extracts from *Tinospora crispa* stems, *Annona squamosa* leaves, *Musa sapientum* flowers, and *Piper sarmentosum* leaves in diabetic rats. *Int J Adv Res Technol* 2013; 2(6):144-9.

- [11] Gunawan F, Sularsih S, Soemartono S. Perbedaan kitosan berat molekul rendah dan tinggi terhadap jumlah sel limfosit pada proses penyembuhan luka pencabutan gigi. *Dent J Kedokt Gigi* 2015; 9(1):113-22.
- [12] Di Carlo S, De Angelis F, Brauner E, Rosella D, Papi P, Pompa G, et al. Histological and immunohistochemical evaluation of mandibular bone tissue regeneration. *Int J Immunopathol Pharmacol* 2018; 32:205873841879824. <https://doi.org/10.1177/2058738418798249>
- [13] Pisoschi AM, Pop A. The role of antioxidants in the chemistry of oxidative stress: a review. *Eur J Med Chem* 2015; 97:55-74. <https://doi.org/10.1016/j.ejmech.2015.04.040>
- [14] Qing C. The molecular biology in wound healing & non-healing wound. *Chin J Traumatol* 2017; 20(4):189-93. <https://doi.org/10.1016/j.cjtee.2017.06.001>
- [15] Jimenez PA, Jimenez SE. Tissue and cellular approaches to wound repair. *Am J Surg* 2004; 187(5A):56S-64S. [https://doi.org/10.1016/S0002-9610\(03\)00305-2](https://doi.org/10.1016/S0002-9610(03)00305-2)
- [16] Yun YR, Won JE, Jeon E, Lee S, Kang W, Jo H, et al. Fibroblast growth factors: biology, function, and application for tissue regeneration. *J Tissue Eng* 2010; 2010:218142. <https://doi.org/10.4061/2010/218142>
- [17] Draoui N, de Zeeuw P, Carmeliet P. Angiogenesis revisited from a metabolic perspective: role and therapeutic implications of endothelial cell metabolism. *Open Biol* 2017; 7(12):170219. <https://doi.org/10.1098/rsob.170219>
- [18] Gonzalez ACO, Costa TF, Andrade ZA, Medrado ARAP. Wound healing - a literature review. *An Bras Dermatol* 2016; 91(5):614-20. <https://doi.org/10.1590/abd1806-4841.20164741>
- [19] Krzyszczyk P, Schloss R, Palmer A, Berthiaume F. The role of macrophages in acute and chronic wound healing and interventions to promote pro-wound healing phenotypes. *Front Physiol* 2018; 9:419. <https://doi.org/10.3389/fphys.2018.00419>
- [20] Honnegowda TM, Kumar P, Udupa EGP, Kumar S, Kumar U, Rao P. Role of angiogenesis and angiogenic factors in acute and chronic wound healing. *Plast Aesthetic Res* 2015; 2:243-9. <https://doi.org/10.4103/2347-9264.165438>
- [21] Honnegowda TM, Kumar P, Padmanabha Udupa EG, Sharan A, Singh R, Prasad HK, et al. A comparative study to evaluate the effect of limited access dressing (LAD) on burn wound healing. *Int Wound J* 2016; 13(5):791-8. <https://doi.org/10.1111/iwj.12384>
- [22] Xia F, Zhong Y, Li M, Chang Q, Liao Y, Liu X, et al. Antioxidant and anti-fatigue constituents of okra. *Nutrients* 2015, 7(10):8846-58. <https://doi.org/10.3390/nu7105435>
- [23] Pratheeshkumar P, Budhreja A, Son YO, Wang X, Zhang Z, Ding S, et al. Quercetin inhibits angiogenesis mediated human prostate tumor growth by targeting VEGFR- 2 regulated AKT/mTOR/P70S6K signaling pathways. *PLoS One* 2012; 7(10):e47516. <https://doi.org/10.1371/journal.pone.0047516>