



MUHAMMAD LUTHFI <m.luthfi@fkg.unair.ac.id>

[DRJ]:Article for re-revision:DRJ_1008_20

2 pesan

Dental Research Journal <editor@drjournal.net>

30 Januari 2021 02.33

Balas Ke: n_naghsh@dnt.mui.ac.ir

Kepada: m.luthfi@fkg.unair.ac.id

If you cannot see this page properly, please [click here](#).

Dear Dr. Luthfi,

NOTE: This e-mail is sent to you as one of the contributing authors. If you are not corresponding author, please co-ordinate with the author designated by your group as the corresponding author for this manuscript

Status of the manuscript titled 'The Efficacy of Okra Fruit Extract on The Expression of TGF- β 1 in The Tooth Socket of Diabetic Wistar Rats' submitted by Dr. Muhammad Luthfi has been changed and a copy of the mail is as;

Dear Dr. Luthfi,

With reference to your manuscript entitled 'The Efficacy of Okra Fruit Extract on The Expression of TGF- β 1 in The Tooth Socket of Diabetic Wistar Rats', please review the comments of the referees from our site <https://www.journalonweb.com/drj>. The manuscript would be reconsidered after requisite modifications as per the comments and instructions provided by the journal.

If you wish to continue with the publication process, kindly make the changes according to the comments and upload the revised manuscript from the site along with the point to point clarifications to the comments indicating clearly where in the manuscript the changes have been carried out. Do check the FAQ related to replying to the comments and uploading a file. The contributors' form/images should be sent separately to the Administrative Office of the journal.

The journal allows two weeks for the revision of the manuscript. If we do not hear from you within this period, we will consider it your non-desire to continue the article with us. Please also note that submission of revised article does not guarantee its final acceptance by the journal.

We thank you for submitting your valuable research work to Dental Research Journal.

With warm personal regards,

Editor

Dental Research Journal

Remarks:

1-The whole manuscript needs English editing

2-Please write "abstract" and "Reference" parts on the basis of author guidelines.

Message sent on Friday, January 29, 2021

Please add editor@drjournal.net as a contact in your E-mail client to ensure that this mail is not considered as a junk mail.

--- END OF MESSAGE ---

MUHAMMAD LUTHFI <m.luthfi@fkg.unair.ac.id>
Kepada: Ratih Irmalia <ratihirmalia@yahoo.com>

31 Januari 2021 22.00

----- Forwarded message -----

Dari: **Dental Research Journal** <editor@drjournal.net>

Date: Sab, 30 Jan 2021 pukul 02.34

Subject: [DRJ]:Article for re-revision:DRJ_1008_20

To: <m.luthfi@fkg.unair.ac.id>

If you cannot see this page properly, please [click here](#).

Dear Dr. Luthfi,

NOTE: This e-mail is sent to you as one of the contributing authors. If you are not corresponding author, please co-ordinate with the author designated by your group as the corresponding author for this manuscript

Status of the manuscript titled 'The Efficacy of Okra Fruit Extract on The Expression of TGF- β 1 in The Tooth Socket of Diabetic Wistar Rats' submitted by Dr. Muhammad Luthfi has been changed and a copy of the mail is as;

Dear Dr. Luthfi,

With reference to your manuscript entitled 'The Efficacy of Okra Fruit Extract on The Expression of TGF- β 1 in The Tooth Socket of Diabetic Wistar Rats', please review the comments of the referees from our site <https://www.journalonweb.com/drj>. The manuscript would be reconsidered after requisite modifications as per the comments and instructions provided by the journal.

If you wish to continue with the publication process, kindly make the changes according to the comments and upload the revised manuscript from the site along with the point to point clarifications to the comments indicating clearly where in the manuscript the changes have been carried out. Do check the FAQ related to replying to the comments and uploading a file. The contributors' form/images should be sent separately to the Administrative Office of the journal.

The journal allows two weeks for the revision of the manuscript. If we do not hear from you within this period, we will consider it your non-desire to continue the article with us. Please also note that submission of revised article does not guarantee its final acceptance by the journal.

We thank you for submitting your valuable research work to Dental Research Journal.

With warm personal regards,

Editor

**Dental Research Journal
Remarks:**

1-The whole manuscript needs English editing

2-Please write “abstract” and “Reference” parts on the basis of author guidelines.

Message sent on Friday, January 29, 2021

Please add editor@drjjournal.net as a contact in your E-mail client to ensure that this mail is not considered as a junk mail.

---- END OF MESSAGE ----



MUHAMMAD LUTHFI <m.luthfi@fkg.unair.ac.id>

[DRJ]:Article for re-revision:DRJ_1008_20

2 pesan

Dental Research Journal <editor@drjournal.net>

30 Januari 2021 02.33

Balas Ke: n_naghsh@dnt.mui.ac.ir

Kepada: m.luthfi@fkg.unair.ac.id

If you cannot see this page properly, please [click here](#).

Dear Dr. Luthfi,

NOTE: This e-mail is sent to you as one of the contributing authors. If you are not corresponding author, please co-ordinate with the author designated by your group as the corresponding author for this manuscript

Status of the manuscript titled 'The Efficacy of Okra Fruit Extract on The Expression of TGF- β 1 in The Tooth Socket of Diabetic Wistar Rats' submitted by Dr. Muhammad Luthfi has been changed and a copy of the mail is as;

Dear Dr. Luthfi,

With reference to your manuscript entitled 'The Efficacy of Okra Fruit Extract on The Expression of TGF- β 1 in The Tooth Socket of Diabetic Wistar Rats', please review the comments of the referees from our site <https://www.journalonweb.com/drj>. The manuscript would be reconsidered after requisite modifications as per the comments and instructions provided by the journal.

If you wish to continue with the publication process, kindly make the changes according to the comments and upload the revised manuscript from the site along with the point to point clarifications to the comments indicating clearly where in the manuscript the changes have been carried out. Do check the FAQ related to replying to the comments and uploading a file. The contributors' form/images should be sent separately to the Administrative Office of the journal.

The journal allows two weeks for the revision of the manuscript. If we do not hear from you within this period, we will consider it your non-desire to continue the article with us. Please also note that submission of revised article does not guarantee its final acceptance by the journal.

We thank you for submitting your valuable research work to Dental Research Journal.

With warm personal regards,

Editor

Dental Research Journal

Remarks:

1-The whole manuscript needs English editing

2-Please write "abstract" and "Reference" parts on the basis of author guidelines.

Message sent on Friday, January 29, 2021

Please add editor@drjournal.net as a contact in your E-mail client to ensure that this mail is not considered as a junk mail.

--- END OF MESSAGE ---

MUHAMMAD LUTHFI <m.luthfi@fkg.unair.ac.id>
Kepada: Ratih Irmalia <ratihirmalia@yahoo.com>

31 Januari 2021 22.00

----- Forwarded message -----

Dari: **Dental Research Journal** <editor@drjournal.net>

Date: Sab, 30 Jan 2021 pukul 02.34

Subject: [DRJ]:Article for re-revision:DRJ_1008_20

To: <m.luthfi@fkg.unair.ac.id>

If you cannot see this page properly, please [click here](#).

Dear Dr. Luthfi,

NOTE: This e-mail is sent to you as one of the contributing authors. If you are not corresponding author, please co-ordinate with the author designated by your group as the corresponding author for this manuscript

Status of the manuscript titled 'The Efficacy of Okra Fruit Extract on The Expression of TGF- β 1 in The Tooth Socket of Diabetic Wistar Rats' submitted by Dr. Muhammad Luthfi has been changed and a copy of the mail is as;

Dear Dr. Luthfi,

With reference to your manuscript entitled 'The Efficacy of Okra Fruit Extract on The Expression of TGF- β 1 in The Tooth Socket of Diabetic Wistar Rats', please review the comments of the referees from our site <https://www.journalonweb.com/drj>. The manuscript would be reconsidered after requisite modifications as per the comments and instructions provided by the journal.

If you wish to continue with the publication process, kindly make the changes according to the comments and upload the revised manuscript from the site along with the point to point clarifications to the comments indicating clearly where in the manuscript the changes have been carried out. Do check the FAQ related to replying to the comments and uploading a file. The contributors' form/images should be sent separately to the Administrative Office of the journal.

The journal allows two weeks for the revision of the manuscript. If we do not hear from you within this period, we will consider it your non-desire to continue the article with us. Please also note that submission of revised article does not guarantee its final acceptance by the journal.

We thank you for submitting your valuable research work to Dental Research Journal.

With warm personal regards,

Editor

**Dental Research Journal
Remarks:**

1-The whole manuscript needs English editing

2-Please write “abstract” and “Reference” parts on the basis of author guidelines.

Message sent on Friday, January 29, 2021

Please add editor@drjjournal.net as a contact in your E-mail client to ensure that this mail is not considered as a junk mail.

---- END OF MESSAGE ----



MUHAMMAD LUTHFI <m.luthfi@fkg.unair.ac.id>

[DRJ]:Article for re-revision:DRJ_1008_20

2 pesan

Dental Research Journal <editor@drjournal.net>

30 Januari 2021 02.33

Balas Ke: n_naghsh@dnt.mui.ac.ir

Kepada: m.luthfi@fkg.unair.ac.id

If you cannot see this page properly, please [click here](#).

Dear Dr. Luthfi,

NOTE: This e-mail is sent to you as one of the contributing authors. If you are not corresponding author, please co-ordinate with the author designated by your group as the corresponding author for this manuscript

Status of the manuscript titled 'The Efficacy of Okra Fruit Extract on The Expression of TGF- β 1 in The Tooth Socket of Diabetic Wistar Rats' submitted by Dr. Muhammad Luthfi has been changed and a copy of the mail is as;

Dear Dr. Luthfi,

With reference to your manuscript entitled 'The Efficacy of Okra Fruit Extract on The Expression of TGF- β 1 in The Tooth Socket of Diabetic Wistar Rats', please review the comments of the referees from our site <https://www.journalonweb.com/drj>. The manuscript would be reconsidered after requisite modifications as per the comments and instructions provided by the journal.

If you wish to continue with the publication process, kindly make the changes according to the comments and upload the revised manuscript from the site along with the point to point clarifications to the comments indicating clearly where in the manuscript the changes have been carried out. Do check the FAQ related to replying to the comments and uploading a file. The contributors' form/images should be sent separately to the Administrative Office of the journal.

The journal allows two weeks for the revision of the manuscript. If we do not hear from you within this period, we will consider it your non-desire to continue the article with us. Please also note that submission of revised article does not guarantee its final acceptance by the journal.

We thank you for submitting your valuable research work to Dental Research Journal.

With warm personal regards,

Editor

Dental Research Journal

Remarks:

1-The whole manuscript needs English editing

2-Please write "abstract" and "Reference" parts on the basis of author guidelines.

Message sent on Friday, January 29, 2021

Please add editor@drjjournal.net as a contact in your E-mail client to ensure that this mail is not considered as a junk mail.

--- END OF MESSAGE ---

MUHAMMAD LUTHFI <m.luthfi@fkg.unair.ac.id>
Kepada: Ratih Irmalia <ratihirmalia@yahoo.com>

31 Januari 2021 22.00

----- Forwarded message -----

Dari: **Dental Research Journal** <editor@drjjournal.net>

Date: Sab, 30 Jan 2021 pukul 02.34

Subject: [DRJ]:Article for re-revision:DRJ_1008_20

To: <m.luthfi@fkg.unair.ac.id>

If you cannot see this page properly, please [click here](#).

Dear Dr. Luthfi,

NOTE: This e-mail is sent to you as one of the contributing authors. If you are not corresponding author, please co-ordinate with the author designated by your group as the corresponding author for this manuscript

Status of the manuscript titled 'The Efficacy of Okra Fruit Extract on The Expression of TGF- β 1 in The Tooth Socket of Diabetic Wistar Rats' submitted by Dr. Muhammad Luthfi has been changed and a copy of the mail is as;

Dear Dr. Luthfi,

With reference to your manuscript entitled 'The Efficacy of Okra Fruit Extract on The Expression of TGF- β 1 in The Tooth Socket of Diabetic Wistar Rats', please review the comments of the referees from our site <https://www.journalonweb.com/drj>. The manuscript would be reconsidered after requisite modifications as per the comments and instructions provided by the journal.

If you wish to continue with the publication process, kindly make the changes according to the comments and upload the revised manuscript from the site along with the point to point clarifications to the comments indicating clearly where in the manuscript the changes have been carried out. Do check the FAQ related to replying to the comments and uploading a file. The contributors' form/images should be sent separately to the Administrative Office of the journal.

The journal allows two weeks for the revision of the manuscript. If we do not hear from you within this period, we will consider it your non-desire to continue the article with us. Please also note that submission of revised article does not guarantee its final acceptance by the journal.

We thank you for submitting your valuable research work to Dental Research Journal.

With warm personal regards,

Editor

**Dental Research Journal
Remarks:**

1-The whole manuscript needs English editing

2-Please write “abstract” and “Reference” parts on the basis of author guidelines.

Message sent on Friday, January 29, 2021

Please add editor@drjjournal.net as a contact in your E-mail client to ensure that this mail is not considered as a junk mail.

---- END OF MESSAGE ----

Full title : The Efficacy of Okra Fruit Extract on the Expression of TGF- β 1 in the Tooth Socket of Diabetic Wistar Rats

Short title : Okra fruit extract on wound healing

ABSTRACT

Background: Patients with diabetes mellitus suffer from an additional macrophage dysfunction in the secretion of growth factor, which later decreases TGF- β 1. This condition disrupts proliferation and angiogenesis. Extract of okra fruit (*Abelmoschus esculentus*) contains flavonoid, an active substance which acts as antioxidant, anti-inflammation, and anti-diabetes. The purpose of this study is to analyze the difference in TGF- β 1 expression in wound healing process after tooth extraction of diabetic Wistar rats.

Materials and Methods: This is a laboratory experimental study using pre-test and post-test on 24 Wistar rats which are divided into 2 groups: control group (treated with streptozocin induction but without administration of okra fruit extract) and treatment group (treated with streptozocin induction and oral administration of 250 mg/kg okra fruit extract once a day). Extractions of the rats' mandibular left incisors were performed using a pair of modified forceps and an elevator. The tooth sockets were then irrigated using saline solution. Four rats in each group were sacrificed on day 3 (KO1, PO1), 5 (KO2, PO2), and 7 (KO3, PO3). The socket tissues from the rats were then immunohistochemically analyzed.

Result: the average level of TGF- β 1 expression in the treatment groups was higher compared to the control group: PO1 (11.59 ± 0.58), PO2 (15.15 ± 1.07), and PO3 (18.75 ± 2.73) as compared to KO1 (5.32 ± 1.69), KO2 (8.47 ± 0.60), and KO3 (9.28 ± 1.16) with p value of 0.001.

Conclusion: The administration of okra fruit extract can increase the level of TGF- β 1 in wounds after tooth extraction of diabetic Wistar rats.

Keyword: diabetes mellitus, TGF- β 1, wound healing

INTRODUCTION

Wound healing is a complex biological process involving hemostasis, inflammation, proliferation, and remodeling.^[1] On the third day of wound healing process, there is a transition from inflammatory phase to proliferation phase, in which a transition from macrophage-1 (M1) to macrophage-2 (M2) occurs. The fifth day is the proliferation phase, in which fibroblasts are transferred to the injured area and M2 plays a dominant role as an anti-inflammatory agent. On the seventh day, the angiogenesis phase reaches its peak.^[2,3] It is also known that healing process is influenced by systemic factors, one of which is comorbidities, such as diabetes mellitus (DM). DM is known to cause macrophage dysfunction in the patients.^[4]

Wound healing process involves a series of activities of damage repair. Prolonged high-blood glucose level may causes a prolonged inflammatory process and high anti-inflammatory activity.^[5] Specifically, in gingival wound healing process in diabetic patients in which insulin-induced fibroblasts dysfunction occurs soon after tooth extraction, associated with a decrease in the level of TGF- β 1 gene expression.^[6] TGF- β 1 expression plays dominant role in wound recovery among other TGF- β isoforms because TGF- β 1 functions to increase proliferation, collagen formation, and differentiation of fibroblasts in the wound proliferation phase. Besides, TGF- β 1 also plays role in forming extracellular matrix (ECM) secretion and those related to morphological proliferation, mononuclear cell differentiation, and osteocytes. TGF- β 1 is involved in angiogenesis by increasing the regulation of vascular endothelial growth factor (VEGF). During wound closure process, TGF- β 1 increases keratinocyte transfer.^[7]

Along with the advancement of science, various treatments have been developed to overcome this problem, one of which uses herbal ingredients. Herbs are in great demand and are used by around 80% of the world's population because of the benefits in terms of safety,

effectiveness, cultural acceptance, and less substantial side effects as compared to synthetic chemicals.^[8] One herb that can accelerate wound healing process is the fruit of okra plant (*Abelmoschus esculentus*).

Okra fruit has antioxidant, anti-inflammatory,^[9] and anti-diabetic^[10] qualities in the process of wound healing. The antioxidant quality of okra is needed in the process of wound healing to eliminate the effects of reactive oxygen species (ROS). Okra fruit's anti-inflammatory feature decreases the production of pro-inflammatory mediators, such as nitric oxide and ROS, and the production of Tumor Necrosis Factor α (TNF- α) and Interleukin-1 β (IL-1 β) stimulated by liposaccharide (LPS).^[9] Flavonoids found in okra fruit also play a role in lowering blood glucose level due to its isoquercetin content which regulates the level of blood glucose and increases immunoreactivity of pancreatic β -cells. In addition, it also has a role in wound healing process.^[9,10] The objective of this study is to calculate the level of expression of TGF- β 1 in post tooth extraction wound healing process in Wistar rats with diabetes mellitus. In addition, this study also aims to verify that administration of okra fruit extract can increase TGF- β 1 expression in post tooth extraction wound healing process in Wistar rats with DM.

MATERIAL AND METHODS

Research Design and Animal Model

Wistar rats used as samples in this study were obtained from the Experimental Animal Unit of the Biochemical Laboratory of the Faculty of Medicine, Universitas Airlangga. Ethical clearance of the research was issued by the Health Research Ethical Clearance Commission with a clearance certificate numbered 231/HRECC.FODM/V/2019.

Collection, adjustment, maintenance, and treatment were carried out in the Experimental Animal Unit of the Biochemical Laboratory of the Faculty of Medicine, Universitas Airlangga. Okra fruit was extracted in *Materia Medika Batu*. Histological preparations were carried out at the Anatomy Pathology Laboratory of the Faculty of Medicine, Universitas Airlangga. Immunohistochemistry dyeing and TGF- β 1 expression calculation were carried out at Brawijaya University, Malang.

Okra fruit extract preparation

Fresh okra fruit collected for the study was dried in a drying oven until a constant weight was reached. The dried fruit was then ground into powder. A total of 2 grams of powder was extracted with 20 ml of 70% ethanol in a ratio of 1:10 (w/v) during the maceration period (24 hours) at room temperature. The mixture of solvent and soaked powder was filtered through filter paper and then concentrated to 1 ml with a rotary evaporator and diluted with 5% dimethyl sulfoxide (DMSO) at a ratio of 1:1 (v/v). The results were then stored at a temperature of -20°C until further use.^[11]

Research Procedure

In this study, 24 male Wistar rats aged 2-3 months with a weight of 150-200 grams were adapted in the same cage at $25 \pm 2^{\circ}\text{C}$. The 24 Wistar rats were divided into 2 groups (control group and treatment group). The rats were supplied with standard pellet food and distilled water *ad libitum* for 7 days and for 4 hours before being induced with streptozotocin

(STZ) (Nacalai Tesque Inc., Japan). The 2% STZ solution was dissolved with 0.1 mol/L citrate buffer solution pH 4.4 at a dose of 45 mg/kg and converted to a dose of 6.75 mg/150gr. The solution was then administered to the Wistar rats through intraperitoneal induction.^[12] Blood glucose levels were measured on day 3 after STZ induction by taking blood sample from the lateral veins in the rats' tails. Measurement were performed using a glucometer (Accu Chek® Instant). The Wistar rats were diagnosed with DM if the blood glucose levels ≥ 200 mg/dl after the STZ induction.^[13] The rats' weight during experiment were not measured.

Wistar rats with DM were then anesthetized through peritoneal injection using 0.1 ml of ketamine per rat. A resting period of 1-1.5 hours were given after the injection, after which extractions of the rats' mandibular left incisors were performed using a pair of modified forceps and an elevator. The tooth sockets were then irrigated with saline solution.^[14]

In the control group, the animals did not receive administration of okra fruit extract. Instead, they were only supplied with distilled water prior to the observation. K_{O1} was observed on the 3rd day, K_{O2} was observed on the 5th day, and K_{O3} was observed on the 7th day. In the treatment group, the rats were given oral administration of okra fruit extract after the tooth extraction with a dose of 250 mg/kg which was converted to a dose of 37.5 mg/150 gr once a day during the treatment. P_{O1} was observed on the 3rd day, P_{O2} was observed on 5th day, and P_{O3} was observed on 7th day.

Wistar rats were sacrificed on the 3rd, 5th and 7th day using lethal injection of intraperitoneal ketamine (no less than 4 times the anesthetic dose or about 0.4 ml/kg). The mandibular of each rat was taken from the temporomandibular joint. After which, the Wistar rats were buried according to the ethical treatments of experimental animals. The mandibles in the incisor area were cut vertically and treated with paraffin method.

Histopathological Specimen Preparation

The histological examination procedure was started by putting the tissues into formalin buffer (10% formalin solution in Phosphate-Buffered Saline pH-7) to be fixed and then put in to paraffin wax. The tissues were cut into slides with a length of 4-6 mm on the glass slide. After being deparaffinized with xylene, the slides were submerged in graded alcohol for dehydration and incubation with EDTA (pH = 8.0) in a microwave oven (750 W) to take TGF- β 1 antigens. Slides were incubated for 20 minutes in 3% H₂O₂ to inhibit endogenous peroxidase activity, and then rinsed three times with phosphate saline buffer (PBS) for 5 minutes each. The slides were then incubated with blocking solutions using a superbloc (Scy Tek Laboratories Inc., US) and peroxide block (Scy Tek Laboratories Inc., US). Slides were incubated overnight with TGF- β 1 antibodies (ab 27969: abcam, Burlingame, US). After being washed in PBS, the slides were treated with UltraTek anti-polyvalent biotinylated antibodies (Scy Tech Laboratories Inc., US) and UltraTek HRP (Scy Tek Laboratories Inc., US). This reaction was visualized by incubating the slides for 7 minutes in 0.1% 3,3-diaminobenzidine and 0.02% hydrogen peroxide solution. Slides were then counterstained with Mayer's hematoxylin (Scy Tech Laboratories Inc., US) and covered. Immunohistochemical positive staining was defined as the detection of brown chromogen from DAB Chromogen staining (Scy Tech Laboratories Inc., US) at the edge of the hematoxylin-stained nucleus distributed in the cytoplasm or plasma cell membrane and analyzed under a light microscope with 1000x magnification at 20 visual fields. TGF- β 1 expression would be seen as positive, immune-reactive cells with a yellowish to brown color, while negative cells would correspond to the counterstain coloring agent used.^[15]

Statistical Analysis

Statistical analysis was performed using SPSS (IBM SPSS Statistics for Windows, Version 24.0: IBM Corp., USA). Shapiro-Wilk test was used to find out normally distributed data. After the distribution test, Levene's homogeneity test was then performed. Once the distribution was found normal and the data was homogeneous, the analysis was continued with One Way ANOVA test and with multiple comparison test using Tukey HSD test.

RESULTS

Based on the laboratory experiment using 24 Wistar rats which were divided into control (K_0) and treatment (P_0) groups, the researchers have observed the wounds from the extraction of the left maxillary incisors on day 3, 5, and 7 to measure the number of TGF- β 1 expression in the wound healing process after tooth extraction of Wistar rats with DM. The blood glucose level of all rats was above 200mg/dl after the induction. TGF- β 1 examination was carried out under a light microscope with 1000x magnification at 20 visual fields (Figure 1).

We observed the expression of TGF- β 1 both with and without okra fruit extract administration. The ANOVA test showed a significant difference among the groups (Table 1). Meanwhile, the multiple comparison test result using Tukey HSD showed a significant increase of TGF- β 1 expression observed on day 3, 5, and 7 in the control group. Likewise, the treatment group also exhibited the same results for day 3, 5, and 7 (Table 2).

TGF- β 1 expressions on days 3, 5, and 7 on the prepared Wistar rats' socket tissues with DM were calculated using a light microscope with 400x magnification at 4 visual fields (Figure 1). TGF- β 1 expression appears as gradients of yellow to brown stains pointed with arrows. Based on Figure 2, it can be seen that on the 3rd day, P_{O1} group showed increasing number of TGF- β 1 expression as compared to K_{O1} group. On the 5th day, P_{O2} showed increasing number of TGF- β 1 expression as compared to K_{O2} group. On the 7th day, P_{O3} showed increasing number of TGF- β 1 expression as compared to K_{O3} group.

DISCUSSION

This research aims to prove that okra fruit extract can increase the expression of TGF- β 1 in wound healing process after tooth extraction in Wistar rats with DM. The observations of TGF- β 1 expression were carried out on day 3, 5, and 7. Since the 3rd day of the wound healing process, a transition from inflammatory phase to proliferation phase has taken place. During the same phase, macrophage-1 (M1) goes under transition to become macrophage-2 (M2). However, the number of M1 is still above M2. Whereas on the 5th day, M2 plays a more dominant role than M1 on the wounds. Proliferation phase also takes place during this time in which fibroblasts migrate to the wound area.^[3] Then, the peak of the angiogenesis phase starts on the 7th day.^[6] M2 acts as an anti-inflammatory in which macrophages release IL-10 and TGF- β , a very strong anti-inflammatory agent that immediately stops the inflammatory process and starts the proliferation phase.^[4] This is the reason why we as researchers observed TGF- β 1 expression as one of the important growth factors in wound healing process.

The results of our research confirm the hypothesis that the administration of okra fruit extract can increase TGF- β 1 expression in the wound healing process after tooth extraction of Wistar rats with DM. Observation were done by calculating the amount of TGF- β 1 expression in both groups, namely the control group (K) and the treatment group (P). In group K, the TGF- β 1 expression from Wistar tooth socket is less than in group P. However, in both K and P groups, we found that the highest number of TGF- β 1 expression on the 7th day, as compared to on the 3rd and 5th day. This is due to the fact that the healing process that involves fibroblasts cell infiltration to the wound occurs the most on the 7th day, thus the number of TGF- β 1 expression is higher than the 3rd and 5th day.^[3,4]

The mean number of TGF- β 1 expression in the K group shows lower results than the P group due to the STZ induction. A few days after the STZ induction, a damage occurs in

pancreatic beta cells which results in insulin resistance and high blood glucose level. In addition, the increased oxidative stress due to the formation of AGEs causes disruption of the fibroblast's proliferation, migration, and dysfunction.^[6]

Yamano et al., state that at the beginning of tooth extraction, the lowest amount of TGF- β 1 expression is obtained compared to the following day.^[16] In addition, a study by Hozzein et al., also infers that the administration of intraperitoneal STZ can cause a significant decrease in regulation of TGF- β 1 in wound tissue.^[17]

In DM patients, an uncontrolled glycemic control causes a disruption in wound healing process, which is a disturbance in the angiogenesis activity that causes pathogenesis mechanism.^[18] In group K, TGF- β 1 expression increased significantly on day 3 to 5, while on days 5 to 7, the expression of TGF- β 1 also increased, though not as significant. This is due to the fact that DM condition disrupts the innate role and function of immunity cells. High glucose level increases the cellular nuclear factor- κ B (NF- κ B) activation. If an injury occurs, the prolonged inflammatory phase results in a pro-inflammatory response that increases the occurrence of chronic inflammation and tissue damage.^[6]

High blood glucose level induces ROS which can be produced both enzymatically and non-enzymatically. Enzymatic production includes nicotinamide adenine dinucleotide phosphate oxidase (NADPH oxidase), nitric oxide synthase (NOS), cytochrome P-450, cyclooxygenase (COX), lipoxygenase (LOX), xanthine oxidase, and myeloperoxidase (MPO),^[19] and results in high pro-inflammatory cytokines which are released by neutrophils and macrophages as well as an increase in abnormal protease activity resulting in disruption of growth factor signaling in the wound healing process. This signaling disruption causes a decrease in growth factor and disrupts in the angiogenesis phase.^[13]

On the other hand, the P group had higher average TGF- β 1 as compared to K group due to the difference in okra fruit extract administration.^[20] Thus, it confirms the hypothesis

that okra fruit extract can increase TGF- β 1 expression. Okra extract has antioxidant, anti-inflammatory, and anti-diabetic qualities in wound healing process.^[8,10] Okra extract contains polyphenols, flavonoids, isoquercetin, and quercetin-3-O-gentiobiose. Flavonoid is useful to repair damaged cells and forms a normal wound healing process by inducing fibroplasia by TGF- β 1.^[21] Quercetin plays a role in regulating TGF- β 1 expression and decreasing the number of inflammatory cells. Quercetin also decreases the number of TNF- α , while increasing fibroblasts proliferation and micro blood vessel density, leading to better re-epithelialization and regular collagen deposition.^[22] Pang et al. state that low-dose flavonoid alone is able to stimulate TGF- β 1 expression which in turn increases TGF- β expression by macrophage stimulation induced by total flavonoids in wounds.^[23] TGF- β 1, secreted by M2 phenotype macrophages, plays a role in inhibiting the recruitment of inflammatory cells.^[24] TGF- β induces the keratinocyte and fibroblasts proliferation, causing the new capillaries formation in granulation tissue and modulation of extracellular matrix deposition resulting in wound healing. TGF- β 1 also plays a role in angiogenesis by increasing the regulation of VEGF. During wound closure, TGF- β 1 increases keratinocyte migration.^[17]

In addition to reducing pro-inflammatory mediator production, okra fruit plays a role in reducing nitric oxide amount and ROS, as well as in reducing the production of TNF- α .^[20] Excessive production of ROS causes activation of the NF- κ B signaling pathway. NF- κ B is a protein that stimulates cytokines and free radicals. It is also a transcription factor that regulates large numbers of genes involved in various immune and inflammatory response processes and causes vascular complications in DM patients and in inflammatory pathogenic processes that can be inhibited by flavonoids.^[21]

Flavonoid contained in okra fruit can reduce blood glucose level,^[10] resulting in a decrease in pro-inflammatory cytokines.^[20] High concentration of fiber and polysaccharides in the okra fruit can stabilize blood glucose by limiting the rate of absorption of sugar in the

intestine.^[25] This complements the flavonoid content of the okra fruit which functions as an inhibitor of α -amylase and α -glucosidase, the enzymes found in the small intestine^[21] which act as carbohydrate catalyst by catalyzing oligosaccharides so that glucose absorption may take place. Inhibition of α -glucosidase can cause catalysis of complex carbohydrate diets such as oligosaccharides and polysaccharides to be inhibited by monosaccharides resulting in decreased blood glucose level.^[10,12]

Glycoprotein-A repetitions predominant protein (GARP) is an important regulator in activating latent TGF- β (LTGF- β) and then binding it to LTGF- β . GARP acts as a docking receptor that functions as a carrier of LTGF- β on the cell surface, activating its role.^[7] GARP also plays role in the regulation of T lymphocytes (Tregs) that form complexes with the α V β 8 integrin to release active TGF- β from the cell surface.^[17] TGF- β 1 stimulates fibroblasts to differentiate into myofibroblasts and then collaborates with these myofibroblasts to produce extracellular matrix (ECM), as well as collagen and matrix proteins, namely fibronectin.^[5] TGF- β 1 together with VEGF and fibroblasts stimulate the angiogenesis process.^[17] This explains the higher expression of TGF- β 1 in P group as compared to K group. Therefore, it can accelerate wound healing process in P group.

CONCLUSION

The administration of okra fruit extract can increase the number of TGF- β 1 in tooth extraction wounds on Wistar rats with DM.

REFERENCES

1. Reinke JM, Sorg H. Wound Repair and Regeneration. *Eur Surg Res* 2012;49:35–43.
2. Benadiba M, Serruya R, Maor Y. Bioaccessibility of Shore Magic® collagen, a low-molecular-weight collagen supplement, in different in vitro barrier models. *Heliyon* 2018;4.
3. Du Y, Ren P, Wang Q, Jiang SK, Zhang M, Li JY, *et al.* Cannabinoid 2 receptor attenuates inflammation during skin wound healing by inhibiting M1 macrophages rather than activating M2 macrophages. *J Inflamm (United Kingdom)* 2018;15:25.
4. Anderson K, Hamm RL. Factors that impair wound healing. *J Am Coll Clin Wound Spec* 2012;4:84–91.
5. Zhao R, Liang H, Clarke E, Jackson C, Xue M. Inflammation in chronic wounds. *Int J Mol Sci* 2016;17.
6. Kido D, Mizutani K, Takeda K, Mikami R, Matsuura T, Iwasaki K, *et al.* Impact of diabetes on gingival wound healing via oxidative stress. Jandeleit-Dahm K, editor. *PLoS One* 2017;12:e0189601.
7. Liu Y, Li Y, Li N, Teng W, Wang M, Zhang Y, *et al.* TGF- β 1 promotes scar fibroblasts proliferation and transdifferentiation via up-regulating MicroRNA-21. *Sci Rep* 2016;6:1–9.
8. Bhowmik D, Sampath Kumar KP, Tripathi P. Traditional Herbal Medicines: An Overview. *Arch Appl Sci Res* 2009;1:165–77.
9. Solomon S. Anti-Oxidant and Anti-Inflammatory Activity of *Abelmoschus esculentus* (Flowers). *Indo Am J Pharm Sci* 2016:600–5.
10. Abbas AY, Muhammad I, AbdulRahman MB, Bilbis LS, Saidu Y, Onu A. Possible Antidiabetic Mechanism of Action of Ex-maradi Okra Fruit Variety

- (*Abelmoschus esculentus*) on Alloxan Induced Diabetic Rats. Niger J Basic Appl Sci 2018;25:101.
11. Yeo YL, Chia YY, Lee CH, Sow HS, Yap WS. Effectiveness of maceration periods with different extraction solvents on in-vitro antimicrobial activity from fruit of *Momordica charantia* L. J Appl Pharm Sci 2014;4:16–23.
 12. Tian Z-H, Miao F-T, Zhang X, Wang Q-H, Lei N, Guo L-C. Therapeutic effect of okra extract on gestational diabetes mellitus rats induced by streptozotocin. Asian Pac J Trop Med 2015;8:1038–42.
 13. Qinna NA, Badwan AA. Impact of streptozotocin on altering normal glucose homeostasis during insulin testing in diabetic rats compared to normoglycemic rats. Drug Des Devel Ther 2015;9:2515–25.
 14. Gunawan F, Sularsih S, Soemartono S. The Differences Effect Between Low and High MolecularWeight Chitosan on Number of Lymphocyte Cells in the Wound Healing Process of Dental Extraction. Dent J Kedokt Gigi 2015;9:113–22.
 15. Sula B, Deveci E, Özevren H, Ekinçi C, Elbey B. Immunohistochemical and histopathological changes in the skin of rats after administration of lead acetate. Int J Morphol 2016;34:918–22.
 16. Yamano S, Kuo WP, Sukotjo C. Downregulated gene expression of TGF- β s in diabetic oral wound healing. J Cranio-Maxillofacial Surg 2013;41.
 17. Hozzein WN, Badr G, Al Ghamdi AA, Sayed A, Al-Waili NS, Garraud O. Topical Application of Propolis Enhances Cutaneous Wound Healing by Promoting TGF-Beta/Smad-Mediated Collagen Production in a Streptozotocin-Induced Type I Diabetic Mouse Model. Cell Physiol Biochem 2015;37:940–54.
 18. Raghav A. Crucial Role of Diabetes Mellitus in Delayed Angiogenesis of Wound. J Pharmacol Clin Res 2018;5:4.

19. Fakhruddin S, Alanazi W, Jackson KE. Diabetes-Induced Reactive Oxygen Species: Mechanism of Their Generation and Role in Renal Injury. *J Diabetes Res* 2017;2017.
20. Shah BN, Seth AK. ANTI-INFLAMMATORY ACTIVITY OF FRUITS OF ABELMOSCHUS ESCULANTUS LINN. *Pharmacol online* 2010;1:208–12.
21. Roy A, Shrivastava SL, Mandal SM. Functional properties of Okra *Abelmoschus esculentus* L. (Moench): traditional claims and scientific evidences. *Plant Sci Today* 2014;1:121–30.
22. Gopalakrishnan A, Ram M, Kumawat S, Tandan S, Kumar D. Quercetin accelerated cutaneous wound healing in rats by increasing levels of VEGF and TGF- β 1 - PubMed. *Indian J Exp Biol* 2016;54:187–95.
23. Pang Y, Zhang Y, Huang L, Xu L, Wang K, Wang D, *et al.* Effects and mechanisms of total flavonoids from *Blumea balsamifera* (L.) DC. on skin wound in rats. *Int J Mol Sci* 2017;18.
24. Liu YC, Zou XB, Chai YF, Yao YM. Macrophage polarization in inflammatory diseases. *Int J Biol Sci* 2014;10:520–9.
25. Durazzo A, Lucarini M, Novellino E, Souto EB, Daliu P, Santini A. *Abelmoschus esculentus* (L.): Bioactive components' beneficial properties-focused on antidiabetic role-for sustainable health applications. *Molecules* 2019;24.

Table list

Table 1. Mean, standard deviation, and normality test of TGF-β1 expression in the control and treatment group.

Group	Mean ± SD	P value
KO1	5.32 ± 1.69	0.001
KO2	8.47 ± 0.60	
KO3	9.28 ± 1.16	
PO1	11.59 ± 0.58	
PO2	15.15 ± 1.07	
PO3	18.75 ± 2.73	

Table 2. Tukey HSD post-hoc multiple comparisons test results in the control and treatment group

Group	KO1	KO2	KO3
KO1		0.030*	0.009*
KO2	0.030*		0.710
Group	PO1	PO2	PO3
PO1		0.041*	0.001*
PO2	0.041*		0.039*

Remarks = * there is a significant difference

Figure list

Figure 1. Expression of TGF- β 1 in day 3, 5, and 7 in socket tissues of Wistar rats with diabetes mellitus in immunohistochemistry examination in microscope with 400x magnification in control group (K_O) and treatment group (P_O)

Figure 2. Mean value graph of TGF- β 1 expression on day 3, 5, and 7

Full title : The Efficacy of Okra Fruit Extract on the Expression of TGF- β 1 in the Tooth Socket of Diabetic Wistar Rats

Short title : Okra fruit extract on wound healing

ABSTRACT

Background: Patients with diabetes mellitus suffer from an additional macrophage dysfunction in the secretion of growth factor, which later decreases TGF- β 1. This condition disrupts proliferation and angiogenesis. Extract of okra fruit (*Abelmoschus esculentus*) contains flavonoid, an active substance which acts as antioxidant, anti-inflammation, and anti-diabetes. The purpose of this study is to analyze the difference in TGF- β 1 expression in wound healing process after tooth extraction of diabetic Wistar rats.

Materials and Methods: This is a laboratory experimental study using pre-test and post-test on 24 Wistar rats which are divided into 2 groups: control group (treated with streptozocin induction but without administration of okra fruit extract) and treatment group (treated with streptozocin induction and oral administration of 250 mg/kg okra fruit extract once a day). Extractions of the rats' mandibular left incisors were performed using a pair of modified forceps and an elevator. The tooth sockets were then irrigated using saline solution. Four rats in each group were sacrificed on day 3 (KO1, PO1), 5 (KO2, PO2), and 7 (KO3, PO3). The socket tissues from the rats were then immunohistochemically analyzed. [Data was analyzed at level significance of 0.05.](#)

Result: the average level of TGF- β 1 expression in the treatment groups was higher compared to the control group: PO1 (11.59 ± 0.58), PO2 (15.15 ± 1.07), and PO3 (18.75 ± 2.73) as compared to KO1 (5.32 ± 1.69), KO2 (8.47 ± 0.60), and KO3 (9.28 ± 1.16) with p value of 0.001.

Conclusion: The administration of okra fruit extract can increase the level of TGF- β 1 in wounds after tooth extraction of diabetic Wistar rats.

Keyword: Okra, diabetes mellitus, [Transforming Growth Factor beta](#), wound healing

INTRODUCTION

Wound healing is a complex biological process involving hemostasis, inflammation, proliferation, and remodeling.^[1] On the third day of wound healing process, there is a transition from inflammatory phase to proliferation phase, in which a transition from macrophage-1 (M1) to macrophage-2 (M2) occurs. The fifth day is the proliferation phase, in which fibroblasts are transferred to the injured area and M2 plays a dominant role as an anti-inflammatory agent. On the seventh day, the angiogenesis phase reaches its peak.^[2,3] It is also known that healing process is influenced by systemic factors, one of which is comorbidities, such as diabetes mellitus (DM). DM is known to cause macrophage dysfunction in the patients.^[4]

Wound healing process involves a series of activities of damage repair. Prolonged high-blood glucose level may causes a prolonged inflammatory process and high anti-inflammatory activity.^[5] Specifically, in gingival wound healing process in diabetic patients in which insulin-induced fibroblasts dysfunction occurs soon after tooth extraction, associated with a decrease in the level of TGF- β 1 gene expression.^[6] TGF- β 1 expression plays dominant role in wound recovery among other TGF- β isoforms because TGF- β 1 functions to increase proliferation, collagen formation, and differentiation of fibroblasts in the wound proliferation phase. Besides, TGF- β 1 also plays role in forming extracellular matrix (ECM) secretion and those related to morphological proliferation, mononuclear cell differentiation, and osteocytes. TGF- β 1 is involved in angiogenesis by increasing the regulation of vascular endothelial growth factor (VEGF). During wound closure process, TGF- β 1 increases keratinocyte transfer.^[7]

Along with the advancement of science, various treatments have been developed to overcome this problem, one of which uses herbal ingredients. Herbs are in great demand and are used by around 80% of the world's population because of the benefits in terms of safety,

effectiveness, cultural acceptance, and less substantial side effects as compared to synthetic chemicals.^[8] One herb that can accelerate wound healing process is the fruit of okra plant (*Abelmoschus esculentus*).

Okra fruit has antioxidant, anti-inflammatory,^[9] and anti-diabetic^[10] qualities in the process of wound healing. The antioxidant quality of okra is needed in the process of wound healing to eliminate the effects of reactive oxygen species (ROS). Okra fruit's anti-inflammatory feature decreases the production of pro-inflammatory mediators, such as nitric oxide and ROS, and the production of Tumor Necrosis Factor α (TNF- α) and Interleukin-1 β (IL-1 β) stimulated by liposaccharide (LPS).^[9] Flavonoids found in okra fruit also play a role in lowering blood glucose level due to its isoquercetin content which regulates the level of blood glucose and increases immunoreactivity of pancreatic β -cells. In addition, it also has a role in wound healing process.^[9,10] The objective of this study is to calculate the level of expression of TGF- β 1 in post tooth extraction wound healing process in Wistar rats with diabetes mellitus. In addition, this study also aims to verify that administration of okra fruit extract can increase TGF- β 1 expression in post tooth extraction wound healing process in Wistar rats with DM.

MATERIAL AND METHODS

Research Design and Animal Model

This is a laboratory-based of analytic experimental study, with post-test only control group design. Wistar rats used as samples in this study were obtained from the Experimental Animal Unit of the Biochemical Laboratory of the Faculty of Medicine, Universitas Airlangga. Ethical clearance of the research was issued by the Health Research Ethical Clearance Commission with a clearance certificate numbered 231/HRECC.FODM/V/2019.

Collection, adjustment, maintenance, and treatment were carried out in the Experimental Animal Unit of the Biochemical Laboratory of the Faculty of Medicine, Universitas Airlangga. Okra fruit was extracted in Materia Medika Batu. Histological preparations were carried out at the Anatomy Pathology Laboratory of the Faculty of Medicine, Universitas Airlangga. Immunohistochemistry dyeing and TGF- β 1 expression calculation were carried out at Brawijaya University, Malang.

Okra fruit extract preparation

Fresh okra fruit collected for the study was dried in a drying oven until a constant weight was reached. The dried fruit was then ground into powder. A total of 2 grams of powder was extracted with 20 ml of 70% ethanol in a ratio of 1:10 (w/v) during the maceration period (24 hours) at room temperature. The mixture of solvent and soaked powder was filtered through filter paper and then concentrated to 1 ml with a rotary evaporator and diluted with 5% dimethyl sulfoxide (DMSO) at a ratio of 1:1 (v/v). The results were then stored at a temperature of -20 °C until further use.^[11]

Research Procedure

In this study, 24 male Wistar rats aged 2-3 months with a weight of 150-200 grams were adapted in the same cage at 25 ± 2 °C. The 24 Wistar rats were divided into 2 groups (control group and treatment group). The rats were supplied with standard pellet food and

distilled water *ad libitum* for 7 days and for 4 hours before being induced with streptozotocin (STZ) (Nacalai Tesque Inc., Japan). The 2% STZ solution was dissolved with 0.1 mol/L citrate buffer solution pH 4.4 at a dose of 45 mg/kg and converted to a dose of 6.75 mg/150gr. The solution was then administered to the Wistar rats through intraperitoneal induction.^[12] Blood glucose levels were measured on day 3 after STZ induction by taking blood sample from the lateral veins in the rats' tails. Measurement were performed using a glucometer (Accu Chek® Instant). The Wistar rats were diagnosed with DM if the blood glucose levels ≥ 200 mg/dl after the STZ induction.^[13] The rats' weight during experiment were not measured.

Wistar rats with DM were then anesthetized through peritoneal injection using 0.1 ml of ketamine per rat. A resting period of 1-1.5 hours were given after the injection, after which extractions of the rats' mandibular left incisors were performed using a pair of modified forceps and an elevator. The tooth sockets were then irrigated with saline solution.^[14]

In the control group, the animals did not receive administration of okra fruit extract. Instead, they were only supplied with distilled water prior to the observation. K_{O1} was observed on the 3rd day, K_{O2} was observed on the 5th day, and K_{O3} was observed on the 7th day. In the treatment group, the rats were given oral administration of okra fruit extract after the tooth extraction with a dose of 250 mg/kg which was converted to a dose of 37.5 mg/150 gr once a day during the treatment. P_{O1} was observed on the 3rd day, P_{O2} was observed on 5th day, and P_{O3} was observed on 7th day.

Wistar rats were sacrificed on the 3rd, 5th and 7th day using lethal injection of intraperitoneal ketamine (no less than 4 times the anesthetic dose or about 0.4 ml/kg). The mandibular of each rat was taken from the temporomandibular joint. After which, the Wistar rats were buried according to the ethical treatments of experimental animals. The mandibles in the incisor area were cut vertically and treated with paraffin method.

Histopathological Specimen Preparation

The histological examination procedure was started by putting the tissues into formalin buffer (10% formalin solution in Phosphate-Buffered Saline pH-7) to be fixed and then put in to paraffin wax. The tissues were cut into slides with a length of 4-6 mm on the glass slide. After being deparaffinized with xylene, the slides were submerged in graded alcohol for dehydration and incubation with EDTA (pH = 8.0) in a microwave oven (750 W) to take TGF- β 1 antigens. Slides were incubated for 20 minutes in 3% H₂O₂ to inhibit endogenous peroxidase activity, and then rinsed three times with phosphate saline buffer (PBS) for 5 minutes each. The slides were then incubated with blocking solutions using a superbloc (Scy Tek Laboratories Inc., US) and peroxide block (Scy Tek Laboratories Inc., US). Slides were incubated overnight with TGF- β 1 antibodies (ab 27969: abcam, Burlingame, US). After being washed in PBS, the slides were treated with UltraTek anti-polyvalent biotinylated antibodies (Scy Tech Laboratories Inc., US) and UltraTek HRP (Scy Tek Laboratories Inc., US). This reaction was visualized by incubating the slides for 7 minutes in 0.1% 3,3-diaminobenzidine and 0.02% hydrogen peroxide solution. Slides were then counterstained with Mayer's hematoxylin (Scy Tech Laboratories Inc., US) and covered. Immunohistochemical positive staining was defined as the detection of brown chromogen from DAB Chromogen staining (Scy Tech Laboratories Inc., US) at the edge of the hematoxylin-stained nucleus distributed in the cytoplasm or plasma cell membrane and analyzed under a light microscope with 1000x magnification at 20 visual fields. TGF- β 1 expression would be seen as positive, immune-reactive cells with a yellowish to brown color, while negative cells would correspond to the counterstain coloring agent used.^[15]

Statistical Analysis

Statistical analysis was performed using SPSS (IBM SPSS Statistics for Windows, Version 24.0: IBM Corp., USA). Shapiro-Wilk test was used to find out normally distributed data. After the distribution test, Levene's homogeneity test was then performed. Once the distribution was found normal and the data was homogeneous, the analysis was continued with One Way ANOVA test and with multiple comparison test using Tukey HSD test.

RESULTS

Based on the laboratory experiment using 24 Wistar rats which were divided into control (K_0) and treatment (P_0) groups, the researchers have observed the wounds from the extraction of the left maxillary incisors on day 3, 5, and 7 to measure the number of TGF- β 1 expression in the wound healing process after tooth extraction of Wistar rats with DM. The blood glucose level of all rats was above 200mg/dl after the induction. TGF- β 1 examination was carried out under a light microscope with 1000x magnification at 20 visual fields (Figure 1).

We observed the expression of TGF- β 1 both with and without okra fruit extract administration. The ANOVA test showed a significant difference among the groups (Table 1). Meanwhile, the multiple comparison test result using Tukey HSD showed a significant increase of TGF- β 1 expression observed on day 3, 5, and 7 in the control group. Likewise, the treatment group also exhibited the same results for day 3, 5, and 7 (Table 2).

TGF- β 1 expressions on days 3, 5, and 7 on the prepared Wistar rats' socket tissues with DM were calculated using a light microscope with 400x magnification at 4 visual fields (Figure 1). TGF- β 1 expression appears as gradients of yellow to brown stains pointed with arrows. Based on Figure 2, it can be seen that on the 3rd day, P_{O1} group showed increasing number of TGF- β 1 expression as compared to K_{O1} group. On the 5th day, P_{O2} showed increasing number of TGF- β 1 expression as compared to K_{O2} group. On the 7th day, P_{O3} showed increasing number of TGF- β 1 expression as compared to K_{O3} group.

DISCUSSION

This research aims to prove that okra fruit extract can increase the expression of TGF- β 1 in wound healing process after tooth extraction in Wistar rats with DM. The observations of TGF- β 1 expression were carried out on day 3, 5, and 7. Since the 3rd day of the wound healing process, a transition from inflammatory phase to proliferation phase has taken place. During the same phase, macrophage-1 (M1) goes under transition to become macrophage-2 (M2). However, the number of M1 is still above M2. Whereas on the 5th day, M2 plays a more dominant role than M1 on the wounds. Proliferation phase also takes place during this time in which fibroblasts migrate to the wound area.^[3] Then, the peak of the angiogenesis phase starts on the 7th day.^[6] M2 acts as an anti-inflammatory in which macrophages release IL-10 and TGF- β , a very strong anti-inflammatory agent that immediately stops the inflammatory process and starts the proliferation phase.^[4] This is the reason why we as researchers observed TGF- β 1 expression as one of the important growth factors in wound healing process.

The results of our research confirm the hypothesis that the administration of okra fruit extract can increase TGF- β 1 expression in the wound healing process after tooth extraction of Wistar rats with DM. Observation were done by calculating the amount of TGF- β 1 expression in both groups, namely the control group (K) and the treatment group (P). In group K, the TGF- β 1 expression from Wistar tooth socket is less than in group P. However, in both K and P groups, we found that the highest number of TGF- β 1 expression on the 7th day, as compared to on the 3rd and 5th day. This is due to the fact that the healing process that involves fibroblasts cell infiltration to the wound occurs the most on the 7th day, thus the number of TGF- β 1 expression is higher than the 3rd and 5th day.^[3,4]

The mean number of TGF- β 1 expression in the K group shows lower results than the P group due to the STZ induction. A few days after the STZ induction, a damage occurs in

pancreatic beta cells which results in insulin resistance and high blood glucose level. In addition, the increased oxidative stress due to the formation of AGEs causes disruption of the fibroblast's proliferation, migration, and dysfunction.^[6]

Yamano et al., state that at the beginning of tooth extraction, the lowest amount of TGF- β 1 expression is obtained compared to the following day.^[16] In addition, a study by Hozzein et al., also infers that the administration of intraperitoneal STZ can cause a significant decrease in regulation of TGF- β 1 in wound tissue.^[17]

In DM patients, an uncontrolled glycemic control causes a disruption in wound healing process, which is a disturbance in the angiogenesis activity that causes pathogenesis mechanism.^[18] In group K, TGF- β 1 expression increased significantly on day 3 to 5, while on days 5 to 7, the expression of TGF- β 1 also increased, though not as significant. This is due to the fact that DM condition disrupts the innate role and function of immunity cells. High glucose level increases the cellular nuclear factor- κ B (NF- κ B) activation. If an injury occurs, the prolonged inflammatory phase results in a pro-inflammatory response that increases the occurrence of chronic inflammation and tissue damage.^[6]

High blood glucose level induces ROS which can be produced both enzymatically and non-enzymatically. Enzymatic production includes nicotinamide adenine dinucleotide phosphate oxidase (NADPH oxidase), nitric oxide synthase (NOS), cytochrome P-450, cyclooxygenase (COX), lipoxygenase (LOX), xanthine oxidase, and myeloperoxidase (MPO),^[19] and results in high pro-inflammatory cytokines which are released by neutrophils and macrophages as well as an increase in abnormal protease activity resulting in disruption of growth factor signaling in the wound healing process. This signaling disruption causes a decrease in growth factor and disrupts in the angiogenesis phase.^[13]

On the other hand, the P group had higher average TGF- β 1 as compared to K group due to the difference in okra fruit extract administration.^[20] Thus, it confirms the hypothesis

that okra fruit extract can increase TGF- β 1 expression. Okra extract has antioxidant, anti-inflammatory, and anti-diabetic qualities in wound healing process.^[8,10] Okra extract contains polyphenols, flavonoids, isoquercetin, and quercetin-3-O-gentiobiose. Flavonoid is useful to repair damaged cells and forms a normal wound healing process by inducing fibroplasia by TGF- β 1.^[21] Quercetin plays a role in regulating TGF- β 1 expression and decreasing the number of inflammatory cells. Quercetin also decreases the number of TNF- α , while increasing fibroblasts proliferation and micro blood vessel density, leading to better re-epithelialization and regular collagen deposition.^[22] Pang et al. state that low-dose flavonoid alone is able to stimulate TGF- β 1 expression which in turn increases TGF- β expression by macrophage stimulation induced by total flavonoids in wounds.^[23] TGF- β 1, secreted by M2 phenotype macrophages, plays a role in inhibiting the recruitment of inflammatory cells.^[24] TGF- β induces the keratinocyte and fibroblasts proliferation, causing the new capillaries formation in granulation tissue and modulation of extracellular matrix deposition resulting in wound healing. TGF- β 1 also plays a role in angiogenesis by increasing the regulation of VEGF. During wound closure, TGF- β 1 increases keratinocyte migration.^[17]

In addition to reducing pro-inflammatory mediator production, okra fruit plays a role in reducing nitric oxide amount and ROS, as well as in reducing the production of TNF- α .^[20] Excessive production of ROS causes activation of the NF- κ B signaling pathway. NF- κ B is a protein that stimulates cytokines and free radicals. It is also a transcription factor that regulates large numbers of genes involved in various immune and inflammatory response processes and causes vascular complications in DM patients and in inflammatory pathogenic processes that can be inhibited by flavonoids.^[21]

Flavonoid contained in okra fruit can reduce blood glucose level,^[10] resulting in a decrease in pro-inflammatory cytokines.^[20] High concentration of fiber and polysaccharides in the okra fruit can stabilize blood glucose by limiting the rate of absorption of sugar in the

intestine.^[25] This complements the flavonoid content of the okra fruit which functions as an inhibitor of α -amylase and α -glucosidase, the enzymes found in the small intestine^[21] which act as carbohydrate catalyst by catalyzing oligosaccharides so that glucose absorption may take place. Inhibition of α -glucosidase can cause catalysis of complex carbohydrate diets such as oligosaccharides and polysaccharides to be inhibited by monosaccharides resulting in decreased blood glucose level.^[10,12]

Glycoprotein-A repetitions predominant protein (GARP) is an important regulator in activating latent TGF- β (LTGF- β) and then binding it to LTGF- β . GARP acts as a docking receptor that functions as a carrier of LTGF- β on the cell surface, activating its role.^[7] GARP also plays role in the regulation of T lymphocytes (Tregs) that form complexes with the α V β 8 integrin to release active TGF- β from the cell surface.^[17] TGF- β 1 stimulates fibroblasts to differentiate into myofibroblasts and then collaborates with these myofibroblasts to produce extracellular matrix (ECM), as well as collagen and matrix proteins, namely fibronectin.^[5] TGF- β 1 together with VEGF and fibroblasts stimulate the angiogenesis process.^[17] This explains the higher expression of TGF- β 1 in P group as compared to K group. Therefore, it can accelerate wound healing process in P group.

CONCLUSION

The administration of okra fruit extract can increase the number of TGF- β 1 in tooth extraction wounds on Wistar rats with DM.

REFERENCES

1. Reinke JM, Sorg H. Wound Repair and Regeneration. *Eur Surg Res* 2012;49:35–43.
2. Benadiba M, Serruya R, Maor Y. Bioaccessibility of Shore Magic® collagen, a low-molecular-weight collagen supplement, in different in vitro barrier models. *Heliyon* 2018;4.
3. Du Y, Ren P, Wang Q, Jiang SK, Zhang M, Li JY, *et al.* Cannabinoid 2 receptor attenuates inflammation during skin wound healing by inhibiting M1 macrophages rather than activating M2 macrophages. *J Inflamm (United Kingdom)* 2018;15:25.
4. Anderson K, Hamm RL. Factors that impair wound healing. *J Am Coll Clin Wound Spec* 2012;4:84–91.
5. Zhao R, Liang H, Clarke E, Jackson C, Xue M. Inflammation in chronic wounds. *Int J Mol Sci* 2016;17.
6. Kido D, Mizutani K, Takeda K, Mikami R, Matsuura T, Iwasaki K, *et al.* Impact of diabetes on gingival wound healing via oxidative stress. Jandeleit-Dahm K, editor. *PLoS One* 2017;12:e0189601.
7. Liu Y, Li Y, Li N, Teng W, Wang M, Zhang Y, *et al.* TGF- β 1 promotes scar fibroblasts proliferation and transdifferentiation via up-regulating MicroRNA-21. *Sci Rep* 2016;6:1–9.
8. Bhowmik D, Sampath Kumar KP, Tripathi P. Traditional Herbal Medicines: An Overview. *Arch Appl Sci Res* 2009;1:165–77.
9. Solomon S. Anti-Oxidant and Anti-Inflammatory Activity of *Abelmoschus esculentus* (Flowers). *Indo Am J Pharm Sci* 2016:600–5.
10. Abbas AY, Muhammad I, AbdulRahman MB, Bilbis LS, Saidu Y, Onu A. Possible Antidiabetic Mechanism of Action of Ex-maradi Okra Fruit Variety

- (*Abelmoschus esculentus*) on Alloxan Induced Diabetic Rats. Niger J Basic Appl Sci 2018;25:101.
11. Yeo YL, Chia YY, Lee CH, Sow HS, Yap WS. Effectiveness of maceration periods with different extraction solvents on in-vitro antimicrobial activity from fruit of *Momordica charantia* L. J Appl Pharm Sci 2014;4:16–23.
 12. Tian Z-H, Miao F-T, Zhang X, Wang Q-H, Lei N, Guo L-C. Therapeutic effect of okra extract on gestational diabetes mellitus rats induced by streptozotocin. Asian Pac J Trop Med 2015;8:1038–42.
 13. Qinna NA, Badwan AA. Impact of streptozotocin on altering normal glucose homeostasis during insulin testing in diabetic rats compared to normoglycemic rats. Drug Des Devel Ther 2015;9:2515–25.
 14. Gunawan F, Sularsih S, Soemartono S. The Differences Effect Between Low and High MolecularWeight Chitosan on Number of Lymphocyte Cells in the Wound Healing Process of Dental Extraction. Dent J Kedokt Gigi 2015;9:113–22.
 15. Sula B, Deveci E, Özevren H, Ekinici C, Elbey B. Immunohistochemical and histopathological changes in the skin of rats after administration of lead acetate. Int J Morphol 2016;34:918–22.
 16. Yamano S, Kuo WP, Sukotjo C. Downregulated gene expression of TGF- β s in diabetic oral wound healing. J Cranio-Maxillofacial Surg 2013;41.
 17. Hozzein WN, Badr G, Al Ghamdi AA, Sayed A, Al-Waili NS, Garraud O. Topical Application of Propolis Enhances Cutaneous Wound Healing by Promoting TGF-Beta/Smad-Mediated Collagen Production in a Streptozotocin-Induced Type I Diabetic Mouse Model. Cell Physiol Biochem 2015;37:940–54.
 18. Raghav A. Crucial Role of Diabetes Mellitus in Delayed Angiogenesis of Wound. J Pharmacol Clin Res 2018;5:4.

19. Fakhruddin S, Alanazi W, Jackson KE. Diabetes-Induced Reactive Oxygen Species: Mechanism of Their Generation and Role in Renal Injury. *J Diabetes Res* 2017;2017.
20. Shah BN, Seth AK. ANTI-INFLAMMATORY ACTIVITY OF FRUITS OF ABELMOSCHUS ESCULANTUS LINN. *Pharmacol online* 2010;1:208–12.
21. Roy A, Shrivastava SL, Mandal SM. Functional properties of Okra *Abelmoschus esculentus* L. (Moench): traditional claims and scientific evidences. *Plant Sci Today* 2014;1:121–30.
22. Gopalakrishnan A, Ram M, Kumawat S, Tandan S, Kumar D. Quercetin accelerated cutaneous wound healing in rats by increasing levels of VEGF and TGF- β 1 - PubMed. *Indian J Exp Biol* 2016;54:187–95.
23. Pang Y, Zhang Y, Huang L, Xu L, Wang K, Wang D, *et al.* Effects and mechanisms of total flavonoids from *Blumea balsamifera* (L.) DC. on skin wound in rats. *Int J Mol Sci* 2017;18.
24. Liu YC, Zou XB, Chai YF, Yao YM. Macrophage polarization in inflammatory diseases. *Int J Biol Sci* 2014;10:520–9.
25. Durazzo A, Lucarini M, Novellino E, Souto EB, Daliu P, Santini A. *Abelmoschus esculentus* (L.): Bioactive components' beneficial properties-focused on antidiabetic role-for sustainable health applications. *Molecules* 2019;24.

Table list

Table 1. Mean, standard deviation, and normality test of TGF-β1 expression (macrophage cells count) in the control and treatment group.

Group	Mean ± SD	P value
KO1	5.32 ± 1.69	0.001
KO2	8.47 ± 0.60	
KO3	9.28 ± 1.16	
PO1	11.59 ± 0.58	
PO2	15.15 ± 1.07	
PO3	18.75 ± 2.73	

Table 2. Tukey HSD post-hoc multiple comparisons test results in the control and treatment group

Group	KO1	KO2	KO3
KO1		0.030*	0.009*
KO2	0.030*		0.710
Group	PO1	PO2	PO3
PO1		0.041*	0.001*
PO2	0.041*		0.039*

Remarks = * there is a significant difference

Figure list

Figure 1. Expression of TGF- β 1 in day 3, 5, and 7 in socket tissues of Wistar rats with diabetes mellitus in immunohistochemistry examination in microscope with 400x magnification in control group (K_O) and treatment group (P_O)

Figure 2. Mean value graph of TGF- β 1 expression on day 3, 5, and 7

Technical/Copyediting by Sinjore Technologies: 14-04-2021

Please upload updated copyright form signed by all authors

<RH>Luthfi, *et al.*: Okra fruit extract on wound healing

Original Article

The efficacy of okra fruit extract on the expression of transforming growth factor beta 1TGF-β1 in the tooth socket of diabetic Wistar rats

Muhammad Luthfi¹, Yuliati¹, Elvina Hasna Wijayanti², Fathilah Binti Abdul Razak³, Wahyuning Ratih Irmalia⁴

Departments of ¹Oral Biology and ²Undergraduate Program, Faculty of Dental Medicine, Universitas Airlangga University, ³Indonesian Health Collaboration and Innovation Institute, Surabaya, Indonesia, ⁴Department of Oral and Craniofacial Sciences, Faculty of Dentistry, University of Malaya, Kuala Lumpur, Malaysia

Address for correspondence:

Dr. Muhammad Luthfi,

Department of Oral Biology, Faculty of Dental Medicine, University of Airlangga, Jl. Mayjend. Prof.Dr. Moestopo 47 60 132 Surabaya, Indonesia.

E-mail: m.luthfi@fkg.unair.ac.id

Received: September 2020

Accepted: April 2021

How to cite this article: Luthfi M, Yuliati, Wijayanti EH, Razak FB, Irmalia WR. The efficacy of okra fruit extract on the expression of transforming growth factor beta 1TGF-β1 in the tooth socket of diabetic Wistar rats. Dent Res J XX:XX:XX.

Full title : The Efficacy of Okra Fruit Extract on the Expression of TGF-β1 in the Tooth Socket of Diabetic Wistar Rats

Formatted: English (United States)

Formatted: Space Before: 0 pt, After: 0 pt

Formatted: Highlight

Commented [content1]: Kindly provide author full name.

Commented [7-2R1]: The author's full name is just 1 word

Formatted: Not Superscript/ Subscript

Commented [content3]: Kindly provide department.

Commented [TE4]: Kindly provide English language.

Commented [content5]: Kindly provide department.

Commented [7-6R5]: There is no department

Formatted: Not Highlight

Formatted: English (United States)

Formatted: Space Before: 0 pt, After: 0 pt

Commented [s7]: Please provide accepted date

Commented [content8]: Kindly provide author initial.

Formatted: English (United States)

Formatted: Space Before: 0 pt, After: 0 pt

Formatted: Font: 12 pt

Formatted: English (United States)

Formatted: Line spacing: Double

Formatted: Font: Bold

Short title : Okra fruit extract on wound healing

ABSTRACT

Background: Patients with diabetes mellitus suffer from an additional macrophage dysfunction in the secretion of growth factor, which later decreases transforming growth factor beta 1 (TGF-β1). This condition disrupts proliferation and angiogenesis. Extract of okra fruit (*Abelmoschus esculentus*) contains flavonoid, an active substance which acts as antioxidant, anti-inflammation, and anti-diabetes. The purpose of this study is to analyze the difference in TGF-β1 expression in wound-wound-healing process after tooth extraction of diabetic Wistar rats.

Materials and Methods: This is a laboratory experimental study using pre-test and post-test on 24 Wistar rats which are divided into 2-two groups: control group (treated with streptozotocin streptozocin-induction but without administration of okra fruit extract) and treatment group (treated with streptozotocin streptozocin-induction and oral administration of 250 mg/kg okra fruit extract once a day). Extractions of the rats' mandibular left incisors were performed using a pair of modified forceps and an elevator. The tooth sockets were then irrigated using saline solution. Four rats in each group were sacrificed on day 3 (KO1, PO1), 5 (KO2, PO2), and 7 (KO3, PO3). The socket tissues from the rats were then immunohistochemically analyzed. Data was-were analyzed at level significance of 0.05.

Results: The average level of TGF-β1 expression in the treatment groups was higher compared to the control group: PO1 (11.59 ± 0.58), PO2 (15.15 ± 1.07), and PO3 (18.75 ± 2.73) as compared to KO1 (5.32 ± 1.69), KO2 (8.47 ± 0.60), and KO3 (9.28 ± 1.16) with P value of= 0.001.

Conclusion: The administration of okra fruit extract can increase the level of TGF-β1 in wounds after tooth extraction of diabetic Wistar rats.

Formatted: Not Highlight

Formatted: Not Highlight

Formatted: Not Highlight

Formatted: Not Highlight

Formatted: Not Highlight

Formatted: Not Highlight

Formatted: Not Highlight

Commented [CE9]: Please note these terms are followed inconsistent in the article. Kindly check and confirm.

Formatted: Not Highlight

Formatted: Font color: Auto

Formatted: Font color: Auto

Formatted: Not Highlight

Formatted: Not Highlight

Formatted: Not Highlight

Formatted: Not Highlight

Formatted: Not Highlight

Formatted: Not Highlight

Formatted: Not Highlight

Formatted: Not Highlight

Keywords: ~~Okra~~, Diabetes mellitus, okra fruit, transforming growth factor beta 1, wound healing, Good health and well-being

Formatted: Indent: Left: 0 cm, Hanging: 2 cm, Line spacing: Double

<H1>INTRODUCTION

Formatted: Font: Bold

Formatted: Line spacing: Double

Wound healing is a complex biological process involving hemostasis, inflammation, proliferation, and remodeling.^[1] On the ~~thir~~^{id}-~~3~~rd day of ~~wound~~-healing process, there is a transition from inflammatory phase to proliferation phase, in which a transition from macrophage-1 (M1) to macrophage-2 (M2) occurs. The ~~fir~~th-~~5~~th day is the proliferation phase, in which fibroblasts are transferred to the injured area and M2 plays a dominant role as an ~~anti-inflammatory~~ agent. On the ~~seventh~~th day, the angiogenesis phase reaches its peak.^[2,3] It is also known that healing process is influenced by systemic factors, one of which is comorbidities, such as diabetes mellitus (DM). DM is known to cause macrophage dysfunction in the patients.^[4]

Formatted: Check spelling and grammar

Formatted: Superscript

Formatted: Not Highlight

Formatted: Superscript

Formatted: Not Highlight

Formatted: Not Highlight

Formatted: Superscript

Formatted: Not Highlight

Formatted: Check spelling and grammar

Formatted: Not Highlight

Formatted: Check spelling and grammar

~~Wound~~-healing process involves a series of activities of damage repair. Prolonged ~~high-blood~~ glucose level may cause a prolonged inflammatory process and high ~~anti-inflammatory~~ activity.^[5] Specifically, in gingival ~~wound~~-healing process ~~in of~~ diabetic patients ~~in which~~ insulin-induced fibroblasts dysfunction occurs soon after tooth extraction.

Formatted: Not Highlight

Formatted: Indent: First line: 0 cm, Line spacing: Double

Formatted: Not Highlight

Formatted: Check spelling and grammar

~~This is~~ associated with a decrease in the level of transforming growth factor beta 1 (TGF-β1) gene expression.^[6] TGF-β1 expression plays a dominant role in wound recovery among other TGF-β isoforms because TGF-β1 functions to increase proliferation, collagen formation, and differentiation of fibroblasts in the wound proliferation phase. Besides, TGF-β1 also plays a role in forming extracellular matrix (ECM) secretion and those related to morphological proliferation, mononuclear cell differentiation, and osteocytes. TGF-β1 is involved in angiogenesis by increasing the regulation of vascular endothelial growth factor (VEGF).

Formatted: Not Highlight

Commented [CE10]: The intended sense of the text is not clear. Kindly review the sentence

Formatted: Check spelling and grammar

Formatted: Not Highlight

Formatted: Not Highlight

Formatted: Not Highlight

Formatted: Not Highlight

Formatted: Not Highlight

Formatted: Not Highlight

Formatted: Not Highlight

During wound closure process, TGF-β1 increases keratinocyte transfer.^[7]

Formatted: Not Highlight

Formatted: Check spelling and grammar

Along with the advancement of science, various treatments have been developed to overcome this problem, one of which uses herbal ingredients. Herbs are in great demand and are used by around 80% of the world's population because of the benefits in terms of safety, effectiveness, cultural acceptance, and less substantial side effects as compared to synthetic chemicals.^[8] One herb that can accelerate wound-healing process is the fruit of okra plant (*Abelmoschus esculentus*).

Formatted: Line spacing: Double

Formatted: Not Highlight

Formatted: Check spelling and grammar

Formatted: Not Superscript/ Subscript

Okra fruit has antioxidant, anti-inflammatory,^[9] and anti-diabetic^[10] qualities in the process of wound healing. The antioxidant quality of okra is needed in the process of wound healing to eliminate the effects of reactive oxygen species (ROS). Okra fruit's anti-inflammatory feature decreases the production of pro-inflammatory mediators, such as nitric oxide and ROS, and the production of tumor necrosis factor α (TNF- α) and interleukin-1 β (IL-1- β) stimulated by lipopolysaccharide (LPS).^[9] Flavonoids found in okra fruit also play a role in lowering blood glucose level due to its isoquercetin content, which regulates the level of blood glucose and increases immunoreactivity of pancreatic β -cells. In addition, it also has a role in wound-healing process.^[9,10] The objective of this study is to calculate the level of expression of TGF- β 1 in post-tooth extraction wound-healing process in Wistar rats with DM diabetes mellitus. In addition, this study also aims to verify that administration of okra fruit extract can increase TGF- β 1 expression in post-tooth extraction wound-healing process in Wistar rats with DM.

Formatted: Not Highlight

Formatted: Check spelling and grammar

Formatted: Not Highlight

Formatted: Check spelling and grammar

Formatted: Not Highlight

Formatted: Not Highlight

Formatted: Not Highlight

Formatted: Not Highlight

Formatted: Not Highlight

Formatted: Check spelling and grammar

Formatted: Not Highlight

Formatted: Check spelling and grammar

Formatted: Not Highlight

Formatted: Not Highlight

Formatted: Not Highlight

MATERIALS AND METHODS

Formatted: Font: Bold

Research design and animal model

Formatted: Font: Bold

Formatted: Font: Bold

This is a laboratory-based analytic experimental study, with post-test-only control group design. Wistar rats used as samples in this study were obtained from the Experimental Animal Unit of the Biochemical Laboratory of the Faculty of Medicine, Universitas

Formatted: Font color: Auto

Formatted: Font color: Auto, Not Highlight

Formatted: Font color: Auto

Formatted: Font color: Auto, Not Highlight

Airlangga. Ethical clearance of the research was issued by the Health Research Ethical Clearance Commission with a clearance certificate numbered 231/HRECC-FODM/V/2019.

Formatted: Not Highlight

Collection, adjustment, maintenance, and treatment were carried out in the Experimental Animal Unit of the Biochemical Laboratory of the Faculty of Medicine, Universitas Airlangga. Okra fruit was extracted in Materia Medika Medica Batu. Histological preparations were carried out at the Anatomy Pathology Laboratory of the Faculty of Medicine, Universitas Airlangga. Immunohistochemistry dyeing and TGF- β 1 expression calculation were carried out at Brawijaya University, Malang.

Formatted: Not Highlight

<H2>Okra fruit extract preparation

Formatted: Font: Bold

Fresh okra fruit collected for the study was dried in a drying oven until a constant weight was reached. The dried fruit was then ground into powder. A total of 2 g of powder was extracted with 20 ml of 70% ethanol in a ratio of 1:10 (w/v) during the maceration period (24 h) at room temperature. The mixture of solvent and soaked powder was filtered through filter paper and then concentrated to 1 ml with a rotary evaporator and diluted with 5% dimethyl sulfoxide (DMSO) at a ratio of 1:1 (v/v). The results were then stored at a temperature of -20°C until further use.^[11]

Formatted: Indent: First line: 0 cm, Line spacing: Double

Formatted: Not Highlight

Formatted: Not Highlight

Formatted: Not Highlight

Formatted: Not Highlight

Formatted: Check spelling and grammar

<H2>Research procedure

Formatted: Line spacing: Double

In this study, 24 male Wistar rats aged 2-3 months with a weight of 150-200 g were adapted in the same cage at 25°C ± 2°C. The 24 Wistar rats were divided into 2-two groups (control group and treatment group). The rats were supplied with standard pellet food and distilled water *ad libitum* for 7 days and for 4 h before being induced with streptozotocin (STZ) (Nacalai Tesque Inc., Japan). The 2% STZ solution was dissolved with 0.1 mol/L citrate buffer solution with pH of 4.4 at a dose of 45 mg/kg and converted to a dose of 6.75 mg/150 g. The solution was then administered to the Wistar rats through intraperitoneal induction.^[12] Blood glucose levels were measured on day 3 after STZ

Formatted: Font: Bold

Formatted: Not Highlight

Formatted: Not Highlight

Formatted: Not Highlight

Formatted: Not Highlight

Formatted: Not Highlight

Formatted: Not Highlight

Formatted: Not Highlight

Formatted: Not Highlight

Formatted: Not Highlight

Formatted: Check spelling and grammar

Formatted: Not Highlight

induction by taking blood sample from the lateral veins in the rats' tails. Measurements were performed using a glucometer (Accu Chek® Instant). The Wistar rats were diagnosed with DM if the blood glucose levels ≥ 200 mg/dl after the STZ induction.^[13] The rats' weight during experiment were was not measured.

Formatted: Superscript

Formatted: Not Highlight

Formatted: Check spelling and grammar

Wistar rats with DM were then anesthetized through peritoneal injection using 0.1 ml of ketamine per rat. A resting period of 1–1.5 h were was given after the injection, after which extractions of the rats' mandibular left incisors were performed using a pair of modified forceps and an elevator. The tooth sockets were then irrigated with saline solution.^[14]

Formatted: Not Highlight

Formatted: Check spelling and grammar

In the control group, the animals did not receive administration of okra fruit extract. Instead, they were only supplied with distilled water prior to before the observation. K_{O1} was observed on the 3rd day, K_{O2} was observed on the 5th day, and K_{O3} was observed on the 7th day. In the treatment group, the rats were given oral administration of okra fruit extract after the tooth extraction with a dose of 250 mg/kg which was converted to a dose of 37.5 mg/150 g once a day during the treatment. P_{O1} was observed on the 3rd day, P_{O2} was observed on 5th day, and P_{O3} was observed on 7th day.

Formatted: Not Highlight

Formatted: Not Highlight

Formatted: Not Highlight

Formatted: Not Highlight

Formatted: Not Highlight

Formatted: Not Highlight

Formatted: Not Highlight

Formatted: Not Highlight

Wistar rats were sacrificed on the 3rd, 5th and 7th day using lethal injection of intraperitoneal ketamine (no ~~less than~~ 4 times the anesthetic dose or about 0.4 ml/kg). The mandibular of each rat was taken from the temporomandibular joint. After which, the Wistar rats were buried according to the ethical treatments of experimental animals. The mandibles in the incisor area were cut vertically and treated with paraffin method.

Formatted: Not Highlight

Formatted: Not Highlight

Formatted: Not Highlight

<H2>Histopathological specimen preparation

Formatted: Font: Bold

Formatted: Font: Bold

The histological examination procedure was started by putting the tissues into formalin buffer (10% formalin solution in phosphate-buffered saline [PBS] pH 7) to be fixed and then put in to paraffin wax. The tissues were cut into slides with a length of 4–6 mm on

Formatted: Not Highlight

Formatted: Not Highlight

the glass slide. After being deparaffinized with xylene, the slides were submerged in graded alcohol for dehydration and incubation with EDTA (pH = 8.0) in a microwave oven (750 W) to take TGF- β 1 antigens. Slides were incubated for 20 min in 3% H₂O₂ to inhibit endogenous peroxidase activity, and then rinsed three times with phosphate saline buffer (PBS) for 5 min each. The slides were then incubated with blocking solutions using a superblock (Scy Tek Laboratories Inc., US) and peroxide block (Scy Tek Laboratories Inc., US). Slides were incubated overnight with TGF- β 1 antibodies (ab 27969: Abcam, Burlingame, US). After being washed in PBS, the slides were treated with UltraTek anti-polyvalent biotinylated antibodies (Scy Tech Laboratories Inc., US) and UltraTek HRP (Scy Tek Laboratories Inc., US). This reaction was visualized by incubating the slides for 7 min in 0.1% 3,3-diaminobenzidine and 0.02% hydrogen peroxide solution. Slides were then counterstained with Mayer's hematoxylin (Scy Tech Laboratories Inc., US) and covered. Immunohistochemical positive staining was defined as the detection of brown chromogen from DAB Chromogen staining (Scy Tech Laboratories Inc., US) at the edge of the hematoxylin-stained nucleus distributed in the cytoplasm or plasma cell membrane and analyzed under a light microscope with \times 1000 magnification at 20 visual fields. TGF- β 1 expression would be seen as positive, immune-reactive cells with a yellowish to brown color, while negative cells would correspond to the counterstain coloring agent used.^[15]

<H2>Statistical analysis

Statistical analysis was performed using SPSS (IBM SPSS Statistics for Windows, Version 24.0: IBM Corp., USA). Shapiro-Wilk test was used to find out normally distributed data. After the distribution test, Levene's homogeneity test was then performed. Once the distribution was found normal and the data was/were homogeneous, the analysis was continued with one-way analysis of variance (ANOVA) test and with multiple comparison test using Tukey honestly significant difference (HSD) test.

Formatted: Not Highlight

Formatted: Not Highlight

Formatted: Not Highlight

Formatted: Not Highlight

Formatted: Not Highlight

Formatted: Not Highlight

Formatted: Not Highlight

Formatted: Not Highlight

Formatted: Not Highlight

Formatted: Not Highlight

Formatted: Not Highlight

Formatted: Check spelling and grammar

Formatted: Font: Bold

<H1>RESULTS

Based on the laboratory experiment using 24 Wistar rats which were divided into control (K₀) and treatment (P₀) groups, the researchers have observed the wounds from the extraction of the left maxillary incisors on day 3, 5, and 7 to measure the number of TGF-β1 expression in the wound-wound-healing process after tooth extraction of Wistar rats with DM. The blood glucose level of all rats was above 200 mg/dl after the induction. TGF-β1 examination was carried out under a light microscope with ×1000 magnification at 20 visual fields [Figure 1].

We observed the expression of TGF-β1 both with and without okra fruit extract administration. The ANOVA test showed a significant difference among the groups [Table 1]. Meanwhile, the multiple comparison test result using Tukey HSD showed a significant increase of TGF-β1 expression observed on day 3, 5, and 7 in the control group. Likewise, the treatment group also exhibited the same results for day 3, 5, and 7 [Table 2].

TGF-β1 expressions on days 3, 5, and 7 on the prepared Wistar rats' socket tissues with DM were calculated using a light microscope with ×400 magnification at 4-four visual fields [Figure 1]. TGF-β1 expression appears as gradients of yellow to brown stains pointed with arrows. Based on Figure 2, it can be seen that on the 3rd day, P₀₁ group showed increasing number of TGF-β1 expression as compared to K₀₁ group. On the 5th day, P₀₂ showed increasing number of TGF-β1 expression as compared to K₀₂ group. On the 7th day, P₀₃ showed increasing number of TGF-β1 expression as compared to K₀₃ group.

<H1>DISCUSSION

This research aims to prove that okra fruit extract can increase the expression of TGF-β1 in wound-wound-healing process after tooth extraction in Wistar rats with DM. The observations of TGF-β1 expression were carried out on day 3, 5, and 7. Since the 3rd day of the wound-wound-healing process, a transition from inflammatory phase to proliferation

Formatted: Font: Bold

Formatted: Not Highlight

Formatted: Not Highlight

Formatted: Not Highlight

Formatted: Not Highlight

Formatted: Not Highlight

Formatted: Not Highlight

Formatted: Not Highlight

Formatted: Not Highlight

Formatted: Not Highlight

Formatted: Not Highlight

Formatted: Indent: First line: 0 cm, Line spacing: Double

Formatted: Not Highlight

Formatted: Not Highlight

Formatted: Not Highlight

Formatted: Not Highlight

Formatted: Not Highlight

Formatted: Not Highlight

Formatted: Not Highlight

Formatted: Not Highlight

Formatted: Not Highlight

Formatted: Line spacing: Double

Formatted: Font: Bold

Formatted: Not Highlight

Formatted: Not Highlight

Formatted: Not Highlight

Formatted: Not Highlight

phase has taken place. During the same phase, ~~macrophage 1~~ (M1) goes under transition to become ~~macrophage 2~~ (M2). However, the number of M1 is still above M2. ~~Whereas~~ However, on the 5th day, M2 plays a more dominant role than M1 on the wounds.

Formatted: Not Highlight

Proliferation phase also takes place during this time in which fibroblasts migrate to the wound area.^[3] Then, the peak of the angiogenesis phase starts on the 7th day.^[6] M2 acts as an anti-inflammatory in which macrophages release IL-10 and TGF- β , a very strong anti-inflammatory agent that immediately stops the inflammatory process and starts the proliferation phase.^[4] This is the reason why we as researchers observed TGF- β 1 expression as one of the important growth factors in wound-wound-healing process.

Formatted: Check spelling and grammar
Formatted: Not Highlight
Formatted: Check spelling and grammar
Formatted: Not Highlight
Formatted: Not Highlight
Formatted: Not Highlight
Formatted: Not Highlight
Formatted: Check spelling and grammar
Formatted: Not Highlight

The results of our research confirm the hypothesis that the administration of okra fruit extract can increase TGF- β 1 expression in the wound-wound-healing process after tooth extraction

Formatted: Indent: First line: 0 cm, Line spacing: Double

of Wistar rats with DM. Observations were done by calculating the amount of TGF- β 1

Formatted: Not Highlight

expression in both groups, namely the control group (K) and the treatment group (P). In group K, the TGF- β 1 expression from Wistar tooth socket is less than in group P. However,

Formatted: Not Highlight

in both K and P groups, we found ~~that~~ the highest number of TGF- β 1 expression on the 7th day, as compared to on the 3rd and 5th day. This is due to the fact that the healing process that

Formatted: Not Highlight
Formatted: Not Highlight
Formatted: Not Highlight

involves fibroblasts cell infiltration to the wound occurs the most on the 7th day; thus, the number of TGF- β 1 expression is higher than the 3rd and 5th day.^[3,4]

Formatted: Not Highlight

—The mean number of TGF- β 1 expression in the K group shows lower results than the

Formatted: Not Highlight
Formatted: Not Highlight

P group due to the STZ induction. A few days after the STZ induction, a ~~damaged~~ damage occurs in pancreatic beta-cells which results in insulin resistance and high blood glucose

Formatted: Check spelling and grammar
Formatted: Line spacing: Double
Formatted: Not Highlight
Formatted: Not Highlight

level. In addition, the increased oxidative stress due to the formation of Advanced Glycation end products (AGEs) causes disruption of the fibroblast's proliferation, migration, and dysfunction.^[6]

Commented [CE11]: Kindly provide expansion.

Formatted: Check spelling and grammar
Formatted: Not Superscript/ Subscript

Yamano *et al.* state that at the beginning of tooth extraction, the lowest amount of TGF- β 1 expression is obtained compared to the following day.^[16] In addition, a study by Hozzein *et al.* also infers that the administration of intraperitoneal STZ can cause a significant decrease in the regulation of TGF- β 1 in wound tissue.^[17]

Formatted: Not Highlight
Formatted: Not Highlight
Formatted: Check spelling and grammar

In DM patients, an uncontrolled glycemic control causes a disruption in wound healing process, which is a disturbance in the angiogenesis activity that causes pathogenesis mechanism.^[18] In group K, TGF- β 1 expression increased significantly on day 3-5, while on days 5-7, the expression of TGF- β 1 also increased, though not as significant.

Formatted: Not Highlight
Formatted: Check spelling and grammar
Formatted: Not Superscript/ Subscript

This is due to the fact that DM condition disrupts the innate role and function of immunity cells. High glucose level increases the cellular nuclear factor- κ B (NF- κ B) activation. If an injury occurs, the prolonged inflammatory phase results in a pro-inflammatory response that increases the occurrence of chronic inflammation and tissue damage.^[6]

Formatted: Check spelling and grammar
Formatted: Not Highlight
Formatted: Not Highlight
Formatted: Not Highlight
Formatted: Not Highlight

High blood glucose level induces ROS which can be produced both enzymatically and non-enzymatically. Enzymatic production includes nicotinamide adenine dinucleotide phosphate oxidase (NADPH oxidase), nitric oxide synthase (NOS), cytochrome P-450, cyclooxygenase (COX), lipoxygenase (LOX), xanthine oxidase, and myeloperoxidase (MPO)^[19] and results

Formatted: Not Highlight
Formatted: Not Highlight
Formatted: Not Highlight
Formatted: Check spelling and grammar

in high pro-inflammatory cytokines which are released by neutrophils and macrophages as well as an increase in abnormal protease activity, resulting in disruption of growth factor signaling in the wound healing process. This signaling disruption causes a decrease in growth factor and disrupts in the angiogenesis phase.^[13]

Formatted: Indent: First line: 0 cm, Line spacing: Double
Formatted: Not Highlight

Formatted: Check spelling and grammar
Formatted: Not Highlight

On the other hand, the P group had higher average TGF- β 1 as compared to K group due to the difference in okra fruit extract administration.^[20] Thus, it confirms the hypothesis that okra fruit extract can increase TGF- β 1 expression. Okra extract has antioxidant, anti-inflammatory, and anti-diabetic qualities in wound healing process.^[8,10] Okra extract

Formatted: Check spelling and grammar
Formatted: Line spacing: Double
Formatted: Not Highlight
Formatted: Check spelling and grammar

contains polyphenols, flavonoids, isoquercetin, and quercetin-3-O-gentiobiose. Flavonoid is

Formatted: Not Highlight
Formatted: Not Highlight
Formatted: Not Highlight
Formatted: Check spelling and grammar

useful to repair damaged cells and forms a normal ~~wound-wound~~-healing process by inducing fibroplasia by TGF- β 1.^[21] Quercetin plays a role in regulating TGF- β 1 expression and decreasing the number of inflammatory cells. Quercetin also decreases the number of TNF- α while increasing fibroblasts proliferation and micro blood vessel density, leading to better ~~re-~~epithelialization and regular collagen deposition.^[22] Pang *et al.* state that low-dose flavonoid alone is able to stimulate TGF- β 1 expression which in turn increases TGF- β expression by macrophage stimulation induced by total flavonoids in wounds.^[23] TGF- β 1, secreted by M2 phenotype macrophages, plays a role in inhibiting the recruitment of inflammatory cells.^[24] TGF- β induces the keratinocyte and fibroblasts proliferation, causing the new capillaries formation in ~~the~~ granulation tissue and modulation of ~~ECM~~extracellular matrix deposition resulting in wound healing. TGF- β 1 also plays a role in angiogenesis by increasing the regulation of VEGF. During wound closure, TGF- β 1 increases keratinocyte migration.^[17]

—In addition to reducing ~~pro-inflammatory~~ mediator production, okra fruit plays a role in reducing nitric oxide amount and ROS, as well as in reducing the production of TNF- α .^[20] Excessive production of ROS causes activation of the NF- κ B signaling pathway. NF- κ B is a protein that stimulates cytokines and free radicals. It is also a transcription factor that regulates large numbers of genes involved in various immune and inflammatory response processes and causes vascular complications in DM patients and in inflammatory pathogenic processes that can be inhibited by flavonoids.^[21]

Flavonoid contained in okra fruit can reduce blood glucose level,^[10] resulting in a decrease in ~~pro-inflammatory~~ cytokines.^[20] High concentration of fiber and polysaccharides in the okra fruit can stabilize blood glucose by limiting the rate of absorption of sugar in the intestine.^[25] This complements the flavonoid content of the okra fruit which functions as an inhibitor of α -amylase and α -glucosidase, the enzymes found in the small intestine^[21] which act as carbohydrate catalyst by catalyzing oligosaccharides so that glucose absorption may take

Formatted: Not Highlight

Formatted: Check spelling and grammar

Formatted: Not Highlight

Formatted: Not Highlight

Formatted: Not Highlight

Formatted: Check spelling and grammar

Formatted: Not Highlight

Formatted: Not Highlight

Formatted: Not Highlight

Formatted: Not Highlight

Formatted: Check spelling and grammar

Formatted: Not Highlight

Formatted: Check spelling and grammar

Formatted: Not Highlight

Formatted: Not Highlight

Formatted: Not Highlight

Formatted: Not Highlight

Formatted: Check spelling and grammar

Formatted: Not Highlight

Formatted: Not Highlight

Formatted: Check spelling and grammar

Formatted: Not Highlight

Formatted: Not Highlight

Formatted: Check spelling and grammar

Formatted: Indent: First line: 0 cm, Line spacing: Double

Formatted: Check spelling and grammar

Formatted: Not Highlight

Formatted: Check spelling and grammar

Formatted: Check spelling and grammar

Formatted: Not Highlight

Formatted: Not Highlight

Formatted: Check spelling and grammar

place. Inhibition of α -glucosidase can cause catalysis of complex carbohydrate diets such as oligosaccharides and polysaccharides to be inhibited by monosaccharides, resulting in decreased blood glucose level.^[10,12]

Formatted: Not Highlight

Glycoprotein-A repetitions predominant protein (GARP) is an important regulator in activating latent TGF- β (LTGF- β) and then binding it to LTGF- β . GARP acts as a docking receptor that functions as a carrier of LTGF- β on the cell surface, activating its role.^[7] GARP also plays a role in the regulation of T lymphocytes (Tregs) that form complexes with the α V β 8 integrin to release active TGF- β from the cell surface.^[17] TGF- β 1 stimulates fibroblasts to differentiate into myofibroblasts and then collaborates with these myofibroblasts to produce extracellular matrix (ECM), as well as collagen and matrix proteins, namely fibronectin.^[5] TGF- β 1 together with VEGF and fibroblasts stimulate the angiogenesis process.^[17] This explains the higher expression of TGF- β 1 in P group as compared to K group. Therefore, it can accelerate wound-wound-healing process in the P group.

Formatted: Check spelling and grammar

Formatted: Not Highlight

Formatted: Not Highlight

Formatted: Not Highlight

Formatted: Not Highlight

Formatted: Not Highlight

Formatted: Check spelling and grammar

Formatted: Not Highlight

Formatted: Not Highlight

Formatted: Check spelling and grammar

Formatted: Not Highlight

Formatted: Check spelling and grammar

Formatted: Not Highlight

Formatted: Check spelling and grammar

Formatted: Not Highlight

<H1>CONCLUSION

Formatted: Line spacing: Double

The administration of okra fruit extract can increase the number of TGF- β 1 in tooth extraction wounds on Wistar rats with DM.

Formatted: Font: Bold

Formatted: Not Highlight

<H2>Financial support and sponsorship

Nil.

<H2>Conflicts of interest

The authors of this manuscript declare that they have no conflicts of interest, real or perceived, financial or nonfinancial in this article.

<H1>REFERENCES

Formatted: Line spacing: Double

Formatted: Font: Bold

Table list

Formatted: Justified, Space After: 0 pt, Line spacing: Double

Table 1. Mean, standard deviation, and normality test of TGF-β1 expression (macrophage cells count) in the control and treatment group.

Group	Mean±SD	P-value
KO1	5.32±1.69	0.001
KO2	8.47±0.60	
KO3	9.28±1.16	
PO1	11.59±0.58	
PO2	15.15±1.07	
PO3	18.75±2.73	

Table 2. Tukey HSD *post hoc* multiple comparisons test results in the control and treatment group

Group	KO1	KO2	KO3
KO1		0.030*	0.009*
KO2	0.030*		0.710
Group	PO1	PO2	PO3
PO1		0.041*	0.001*
PO2	0.041*		0.039*

Remarks = * there is a significant difference

1. [Reinke JM, Sorg H. Wound repair and regeneration. Eur Surg Res 2012;49:35-43.](#)
2. [Benadiba M, Serruya R, Maor Y. Bioaccessibility of Shore Magic® collagen, a low-molecular-weight collagen supplement, in different *in vitro* barrier models. Heliyon 2018;4:e00821.](#)

3. [Du Y, Ren P, Wang Q, Jiang SK, Zhang M, Li JY, et al. Cannabinoid 2 receptor attenuates inflammation during skin wound healing by inhibiting M1 macrophages rather than activating M2 macrophages. J Inflamm \(Lond\) 2018;15:25.](#)
4. [Anderson K, Hamm RL. Factors that impair wound healing. J Am Coll Clin Wound Spec 2012;4:84-91.](#)
5. [Zhao R, Liang H, Clarke E, Jackson C, Xue M. Inflammation in chronic wounds. Int J Mol Sci 2016;17:2085.](#)
6. [Kido D, Mizutani K, Takeda K, Mikami R, Matsuura T, Iwasaki K, et al. Impact of diabetes on gingival wound healing via oxidative stress. PLoS One 2017;12:e0189601.](#)
7. [Liu Y, Li Y, Li N, Teng W, Wang M, Zhang Y, et al. TGF- \$\beta\$ 1 promotes scar fibroblasts proliferation and transdifferentiation via up-regulating MicroRNA-21. Sci Rep 2016;6:1-9.](#)
8. [Bhowmik D, Sampath Kumar KP, Tripathi P. Traditional herbal medicines: An overview. Arch Appl Sci Res 2009;1:165-77.](#)
9. [Solomon S. Anti-oxidant and anti-inflammatory activity of *Abelmoschus esculentus* \(Flowers\). Indo Am J Pharm Sci 2016:600-5.](#)
10. [Abbas AY, Muhammad I, AbdulRahman MB, Bilbis LS, Saidu Y, Onu A. Possible antidiabetic mechanism of action of ex-maradi okra fruit variety \(*Abelmoschus esculentus*\) on alloxan induced diabetic rats. Niger J Basic Appl Sci 2018;25:101.](#)
11. [Yeo YL, Chia YY, Lee CH, Sow HS, Yap WS. Effectiveness of maceration periods with different extraction solvents on *in-vitro* antimicrobial activity from fruit of *Momordica charantia* L. J Appl Pharm Sci 2014;4:16-23.](#)

12. [Tian ZH, Miao FT, Zhang X, Wang QH, Lei N, Guo LC. Therapeutic effect of okra extract on gestational diabetes mellitus rats induced by streptozotocin. Asian Pac J Trop Med 2015;8:1038-42.](#)
13. [Qinna NA, Badwan AA. Impact of streptozotocin on altering normal glucose homeostasis during insulin testing in diabetic rats compared to normoglycemic rats. Drug Des Devel Ther 2015;9:2515-25.](#)
14. [Gunawan F, Sularsih S, Soemartono S. The differences effect between low and high molecular weight chitosan on number of lymphocyte cells in the wound healing process of dental extraction. Dent J Kedokt Gigi 2015;9:113-22.](#)
15. [Sula B, Deveci E, Özevren H, Ekinci C, Elbey B. Immunohistochemical and histopathological changes in the skin of rats after administration of lead acetate. Int J Morphol 2016;34:918-22.](#)
16. [Yamano S, Kuo WP, Sukotjo C. Downregulated gene expression of TGF-βs in diabetic oral wound healing. J Craniomaxillofac Surg 2013;41:e42-8.](#)
17. [Hozzein WN, Badr G, Al Ghamdi AA, Sayed A, Al-Waili NS, Garraud O. Topical application of propolis enhances cutaneous wound healing by promoting TGF-beta/Smad-mediated collagen production in a streptozotocin-induced type I diabetic mouse model. Cell Physiol Biochem 2015;37:940-54.](#)
18. [Raghav A. Crucial role of diabetes mellitus in delayed angiogenesis of wound. J Pharmacol Clin Res 2018;5:4.](#)
19. [Fakhruddin S, Alanazi W, Jackson KE. Diabetes-induced reactive oxygen species: Mechanism of their generation and role in renal injury. J Diabetes Res 2017;2017:8379327.](#)
20. [Shah BN, Seth AK. Anti-inflammatory activity of fruits of *Abelmoschus esculantus* Linn. Pharmacol Online 2010;1:208-12.](#)

Formatted: Check spelling and grammar

Commented [s12]: Kindly check the page number.

Formatted: Font: 12 pt

21. Roy A, Shrivastava SL, Mandal SM. Functional properties of Okra *Abelmoschus esculentus* L. (Moench): Traditional claims and scientific evidences. *Plant Sci Today* 2014;1:121-30.
22. Gopalakrishnan A, Ram M, Kumawat S, Tandan S, Kumar D. Quercetin accelerated cutaneous wound healing in rats by increasing levels of VEGF and TGF- β 1 – PubMed. *Indian J Exp Biol* 2016;54:187-95.
23. Pang Y, Zhang Y, Huang L, Xu L, Wang K, Wang D, *et al*. Effects and mechanisms of total flavonoids from *Blumea balsamifera* (L.) DC. on skin wound in rats. *Int J Mol Sci* 2017;18:2766.
24. Liu YC, Zou XB, Chai YF, Yao YM. Macrophage polarization in inflammatory diseases. *Int J Biol Sci* 2014;10:520-9.
25. Durazzo A, Lucarini M, Novellino E, Souto EB, Daliu P, Santini A. *Abelmoschus esculentus* (L.): Bioactive components' beneficial properties-focused on antidiabetic role-for sustainable health applications. *Molecules* 2018;24:38.

Formatted: Line spacing: Double

Formatted: Line spacing: Double

Figure List Legends

Figure 1-: Expression of transforming growth factor beta 1 TGF- β 1 in day 3, 5, and 7 in socket tissues of Wistar rats with diabetes mellitus in immunohistochemistry examination in microscope with $\times 400\times$ magnification in control group (K₀) and treatment group (P₀).

Figure 2-: Mean value graph of transforming growth factor beta 1 TGF- β 1 expression on day 3, 5, and 7.

Formatted: Font: Bold

Formatted: Font: Bold

Formatted: Line spacing: Double

Formatted: Font: Bold

Formatted: Not Highlight

Formatted: Font: Bold

Formatted: Not Highlight

Formatted: Justified

Tables

Table 1: Mean, standard deviation, and normality test of transforming growth factor beta 1 expression (macrophage cells count) in the control and treatment group

<u>Group</u>	<u>Mean±SD</u>	<u>P</u>
<u>KO1</u>	<u>5.32±1.69</u>	<u>0.001</u>
<u>KO2</u>	<u>8.47±0.60</u>	
<u>KO3</u>	<u>9.28±1.16</u>	
<u>PO1</u>	<u>11.59±0.58</u>	
<u>PO2</u>	<u>15.15±1.07</u>	
<u>PO3</u>	<u>18.75±2.73</u>	

Formatted Table

SD: Standard deviation

Table 2: Tukey honestly significant difference *post hoc* multiple comparisons test results in the control and treatment group

<u>Group</u>	<u>KO1</u>	<u>KO2</u>	<u>KO3</u>
<u>KO1</u>		<u>0.030*</u>	<u>0.009*</u>
<u>KO2</u>	<u>0.030*</u>		<u>0.710</u>
<u>Group</u>	<u>PO1</u>	<u>PO2</u>	<u>PO3</u>
<u>PO1</u>		<u>0.041*</u>	<u>0.001*</u>
<u>PO2</u>	<u>0.041*</u>		<u>0.039*</u>

*There is a significant difference

Formatted Table

Commented [Table13]: Kindly check table formation.

Table 2: Tukey honestly significant difference *post hoc* multiple comparisons treatment group

<u>Group</u>	<u>KO1</u>	<u>KO2</u>	<u>KO3</u>
<u>KO1</u>		<u>0.030*</u>	<u>0.009*</u>
<u>KO2</u>	<u>0.030*</u>		<u>0.710</u>
<u>Group</u>	<u>PO1</u>	<u>PO2</u>	<u>PO3</u>
<u>PO1</u>		<u>0.041*</u>	<u>0.001*</u>
<u>PO2</u>	<u>0.041*</u>		<u>0.039*</u>

Remarks: *There is a significant difference

Formatted Table

Formatted: Font: Bold

Formatted: Centered

Commented [Table14]: Kindly check table formation.

Formatted: Line spacing: Double

Proofs corrections

Journal

Article title

I would like to recheck the corrections: Yes / No

If you have access to Acrobat, it may be helpful to mark the corrections in the PDF file using PENCIL and NOTE tools. Alternatively provide the list of corrections using this table. Please make the corrections' list self-explanatory and easy to understandable for a non-medical technical person.

List of corrections

Page number	Column (Left / Right)	Paragraph number from top	Line number from top of paragraph	Delete this text (Error)	Replace deleted text with (correction)
1	Left	AQ8	9		has been followed up
2	Left	AQ1	10		Airlangga
3	Right	AQ2	52		Yuliati (author has no initials)
4	Left	AQ4	13	Specifically, in gingival wound-healing process of diabetic patients insulin-induced fibroblasts dysfunction occurs soon after tooth extraction. This is associated with a decrease in the level of transforming growth factor beta 1 (TGF-b1) gene expression	which results in fibroblast dysfunction occurring in the wound healing process in diabetic patients, resulting in a decrease in the expression level of the tumor growth factor beta 1 (TGF- β 1) gene.
5	Right	AQ7	33	Table 2: Tukey honestly significant difference post hoc multiple comparisons test results in the control and treatment group	Table 2. Tukey's multiple comparison test in the control and treatment groups

6	Left	AQ5	36	Advanced Glycation end products (AGEs)	Advanced Glycation end products (AGEs) (already available)
7	Left	AQ6	12	Fakhruddin S, Alanazi W, Jackson KE. Diabetes-induced reactive oxygen species: Mechanism of their generation and role in renal injury. J Diabetes Res 2017;2017:8379327.	Fakhruddin S, Alanazi W, Jackson KE. Diabetes-induced reactive oxygen species: Mechanism of their generation and role in renal injury. J Diabetes Res 2017;1-30
8	Right		37	Good health and well-being	none

Original Article

The efficacy of okra fruit extract on the expression of transforming growth factor beta 1 in the tooth socket of diabetic Wistar rats

Muhammad Luthfi¹, Yuliati¹, Elvina Hasna Wijayanti², Fathilah Binti Abdul Razak³, Wahyuning Ratih Irmalia⁴

Departments of ¹Oral Biology and ²Undergraduate Program, Faculty of Dental Medicine, Airlangga University, ⁴Indonesian Health Collaboration and Innovation Institute, Surabaya, Indonesia, ³Department of Oral and Craniofacial Sciences. Faculty of Dentistry, University of Malaya, Kuala Lumpur, Malaysia

ABSTRACT

Background: Patients with diabetes mellitus suffer from an additional macrophage dysfunction in the secretion of growth factor, which later decreases transforming growth factor beta 1 (TGF- β 1). This condition disrupts proliferation and angiogenesis. Extract of okra fruit (*Abelmoschus esculentus*) contains flavonoid, an active substance which acts as antioxidant, anti-inflammation, and antidiabetes. The purpose of this study is to analyze the difference in TGF- β 1 expression in wound-healing process after tooth extraction of diabetic Wistar rats.

Materials and Methods: This is a laboratory experimental study using pretest and posttest on 24 Wistar rats which are divided into two groups: control group (treated with streptozotocin induction but without administration of okra fruit extract) and treatment group (treated with streptozotocin induction and oral administration of 250 mg/kg okra fruit extract once a day). Extractions of the rats' mandibular left incisors were performed using a pair of modified forceps and an elevator. The tooth sockets were then irrigated using saline solution. Four rats in each group were sacrificed on day 3 (KO1, PO1), 5 (KO2, PO2), and 7 (KO3, PO3). The socket tissues from the rats were then immunohistochemically analyzed. Data were analyzed at level significance of 0.05.

Results: The average level of TGF- β 1 expression in the treatment groups was higher compared to the control group: PO1 (11.59 ± 0.58), PO2 (15.15 ± 1.07), and PO3 (18.75 ± 2.73) as compared to KO1 (5.32 ± 1.69), KO2 (8.47 ± 0.60), and KO3 (9.28 ± 1.16) with $P = 0.001$.

Conclusion: The administration of okra fruit extract can increase the level of TGF- β 1 in wounds after tooth extraction of diabetic Wistar rats.

Key Words: Diabetes mellitus, okra fruit, transforming growth factor beta 1, wound healing, none

Received: September 2020
Accepted: April 2021

Address for correspondence:
Dr. Muhammad Lutfi,
Department of Oral Biology,
Faculty of Dental Medicine,
University of Airlangga, Jl.
Mayjend. Prof. Dr. Moestopo
47 60 132 Surabaya,
Indonesia.
E-mail: m.luthfi@fkg.unair.
ac.id

INTRODUCTION

Wound healing is a complex biological process involving hemostasis, inflammation, proliferation, and remodeling.^[1] On the 3rd day of wound-healing process, there is a transition from inflammatory phase

to proliferation phase, in which a transition from macrophage-1 (M1) to macrophage-2 (M2) occurs. The 5th day is the proliferation phase, in which fibroblasts are transferred to the injured area and

This is an open access journal, and articles are distributed under the terms of the Creative Commons Attribution-NonCommercial-ShareAlike 4.0 License, which allows others to remix, tweak, and build upon the work non-commercially, as long as appropriate credit is given and the new creations are licensed under the identical terms.

For reprints contact: WKHLRPMedknow_reprints@wolterskluwer.com

How to cite this article: Luthfi M, Yuliati, Wijayanti EH, Razak FB, Irmalia WR. The efficacy of okra fruit extract on the expression of transforming growth factor beta 1 in the tooth socket of diabetic Wistar rats. Dent Res J 2021;XX:XX-XX.

Access this article online



Website: www.drj.ir
www.drjjournal.net
www.ncbi.nlm.nih.gov/pmc/journals/1480

M2 plays a dominant role as an anti-inflammatory agent. On the 7th day, the angiogenesis phase reaches its peak.^[2,3] It is also known that healing process is influenced by systemic factors, one of which is comorbidities, such as diabetes mellitus (DM). DM is known to cause macrophage dysfunction in the patients.^[4]

Wound-healing process involves a series of activities of damage repair. Prolonged high-blood glucose level may cause a prolonged inflammatory process and high anti-inflammatory activity.^[5] Which results in fibroblast dysfunction occurring in the wound healing process in diabetic patients, resulting in a decrease in the expression level of the tumor growth factor beta 1 (TGF- β 1) gene.^[6] TGF- β 1 expression plays a dominant role in wound recovery among other TGF- β isoforms because TGF- β 1 functions to increase proliferation, collagen formation, and differentiation of fibroblasts in the wound proliferation phase. Besides, TGF- β 1 also plays a role in forming extracellular matrix (ECM) secretion and those related to morphological proliferation, mononuclear cell differentiation, and osteocytes. TGF- β 1 is involved in angiogenesis by increasing the regulation of vascular endothelial growth factor (VEGF). During wound closure process, TGF- β 1 increases keratinocyte transfer.^[7]

Along with the advancement of science, various treatments have been developed to overcome this problem, one of which uses herbal ingredients. Herbs are in great demand and are used by around 80% of the world's population because of the benefits in terms of safety, effectiveness, cultural acceptance, and less substantial side effects as compared to synthetic chemicals.^[8] One herb that can accelerate wound-healing process is the fruit of okra plant (*Abelmoschus esculentus*).

Okra fruit has antioxidant, anti-inflammatory,^[9] and antidiabetic^[10] qualities in the process of wound healing. The antioxidant quality of okra is needed in the process of wound healing to eliminate the effects of reactive oxygen species (ROS). Okra fruit's anti-inflammatory feature decreases the production of proinflammatory mediators, such as nitric oxide and ROS, and the production of tumor necrosis factor alpha (TNF- α) and interleukin-1 beta (IL-1 β) stimulated by lipopolysaccharide.^[9] Flavonoids found in okra fruit also play a role in lowering blood glucose level due to its isoquercetin content,

which regulates the level of blood glucose and increases immunoreactivity of pancreatic β -cells. In addition, it also has a role in wound-healing process.^[9,10] The objective of this study is to calculate the level of expression of TGF- β 1 in posttooth extraction wound-healing process in Wistar rats with DM. In addition, this study also aims to verify that administration of okra fruit extract can increase TGF- β 1 expression in posttooth extraction wound-healing process in Wistar rats with DM.

MATERIALS AND METHODS

Research design and animal model

This is a laboratory-based of analytic experimental study, with posttest-only control group design. Wistar rats used as samples in this study were obtained from the Experimental Animal Unit of the Biochemical Laboratory of the Faculty of Medicine, Universitas Airlangga. Ethical clearance of the research was issued by the Health Research Ethical Clearance Commission with a clearance certificate numbered 231/HRECC.FODM/V/2019.

Collection, adjustment, maintenance, and treatment were carried out in the Experimental Animal Unit of the Biochemical Laboratory of the Faculty of Medicine, Universitas Airlangga. Okra fruit was extracted in Materia Medica Batu. Histological preparations were carried out at the Anatomy Pathology Laboratory of the Faculty of Medicine, Universitas Airlangga. Immunohistochemistry dyeing and TGF- β 1 expression calculation were carried out at Brawijaya University, Malang.

Okra fruit extract preparation

Fresh okra fruit collected for the study was dried in a drying oven until a constant weight was reached. The dried fruit was then ground into powder. A total of 2 g of powder was extracted with 20 ml of 70% ethanol in a ratio of 1:10 (w/v) during the maceration period (24 h) at room temperature. The mixture of solvent and soaked powder was filtered through filter paper and then concentrated to 1 ml with a rotary evaporator and diluted with 5% dimethyl sulfoxide at a ratio of 1:1 (v/v). The results were then stored at a temperature of -20°C until further use.^[11]

Research procedure

In this study, 24 male Wistar rats aged 2–3 months with a weight of 150–200 g were adapted in the same cage at $25^{\circ}\text{C} \pm 2^{\circ}\text{C}$. The 24 Wistar rats were divided into two groups (control group and treatment group).

The rats were supplied with standard pellet food and distilled water *ad libitum* for 7 days and for 4 h before being induced with streptozotocin (STZ) (Nacalai Tesque Inc., Japan). The 2% STZ solution was dissolved with 0.1 mol/L citrate buffer solution with pH of 4.4 at a dose of 45 mg/kg and converted to a dose of 6.75 mg/150 g. The solution was then administered to the Wistar rats through intraperitoneal induction.^[12] Blood glucose levels were measured on day 3 after STZ induction by taking blood sample from the lateral veins in the rats' tails. Measurements were performed using a glucometer (Accu Chek® Instant). The Wistar rats were diagnosed with DM if the blood glucose levels ≥ 200 mg/dl after the STZ induction.^[13] The rats' weight during experiment was not measured.

Wistar rats with DM were then anesthetized through peritoneal injection using 0.1 ml of ketamine per rat. A resting period of 1–1.5 h was given after the injection, after which extractions of the rats' mandibular left incisors were performed using a pair of modified forceps and an elevator. The tooth sockets were then irrigated with saline solution.^[14]

In the control group, the animals did not receive administration of okra fruit extract. Instead, they were only supplied with distilled water before the observation. K_{O1} was observed on the 3rd day, K_{O2} was observed on the 5th day, and K_{O3} was observed on the 7th day. In the treatment group, the rats were given oral administration of okra fruit extract after the tooth extraction with a dose of 250 mg/kg which was converted to a dose of 37.5 mg/150 g once a day during the treatment. P_{O1} was observed on the 3rd day, P_{O2} was observed on 5th day, and P_{O3} was observed on 7th day.

Wistar rats were sacrificed on the 3rd, 5th, and 7th day using lethal injection of intraperitoneal ketamine (no < 4 times the anesthetic dose or about 0.4 ml/kg). The mandibular of each rat was taken from the temporomandibular joint. After which, the Wistar rats were buried according to the ethical treatments of experimental animals. The mandibles in the incisor area were cut vertically and treated with paraffin method.

Histopathological specimen preparation

The histological examination procedure was started by putting the tissues into formalin buffer (10% formalin solution in phosphate-buffered saline [PBS] pH 7) to be fixed and then put into paraffin wax. The

tissues were cut into slides with a length of 4–6 mm on the glass slide. After being deparaffinized with xylene, the slides were submerged in graded alcohol for dehydration and incubation with EDTA (pH = 8.0) in a microwave oven (750 W) to take TGF- $\beta 1$ antigens. Slides were incubated for 20 min in 3% H_2O_2 to inhibit endogenous peroxidase activity and then rinsed three times with PBS for 5 min each. The slides were then incubated with blocking solutions using a superbloc (Scy Tek Laboratories Inc., US) and peroxide block (Scy Tek Laboratories Inc., US). Slides were incubated overnight with TGF- $\beta 1$ antibodies (ab 27969: Abcam, Burlingame, US). After being washed in PBS, the slides were treated with UltraTek antipolyvalent biotinylated antibodies (Scy Tek Laboratories Inc., US) and UltraTek HRP (Scy Tek Laboratories Inc., US). This reaction was visualized by incubating the slides for 7 min in 0.1% 3.3 diaminobenzidine and 0.02% hydrogen peroxide solution. Slides were then counterstained with Mayer's hematoxylin (Scy Tek Laboratories Inc., US) and covered. Immunohistochemical positive staining was defined as the detection of brown chromogen from DAB Chromogen staining (Scy Tek Laboratories Inc., US) at the edge of the hematoxylin-stained nucleus distributed in the cytoplasm or plasma cell membrane and analyzed under a light microscope with $\times 1000$ at 20 visual fields. TGF- $\beta 1$ expression would be seen as positive, immunoreactive cells with a yellowish to brown color, while negative cells would correspond to the counterstain coloring agent used.^[15]

Statistical analysis

Statistical analysis was performed using SPSS (IBM SPSS Statistics for Windows, Version 24.0: IBM Corp., USA). Shapiro–Wilk test was used to find out normally distributed data. After the distribution test, Levene's homogeneity test was then performed. Once the distribution was found normal and the data were homogeneous, the analysis was continued with one-way analysis of variance (ANOVA) test and with multiple comparison test using Tukey honestly significant difference (HSD) test.

RESULTS

Based on the laboratory experiment using 24 Wistar rats which were divided into control (K_O) and treatment (P_O) groups, the researchers have observed the wounds from the extraction of the left maxillary incisors on day 3,

5, and 7 to measure the number of TGF- β 1 expression in the wound-healing process after tooth extraction of Wistar rats with DM. The blood glucose level of all rats was above 200 mg/dl after the induction. TGF- β 1 examination was carried out under a light microscope with $\times 1000$ at 20 visual fields [Figure 1].

We observed the expression of TGF- β 1 both with and without okra fruit extract administration. The ANOVA test showed a significant difference among the groups [Table 1]. Meanwhile, the multiple comparison test result using Tukey HSD showed a significant increase of TGF- β 1 expression observed on day 3, 5, and 7 in the control group. Likewise, the treatment group also exhibited the same results for day 3, 5, and 7 [Table 2].

TGF- β 1 expressions on days 3, 5, and 7 on the prepared Wistar rats' socket tissues with DM were calculated using a light microscope with $\times 400$ at four visual fields [Figure 1]. TGF- β 1 expression appears as gradients of yellow to brown stains pointed with arrows. Based on Figure 2, it can be seen that on the 3rd day, P_{O1} group showed increasing number of TGF- β 1 expression as compared to K_{O1} group. On the 5th day, P_{O2} showed increasing number of TGF- β 1 expression as compared to K_{O2} group. On the 7th day, P_{O3} showed increasing number of TGF- β 1 expression as compared to K_{O3} group.

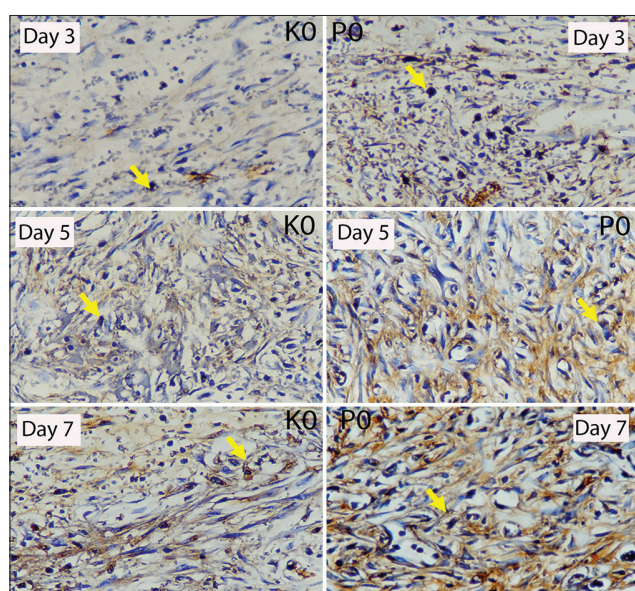


Figure 1: Expression of transforming growth factor beta 1 in day 3, 5, and 7 in socket tissues of Wistar rats with diabetes mellitus in immunohistochemistry examination in microscope with $\times 400$ in control group (K_O) and treatment group (P_O).

DISCUSSION

This research aims to prove that okra fruit extract can increase the expression of TGF- β 1 in wound-healing process after tooth extraction in Wistar rats with DM. The observations of TGF- β 1 expression were carried out on day 3, 5, and 7. Since the 3rd day of the wound-healing process, a transition from inflammatory phase to proliferation phase has taken place. During the same phase, M1 goes under transition to become M2. However, the number of M1 is still above M2. However, on the 5th day, M2 plays a more dominant role than M1 on the wounds. Proliferation phase also takes place during this time in which fibroblasts migrate to the wound area.^[3] Then, the peak of the angiogenesis phase starts on the 7th day.^[6] M2 acts as

Table 1: Mean, standard deviation, and normality test of transforming growth factor beta 1 expression (macrophage cells count) in the control and treatment group

Group	Mean \pm SD	P
KO1	5.32 \pm 1.69	0.001
KO2	8.47 \pm 0.60	
KO3	9.28 \pm 1.16	
PO1	11.59 \pm 0.58	
PO2	15.15 \pm 1.07	
PO3	18.75 \pm 2.73	

SD: Standard deviation

Table 2: Tukey's multiple comparison test in the control and treatment groups

Group	KO1	KO2	KO3
KO1		0.030*	0.009*
KO2	0.030*		0.710
Group	PO1	PO2	PO3
PO1		0.041*	0.001*
PO2	0.041*		0.039*

*There is a significant difference

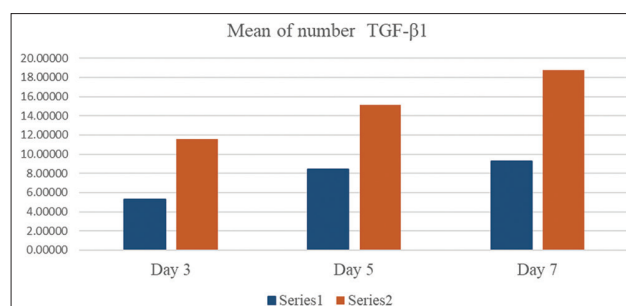


Figure 2: Mean value graph of transforming growth factor beta 1 expression on day 3, 5, and 7.

an anti-inflammatory in which macrophages release IL-10 and TGF- β , a very strong anti-inflammatory agent that immediately stops the inflammatory process and starts the proliferation phase.^[4] This is the reason why we as researchers observed TGF- β 1 expression as one of the important growth factors in wound-healing process.

The results of our research confirm the hypothesis that the administration of okra fruit extract can increase TGF- β 1 expression in the wound-healing process after tooth extraction of Wistar rats with DM. Observations were done by calculating the amount of TGF- β 1 expression in both groups, namely the control group (K) and the treatment group (P). In group K, the TGF- β 1 expression from Wistar tooth socket is less than in group P. However, in both K and P groups, we found the highest number of TGF- β 1 expression on the 7th day, as compared to on the 3rd and 5th day. This is due to the fact that the healing process that involves fibroblasts cell infiltration to the wound occurs the most on the 7th day; thus, the number of TGF- β 1 expression is higher than the 3rd and 5th day.^[3,4]

The mean number of TGF- β 1 expression in the K group shows lower results than the P group due to the STZ induction. A few days after the STZ induction, damage occurs in pancreatic beta-cells which results in insulin resistance and high-blood glucose level. In addition, the increased oxidative stress due to the formation of Advanced Glycation end products (AGEs) causes disruption of the fibroblast's proliferation, migration, and dysfunction.^[6]

Yamano *et al.* state that at the beginning of tooth extraction, the lowest amount of TGF- β 1 expression is obtained compared to the following day.^[16] In addition, a study by Hozzein *et al.* also infers that the administration of intraperitoneal STZ can cause a significant decrease in the regulation of TGF- β 1 in wound tissue.^[17]

In DM patients, an uncontrolled glycemic control causes a disruption in wound-healing process, which is a disturbance in the angiogenesis activity that causes pathogenesis mechanism.^[18] In group K, TGF- β 1 expression increased significantly on day 3–5, while on days 5–7, the expression of TGF- β 1 also increased, though not as significant. This is due to the fact that DM condition disrupts the innate role and function of immunity cells. High glucose level increases the cellular nuclear factor- κ B (NF- κ B) activation. If an injury

occurs, the prolonged inflammatory phase results in a proinflammatory response that increases the occurrence of chronic inflammation and tissue damage.^[6]

High-blood glucose level induces ROS which can be produced both enzymatically and nonenzymatically. Enzymatic production includes nicotinamide adenine dinucleotide phosphate oxidase (oxidase), nitric oxide synthase, cytochrome P-450, cyclooxygenase, lipoxygenase, xanthine oxidase, and myeloperoxidase^[19] and results in high proinflammatory cytokines which are released by neutrophils and macrophages as well as an increase in abnormal protease activity, resulting in disruption of growth factor signaling in the wound-healing process. This signaling disruption causes a decrease in growth factor and disrupts in the angiogenesis phase.^[13]

On the other hand, the P group had higher average TGF- β 1 as compared to K group due to the difference in okra fruit extract administration.^[20] Thus, it confirms the hypothesis that okra fruit extract can increase TGF- β 1 expression. Okra extract has antioxidant, anti-inflammatory, and antidiabetic qualities in wound-healing process.^[8,10] Okra extract contains polyphenols, flavonoids, isoquercetin, and quercetin-3-O-gentiobiose. Flavonoid is useful to repair damaged cells and forms a normal wound-healing process by inducing fibroplasia by TGF- β 1.^[21] Quercetin plays a role in regulating TGF- β 1 expression and decreasing the number of inflammatory cells. Quercetin also decreases the number of TNF- α while increasing fibroblasts proliferation and micro blood vessel density, leading to better reepithelialization and regular collagen deposition.^[22] Pang *et al.* state that low-dose flavonoid alone is able to stimulate TGF- β 1 expression which in turn increases TGF- β expression by macrophage stimulation induced by total flavonoids in wounds.^[23] TGF- β 1, secreted by M2 phenotype macrophages, plays a role in inhibiting the recruitment of inflammatory cells.^[24] TGF- β induces the keratinocyte and fibroblasts proliferation, causing the new capillaries formation in the granulation tissue and modulation of ECM deposition resulting in wound healing. TGF- β 1 also plays a role in angiogenesis by increasing the regulation of VEGF. During wound closure, TGF- β 1 increases keratinocyte migration.^[17]

In addition to reducing proinflammatory mediator production, okra fruit plays a role in reducing nitric oxide amount and ROS, as well as in reducing

the production of TNF- α .^[20] Excessive production of ROS causes activation of the NF- κ B signaling pathway. NF- κ B is a protein that stimulates cytokines and free radicals. It is also a transcription factor that regulates large numbers of genes involved in various immune and inflammatory response processes and causes vascular complications in DM patients and in inflammatory pathogenic processes that can be inhibited by flavonoids.^[21]

Flavonoid contained in okra fruit can reduce blood glucose level,^[10] resulting in a decrease in proinflammatory cytokines.^[20] High concentration of fiber and polysaccharides in the okra fruit can stabilize blood glucose by limiting the rate of absorption of sugar in the intestine.^[25] This complements the flavonoid content of the okra fruit which functions as an inhibitor of α -amylase and α -glucosidase, the enzymes found in the small intestine^[21] which act as carbohydrate catalyst by catalyzing oligosaccharides so that glucose absorption may take place. Inhibition of α -glucosidase can cause catalysis of complex carbohydrate diets such as oligosaccharides and polysaccharides to be inhibited by monosaccharides, resulting in decreased blood glucose level.^[10,12]

Glycoprotein-A repetitions predominant protein (GARP) is an important regulator in activating latent TGF- β (LTGF- β) and then binding it to LTGF- β . GARP acts as a docking receptor that functions as a carrier of LTGF- β on the cell surface, activating its role.^[7] GARP also plays a role in the regulation of T lymphocytes (Tregs) that form complexes with the α V β 8 integrin to release active TGF- β from the cell surface.^[17] TGF- β 1 stimulates fibroblasts to differentiate into myofibroblasts and then collaborates with these myofibroblasts to produce ECM, as well as collagen and matrix proteins, namely fibronectin.^[5] TGF- β 1 together with VEGF and fibroblasts stimulate the angiogenesis process.^[17] This explains the higher expression of TGF- β 1 in P group as compared to K group. Therefore, it can accelerate wound-healing process in the P group.

CONCLUSION

The administration of okra fruit extract can increase the number of TGF- β 1 in tooth extraction wounds on Wistar rats with DM.

Financial support and sponsorship
Nil.

Conflicts of interest

The authors of this manuscript declare that they have no conflicts of interest, real or perceived, financial or nonfinancial in this article.

REFERENCES

1. Reinke JM, Sorg H. Wound repair and regeneration. *Eur Surg Res* 2012;49:35-43.
2. Benadiba M, Serruya R, Maor Y. Bioaccessibility of Shore Magic® collagen, a low-molecular-weight collagen supplement, in different *in vitro* barrier models. *Heliyon* 2018;4:e00821.
3. Du Y, Ren P, Wang Q, Jiang SK, Zhang M, Li JY, et al. Cannabinoid 2 receptor attenuates inflammation during skin wound healing by inhibiting M1 macrophages rather than activating M2 macrophages. *J Inflamm (Lond)* 2018;15:25.
4. Anderson K, Hamm RL. Factors that impair wound healing. *J Am Coll Clin Wound Spec* 2012;4:84-91.
5. Zhao R, Liang H, Clarke E, Jackson C, Xue M. Inflammation in chronic wounds. *Int J Mol Sci* 2016;17:2085.
6. Kido D, Mizutani K, Takeda K, Mikami R, Matsuura T, Iwasaki K, et al. Impact of diabetes on gingival wound healing via oxidative stress. *PLoS One* 2017;12:e0189601.
7. Liu Y, Li Y, Li N, Teng W, Wang M, Zhang Y, et al. TGF- β 1 promotes scar fibroblasts proliferation and transdifferentiation via up-regulating MicroRNA-21. *Sci Rep* 2016;6:1-9.
8. Bhowmik D, Sampath Kumar KP, Tripathi P. Traditional herbal medicines: An overview. *Arch Appl Sci Res* 2009;1:165-77.
9. Solomon S. Anti-oxidant and anti-inflammatory activity of *Abelmoschus esculentus* (Flowers). *Indo Am J Pharm Sci* 2016:600-5.
10. Abbas AY, Muhammad I, AbdulRahman MB, Bilbis LS, Saidu Y, Onu A. Possible antidiabetic mechanism of action of ex-maradi okra fruit variety (*Abelmoschus esculentus*) on alloxan induced diabetic rats. *Niger J Basic Appl Sci* 2018;25:101.
11. Yeo YL, Chia YY, Lee CH, Sow HS, Yap WS. Effectiveness of maceration periods with different extraction solvents on *in-vitro* antimicrobial activity from fruit of *Momordica charantia* L. *J Appl Pharm Sci* 2014;4:16-23.
12. Tian ZH, Miao FT, Zhang X, Wang QH, Lei N, Guo LC. Therapeutic effect of okra extract on gestational diabetes mellitus rats induced by streptozotocin. *Asian Pac J Trop Med* 2015;8:1038-42.
13. Qinna NA, Badwan AA. Impact of streptozotocin on altering normal glucose homeostasis during insulin testing in diabetic rats compared to normoglycemic rats. *Drug Des Devel Ther* 2015;9:2515-25.
14. Gunawan F, Sularsih S, Soemartono S. The differences effect between low and high molecular weight chitosan on number of lymphocyte cells in the wound healing process of dental extraction. *Dent J Kedokt Gigi* 2015;9:113-22.
15. Sula B, Deveci E, Özevren H, Ekinçi C, Elbey B. Immunohistochemical and histopathological changes in the skin of rats after administration of lead acetate. *Int J Morphol* 2016;34:918-22.
16. Yamano S, Kuo WP, Sukotjo C. Downregulated gene expression

- of TGF- β s in diabetic oral wound healing. J Craniomaxillofac Surg 2013;41:e42-8.
17. Hozzein WN, Badr G, Al Ghamdi AA, Sayed A, Al-Waili NS, Garraud O. Topical application of propolis enhances cutaneous wound healing by promoting TGF-beta/Smad-mediated collagen production in a streptozotocin-induced type I diabetic mouse model. Cell Physiol Biochem 2015;37:940-54.
18. Raghav A. Crucial role of diabetes mellitus in delayed angiogenesis of wound. J Pharmacol Clin Res 2018;5:4.
19. Fakhruddin S, Alanazi W, Jackson KE. Diabetes-induced reactive oxygen species: Mechanism of their generation and role in renal injury. J Diabetes Res 2017;1-30.
20. Shah BN, Seth AK. Anti-inflammatory activity of fruits of *Abelmoschus esculantus* Linn. Pharmacol Online 2010;1:208-12.
21. Roy A, Shrivastava SL, Mandal SM. Functional properties of Okra *Abelmoschus esculentus* L. (Moench): Traditional claims and scientific evidences. Plant Sci Today 2014;1:121-30.
22. Gopalakrishnan A, Ram M, Kumawat S, Tandan S, Kumar D. Quercetin accelerated cutaneous wound healing in rats by increasing levels of VEGF and TGF- β 1 – PubMed. Indian J Exp Biol 2016;54:187-95.
23. Pang Y, Zhang Y, Huang L, Xu L, Wang K, Wang D, et al. Effects and mechanisms of total flavonoids from *Blumea balsamifera* (L.) DC. on skin wound in rats. Int J Mol Sci 2017;18:2766.
24. Liu YC, Zou XB, Chai YF, Yao YM. Macrophage polarization in inflammatory diseases. Int J Biol Sci 2014;10:520-9.
25. Durazzo A, Lucarini M, Novellino E, Souto EB, Daliu P, Santini A. *Abelmoschus esculentus* (L.): Bioactive components' beneficial properties-focused on antidiabetic role-for sustainable health applications. Molecules 2018;24:38.

Author Queries???

AQ8: Kindly provide this author signature missed in the copy right form.

AQ9: Kindly check and confirm the word.

Proofs corrections

Journal

Article title

I would like to recheck the corrections: Yes / No

If you have access to Acrobat, it may be helpful to mark the corrections in the PDF file using PENCIL and NOTE tools. Alternatively provide the list of corrections using this table. Please make the corrections' list self-explanatory and easy to understandable for a non-medical technical person.

List of corrections

Page number	Column (Left / Right)	Paragraph number from top	Line number from top of paragraph	Delete this text (Error)	Replace deleted text with (correction)
AQ8	Left	1	9	none	The following is the author's signature link that is not answered in the copyright form https://drive.google.com/file/d/1U1ARd5ETPhurJImGR4YNCom0MZImxKTd/view?usp=sharing
AQ9	Left	1	27	Dr. Muhammad Luthfi, Department of Oral Biology, Faculty of Dental Medicine, University of Airlangga, Jl. Mayjend. Prof.Dr. Moestopo 47 60 132 Surabaya, Indonesia. E-mail: m.luthfi@fkg.unair. ac.id	Dr. Muhammad Luthfi, Department of Oral Biology, Faculty of Dental Medicine, Universitas Airlangga. Mayjend. Prof.Dr. Moestopo 47 60 132 Surabaya, East Java ,Indonesia. E-mail: m.luthfi@fkg.unair. ac.id

Original Article

The efficacy of okra fruit extract on the expression of transforming growth factor beta 1 in the tooth socket of diabetic Wistar rats

Muhammad Luthfi¹, Yuliati¹, Elvina Hasna Wijayanti², Fathilah Binti Abdul Razak³, Wahyuning Ratih Irmalia⁴Departments of ¹Oral Biology and ²Undergraduate Program, Faculty of Dental Medicine, Airlangga University, ⁴Indonesian Health Collaboration and Innovation Institute, Surabaya, Indonesia, ³Department of Oral and Craniofacial Sciences. Faculty of Dentistry, University of Malaya, Kuala Lumpur, Malaysia

ABSTRACT

Background: Patients with diabetes mellitus suffer from an additional macrophage dysfunction in the secretion of growth factor, which later decreases transforming growth factor beta 1 (TGF- β 1). This condition disrupts proliferation and angiogenesis. Extract of okra fruit (*Abelmoschus esculentus*) contains flavonoid, an active substance which acts as antioxidant, anti-inflammation, and antidiabetes. The purpose of this study is to analyze the difference in TGF- β 1 expression in wound-healing process after tooth extraction of diabetic Wistar rats.

Materials and Methods: This is a laboratory experimental study using pretest and posttest on 24 Wistar rats which are divided into two groups: control group (treated with streptozotocin induction but without administration of okra fruit extract) and treatment group (treated with streptozotocin induction and oral administration of 250 mg/kg okra fruit extract once a day). Extractions of the rats' mandibular left incisors were performed using a pair of modified forceps and an elevator. The tooth sockets were then irrigated using saline solution. Four rats in each group were sacrificed on day 3 (KO1, PO1), 5 (KO2, PO2), and 7 (KO3, PO3). The socket tissues from the rats were then immunohistochemically analyzed. Data were analyzed at level significance of 0.05.

Results: The average level of TGF- β 1 expression in the treatment groups was higher compared to the control group: PO1 (11.59 ± 0.58), PO2 (15.15 ± 1.07), and PO3 (18.75 ± 2.73) as compared to KO1 (5.32 ± 1.69), KO2 (8.47 ± 0.60), and KO3 (9.28 ± 1.16) with $P = 0.001$.

Conclusion: The administration of okra fruit extract can increase the level of TGF- β 1 in wounds after tooth extraction of diabetic Wistar rats.

Key Words: Diabetes mellitus, okra fruit, transforming growth factor beta 1, wound healing, none

Received: September 2020
Accepted: April 2021

Address for correspondence:
Dr. Muhammad Lutfi,
Department of Oral Biology,
Faculty of Dental Medicine,
Universitas Airlangga.
Mayjend. Prof. Dr. Moestopo
47 60 132 Surabaya, East
Java, Indonesia.
E-mail: m.luthfi@fkg.unair.
ac.id

INTRODUCTION

Wound healing is a complex biological process involving hemostasis, inflammation, proliferation, and remodeling.^[1] On the 3rd day of wound-healing process, there is a transition from inflammatory phase

to proliferation phase, in which a transition from macrophage-1 (M1) to macrophage-2 (M2) occurs. The 5th day is the proliferation phase, in which fibroblasts are transferred to the injured area and

This is an open access journal, and articles are distributed under the terms of the Creative Commons Attribution-NonCommercial-ShareAlike 4.0 License, which allows others to remix, tweak, and build upon the work non-commercially, as long as appropriate credit is given and the new creations are licensed under the identical terms.

For reprints contact: WKHLRPMedknow_reprints@wolterskluwer.com

How to cite this article: Luthfi M, Yuliati, Wijayanti EH, Razak FB, Irmalia WR. The efficacy of okra fruit extract on the expression of transforming growth factor beta 1 in the tooth socket of diabetic Wistar rats. Dent Res J 2021;XX:XX-XX.

Access this article online



Website: www.drj.ir
www.drjjournal.net
www.ncbi.nlm.nih.gov/pmc/journals/1480

M2 plays a dominant role as an anti-inflammatory agent. On the 7th day, the angiogenesis phase reaches its peak.^[2,3] It is also known that healing process is influenced by systemic factors, one of which is comorbidities, such as diabetes mellitus (DM). DM is known to cause macrophage dysfunction in the patients.^[4]

Wound-healing process involves a series of activities of damage repair. Prolonged high-blood glucose level may cause a prolonged inflammatory process and high anti-inflammatory activity.^[5] Which results in fibroblast dysfunction occurring in the wound healing process in diabetic patients, resulting in a decrease in the expression level of the tumor growth factor beta 1 (TGF- β 1) gene.^[6] TGF- β 1 expression plays a dominant role in wound recovery among other TGF- β isoforms because TGF- β 1 functions to increase proliferation, collagen formation, and differentiation of fibroblasts in the wound proliferation phase. Besides, TGF- β 1 also plays a role in forming extracellular matrix (ECM) secretion and those related to morphological proliferation, mononuclear cell differentiation, and osteocytes. TGF- β 1 is involved in angiogenesis by increasing the regulation of vascular endothelial growth factor (VEGF). During wound closure process, TGF- β 1 increases keratinocyte transfer.^[7]

Along with the advancement of science, various treatments have been developed to overcome this problem, one of which uses herbal ingredients. Herbs are in great demand and are used by around 80% of the world's population because of the benefits in terms of safety, effectiveness, cultural acceptance, and less substantial side effects as compared to synthetic chemicals.^[8] One herb that can accelerate wound-healing process is the fruit of okra plant (*Abelmoschus esculentus*).

Okra fruit has antioxidant, anti-inflammatory,^[9] and antidiabetic^[10] qualities in the process of wound healing. The antioxidant quality of okra is needed in the process of wound healing to eliminate the effects of reactive oxygen species (ROS). Okra fruit's anti-inflammatory feature decreases the production of proinflammatory mediators, such as nitric oxide and ROS, and the production of tumor necrosis factor alpha (TNF- α) and interleukin-1 beta (IL-1 β) stimulated by lipopolysaccharide.^[9] Flavonoids found in okra fruit also play a role in lowering blood glucose level due to its isoquercetin content,

which regulates the level of blood glucose and increases immunoreactivity of pancreatic β -cells. In addition, it also has a role in wound-healing process.^[9,10] The objective of this study is to calculate the level of expression of TGF- β 1 in posttooth extraction wound-healing process in Wistar rats with DM. In addition, this study also aims to verify that administration of okra fruit extract can increase TGF- β 1 expression in posttooth extraction wound-healing process in Wistar rats with DM.

MATERIALS AND METHODS

Research design and animal model

This is a laboratory-based of analytic experimental study, with posttest-only control group design. Wistar rats used as samples in this study were obtained from the Experimental Animal Unit of the Biochemical Laboratory of the Faculty of Medicine, Universitas Airlangga. Ethical clearance of the research was issued by the Health Research Ethical Clearance Commission with a clearance certificate numbered 231/HRECC.FODM/V/2019.

Collection, adjustment, maintenance, and treatment were carried out in the Experimental Animal Unit of the Biochemical Laboratory of the Faculty of Medicine, Universitas Airlangga. Okra fruit was extracted in Materia Medica Batu. Histological preparations were carried out at the Anatomy Pathology Laboratory of the Faculty of Medicine, Universitas Airlangga. Immunohistochemistry dyeing and TGF- β 1 expression calculation were carried out at Brawijaya University, Malang.

Okra fruit extract preparation

Fresh okra fruit collected for the study was dried in a drying oven until a constant weight was reached. The dried fruit was then ground into powder. A total of 2 g of powder was extracted with 20 ml of 70% ethanol in a ratio of 1:10 (w/v) during the maceration period (24 h) at room temperature. The mixture of solvent and soaked powder was filtered through filter paper and then concentrated to 1 ml with a rotary evaporator and diluted with 5% dimethyl sulfoxide at a ratio of 1:1 (v/v). The results were then stored at a temperature of -20°C until further use.^[11]

Research procedure

In this study, 24 male Wistar rats aged 2–3 months with a weight of 150–200 g were adapted in the same cage at $25^{\circ}\text{C} \pm 2^{\circ}\text{C}$. The 24 Wistar rats were divided into two groups (control group and treatment group).

The rats were supplied with standard pellet food and distilled water *ad libitum* for 7 days and for 4 h before being induced with streptozotocin (STZ) (Nacalai Tesque Inc., Japan). The 2% STZ solution was dissolved with 0.1 mol/L citrate buffer solution with pH of 4.4 at a dose of 45 mg/kg and converted to a dose of 6.75 mg/150 g. The solution was then administered to the Wistar rats through intraperitoneal induction.^[12] Blood glucose levels were measured on day 3 after STZ induction by taking blood sample from the lateral veins in the rats' tails. Measurements were performed using a glucometer (Accu Chek® Instant). The Wistar rats were diagnosed with DM if the blood glucose levels ≥ 200 mg/dl after the STZ induction.^[13] The rats' weight during experiment was not measured.

Wistar rats with DM were then anesthetized through peritoneal injection using 0.1 ml of ketamine per rat. A resting period of 1–1.5 h was given after the injection, after which extractions of the rats' mandibular left incisors were performed using a pair of modified forceps and an elevator. The tooth sockets were then irrigated with saline solution.^[14]

In the control group, the animals did not receive administration of okra fruit extract. Instead, they were only supplied with distilled water before the observation. K_{O1} was observed on the 3rd day, K_{O2} was observed on the 5th day, and K_{O3} was observed on the 7th day. In the treatment group, the rats were given oral administration of okra fruit extract after the tooth extraction with a dose of 250 mg/kg which was converted to a dose of 37.5 mg/150 g once a day during the treatment. P_{O1} was observed on the 3rd day, P_{O2} was observed on 5th day, and P_{O3} was observed on 7th day.

Wistar rats were sacrificed on the 3rd, 5th, and 7th day using lethal injection of intraperitoneal ketamine (no < 4 times the anesthetic dose or about 0.4 ml/kg). The mandibular of each rat was taken from the temporomandibular joint. After which, the Wistar rats were buried according to the ethical treatments of experimental animals. The mandibles in the incisor area were cut vertically and treated with paraffin method.

Histopathological specimen preparation

The histological examination procedure was started by putting the tissues into formalin buffer (10% formalin solution in phosphate-buffered saline [PBS] pH 7) to be fixed and then put into paraffin wax. The

tissues were cut into slides with a length of 4–6 mm on the glass slide. After being deparaffinized with xylene, the slides were submerged in graded alcohol for dehydration and incubation with EDTA (pH = 8.0) in a microwave oven (750 W) to take TGF- β 1 antigens. Slides were incubated for 20 min in 3% H_2O_2 to inhibit endogenous peroxidase activity and then rinsed three times with PBS for 5 min each. The slides were then incubated with blocking solutions using a superbloc (Scy Tek Laboratories Inc., US) and peroxide block (Scy Tek Laboratories Inc., US). Slides were incubated overnight with TGF- β 1 antibodies (ab 27969: Abcam, Burlingame, US). After being washed in PBS, the slides were treated with UltraTek antipolyvalent biotinylated antibodies (Scy Tek Laboratories Inc., US) and UltraTek HRP (Scy Tek Laboratories Inc., US). This reaction was visualized by incubating the slides for 7 min in 0.1% 3.3 diaminobenzidine and 0.02% hydrogen peroxide solution. Slides were then counterstained with Mayer's hematoxylin (Scy Tek Laboratories Inc., US) and covered. Immunohistochemical positive staining was defined as the detection of brown chromogen from DAB Chromogen staining (Scy Tek Laboratories Inc., US) at the edge of the hematoxylin-stained nucleus distributed in the cytoplasm or plasma cell membrane and analyzed under a light microscope with $\times 1000$ at 20 visual fields. TGF- β 1 expression would be seen as positive, immunoreactive cells with a yellowish to brown color, while negative cells would correspond to the counterstain coloring agent used.^[15]

Statistical analysis

Statistical analysis was performed using SPSS (IBM SPSS Statistics for Windows, Version 24.0: IBM Corp., USA). Shapiro–Wilk test was used to find out normally distributed data. After the distribution test, Levene's homogeneity test was then performed. Once the distribution was found normal and the data were homogeneous, the analysis was continued with one-way analysis of variance (ANOVA) test and with multiple comparison test using Tukey honestly significant difference (HSD) test.

RESULTS

Based on the laboratory experiment using 24 Wistar rats which were divided into control (K_O) and treatment (P_O) groups, the researchers have observed the wounds from the extraction of the left maxillary incisors on day 3,

5, and 7 to measure the number of TGF- β 1 expression in the wound-healing process after tooth extraction of Wistar rats with DM. The blood glucose level of all rats was above 200 mg/dl after the induction. TGF- β 1 examination was carried out under a light microscope with $\times 1000$ at 20 visual fields [Figure 1].

We observed the expression of TGF- β 1 both with and without okra fruit extract administration. The ANOVA test showed a significant difference among the groups [Table 1]. Meanwhile, the multiple comparison test result using Tukey HSD showed a significant increase of TGF- β 1 expression observed on day 3, 5, and 7 in the control group. Likewise, the treatment group also exhibited the same results for day 3, 5, and 7 [Table 2].

TGF- β 1 expressions on days 3, 5, and 7 on the prepared Wistar rats' socket tissues with DM were calculated using a light microscope with $\times 400$ at four visual fields [Figure 1]. TGF- β 1 expression appears as gradients of yellow to brown stains pointed with arrows. Based on Figure 2, it can be seen that on the 3rd day, P_{O1} group showed increasing number of TGF- β 1 expression as compared to K_{O1} group. On the 5th day, P_{O2} showed increasing number of TGF- β 1 expression as compared to K_{O2} group. On the 7th day, P_{O3} showed increasing number of TGF- β 1 expression as compared to K_{O3} group.

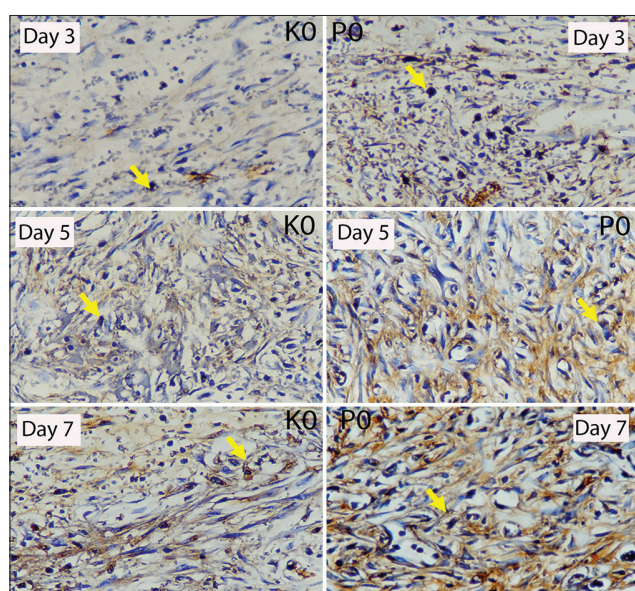


Figure 1: Expression of transforming growth factor beta 1 in day 3, 5, and 7 in socket tissues of Wistar rats with diabetes mellitus in immunohistochemistry examination in microscope with $\times 400$ in control group (K_O) and treatment group (P_O).

DISCUSSION

This research aims to prove that okra fruit extract can increase the expression of TGF- β 1 in wound-healing process after tooth extraction in Wistar rats with DM. The observations of TGF- β 1 expression were carried out on day 3, 5, and 7. Since the 3rd day of the wound-healing process, a transition from inflammatory phase to proliferation phase has taken place. During the same phase, M1 goes under transition to become M2. However, the number of M1 is still above M2. However, on the 5th day, M2 plays a more dominant role than M1 on the wounds. Proliferation phase also takes place during this time in which fibroblasts migrate to the wound area.^[3] Then, the peak of the angiogenesis phase starts on the 7th day.^[6] M2 acts as

Table 1: Mean, standard deviation, and normality test of transforming growth factor beta 1 expression (macrophage cells count) in the control and treatment group

Group	Mean \pm SD	P
KO1	5.32 \pm 1.69	0.001
KO2	8.47 \pm 0.60	
KO3	9.28 \pm 1.16	
PO1	11.59 \pm 0.58	
PO2	15.15 \pm 1.07	
PO3	18.75 \pm 2.73	

SD: Standard deviation

Table 2: Tukey's multiple comparison test in the control and treatment groups

Group	KO1	KO2	KO3
KO1		0.030*	0.009*
KO2	0.030*		0.710
Group	PO1	PO2	PO3
PO1		0.041*	0.001*
PO2	0.041*		0.039*

*There is a significant difference

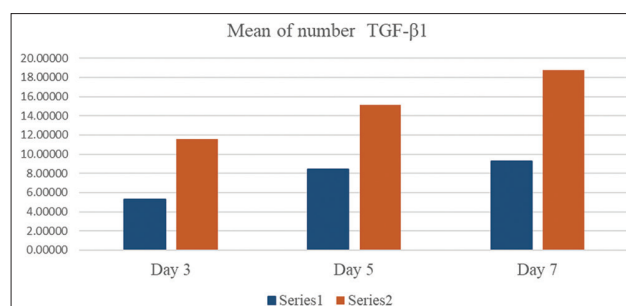


Figure 2: Mean value graph of transforming growth factor beta 1 expression on day 3, 5, and 7.

an anti-inflammatory in which macrophages release IL-10 and TGF- β , a very strong anti-inflammatory agent that immediately stops the inflammatory process and starts the proliferation phase.^[4] This is the reason why we as researchers observed TGF- β 1 expression as one of the important growth factors in wound-healing process.

The results of our research confirm the hypothesis that the administration of okra fruit extract can increase TGF- β 1 expression in the wound-healing process after tooth extraction of Wistar rats with DM. Observations were done by calculating the amount of TGF- β 1 expression in both groups, namely the control group (K) and the treatment group (P). In group K, the TGF- β 1 expression from Wistar tooth socket is less than in group P. However, in both K and P groups, we found the highest number of TGF- β 1 expression on the 7th day, as compared to on the 3rd and 5th day. This is due to the fact that the healing process that involves fibroblasts cell infiltration to the wound occurs the most on the 7th day; thus, the number of TGF- β 1 expression is higher than the 3rd and 5th day.^[3,4]

The mean number of TGF- β 1 expression in the K group shows lower results than the P group due to the STZ induction. A few days after the STZ induction, damage occurs in pancreatic beta-cells which results in insulin resistance and high-blood glucose level. In addition, the increased oxidative stress due to the formation of Advanced Glycation end products (AGEs) causes disruption of the fibroblast's proliferation, migration, and dysfunction.^[6]

Yamano *et al.* state that at the beginning of tooth extraction, the lowest amount of TGF- β 1 expression is obtained compared to the following day.^[16] In addition, a study by Hozzein *et al.* also infers that the administration of intraperitoneal STZ can cause a significant decrease in the regulation of TGF- β 1 in wound tissue.^[17]

In DM patients, an uncontrolled glycemic control causes a disruption in wound-healing process, which is a disturbance in the angiogenesis activity that causes pathogenesis mechanism.^[18] In group K, TGF- β 1 expression increased significantly on day 3–5, while on days 5–7, the expression of TGF- β 1 also increased, though not as significant. This is due to the fact that DM condition disrupts the innate role and function of immunity cells. High glucose level increases the cellular nuclear factor- κ B (NF- κ B) activation. If an injury

occurs, the prolonged inflammatory phase results in a proinflammatory response that increases the occurrence of chronic inflammation and tissue damage.^[6]

High-blood glucose level induces ROS which can be produced both enzymatically and nonenzymatically. Enzymatic production includes nicotinamide adenine dinucleotide phosphate oxidase (oxidase), nitric oxide synthase, cytochrome P-450, cyclooxygenase, lipoxygenase, xanthine oxidase, and myeloperoxidase^[19] and results in high proinflammatory cytokines which are released by neutrophils and macrophages as well as an increase in abnormal protease activity, resulting in disruption of growth factor signaling in the wound-healing process. This signaling disruption causes a decrease in growth factor and disrupts in the angiogenesis phase.^[13]

On the other hand, the P group had higher average TGF- β 1 as compared to K group due to the difference in okra fruit extract administration.^[20] Thus, it confirms the hypothesis that okra fruit extract can increase TGF- β 1 expression. Okra extract has antioxidant, anti-inflammatory, and antidiabetic qualities in wound-healing process.^[8,10] Okra extract contains polyphenols, flavonoids, isoquercetin, and quercetin-3-O-gentiobiose. Flavonoid is useful to repair damaged cells and forms a normal wound-healing process by inducing fibroplasia by TGF- β 1.^[21] Quercetin plays a role in regulating TGF- β 1 expression and decreasing the number of inflammatory cells. Quercetin also decreases the number of TNF- α while increasing fibroblasts proliferation and micro blood vessel density, leading to better reepithelialization and regular collagen deposition.^[22] Pang *et al.* state that low-dose flavonoid alone is able to stimulate TGF- β 1 expression which in turn increases TGF- β expression by macrophage stimulation induced by total flavonoids in wounds.^[23] TGF- β 1, secreted by M2 phenotype macrophages, plays a role in inhibiting the recruitment of inflammatory cells.^[24] TGF- β induces the keratinocyte and fibroblasts proliferation, causing the new capillaries formation in the granulation tissue and modulation of ECM deposition resulting in wound healing. TGF- β 1 also plays a role in angiogenesis by increasing the regulation of VEGF. During wound closure, TGF- β 1 increases keratinocyte migration.^[17]

In addition to reducing proinflammatory mediator production, okra fruit plays a role in reducing nitric oxide amount and ROS, as well as in reducing

the production of TNF- α .^[20] Excessive production of ROS causes activation of the NF- κ B signaling pathway. NF- κ B is a protein that stimulates cytokines and free radicals. It is also a transcription factor that regulates large numbers of genes involved in various immune and inflammatory response processes and causes vascular complications in DM patients and in inflammatory pathogenic processes that can be inhibited by flavonoids.^[21]

Flavonoid contained in okra fruit can reduce blood glucose level,^[10] resulting in a decrease in proinflammatory cytokines.^[20] High concentration of fiber and polysaccharides in the okra fruit can stabilize blood glucose by limiting the rate of absorption of sugar in the intestine.^[25] This complements the flavonoid content of the okra fruit which functions as an inhibitor of α -amylase and α -glucosidase, the enzymes found in the small intestine^[21] which act as carbohydrate catalyst by catalyzing oligosaccharides so that glucose absorption may take place. Inhibition of α -glucosidase can cause catalysis of complex carbohydrate diets such as oligosaccharides and polysaccharides to be inhibited by monosaccharides, resulting in decreased blood glucose level.^[10,12]

Glycoprotein-A repetitions predominant protein (GARP) is an important regulator in activating latent TGF- β (LTGF- β) and then binding it to LTGF- β . GARP acts as a docking receptor that functions as a carrier of LTGF- β on the cell surface, activating its role.^[7] GARP also plays a role in the regulation of T lymphocytes (Tregs) that form complexes with the α V β 8 integrin to release active TGF- β from the cell surface.^[17] TGF- β 1 stimulates fibroblasts to differentiate into myofibroblasts and then collaborates with these myofibroblasts to produce ECM, as well as collagen and matrix proteins, namely fibronectin.^[5] TGF- β 1 together with VEGF and fibroblasts stimulate the angiogenesis process.^[17] This explains the higher expression of TGF- β 1 in P group as compared to K group. Therefore, it can accelerate wound-healing process in the P group.

CONCLUSION

The administration of okra fruit extract can increase the number of TGF- β 1 in tooth extraction wounds on Wistar rats with DM.

Financial support and sponsorship
Nil.

Conflicts of interest

The authors of this manuscript declare that they have no conflicts of interest, real or perceived, financial or nonfinancial in this article.

REFERENCES

1. Reinke JM, Sorg H. Wound repair and regeneration. *Eur Surg Res* 2012;49:35-43.
2. Benadiba M, Serruya R, Maor Y. Bioaccessibility of Shore Magic® collagen, a low-molecular-weight collagen supplement, in different *in vitro* barrier models. *Heliyon* 2018;4:e00821.
3. Du Y, Ren P, Wang Q, Jiang SK, Zhang M, Li JY, et al. Cannabinoid 2 receptor attenuates inflammation during skin wound healing by inhibiting M1 macrophages rather than activating M2 macrophages. *J Inflamm (Lond)* 2018;15:25.
4. Anderson K, Hamm RL. Factors that impair wound healing. *J Am Coll Clin Wound Spec* 2012;4:84-91.
5. Zhao R, Liang H, Clarke E, Jackson C, Xue M. Inflammation in chronic wounds. *Int J Mol Sci* 2016;17:2085.
6. Kido D, Mizutani K, Takeda K, Mikami R, Matsuura T, Iwasaki K, et al. Impact of diabetes on gingival wound healing via oxidative stress. *PLoS One* 2017;12:e0189601.
7. Liu Y, Li Y, Li N, Teng W, Wang M, Zhang Y, et al. TGF- β 1 promotes scar fibroblasts proliferation and transdifferentiation via up-regulating MicroRNA-21. *Sci Rep* 2016;6:1-9.
8. Bhowmik D, Sampath Kumar KP, Tripathi P. Traditional herbal medicines: An overview. *Arch Appl Sci Res* 2009;1:165-77.
9. Solomon S. Anti-oxidant and anti-inflammatory activity of *Abelmoschus esculentus* (Flowers). *Indo Am J Pharm Sci* 2016:600-5.
10. Abbas AY, Muhammad I, AbdulRahman MB, Bilbis LS, Saidu Y, Onu A. Possible antidiabetic mechanism of action of ex-maradi okra fruit variety (*Abelmoschus esculentus*) on alloxan induced diabetic rats. *Niger J Basic Appl Sci* 2018;25:101.
11. Yeo YL, Chia YY, Lee CH, Sow HS, Yap WS. Effectiveness of maceration periods with different extraction solvents on *in-vitro* antimicrobial activity from fruit of *Momordica charantia* L. *J Appl Pharm Sci* 2014;4:16-23.
12. Tian ZH, Miao FT, Zhang X, Wang QH, Lei N, Guo LC. Therapeutic effect of okra extract on gestational diabetes mellitus rats induced by streptozotocin. *Asian Pac J Trop Med* 2015;8:1038-42.
13. Qinna NA, Badwan AA. Impact of streptozotocin on altering normal glucose homeostasis during insulin testing in diabetic rats compared to normoglycemic rats. *Drug Des Devel Ther* 2015;9:2515-25.
14. Gunawan F, Sularsih S, Soemartono S. The differences effect between low and high molecular weight chitosan on number of lymphocyte cells in the wound healing process of dental extraction. *Dent J Kedokt Gigi* 2015;9:113-22.
15. Sula B, Deveci E, Özevren H, Ekinçi C, Elbey B. Immunohistochemical and histopathological changes in the skin of rats after administration of lead acetate. *Int J Morphol* 2016;34:918-22.
16. Yamano S, Kuo WP, Sukotjo C. Downregulated gene expression

- of TGF- β s in diabetic oral wound healing. *J Craniomaxillofac Surg* 2013;41:e42-8.
17. Hozzein WN, Badr G, Al Ghamdi AA, Sayed A, Al-Waili NS, Garraud O. Topical application of propolis enhances cutaneous wound healing by promoting TGF-beta/Smad-mediated collagen production in a streptozotocin-induced type I diabetic mouse model. *Cell Physiol Biochem* 2015;37:940-54.
18. Raghav A. Crucial role of diabetes mellitus in delayed angiogenesis of wound. *J Pharmacol Clin Res* 2018;5:4.
19. Fakhruddin S, Alanazi W, Jackson KE. Diabetes-induced reactive oxygen species: Mechanism of their generation and role in renal injury. *J Diabetes Res* 2017;1-30.
20. Shah BN, Seth AK. Anti-inflammatory activity of fruits of *Abelmoschus esculantus* Linn. *Pharmacol Online* 2010;1:208-12.
21. Roy A, Shrivastava SL, Mandal SM. Functional properties of Okra *Abelmoschus esculentus* L. (Moench): Traditional claims and scientific evidences. *Plant Sci Today* 2014;1:121-30.
22. Gopalakrishnan A, Ram M, Kumawat S, Tandan S, Kumar D. Quercetin accelerated cutaneous wound healing in rats by increasing levels of VEGF and TGF- β 1 – PubMed. *Indian J Exp Biol* 2016;54:187-95.
23. Pang Y, Zhang Y, Huang L, Xu L, Wang K, Wang D, et al. Effects and mechanisms of total flavonoids from *Blumea balsamifera* (L.) DC. on skin wound in rats. *Int J Mol Sci* 2017;18:2766.
24. Liu YC, Zou XB, Chai YF, Yao YM. Macrophage polarization in inflammatory diseases. *Int J Biol Sci* 2014;10:520-9.
25. Durazzo A, Lucarini M, Novellino E, Souto EB, Daliu P, Santini A. *Abelmoschus esculentus* (L.): Bioactive components' beneficial properties-focused on antidiabetic role-for sustainable health applications. *Molecules* 2018;24:38.

- Home ▶
- Submission ▶
- Downloads ▶
- Symposia ▶
- Submitted manuscript(s) ▶
- Accepted manuscripts ▶
- Personal details ▶
- About us ▶
- Reach us ▶
- Help ▶

Article details...	
Title	The Efficacy of Okra Fruit Extract on The Expression of TGF- β 1 in The Tooth Socket of Diabetic Wistar Rats
Type	Original Article
Submission Date	07-Sep-20 11:16
Abstract	Click here to view Abstract
Subjects	Dentistr - Click here to update
Author profiles	[View author profiles]
Price	Payment for: Article processing charge for DRJ_1008_20 Amt paid: US \$ 700 [Online Payment received...]

Your article files...																																	
First Page File(s)	DRJ_1008_20FP.docx DRJ_1008_20FPR1.docx DRJ_1008_20FPR1.pdf																																
Article File(s)	<table border="1"> <tbody> <tr> <td>1</td><td>DRJ_1008_20.docx</td> <td>2</td><td>DRJ_1008_20R1.docx</td> <td>3</td><td>DRJ_1008_20R3.docx</td> <td>4</td><td>DRJ_1008_20R4.docx</td> </tr> <tr> <td>5</td><td>DRJ_1008_20R5.docx</td> <td>6</td><td>DRJ_1008_20R6.docx</td> <td>7</td><td>DRJ_1008_20R7.doc</td> <td>8</td><td>DRJ_1008_20R8.doc</td> </tr> <tr> <td>9</td><td>DRJ_1008_20R9.doc</td> <td>10</td><td>DRJ_1008_20R10.doc</td> <td>11</td><td>DRJ_1008_20R11.pdf</td> <td>12</td><td>DRJ_1008_20R12.doc</td> </tr> <tr> <td>13</td><td>DRJ_1008_20R13.pdf</td> <td>14</td><td>DRJ_1008_20R14.doc</td> <td>15</td><td>DRJ_1008_20R15.pdf</td> <td></td><td></td> </tr> </tbody> </table>	1	DRJ_1008_20.docx	2	DRJ_1008_20R1.docx	3	DRJ_1008_20R3.docx	4	DRJ_1008_20R4.docx	5	DRJ_1008_20R5.docx	6	DRJ_1008_20R6.docx	7	DRJ_1008_20R7.doc	8	DRJ_1008_20R8.doc	9	DRJ_1008_20R9.doc	10	DRJ_1008_20R10.doc	11	DRJ_1008_20R11.pdf	12	DRJ_1008_20R12.doc	13	DRJ_1008_20R13.pdf	14	DRJ_1008_20R14.doc	15	DRJ_1008_20R15.pdf		
1	DRJ_1008_20.docx	2	DRJ_1008_20R1.docx	3	DRJ_1008_20R3.docx	4	DRJ_1008_20R4.docx																										
5	DRJ_1008_20R5.docx	6	DRJ_1008_20R6.docx	7	DRJ_1008_20R7.doc	8	DRJ_1008_20R8.doc																										
9	DRJ_1008_20R9.doc	10	DRJ_1008_20R10.doc	11	DRJ_1008_20R11.pdf	12	DRJ_1008_20R12.doc																										
13	DRJ_1008_20R13.pdf	14	DRJ_1008_20R14.doc	15	DRJ_1008_20R15.pdf																												
	Additional comments / edits by reviewer / editor																																
	<table border="1"> <tbody> <tr> <td>1</td> <td>DRJ_1008_20R2_ref.docx</td> </tr> </tbody> </table>	1	DRJ_1008_20R2_ref.docx																														
1	DRJ_1008_20R2_ref.docx																																
Images	View Images																																
Forms	No Forms Uploaded																																
CheckList	View CheckList																																

Article related...	
Search PubMed	View copyright form
Search in Medknow	Copyright form received Images Received
This article is assigned to November:2021 issue.	

Progress of review process...				
	Status	Comments	Phase entry date	Days in review
1	Editorial Review	-	07/Sep/20 11:16	--
3	Editorial review	-	10/Sep/20 04:36	3 [3]
5	Technical Modification	Remark	10/Sep/20 07:16	3 [0]
7	Editorial Review	-	12/Sep/20 05:06	5 [2]
9	Peer Review	-	18/Sep/20 15:58	11 [6]
	--do--	-	19/Sep/20 05:51	12 [1]
	--do--	-	02/Oct/20 07:45	25 [14]
	--do--	-	03/Oct/20 09:53	26 [15]
	--do--	-	20/Oct/20 12:48	43 [32]
11	Under revision	Remark	28/Oct/20 07:43	51 [8]
13	Editorial Review	-	20/Nov/20 23:23	74 [23]
15	Re-revision	Remark	25/Nov/20 08:15	79 [5]
17	Editorial Review	-	05/Dec/20 21:00	89 [10]
19	Re-revision	Remark	29/Jan/21 19:33	144 [55]
21	Editorial Review	-	13/Feb/21 10:46	159 [15]
23	Re-revision	Remark	03/Mar/21 07:53	177 [18]
25	Editorial Review	-	14/Mar/21 11:18	188 [11]
27	Editorial review	-	15/Mar/21 07:56	189 [1]
	--do--	-	17/Mar/21 05:57	191 [2]
30	Re-revision	Remark	18/Mar/21 20:37	192 [1]
32	Editorial Review	-	28/Mar/21 01:21	202 [10]
34	Editorial review	-	31/Mar/21 12:49	205 [3]
36	Manuscript charges	-	03/Apr/21 07:19	208 [3]
	--do--	-	03/Apr/21 07:23	208 [0]
	--do--	-	03/Apr/21 07:31	208 [0]
38	Technical check	-	14/Apr/21 08:23	219 [11]
	--do--	-	14/Apr/21 09:56	219 [0]
41	Revision	-	20/Apr/21 17:02	225 [6]
43	Pre-Acceptance proof	-	25/Apr/21 19:17	230 [5]
45	Accepted	-	03/May/21 05:15	238 [8]
47	Under issue preparation	-	13/May/21 09:54	248 [10]
	--do--	-	27/May/21 16:21	262 [14]
50	For proof check	-	28/May/21 05:26	263 [1]
52	Under preparation for issue	-	02/Jun/21 13:31	268 [5]
	--do--	-	03/Jun/21 06:20	269 [1]
	--do--	-	03/Jun/21 13:22	269 [0]
56	For proof check	-	25/Jun/21 12:05	291 [22]
58	Under preparation for issue	-	12/Jul/21 15:39	308 [17]
	--do--	-	13/Jul/21 06:53	309 [1]
	--do--	-	14/Jul/21 07:30	310 [1]
	--do--	-	03/Aug/21 08:39	330 [20]
63	Article published	-	22/Nov/21 07:54	441 [111]
	--do--	-	26/Nov/21 11:29	445 [4]

Original Article

The efficacy of okra fruit extract on the expression of transforming growth factor beta I in the tooth socket of diabetic Wistar rats

Muhammad Luthfi¹, Yuliati¹, Elvina Hasna Wijayanti², Fathilah Binti Abdul Razak³, Wahyuning Ratih Irmalia⁴

Departments of ¹Oral Biology and ²Undergraduate Program, Faculty of Dental Medicine, Airlangga University, ⁴Indonesian Health Collaboration and Innovation Institute, Surabaya, Indonesia, ³Department of Oral and Craniofacial Sciences. Faculty of Dentistry, University of Malaya, Kuala Lumpur, Malaysia

ABSTRACT

Background: Patients with diabetes mellitus suffer from an additional macrophage dysfunction in the secretion of growth factor, which later decreases transforming growth factor beta I (TGF- β 1). This condition disrupts proliferation and angiogenesis. Extract of okra fruit (*Abelmoschus esculentus*) contains flavonoid, an active substance which acts as antioxidant, anti-inflammation, and antidiabetes. The purpose of this study is to analyze the difference in TGF- β 1 expression in wound-healing process after tooth extraction of diabetic Wistar rats.

Materials and Methods: This is a laboratory experimental study using pretest and posttest on 24 Wistar rats which are divided into two groups: control group (treated with streptozotocin induction but without administration of okra fruit extract) and treatment group (treated with streptozotocin induction and oral administration of 250 mg/kg okra fruit extract once a day). Extractions of the rats' mandibular left incisors were performed using a pair of modified forceps and an elevator. The tooth sockets were then irrigated using saline solution. Four rats in each group were sacrificed on day 3 (KO1, PO1), 5 (KO2, PO2), and 7 (KO3, PO3). The socket tissues from the rats were then immunohistochemically analyzed. Data were analyzed at level significance of 0.05.

Results: The average level of TGF- β 1 expression in the treatment groups was higher compared to the control group: PO1 (11.59 ± 0.58), PO2 (15.15 ± 1.07), and PO3 (18.75 ± 2.73) as compared to KO1 (5.32 ± 1.69), KO2 (8.47 ± 0.60), and KO3 (9.28 ± 1.16) with $P = 0.001$.

Conclusion: The administration of okra fruit extract can increase the level of TGF- β 1 in wounds after tooth extraction of diabetic Wistar rats.

Key Words: Diabetes mellitus, okra fruit, transforming growth factor beta I, wound healing, none

Received: 07-Sep-2020
Revised: 18-Mar-2021
Accepted: 03-May-2021
Published: 22-Nov-2021

Address for correspondence:
Dr. Muhammad Luthfi,
Department of Oral Biology,
Faculty of Dental Medicine,
Universitas Airlangga.
Mayjend. Prof. Dr. Moestopo
47 60 132 Surabaya, East
Java, Indonesia.
E-mail: m.luthfi@fkg.unair.ac.id

INTRODUCTION

Wound healing is a complex biological process involving hemostasis, inflammation, proliferation, and remodeling.^[1] On the 3rd day of wound-healing process, there is a transition from inflammatory phase

to proliferation phase, in which a transition from macrophage-1 (M1) to macrophage-2 (M2) occurs. The 5th day is the proliferation phase, in which fibroblasts are transferred to the injured area and

This is an open access journal, and articles are distributed under the terms of the Creative Commons Attribution-NonCommercial-ShareAlike 4.0 License, which allows others to remix, tweak, and build upon the work non-commercially, as long as appropriate credit is given and the new creations are licensed under the identical terms.

For reprints contact: WKHLRPMedknow_reprints@wolterskluwer.com

How to cite this article: Luthfi M, Yuliati, Wijayanti EH, Razak FB, Irmalia WR. The efficacy of okra fruit extract on the expression of transforming growth factor beta I in the tooth socket of diabetic Wistar rats. *Dent Res J* 2021;18:91.

Access this article online



Website: www.drj.ir
www.drjournal.net
www.ncbi.nlm.nih.gov/pmc/journals/1480

M2 plays a dominant role as an anti-inflammatory agent. On the 7th day, the angiogenesis phase reaches its peak.^[2,3] It is also known that healing process is influenced by systemic factors, one of which is comorbidities, such as diabetes mellitus (DM). DM is known to cause macrophage dysfunction in the patients.^[4]

Wound-healing process involves a series of activities of damage repair. Prolonged high-blood glucose level may cause a prolonged inflammatory process and high anti-inflammatory activity.^[5] Which results in fibroblast dysfunction occurring in the wound healing process in diabetic patients, resulting in a decrease in the expression level of the tumor growth factor beta 1 (TGF- β 1) gene.^[6] TGF- β 1 expression plays a dominant role in wound recovery among other TGF- β isoforms because TGF- β 1 functions to increase proliferation, collagen formation, and differentiation of fibroblasts in the wound proliferation phase. Besides, TGF- β 1 also plays a role in forming extracellular matrix (ECM) secretion and those related to morphological proliferation, mononuclear cell differentiation, and osteocytes. TGF- β 1 is involved in angiogenesis by increasing the regulation of vascular endothelial growth factor (VEGF). During wound closure process, TGF- β 1 increases keratinocyte transfer.^[7]

Along with the advancement of science, various treatments have been developed to overcome this problem, one of which uses herbal ingredients. Herbs are in great demand and are used by around 80% of the world's population because of the benefits in terms of safety, effectiveness, cultural acceptance, and less substantial side effects as compared to synthetic chemicals.^[8] One herb that can accelerate wound-healing process is the fruit of okra plant (*Abelmoschus esculentus*).

Okra fruit has antioxidant, anti-inflammatory,^[9] and antidiabetic^[10] qualities in the process of wound healing. The antioxidant quality of okra is needed in the process of wound healing to eliminate the effects of reactive oxygen species (ROS). Okra fruit's anti-inflammatory feature decreases the production of proinflammatory mediators, such as nitric oxide and ROS, and the production of tumor necrosis factor alpha (TNF- α) and interleukin-1 beta (IL-1 β) stimulated by lipopolysaccharide.^[9] Flavonoids found in okra fruit also play a role in lowering blood glucose level due to its isoquercetin content,

which regulates the level of blood glucose and increases immunoreactivity of pancreatic β -cells. In addition, it also has a role in wound-healing process.^[9,10] The objective of this study is to calculate the level of expression of TGF- β 1 in posttooth extraction wound-healing process in Wistar rats with DM. In addition, this study also aims to verify that administration of okra fruit extract can increase TGF- β 1 expression in posttooth extraction wound-healing process in Wistar rats with DM.

MATERIALS AND METHODS

Research design and animal model

This is a laboratory-based of analytic experimental study, with posttest-only control group design. Wistar rats used as samples in this study were obtained from the Experimental Animal Unit of the Biochemical Laboratory of the Faculty of Medicine, Universitas Airlangga. Ethical clearance of the research was issued by the Health Research Ethical Clearance Commission with a clearance certificate numbered 231/HRECC.FODM/V/2019.

Collection, adjustment, maintenance, and treatment were carried out in the Experimental Animal Unit of the Biochemical Laboratory of the Faculty of Medicine, Universitas Airlangga. Okra fruit was extracted in Materia Medica Batu. Histological preparations were carried out at the Anatomy Pathology Laboratory of the Faculty of Medicine, Universitas Airlangga. Immunohistochemistry dyeing and TGF- β 1 expression calculation were carried out at Brawijaya University, Malang.

Okra fruit extract preparation

Fresh okra fruit collected for the study was dried in a drying oven until a constant weight was reached. The dried fruit was then ground into powder. A total of 2 g of powder was extracted with 20 ml of 70% ethanol in a ratio of 1:10 (w/v) during the maceration period (24 h) at room temperature. The mixture of solvent and soaked powder was filtered through filter paper and then concentrated to 1 ml with a rotary evaporator and diluted with 5% dimethyl sulfoxide at a ratio of 1:1 (v/v). The results were then stored at a temperature of -20°C until further use.^[11]

Research procedure

In this study, 24 male Wistar rats aged 2–3 months with a weight of 150–200 g were adapted in the same cage at $25^{\circ}\text{C} \pm 2^{\circ}\text{C}$. The 24 Wistar rats were divided into two groups (control group and treatment group).

The rats were supplied with standard pellet food and distilled water *ad libitum* for 7 days and for 4 h before being induced with streptozotocin (STZ) (Nacalai Tesque Inc., Japan). The 2% STZ solution was dissolved with 0.1 mol/L citrate buffer solution with pH of 4.4 at a dose of 45 mg/kg and converted to a dose of 6.75 mg/150 g. The solution was then administered to the Wistar rats through intraperitoneal induction.^[12] Blood glucose levels were measured on day 3 after STZ induction by taking blood sample from the lateral veins in the rats' tails. Measurements were performed using a glucometer (Accu Chek® Instant). The Wistar rats were diagnosed with DM if the blood glucose levels ≥ 200 mg/dl after the STZ induction.^[13] The rats' weight during experiment was not measured.

Wistar rats with DM were then anesthetized through peritoneal injection using 0.1 ml of ketamine per rat. A resting period of 1–1.5 h was given after the injection, after which extractions of the rats' mandibular left incisors were performed using a pair of modified forceps and an elevator. The tooth sockets were then irrigated with saline solution.^[14]

In the control group, the animals did not receive administration of okra fruit extract. Instead, they were only supplied with distilled water before the observation. K_{O1} was observed on the 3rd day, K_{O2} was observed on the 5th day, and K_{O3} was observed on the 7th day. In the treatment group, the rats were given oral administration of okra fruit extract after the tooth extraction with a dose of 250 mg/kg which was converted to a dose of 37.5 mg/150 g once a day during the treatment. P_{O1} was observed on the 3rd day, P_{O2} was observed on 5th day, and P_{O3} was observed on 7th day.

Wistar rats were sacrificed on the 3rd, 5th, and 7th day using lethal injection of intraperitoneal ketamine (no <4 times the anesthetic dose or about 0.4 ml/kg). The mandibular of each rat was taken from the temporomandibular joint. After which, the Wistar rats were buried according to the ethical treatments of experimental animals. The mandibles in the incisor area were cut vertically and treated with paraffin method.

Histopathological specimen preparation

The histological examination procedure was started by putting the tissues into formalin buffer (10% formalin solution in phosphate-buffered saline [PBS] pH 7) to be fixed and then put into paraffin wax. The

tissues were cut into slides with a length of 4–6 mm on the glass slide. After being deparaffinized with xylene, the slides were submerged in graded alcohol for dehydration and incubation with EDTA (pH = 8.0) in a microwave oven (750 W) to take TGF- β 1 antigens. Slides were incubated for 20 min in 3% H_2O_2 to inhibit endogenous peroxidase activity and then rinsed three times with PBS for 5 min each. The slides were then incubated with blocking solutions using a superbloc (Scy Tek Laboratories Inc., US) and peroxide block (Scy Tek Laboratories Inc., US). Slides were incubated overnight with TGF- β 1 antibodies (ab 27969: Abcam, Burlingame, US). After being washed in PBS, the slides were treated with UltraTek antipolyvalent biotinylated antibodies (Scy Tech Laboratories Inc., US) and UltraTek HRP (Scy Tek Laboratories Inc., US). This reaction was visualized by incubating the slides for 7 min in 0.1% 3.3 diaminobenzidine and 0.02% hydrogen peroxide solution. Slides were then counterstained with Mayer's hematoxylin (Scy Tech Laboratories Inc., US) and covered. Immunohistochemical positive staining was defined as the detection of brown chromogen from DAB Chromogen staining (Scy Tech Laboratories Inc., US) at the edge of the hematoxylin-stained nucleus distributed in the cytoplasm or plasma cell membrane and analyzed under a light microscope with $\times 1000$ at 20 visual fields. TGF- β 1 expression would be seen as positive, immunoreactive cells with a yellowish to brown color, while negative cells would correspond to the counterstain coloring agent used.^[15]

Statistical analysis

Statistical analysis was performed using SPSS (IBM SPSS Statistics for Windows, Version 24.0: IBM Corp., USA). Shapiro–Wilk test was used to find out normally distributed data. After the distribution test, Levene's homogeneity test was then performed. Once the distribution was found normal and the data were homogeneous, the analysis was continued with one-way analysis of variance (ANOVA) test and with multiple comparison test using Tukey honestly significant difference (HSD) test.

RESULTS

Based on the laboratory experiment using 24 Wistar rats which were divided into control (K_O) and treatment (P_O) groups, the researchers have observed the wounds from the extraction of the left maxillary incisors on day 3,

5, and 7 to measure the number of TGF-β1 expression in the wound-healing process after tooth extraction of Wistar rats with DM. The blood glucose level of all rats was above 200 mg/dl after the induction. TGF-β1 examination was carried out under a light microscope with ×1000 at 20 visual fields [Figure 1].

We observed the expression of TGF-β1 both with and without okra fruit extract administration. The ANOVA test showed a significant difference among the groups [Table 1]. Meanwhile, the multiple comparison test result using Tukey HSD showed a significant increase of TGF-β1 expression observed on day 3, 5, and 7 in the control group. Likewise, the treatment group also exhibited the same results for day 3, 5, and 7 [Table 2].

TGF-β1 expressions on days 3, 5, and 7 on the prepared Wistar rats' socket tissues with DM were calculated using a light microscope with ×400 at four visual fields [Figure 1]. TGF-β1 expression appears as gradients of yellow to brown stains pointed with arrows. Based on Figure 2, it can be seen that on the 3rd day, P₀₁ group showed increasing number of TGF-β1 expression as compared to K₀₁ group. On the 5th day, P₀₂ showed increasing number of TGF-β1 expression as compared to K₀₂ group. On the 7th day, P₀₃ showed increasing number of TGF-β1 expression as compared to K₀₃ group.

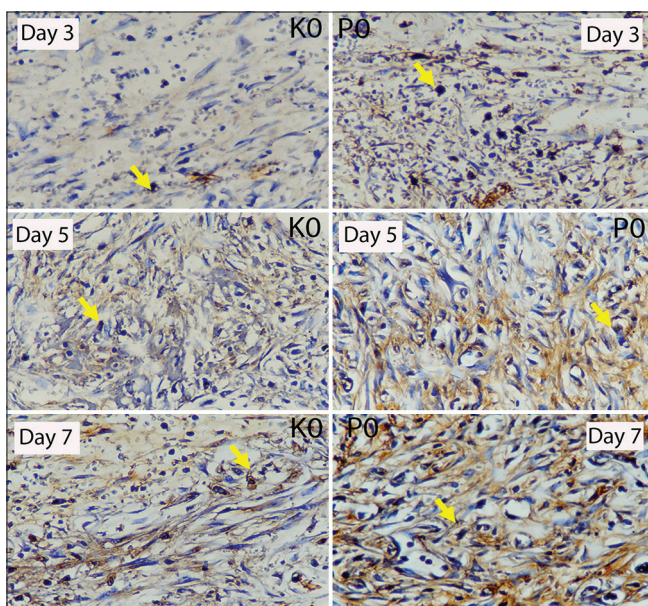


Figure 1: Expression of transforming growth factor beta 1 in day 3, 5, and 7 in socket tissues of Wistar rats with diabetes mellitus in immunohistochemistry examination in microscope with ×400 in control group (K₀) and treatment group (P₀).

DISCUSSION

This research aims to prove that okra fruit extract can increase the expression of TGF-β1 in wound-healing process after tooth extraction in Wistar rats with DM. The observations of TGF-β1 expression were carried out on day 3, 5, and 7. Since the 3rd day of the wound-healing process, a transition from inflammatory phase to proliferation phase has taken place. During the same phase, M1 goes under transition to become M2. However, the number of M1 is still above M2. However, on the 5th day, M2 plays a more dominant role than M1 on the wounds. Proliferation phase also takes place during this time in which fibroblasts migrate to the wound area.^[3] Then, the peak of the angiogenesis phase starts on the 7th day.^[6] M2 acts as

Table 1: Mean, standard deviation, and normality test of transforming growth factor beta 1 expression (macrophage cells count) in the control and treatment group

Group	Mean±SD	P
KO1	5.32±1.69	0.001
KO2	8.47±0.60	
KO3	9.28±1.16	
PO1	11.59±0.58	
PO2	15.15±1.07	
PO3	18.75±2.73	

SD: Standard deviation

Table 2: Tukey's multiple comparison test in the control and treatment groups

Group	KO1	KO2	KO3
KO1		0.030*	0.009*
KO2	0.030*		0.710
Group	PO1	PO2	PO3
PO1		0.041*	0.001*
PO2	0.041*		0.039*

*There is a significant difference

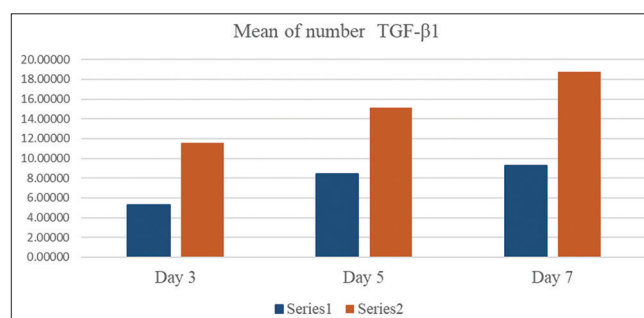


Figure 2: Mean value graph of transforming growth factor beta 1 expression on day 3, 5, and 7.

an anti-inflammatory in which macrophages release IL-10 and TGF- β , a very strong anti-inflammatory agent that immediately stops the inflammatory process and starts the proliferation phase.^[4] This is the reason why we as researchers observed TGF- β 1 expression as one of the important growth factors in wound-healing process.

The results of our research confirm the hypothesis that the administration of okra fruit extract can increase TGF- β 1 expression in the wound-healing process after tooth extraction of Wistar rats with DM. Observations were done by calculating the amount of TGF- β 1 expression in both groups, namely the control group (K) and the treatment group (P). In group K, the TGF- β 1 expression from Wistar tooth socket is less than in group P. However, in both K and P groups, we found the highest number of TGF- β 1 expression on the 7th day, as compared to on the 3rd and 5th day. This is due to the fact that the healing process that involves fibroblasts cell infiltration to the wound occurs the most on the 7th day; thus, the number of TGF- β 1 expression is higher than the 3rd and 5th day.^[3,4]

The mean number of TGF- β 1 expression in the K group shows lower results than the P group due to the STZ induction. A few days after the STZ induction, damage occurs in pancreatic beta-cells which results in insulin resistance and high-blood glucose level. In addition, the increased oxidative stress due to the formation of Advanced Glycation end products (AGEs) causes disruption of the fibroblast's proliferation, migration, and dysfunction.^[6]

Yamano *et al.* state that at the beginning of tooth extraction, the lowest amount of TGF- β 1 expression is obtained compared to the following day.^[16] In addition, a study by Hozzein *et al.* also infers that the administration of intraperitoneal STZ can cause a significant decrease in the regulation of TGF- β 1 in wound tissue.^[17]

In DM patients, an uncontrolled glycemic control causes a disruption in wound-healing process, which is a disturbance in the angiogenesis activity that causes pathogenesis mechanism.^[18] In group K, TGF- β 1 expression increased significantly on day 3–5, while on days 5–7, the expression of TGF- β 1 also increased, though not as significant. This is due to the fact that DM condition disrupts the innate role and function of immunity cells. High glucose level increases the cellular nuclear factor- κ B (NF- κ B) activation. If an injury

occurs, the prolonged inflammatory phase results in a proinflammatory response that increases the occurrence of chronic inflammation and tissue damage.^[6]

High-blood glucose level induces ROS which can be produced both enzymatically and nonenzymatically. Enzymatic production includes nicotinamide adenine dinucleotide phosphate oxidase (oxidase), nitric oxide synthase, cytochrome P-450, cyclooxygenase, lipoxygenase, xanthine oxidase, and myeloperoxidase^[19] and results in high proinflammatory cytokines which are released by neutrophils and macrophages as well as an increase in abnormal protease activity, resulting in disruption of growth factor signaling in the wound-healing process. This signaling disruption causes a decrease in growth factor and disrupts in the angiogenesis phase.^[13]

On the other hand, the P group had higher average TGF- β 1 as compared to K group due to the difference in okra fruit extract administration.^[20] Thus, it confirms the hypothesis that okra fruit extract can increase TGF- β 1 expression. Okra extract has antioxidant, anti-inflammatory, and antidiabetic qualities in wound-healing process.^[8,10] Okra extract contains polyphenols, flavonoids, isoquercetin, and quercetin-3-O-gentiobiose. Flavonoid is useful to repair damaged cells and forms a normal wound-healing process by inducing fibroplasia by TGF- β 1.^[21] Quercetin plays a role in regulating TGF- β 1 expression and decreasing the number of inflammatory cells. Quercetin also decreases the number of TNF- α while increasing fibroblasts proliferation and micro blood vessel density, leading to better reepithelialization and regular collagen deposition.^[22] Pang *et al.* state that low-dose flavonoid alone is able to stimulate TGF- β 1 expression which in turn increases TGF- β expression by macrophage stimulation induced by total flavonoids in wounds.^[23] TGF- β 1, secreted by M2 phenotype macrophages, plays a role in inhibiting the recruitment of inflammatory cells.^[24] TGF- β induces the keratinocyte and fibroblasts proliferation, causing the new capillaries formation in the granulation tissue and modulation of ECM deposition resulting in wound healing. TGF- β 1 also plays a role in angiogenesis by increasing the regulation of VEGF. During wound closure, TGF- β 1 increases keratinocyte migration.^[17]

In addition to reducing proinflammatory mediator production, okra fruit plays a role in reducing nitric oxide amount and ROS, as well as in reducing

the production of TNF- α .^[20] Excessive production of ROS causes activation of the NF- κ B signaling pathway. NF- κ B is a protein that stimulates cytokines and free radicals. It is also a transcription factor that regulates large numbers of genes involved in various immune and inflammatory response processes and causes vascular complications in DM patients and in inflammatory pathogenic processes that can be inhibited by flavonoids.^[21]

Flavonoid contained in okra fruit can reduce blood glucose level,^[10] resulting in a decrease in proinflammatory cytokines.^[20] High concentration of fiber and polysaccharides in the okra fruit can stabilize blood glucose by limiting the rate of absorption of sugar in the intestine.^[25] This complements the flavonoid content of the okra fruit which functions as an inhibitor of α -amylase and α -glucosidase, the enzymes found in the small intestine^[21] which act as carbohydrate catalyst by catalyzing oligosaccharides so that glucose absorption may take place. Inhibition of α -glucosidase can cause catalysis of complex carbohydrate diets such as oligosaccharides and polysaccharides to be inhibited by monosaccharides, resulting in decreased blood glucose level.^[10,12]

Glycoprotein-A repetitions predominant protein (GARP) is an important regulator in activating latent TGF- β (LTGF- β) and then binding it to LTGF- β . GARP acts as a docking receptor that functions as a carrier of LTGF- β on the cell surface, activating its role.^[7] GARP also plays a role in the regulation of T lymphocytes (Tregs) that form complexes with the α V β 8 integrin to release active TGF- β from the cell surface.^[17] TGF- β 1 stimulates fibroblasts to differentiate into myofibroblasts and then collaborates with these myofibroblasts to produce ECM, as well as collagen and matrix proteins, namely fibronectin.^[5] TGF- β 1 together with VEGF and fibroblasts stimulate the angiogenesis process.^[17] This explains the higher expression of TGF- β 1 in P group as compared to K group. Therefore, it can accelerate wound-healing process in the P group.

CONCLUSION

The administration of okra fruit extract can increase the number of TGF- β 1 in tooth extraction wounds on Wistar rats with DM.

Financial support and sponsorship

Nil.

Conflicts of interest

The authors of this manuscript declare that they have no conflicts of interest, real or perceived, financial or nonfinancial in this article.

REFERENCES

1. Reinke JM, Sorg H. Wound repair and regeneration. *Eur Surg Res* 2012;49:35-43.
2. Benadiba M, Serruya R, Maor Y. Bioaccessibility of Shore Magic® collagen, a low-molecular-weight collagen supplement, in different *in vitro* barrier models. *Heliyon* 2018;4:e00821.
3. Du Y, Ren P, Wang Q, Jiang SK, Zhang M, Li JY, *et al.* Cannabinoid 2 receptor attenuates inflammation during skin wound healing by inhibiting M1 macrophages rather than activating M2 macrophages. *J Inflamm (Lond)* 2018;15:25.
4. Anderson K, Hamm RL. Factors that impair wound healing. *J Am Coll Clin Wound Spec* 2012;4:84-91.
5. Zhao R, Liang H, Clarke E, Jackson C, Xue M. Inflammation in chronic wounds. *Int J Mol Sci* 2016;17:2085.
6. Kido D, Mizutani K, Takeda K, Mikami R, Matsuura T, Iwasaki K, *et al.* Impact of diabetes on gingival wound healing via oxidative stress. *PLoS One* 2017;12:e0189601.
7. Liu Y, Li Y, Li N, Teng W, Wang M, Zhang Y, *et al.* TGF- β 1 promotes scar fibroblasts proliferation and transdifferentiation via up-regulating MicroRNA-21. *Sci Rep* 2016;6:1-9.
8. Bhowmik D, Sampath Kumar KP, Tripathi P. Traditional herbal medicines: An overview. *Arch Appl Sci Res* 2009;1:165-77.
9. Solomon S. Anti-oxidant and anti-inflammatory activity of *Abelmoschus esculentus* (Flowers). *Indo Am J Pharm Sci* 2016:600-5.
10. Abbas AY, Muhammad I, AbdulRahman MB, Bilbis LS, Saidu Y, Onu A. Possible antidiabetic mechanism of action of ex-maradi okra fruit variety (*Abelmoschus esculentus*) on alloxan induced diabetic rats. *Niger J Basic Appl Sci* 2018;25:101.
11. Yeo YL, Chia YY, Lee CH, Sow HS, Yap WS. Effectiveness of maceration periods with different extraction solvents on *in-vitro* antimicrobial activity from fruit of *Momordica charantia* L. *J Appl Pharm Sci* 2014;4:16-23.
12. Tian ZH, Miao FT, Zhang X, Wang QH, Lei N, Guo LC. Therapeutic effect of okra extract on gestational diabetes mellitus rats induced by streptozotocin. *Asian Pac J Trop Med* 2015;8:1038-42.
13. Qinna NA, Badwan AA. Impact of streptozotocin on altering normal glucose homeostasis during insulin testing in diabetic rats compared to normoglycemic rats. *Drug Des Devel Ther* 2015;9:2515-25.
14. Gunawan F, Sularsih S, Soemartono S. The differences effect between low and high molecular weight chitosan on number of lymphocyte cells in the wound healing process of dental extraction. *Dent J Kedokt Gigi* 2015;9:113-22.
15. Sula B, Deveci E, Özevren H, Ekinçi C, Elbey B. Immunohistochemical and histopathological changes in the skin of rats after administration of lead acetate. *Int J Morphol* 2016;34:918-22.
16. Yamano S, Kuo WP, Sukotjo C. Downregulated gene expression

- of TGF- β s in diabetic oral wound healing. *J Craniomaxillofac Surg* 2013;41:e42-8.
17. Hozzein WN, Badr G, Al Ghamdi AA, Sayed A, Al-Waili NS, Garraud O. Topical application of propolis enhances cutaneous wound healing by promoting TGF-beta/Smad-mediated collagen production in a streptozotocin-induced type I diabetic mouse model. *Cell Physiol Biochem* 2015;37:940-54.
 18. Raghav A. Crucial role of diabetes mellitus in delayed angiogenesis of wound. *J Pharmacol Clin Res* 2018;5:4.
 19. Fakhruddin S, Alanazi W, Jackson KE. Diabetes-induced reactive oxygen species: Mechanism of their generation and role in renal injury. *J Diabetes Res* 2017;1-30.
 20. Shah BN, Seth AK. Anti-inflammatory activity of fruits of *Abelmoschus esculentus* Linn. *Pharmacol Online* 2010;1:208-12.
 21. Roy A, Shrivastava SL, Mandal SM. Functional properties of Okra *Abelmoschus esculentus* L. (Moench): Traditional claims and scientific evidences. *Plant Sci Today* 2014;1:121-30.
 22. Gopalakrishnan A, Ram M, Kumawat S, Tandan S, Kumar D. Quercetin accelerated cutaneous wound healing in rats by increasing levels of VEGF and TGF- β 1 – PubMed. *Indian J Exp Biol* 2016;54:187-95.
 23. Pang Y, Zhang Y, Huang L, Xu L, Wang K, Wang D, *et al.* Effects and mechanisms of total flavonoids from *Blumea balsamifera* (L.) DC. on skin wound in rats. *Int J Mol Sci* 2017;18:2766.
 24. Liu YC, Zou XB, Chai YF, Yao YM. Macrophage polarization in inflammatory diseases. *Int J Biol Sci* 2014;10:520-9.
 25. Durazzo A, Lucarini M, Novellino E, Souto EB, Daliu P, Santini A. *Abelmoschus esculentus* (L.): Bioactive components' beneficial properties-focused on antidiabetic role-for sustainable health applications. *Molecules* 2018;24:38.