

# Acceleration of post-tooth extraction socket healing after continuous aerobic and anaerobic physical exercise in wistar rats (*Rattus norvegicus*)

*by* Aqsa Sjuhada Oki

---

**Submission date:** 21-Apr-2021 11:06AM (UTC+0800)

**Submission ID:** 1565274058

**File name:** naerobic\_physical\_exercise\_in\_wistar\_rats\_Rattus\_norvegicus.pdf (392.75K)

**Word count:** 4168

**Character count:** 22622

Research Report

## Acceleration of post-tooth extraction socket healing after continuous aerobic and anaerobic physical exercise in Wistar rats (*Rattus norvegicus*)

Aqsa Sjuhada Oki,<sup>1</sup> Moch Febi Alviansyah,<sup>1</sup> Christian Khoswanto,<sup>1</sup> Retno Pudji Rahayu<sup>2</sup> and Muhammad Luthfi<sup>1</sup>

<sup>1</sup>Department of Oral Biology

<sup>2</sup>Department of Oral and Maxillofacial Pathology

Faculty of Dental Medicine, Universitas Airlangga, Surabaya, Indonesia

### ABSTRACT

**Background:** Physical exercise has been proven to accelerate wound healing. Physical training itself consists of aerobic (continuous training) and anaerobic (interval training) exercise. The effectiveness of continuous physical exercise on post-tooth extraction wound healing is the focus of this study. **Purpose:** This study aims to investigate the differences in post-tooth extraction wound healing in Wistar rats (*Rattus norvegicus*) after aerobic and anaerobic exercise based on the number of fibroblasts and neovascularisation. **Methods:** Wistar rats were divided into three groups: the control group (K1); K2 undertook continuous aerobic exercise, swimming at 50% maximum swimming capacity (MSC) with an additional 3% bodyweight load; K3 undertook anaerobic continuous exercise, swimming at 65% MSC with a 6% load. The rats swam three times per week for six weeks. The number of fibroblasts and neovascularisation were examined three days after tooth extraction. Data was analysed using the one-way analysis of variance (ANOVA) and Least Significant Difference (LSD) tests ( $p < 0.05$ ). **Results:** There was a significant difference in the number of fibroblasts between the K2 and K3 groups. There was no significant difference between K2 and K3 in the amount of neovascularisation. **Conclusion:** There were differences in the number of fibroblasts but not neovascularisation after tooth extraction in Wistar rats given aerobic and anaerobic continuous training.

**Keywords:** continuous aerobic physical exercise; continuous anaerobic physical exercise; fibroblasts; neovascularisation; post-tooth extraction wound healing

**Correspondence:** Aqsa Sjuhada Oki, Department of Oral Biology, Faculty of Dental Medicine, Universitas Airlangga, Jl Mayjen Prof Dr Moestopo No. 47 Surabaya 60132 Indonesia. Email: aqsa@fkg.unair.ac.id

### INTRODUCTION

Tooth extraction is an irreversible surgical procedure that sometimes causes complications if it is not handled properly.<sup>1</sup> Dental extraction complications can be divided into intraoperative complications, complications shortly after extraction and complications a long time after extraction. These occur because of microorganism infections, trauma, drugs or smoking. There have been efforts to reduce complications and accelerate wound healing using antibiotics, antifibrinolytics and topical drug applications.<sup>2</sup> However, the administration of drugs can cause further problems, such as allergies, resistance and systemic complications. Antibiotics can be used as

life-saving drugs and treatments to prevent infection, but they are also a predisposing factor for superinfection due to resistance and toxicity.<sup>3,4</sup> The effect of antibiotic resistance is called the Eagle effect, which increases the minimum bactericidal concentration (MBC) of antibiotics so that the dose needed to kill the bacteria must be increased.<sup>5</sup>

Efforts to improve wound healing with drugs are considered to have shortcomings, so an alternative form of therapy with exercise has been studied, but this is still not the primary choice. Regular physical exercise produces positive health effects, such as reducing various cardiovascular diseases, disorders of metabolic syndrome and osteoporosis.<sup>6</sup> It can supply nutrients and oxygen, which can accelerate the wound healing process, and it can

increase the secretion of healing factors to help the wound healing process.<sup>7</sup>

Previous studies have shown that physical exercise or sport is proven to heal wounds significantly in people who participate compared to those who do not.<sup>8</sup> One study explored the effect of continuous moderate-intensity physical exercise on the number of fibroblasts and neovascular disease in Wistar rat extract scars. The study found that participating in exercise increased the number of fibroblasts and neovascularisation in tooth extraction scars.<sup>9</sup> Physical exercise even accelerated wound healing in the inflammatory phase after tooth extraction. The study showed that physical exercise is one of the factors that can accelerate the wound healing process.<sup>10</sup> The proliferation phase occurs at the end of the inflammatory phase for up to 14–21 days after the injury. This phase's main objective is to repair injured tissue by fibroplasia, which includes wound closure, angiogenesis, re-epithelialisation and fibroplasia. Fibroblasts play a huge role in the repair process responsible for product preparation and protein structure that is used during the tissue reconstruction process.<sup>11</sup>

The response made by fibroblast cells in fibroplasia is proliferation, migration, formation of the extracellular matrix and wound contraction; angiogenesis or neovascularisation also occur in this stage. Angiogenesis is the process of forming new capillaries in a wound, and it is significant in the proliferation stage of the wound healing process because it generates new blood vessels to access nutrients, oxygen and other components in the wound healing process.<sup>12</sup>

At this stage, extracellular matrix biosynthesis occurs, which is the temporary matrix formed mainly from fibrin and fibronectin tissue and replaced by collagen matrix enriched in proteoglycans, glycosaminoglycans and non-collagen glycoproteins, which, in turn, causes the restoration of proper tissue structure and function. Cells that play an essential role in ECM biosynthesis are fibroblasts that secrete extracellular matrix products and components and the formation of granulation tissue. First, components and growth factors previously secreted by macrophages will stimulate the formation of a scaffold in the form of a granulation tissue matrix, such as collagenase, fibronectin and extracellular matrix components. The scaffold formed by these components will function as a facility for the collagen fibrogenesis process. Furthermore, within two weeks after injury, collagen increases and fibroblasts decrease due to apoptosis.<sup>13</sup> Based on the above explanation, this study aims to investigate the differences in the effectiveness of continuous aerobic and anaerobic exercise on the acceleration of wound healing after tooth extraction in Wistar rats (*Rattus norvegicus*) by observing the number of fibroblasts and neovascularisation.

## MATERIALS AND METHODS

This research was conducted after obtaining an ethical eligibility certification issued by the research ethics

commission under 190/HRECC.FODM/IV/2019. This study involves a post-test only control group with *in vivo* true experimental design. Thirty Wistar rats (*R. norvegicus*) were used with the criteria being 8–12 weeks-old, male and 250–300 grams in body weight. The animals were kept in a plastic cage during the day with enough air and light for acclimatisation. The cages were divided by groups and labelled to distinguish each cage. After the acclimatisation process, each rat's body weight was measured to determine the load given.

The rats were divided into three groups: the control group (K1) did not perform any physical activity; K2 participated in continuous aerobic exercise (swimming) with an additional load of 3% of the rats' body weight; K3 participated in continuous anaerobic exercise (swimming) with an additional load of 6%. The load was in the form of a paper clip tied to a rope one-third of the way from the base of the rat's tail. The control group was not given a load. After being given a load, the rats' maximum swimming capacity (MSC) was calculated to distinguish between the types of physical activity in each treatment group. This was obtained using the rats' weights and the maximum time they could swim for (until they started to sink, marked by the emergence of air bubbles) or when they stopped swimming. The MSC calculation was not carried out for the control group because the rats were placed in containers of water that came up to their feet so that the body temperatures of the control group and treatment groups were equalised. K2 swam at 50% MSC with a load of 3% body weight, and K3 swam at 65% MSC with an additional load of 6% body weight.<sup>14,15</sup>

All three groups were treated three times a week for six weeks. In the seventh week, each rat was anaesthetised with a ketamine injection to extract the mandibular left incisor. This was performed with modified pliers then irrigated with distilled water to remove debris and the remnants of the extraction. On the third day after the extraction, euthanasia was carried out on all rats so their mandibles could be removed. Histology tissue was taken to check the number of fibroblasts and neovascularisation in the post-tooth extraction socket.<sup>10</sup>

The tissue was extracted using a microtome with a thickness of 4–6 µm then it was attached to a glass object. Xylol was used for deparaffination and 90% alcohol for rehydration. Hematoxylin-eosin (HE) staining (Merck Chemical, Darmstadt, Germany) was used, which, in acidic conditions, will attract alkaline substances/solutions so they will turn blue, and the cytoplasm is alkaline, which will attract acidic substances/solutions so they turn red. To colour the nucleus and cytoplasm, 0.6% HCl was stained for differentiation using 0.5% lithium carbonate to give the nucleus a blue colour, and eosin stain was used to give the cytoplasm a red colour. The process ended with dehydration and mounting. Preparations were read by counting the number of fibroblast cells and neovascularisation in five fields using a light microscope with 400x magnification. There were three observers.<sup>15</sup>

1

After histological readings to find the number of fibroblasts and neovascularisation, data was collected for statistical tests using Statistical Package of Social Science (SPSS) version 16.0 for Windows (IBM, New York, USA) with normality and homogeneity tests conducted in advance to determine the different tests performed. The normality test was conducted using the Shapiro-Wilk's test and Levene's test was used to test homogeneity ( $p > 0.05$ ); subsequently, a parametric comparison test was performed with one-way ANOVA along with a non-parametric comparison using the Kruskal-Wallis test ( $p < 0.05$ ). The LSD posthoc test was used to analyse the difference between groups after the ANOVA test was performed ( $p < 0.05$ ).

**RESULTS**

The observation of fibroblast cells in the mandibular incisor socket of the Wistar rat can be seen in Figure 1. The average results of the number of fibroblasts in the wound healing process after the extraction of the Wistar rat tooth and the results of normality and homogeneity tests are available in Table 1.

**Table 1.** The mean, normality test and homogeneity test of the number of fibroblasts in each group

Groups	Mean ± SD	Normality test	Homogeneity test
K1	15.00 ± 0.8165	0.144*	
K2	17.86 ± 1.9518	0.200*	0.101*
K3	20.71 ± 3.3523	0.119*	

\*significant at  $p > 0.05$

The highest mean value of the number of fibroblasts was found in the anaerobic continuous training group (K3), while the lowest fibroblast mean values were found in the control group that did not swim (K1). In the normality test results using the Shapiro-Wilk's test, all groups had normal distribution values ( $p > 0.05$ ), whereas the homogeneity test results using Levene's test had a significance of 0.101, which provides homogeneous data.

Table 2 displays the results from the ANOVA test, which obtained a significance value of 0.001 ( $p < 0.05$ ); this indicates a significant difference between the groups. The results of the LSD posthoc tests, in Table 3, shows significant differences between all three groups ( $p < 0.05$ ).

The observation of neovascularisation in the mandibular incisor socket of the Wistar rat can be seen in Figure 2.

**Table 2.** Overall difference test of fibroblast groups

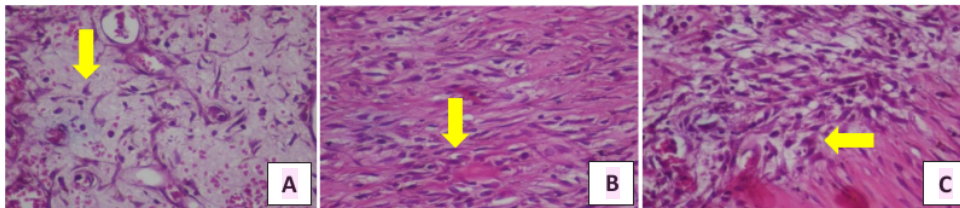
One-way ANOVA	
<i>p</i> -value	0.001*
$\alpha$	0.05

\*significant at  $p < 0.05$

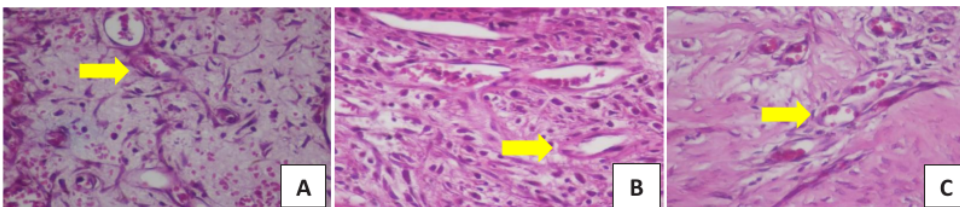
**Table 3.** Difference test between fibroblast groups using LSD posthoc test

Groups	K	K1	K2
K1			
K2	0.031*		
K3	0.000*	0.031*	

\*significant at  $p < 0.05$



**Figure 1.** Fibroblast in the socket of a maxillary incisor tooth extraction with HE staining, indicated by the yellow arrows. Groups K1 (A), K2 (B) and K3 (C).



**Figure 2.** Neovascularisation in the socket of a mandibular incisor tooth extraction with HE staining, indicated by the yellow arrows. Groups K1 (A), K2 (B) and K3 (C).



**Table 4.** The mean and standard deviation of neovascularisation amounts

Groups	Mean ± SD	Normality test	Homogeneity test
K1	8.57 ± 1.1339	0.262*	0.335*
K2	9.28 ± 1.7043	0.140*	
K3	10.71 ± 2.2887	0.518*	

\*significant at  $p > 0.05$ **Table 5.** Overall difference test of the neovascularisation groups

	One-way ANOVA
$p$ -value	0.098
$\alpha$	0.05

 $p$ -value: One-way ANOVA significance value of neovascularisation variable;  $\alpha$ : Significance value of the different tests.

Table 4 shows the neovascularisation mean values along with the results of the normality and homogeneity tests. In the table, the highest neovascularisation mean is in the continuous anaerobic exercise group (K3), and the lowest average is in the control group (K1). The normality test for each group shows that the distribution data is normal because  $p > 0.05$ , whereas the homogeneity test results show 0.335, which means homogeneous data continued with the one-way ANOVA parametric test. Table 5 shows that the different test results for the whole neovascularisation group gave a result of 0.098 ( $p > 0.05$ ), which means there were no significant differences between the groups on neovascularisation variables.

## DISCUSSION

The wound healing process has several healing phases, including haemostasis, inflammation, proliferation and remodelling. As one of the factors that influences wound healing is oxygen, participating in physical exercise is expected to increase tissue oxygen consumption ( $VO_2$  max) so that the wound healing process is faster due to the stimulation of cells. Cells that play a role in wound healing include PMN cells, macrophages, fibroblasts and neovascularisation.<sup>16</sup>

As experimental animals, Wistar rats have several advantages: they are cheap, easy to obtain, breed and keep, and they have a physiological body that is almost the same as humans. During the experiment, several rats became sick and died, so they had to be removed from the study. The swim test was used because the research tools and materials could be easily prepared and have been proven by other researchers to obtain reasonably good results.<sup>17</sup>

The groups for aerobic and anaerobic continuous exercise training were determined by calculating the results of the MSC and body weight of the experimental animals. Aerobic exercise intensity was 50% of the MSC and a weighting of 3% (medium intensity), while 65% of the MSC and a load of 6% were chosen as anaerobic physical exercise

(high intensity). An obstacle in determining anaerobic physical exercise occurred because all of the literature suggests that methods of high-intensity anaerobic exercise involve interval training. However, the focus of this study was on continuous training. Therefore, as a preliminary study, we experimented with continuous anaerobic exercise at 65% MSC and a 7% load. However, several Wistar rats experienced fatigue and then death, so the researchers lowered the MSC and load without reducing the essence of the high-intensity physical exercise.<sup>18,19</sup>

Wound healing occurs in the proliferation phase, after haemostasis and inflammation but before remodelling. In the proliferation phase, several vital processes are related to studying the number of fibroblasts and neovascularisation. Macrophage cells found in the inflammation phase secrete matrices and growth factors to stimulate fibroplasia and angiogenesis. These include metalloproteinase, platelet-derived growth factor (PDGF), fibroblast growth factor (FGF), epidermal growth factor (EGF), transforming growth factor-beta and alpha ( $TGF-\beta/\alpha$ ) and vascular endothelial growth factor (VEGF). The process of angiogenesis and the proliferation of fibroblasts occur in tandem. When a wound occurs, branches of capillary blood vessels form around the edge resulting in bleeding for blood clot formation. The proliferation phase occurs after the fibroplasia process.<sup>12</sup>

Fibroplasia is the process of stimulating fibroblast cells to actively proliferate, migrate and form an extracellular matrix (ECM). The matrix will function as a scaffold for the next wound healing process. After fibroplasia comes angiogenesis, which is the process of forming neovascularisation. This process restores blood circulation to the injured area and prevents the development of necrotic tissue. The process is stimulated by factors and growth components, such as basic FGF,  $TGF-\beta$ , tumour necrosis factor- $\alpha$  (TNF- $\alpha$ ), VEGF, angiogenin and angiotrofin. The cells that perform neovascularisation are stimulated and migrate to the temporary matrix (scaffold) that has been formed by fibroblast cells. Subsequently, cells develop and form a new network of blood vessels into tubular structures. The processes of fibroplasia and angiogenesis go hand-in-hand and synergise to form a layer of collagen and epithelium, which is a sign of the final phase of wound healing or remodelling.<sup>20,21</sup>

This statement supports the proven research results on fibroblasts in the treatment group rather than the control group. The process of fibroplasia in wound tissue after tooth extraction in Wistar rats is mediated by fibroblast cells stimulating the formation of the extracellular matrix so that fibroblasts can be seen in histological preparations. In this process, angiogenesis will be followed by neovascularisation. However, on the histopathological readings, the neovascularisation results were insignificant. This is likely to occur because the angiogenesis process occurs on the second and third day when the fibroplasia process has already taken place.<sup>22</sup>

Another factor affecting the results is the determination of the training intensity method, which has almost the

same effect. In the continuous anaerobic exercise group, researchers have not used a standard method for determining the magnitude of the MSC and the load that is given, so the results can be biased if there is no standardisation. Additionally, it proves that interval-type training is better than continuous training because there is a resting phase that improves the effectiveness of the exercise.<sup>20</sup> Non-standardised tooth extraction techniques can also affect the results due to the occurrence of root fractures and bleeding during high extractions, which will disrupt the wound healing process.<sup>15</sup>

Theoretically, physical exercise will affect the wound healing process due to the appearance of free radicals in the body, which will disturb or delay wound healing. This happens if the period between the process of injury and participation in physical activity is close together, or even physical activity is only carried out after the injury. The healing process will be disrupted due to a lack of oxygen to the wound tissue and the build-up of lactic acid during sports activities. At a molecular level, the build-up of lactic acid causes reactive oxidative stress (ROS) and free radicals and inhibits scaffold formation in fibroplasia.<sup>9</sup>

In this study, physical exercise was performed before tooth extraction in Wistar rats. The training involved either continuous aerobic training or continuous anaerobic training. The results of this study indicated a higher number of fibroblasts and neovascularisation in the anaerobic training group (K3) because the heart and body adapt after 7–10 days after exercise by thickening the heart muscle and increasing lung capacity.<sup>21</sup> At the beginning of exercise (<7 days), lactic acid increases and VO<sub>2</sub> max decreases, which is proven to be significant, and this was demonstrated at the highest level in the anaerobic exercise group.<sup>22</sup>

Anaerobically, VO<sub>2</sub> max increases and the heart supplies blood to the body more efficiently and effectively due to the body's adaptation processes.<sup>23</sup> These conditions accelerate the wound healing process. Statements and research by Flora et al. and Shi et al. support the results of this study, which showed the number of fibroblasts in the continuous anaerobic exercise group (K3) was higher than the continuous aerobic exercise group (K2).<sup>22,24</sup> Based on the results of this study, we concluded that anaerobic exercise provides a wound-healing acceleration effect on increasing the number of fibroblasts compared to aerobic exercise.

## ACKNOWLEDGEMENTS

We are particularly grateful to the head of the Department of Oral Biology, Faculty of Dental Medicine, Universitas Airlangga for technical and organisational support.

## REFERENCES

1. Fakhrruzazi, Hakim RF, Ulfa L. The differences blood glucose levels at random before and after tooth extraction of the patients at dental installation RSUDZA Banda Aceh. *Cakradonya Dent J.* 2017; 9(2): 96–100.
2. Preetha S. An overview of dry socket and its management. *IOSR J Dent Med Sci.* 2014; 13(5): 32–5.
3. Wright J, Paauw DS. Complications of antibiotic therapy. *Med Clin North Am.* 2013; 97(4): 667–79.
4. Blumenthal KG, Peter JG, Trubiano JA, Phillips EJ. Antibiotic allergy. *Lancet.* 2019; 393(10167): 183–98.
5. Prasetyoputri A, Jarrad AM, Cooper MA, Blaskovich MAT. The eagle effect and antibiotic-induced persistence: Two sides of the same coin? *Trends Microbiol.* 2019; 27(4): 339–54.
6. Harun L. Perbandingan kadar interleukin-6 dan jumlah limfosit setelah latihan aerobik ringan dan sedang pada remaja. *Heal J.* 2018; 1(2): 64–8.
7. Keylock KT, Vieira VJ, Wallig MA, DiPietro LA, Schrementi M, Woods JA. Exercise accelerates cutaneous wound healing and decreases wound inflammation in aged mice. *Am J Physiol - Regul Integr Comp Physiol.* 2008; 294(1): R179–84.
8. Pence BD, Woods JA. Exercise, obesity, and cutaneous wound healing: Evidence from rodent and human studies. *Adv Wound Care.* 2014; 3(1): 71–9.
9. Oki AS, Bimarahmanda ME, Rahardjo MB. Increased number of fibroblasts and neovascularization after tooth extraction in wistar rats with moderate-intensity continuous exercise. *J Int Dent Med Res.* 2018; 11(3): 840–5.
10. Oki AS, Amalia N, Tantiana. Wound healing acceleration in inflammation phase of post-tooth extraction after aerobic and anaerobic exercise. *Sci Sport.* 2020; 35(3): 168.e1-168.e6.
11. Gonzalez ACDO, Andrade ZDA, Costa TF, Medrado ARAP. Wound healing - A literature review. *An Bras Dermatol.* 2016; 91(5): 614–20.
12. Olczyk P, Mencner, Komosinska-Vashev K. The role of the extracellular matrix components in cutaneous wound healing. *Biomed Res Int.* 2014; 2014: 747584.
13. Ercan E. The effect of platelet-rich fibrin and titanium prepared platelet-rich fibrin on early soft tissue healing of extraction sites. *Cumhuriyet Dent J.* 2018; 21(4): 304–10.
14. Way KL, Sultana RN, Sabag A, Baker MK, Johnson NA. The effect of high intensity interval training versus moderate intensity continuous training on arterial stiffness and 24 h blood pressure responses: A systematic review and meta-analysis. *J Sci Med Sport.* 2019; 22(4): 385–91.
15. Khoswanto C. A new technique for research on wound healing through extraction of mandibular lower incisors in Wistar rats. *Eur J Dent.* 2019; 13(2): 235–7.
16. Oki AS, Farhana N, Yulianti. The effect of aerobic and anaerobic interval exercise on the proliferation phase of wound healing in tooth extraction of *Rattus norvegicus*. *Acta Med Philipp.* 2019; 53(5): 417–22.
17. Setyadewi W, Oki AS, Sunariani J. Moderate intensity physical exercise effect on PMN and macrophage expression in *Rattus norvegicus* post tooth extraction. *J Int Dent Med Res.* 2017; 10(2): 364–7.
18. Goh J, Ladiges WC. Exercise enhances wound healing and prevents cancer progression during aging by targeting macrophage polarity. *Mech Ageing Dev.* 2014; 139(1): 41–8.
19. Rashidi M, Salehian O, Vaezi G. The effect of high intensity anaerobic training on the blood lactate levels after active recovery. *Eur J Exp Biol.* 2013; 3(6): 346–50.
20. Irmawati A, Giffari FZ, Oki AS. The effect of moderate exercise on vascular endothelial growth factor expression during tooth socket wound healing after tooth extraction. *J Postgrad Med Inst.* 2018; 32(1): 19–23.
21. Ding J, Tredget EE. The role of chemokines in fibrotic wound healing. *Adv Wound Care.* 2015; 4(11): 673–86.
22. Shi M, Wang X, Yamanaka T, Ogita F, Nakatani K, Takeuchi T. Effects of anaerobic exercise and aerobic exercise on biomarkers of oxidative stress. *Environ Health Prev Med.* 2007; 12(5): 202–8.
23. Tatullo M. The regenerative dentistry: Current approaches and future insights. *Cumhuriyet Dent J.* 2020; 23(1): 1–3.
24. Flora R. Pengaruh latihan fisik anaerobik terhadap kadar laktat plasma dan kadar laktat jaringan otot jantung tikus Wistar. *Biomed J Indones.* 2015; 1(1): 40–2.

# Acceleration of post-tooth extraction socket healing after continuous aerobic and anaerobic physical exercise in wistar rats (*Rattus norvegicus*)

## ORIGINALITY REPORT

17%

SIMILARITY INDEX

11%

INTERNET SOURCES

9%

PUBLICATIONS

6%

STUDENT PAPERS

## PRIMARY SOURCES

1	Submitted to Universitas Airlangga Student Paper	5%
2	<a href="https://repository.unair.ac.id">repository.unair.ac.id</a> Internet Source	2%
3	"Poster", Journal Of Clinical Periodontology, 2015. Publication	1%
4	Batoryna Olgierd, Żyła Kamila, Banyś Anna, Morawiec Emilia. "The Pluripotent Activities of Caffeic Acid Phenethyl Ester", Molecules, 2021 Publication	1%
5	<a href="http://www.dovepress.com">www.dovepress.com</a> Internet Source	1%
6	Fitri Kurnia Rahayu, Sri Ratna Dwiningsih, Ashon Sa'adi, Lilik Herawati. "Effects of different intensities of exercise on folliculogenesis in mice: Which is better?",	1%

# Clinical and Experimental Reproductive Medicine, 2021

Publication

---

7	<a href="http://www.thieme-connect.de">www.thieme-connect.de</a> Internet Source	1 %
8	<a href="http://docplayer.net">docplayer.net</a> Internet Source	1 %
9	<a href="http://e-nrp.org">e-nrp.org</a> Internet Source	1 %
10	<a href="http://www.woundsresearch.com">www.woundsresearch.com</a> Internet Source	1 %
11	<a href="http://worldwidescience.org">worldwidescience.org</a> Internet Source	<1 %
12	<a href="http://researcherslinks.com">researcherslinks.com</a> Internet Source	<1 %
13	<a href="http://zombiedoc.com">zombiedoc.com</a> Internet Source	<1 %
14	<a href="http://www.hindawi.com">www.hindawi.com</a> Internet Source	<1 %
15	<a href="http://www.thieme-connect.com">www.thieme-connect.com</a> Internet Source	<1 %
16	"Poster Abstracts", Journal Of Clinical Periodontology, 2012. Publication	<1 %

---



17 Muhammad Luthfi, Wisnu Setyari Juliastuti, Yuniar Aliyah Risky. "Angiogenesis of Extracted Tooth Wound on Wistar Rats After Application of Okra (*Abelmoschus esculentus*) Gel Extract", Pesquisa Brasileira em Odontopediatria e Clínica Integrada, 2020  
Publication

---

18 [core.ac.uk](https://core.ac.uk)  
Internet Source

---

19 [www.fisheriesjournal.com](http://www.fisheriesjournal.com)  
Internet Source

---

20 Marmolejo-Ramos, Fernando, María Rosa Elosúa, Yuki Yamada, Nicholas Francis Hamm, and Kimihiro Noguchi. "Appraisal of Space Words and Allocation of Emotion Words in Bodily Space", PLoS ONE, 2013.  
Publication

---

21 [journal.umbjm.ac.id](http://journal.umbjm.ac.id)  
Internet Source

---

22 [journal.unismuh.ac.id](http://journal.unismuh.ac.id)  
Internet Source

---

23 [journals.sagepub.com](http://journals.sagepub.com)  
Internet Source

---

24 [revista.nutricion.org](http://revista.nutricion.org)  
Internet Source

---

[www.nature.com](http://www.nature.com)

25

Internet Source

<1 %

26

[www.vetcer.org](http://www.vetcer.org)

Internet Source

<1 %

27

Anna A. Borovikova, Mary E. Ziegler, Derek A. Banyard, Garrett A. Wirth et al. "Adipose-Derived Tissue in the Treatment of Dermal Fibrosis", *Annals of Plastic Surgery*, 2018

Publication

<1 %

28

Jie Bao, Katja Närhi, Ana Teodòsio, Annabrita Hemmes et al. "The role of SOX9 in non-small cell lung cancer progression is histopathology-selective", Cold Spring Harbor Laboratory, 2020

Publication

<1 %

Exclude quotes On

Exclude matches Off

Exclude bibliography On

# Acceleration of post-tooth extraction socket healing after continuous aerobic and anaerobic physical exercise in wistar rats (*Rattus norvegicus*)

---

GRADEMARK REPORT

---

FINAL GRADE

**/100**

GENERAL COMMENTS

**Instructor**

---

PAGE 1

---

PAGE 2

---

PAGE 3

---

PAGE 4

---

PAGE 5

---