

Identification and Prevalence of Digestive Tract Endoparasites of Goats in Ujungpangkah, Gresik District

by Endang Suprihati

Submission date: 29-Mar-2022 10:46AM (UTC+0800)

Submission ID: 1795673710

File name: Identification_and_Prevalence_of_Digestive.pdf (485.68K)

Word count: 2518

Character count: 13319

Identification and Prevalence of Digestive Tract Endoparasites of Goats in Ujungpangkah, Gresik District

¹⁾Muhammad Fahmi Abdillah, ²⁾Nunuk Dyah Retno Lastuti, ³⁾Suzanita Utama, ¹⁾Endang Suprihati

¹⁾Student, Faculty of Veterinary Medicine, Universitas Airlangga, muhammadfahmiabd@gmail.com

²⁾Division of Veterinary Parasitology, Faculty of Veterinary Medicine, Universitas Airlangga

³⁾Division of Veterinary Reproduction, Faculty of Veterinary Medicine, Universitas Airlangga

Received: 15-08-2021, Accepted: 25-08-2021, Published Online: 30-09-2021

Corresponding author: nunukdyah53@gmail.com

Abstract

This study aims to determine the prevalence and species of endoparasite that infect the digestive tract of goats in Ujungpangkah Sub-District, Gresik District. This study was conducted in February-March 2021 with 100 samples of goat's stool. Sample examination was conducted in the laboratory of the Division of Veterinary Parasitology, Faculty of Veterinary Medicine, Universitas Airlangga. In fecal examination found four types of endoparasites, which were: *Eimeria* sp. 62%, *Blastocystis* sp. 5%, *Haemonchus* sp. 4%, *Strongyloides* sp. 2% and mixed infection prevalence was 3%. This study showed a prevalence of 76% digestive tract endoparasite. The Chi-Square test showed significant differences ($p < 0.05$) between groups of goats aged under one year (57%) and over one year (43%).

Keywords: *Eimeria* sp, *Blastocystis* sp, *Haemonchus* sp, *Strongyloides* sp, Ujungpangkah, Goat.

Introduction

Ujungpangkah District is one of the sub-districts in the Gresik Regency. Most of the population raise goats. The population of goats in Ujungpangkah District is 4,060 heads (Central Bureau of Statistics of Gresik Regency, 2019). Based on the results of observations on October 5, 2020, it was found that there were goats in Ujungpangkah District with conditions that looked thin and some had diarrhea. This is by the research that has been reported by Thalma *et al.* (2016) that the lean body condition of goats is one of the signs that livestock is infected by endoparasites. Herbowo and Firmansyah (2003) stated that the types of endoparasites that can cause diarrhea are protozoa (*Giardia* sp., *Cryptosporidium* sp., *Entamoeba* sp., *Balantidium coli*) and helminth infections, one of which is *Strongyloides* sp.

According to Rophi (2015), the tropical climate in Indonesia is very supportive of the survival of endoparasites and helps the occurrence of infection in goats. Geographical conditions in Indonesia which have a tropical climate and are supported by humid and hot air cause the spread of endoparasites to occur quite high (Yuliato, 2007). Geographically, the location of Ujungpangkah Subdistrict, Gresik Regency is located in an area near the coast with

high temperature and humidity conditions making it possible for the transmission of endoparasite infection in goats.

Endoparasite infection will cause worldwide economic losses and livestock health problems (Indraswari *et al.*, 2017). Losses due to endoparasite infection according to the Directorate General of Livestock (2010), reach 4 billion rupiah per year. The health losses of goats due to endoparasite infection include weight loss, dehydration, fatigue, while severe infections can cause diarrhea (Daugochies and Najdrowski, 2005). This is due to damage to the intestinal epithelium so that it can reduce the ability to digest and absorb food substances in the intestines and reduce the production of enzymes that play a role in the digestive process, while large amounts of endoparasite infection can cause disruption of the digestive process and inhibit livestock growth (Zalizar, 2017).

Materials and Methods

A sampling of goat feces as many as 100 samples was carried out in five villages in Ujungpangkah District, Gresik Regency, namely Pangkahwetan, Pangkahkulon, Banyuurip, Gosari, and Sekapuk villages then added 2.5% potassium bichromate ($K_2Cr_2O_7$) as a preservative. Each plastic ointment pot is labeled. The



This work is licensed under a Creative Commons Attribution-Share Alike 4.0 International License

12 samples were examined at the Veterinary Parasitology Laboratory, Faculty of Veterinary Medicine, Airlangga University, Surabaya with sedimentation and floating methods.

In this method, a stool suspension is made with a 1:10 ratio of feces and water which is put in a test tube. The suspension was stirred and filtered using a plastic tea filter that was accommodated in a plastic cup. The filtrate was put into a centrifuge tube and centrifuged at 1500 rpm for five minutes. The supernatant was discarded, then the precipitate was added with water and centrifuged again. This process was repeated until a clear supernatant was obtained. After the last centrifugation process, the clear supernatant was removed and a little was left, the precipitate was stirred then took a small amount of precipitate using a Pasteur pipette, the precipitate was placed on a slide and covered with a coverslip, and then examined with a microscope with a magnification of 100x (Mumpuni et al, 2017).

The suspension of feces with a ratio of feces and water of 1:10 was then filtered. The filtrate obtained was put into a centrifuge tube and then centrifuged at 1500 rpm for 5 minutes. Furthermore, the supernatant was discarded, then added with aqua dest, and centrifuged again. This is done repeatedly until the supernatant appears clear. After the last centrifugation process, the clear supernatant was discarded and replaced with a saturated sugar solution up to 1 cm from the mouth of the tube and then centrifuged again in the same way. The centrifuge tube is placed on the tube rack and saturated sugar solution is added until it looks convex at the mouth of the centrifuge tube. Then, the coverslip was placed on top of the centrifuge tube and left for 15 minutes. After

11 that, the coverslip was taken and placed on a slide and examined under a microscope with a magnification of 100x (Mumpuni et al, 2017).

Samples were declared positive if one of the fecal examination methods (sedimentation and buoyancy methods) found endoparasites by looking at the morphology and measuring the endoparasites using the Soulsby (1986) identification key. Calculation of prevalence can be obtained from the number of samples that are positive for endoparasites divided by the total number of samples and then presented as a percentage.

The research data were analyzed using the Chi-Square test. Statistical analysis used the SPSS (Statistical Product and Service Solution) for Windows rel 22.0 program to determine the effect of goat age on the prevalence of digestive tract endoparasitic infections in goats.

Results and Discussion

Based on laboratory examinations using the sedimentation method and the floating method on 100 samples of goat feces taken in Ujungpangkah Sub-District, Gresik District from February to March 2021, 76 samples were found to be positive for digestive tract endoparasites in the form of single or mixed infections.

On examination of feces found four types of endoparasites, namely: *Eimeria* sp. 62%, *Blastocystis* sp. 5%, *Haemonchus* sp. 4%, *Strongyloides* sp. 2% and the prevalence of mixed infections as much as 3%, are fully presented in Table 1. The results of the prevalence of gastrointestinal endoparasites by age and type of endoparasites can be seen at Table 2.

Table 1. Digestive Tract Endoparasite Infection in Goats Raised in Ujungpangkah Sub-District, Gresik District

| Sample | Infection | | | Type of Endoparasites | | |
|----------|-------------------|-------|------------------|--|-------|------------------|
| | Type of Infection | Total | Presentation (%) | Endoparasites | Total | Presentation (%) |
| Positive | Single | 73/76 | 96 | <i>Eimeria</i> sp. | 62/73 | 85 |
| | | | | <i>Blastocystis</i> sp. | 5/73 | 7 |
| | | | | <i>Haemonchus</i> sp. | 4/73 | 5 |
| | | | | <i>Strongyloides</i> sp. | 2/73 | 3 |
| | Mixed | 3/76 | 4 | <i>Eimeria</i> sp. and <i>Blastocystis</i> sp. | 2/3 | 67 |
| | | | | <i>Eimeria</i> sp. and <i>Haemonchus</i> sp. | 1/3 | 33 |

Table 2. Prevalence of Gastrointestinal Endoparasite Infection in Goats in Ujungpangkah Sub-District, Gresik District based on Age and Type of Endoparasites.

| Type of Endoparasites | Infected Sample | Prevalence | |
|--|-----------------|------------------------|------------------------|
| | | <1 year (positive/(%)) | >1 year (positive/(%)) |
| <i>Eimeria</i> sp. | 62 | 36/62 (58%) | 26/62 (42%) |
| <i>Blastocystis</i> sp. | 5 | 1/5 (20%) | 4/5 (80%) |
| <i>Haemonchus</i> sp. | 4 | 3/4 (75%) | 1/4 (25%) |
| <i>Strongyloides</i> sp. | 2 | 1/2 (50%) | 1/2 (50%) |
| <i>Eimeria</i> sp. and <i>Blastocystis</i> sp. | 2 | 1/2 (50%) | 1/2 (50%) |
| <i>Eimeria</i> sp. and <i>Haemonchus</i> sp. | 1 | 1/1 (100%) | 0/1 (0%) |

The results showed that the prevalence rate of gastrointestinal endoparasite infection in goats kept in Ujungpangkah, Gresik District was 76% of the total 100 samples that had been examined. The data obtained were the prevalence of digestive tract endoparasites in goats aged less than 1 year of 91.5% with a total of 43 positive samples from a total of 47 samples. The prevalence of digestive tract endoparasites in goats with the age of more than 1 year was 62.3% with 33 positive samples from 53 samples. The Chi-Square analysis showed a significant value of 0.001. This shows that the highly difference ($p < 0.01$) in age affects the prevalence of gastrointestinal endoparasite infection.

The types of endoparasites found in goat feces samples using the floating method can be seen in Figure 1. This study found four species of endoparasites, namely *Eimeria* sp., *Blastocystis* sp., *Haemonchus* sp., and *Strongyloides* sp. in goat feces samples. General characteristics of *Eimeria* sp. which has sporulated that has 4 sporocysts that are visible have a two-layered wall, the outer layer is colorless while the inner layer is dark. Based on size and shape, this study found the oocyst stage of *Eimeria* sp. (62%). *Eimeria* sp. occurs more often in the rainy season and there is an increase in infection because the humidity in the environment is favorable for protozoa to sporulate (Kumar *et al.*, 2016). The *Eimeria* found in this study is thought to be close to the species *Eimeria caprovina* and *Eimeria christenseni*. The species *Eimeria christenseni* has an ovoid shape, has a microphil cup, and measures 30.60 x 22.37 m. while *E. caprovina* also has an ovoid shape but no microphil cup and has a size of 33.71 x 24.93 m. These characteristics and sizes are by the statement of Macedo *et al.*, (2019) that *Eimeria christenseni* has a size of 38.4 ± 2.69 m x 24.72 ± 2.21 m and *E. caprovina* has a size of 31.76 ± 3.11 m x 23.27 ± 2.25 m.

Blastocystis sp. (5%) was also found in this study. *Blastocystis* sp. vacuolar cyst stage measuring 24.66 x 22.64 m round, thick-walled. In

this study, eggs of worms were also found, namely *Haemonchus* sp. (4%) and *Strongyloides* sp. (2%). Eggs of *Haemonchus* sp. found in this study was in the form of a thin oval shell, equal in shape (equal) at both poles, the edges of the morula did not fill the egg cavity and had a length of 77.49 m with a width of 33.63 m. In *Strongyloides* sp. worm eggs. Obtained in this study and has a length of 64.23 m with a width of 24.79 m. The results of this examination are by previous research by Mulyadi *et al.*, (2017) which stated that worm species from the nematode class were more commonly found in livestock than worm species from the cestode and trematode classes. This could be since nematode worms are helminths of the digestive tract that do not require an intermediate host, so the life cycle of these worms takes place more quickly (Southwell, 2008).

The number of feces and feed residue that accumulate in the cage can be one of the factors for the high prevalence of the protozoan *Eimeria* sp. employing transmission through ingestion of oocysts with food contaminated by oocysts originating from accumulated feces (Indraswari *et al.*, 2017). Dirt that accumulates in the cage makes the cage more humid and has a warmer temperature. A humid environment is a suitable condition for the growth of various types of parasites, so it is possible to continue their life cycle (Purwanta *et al.*, 2006).

Goats less than one-year-old have a prevalence rate of 91.5% while those aged more than one year have a prevalence rate of 62.3%. This is by the statement of Om *et al.* (2010), namely the prevalence of endoparasites in young goats is higher than in adult goats. Heidari *et al.* (2014) stated that young goats have lower immunity and will be infected if the cage placement is mixed together with adult goats. Adult goats are more resistant to endoparasitic infections because their immune systems are fully developed.

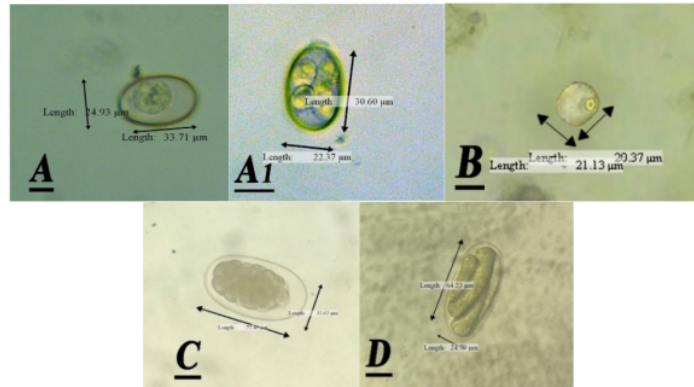


Figure 1. Images of Endoparasites found. (A), *Eimeria caprovina*; (A₁), *Eimeria christensenii*; (B), *Blastocystis* sp.; (C), *Haemonchus* sp.; (D), *Strongyloides* sp. (400x magnification).

Conclusions

The conclusion of the results, that the types of endoparasites found in goats kept in Ujungpangkah Sub-District, Gresik District was *Eimeria* sp., *Blastocystis* sp., *Haemonchus* sp., and *Strongyloides* sp. The prevalence of gastrointestinal endoparasite infection in goats was 76%. The prevalence of gastrointestinal endoparasite infection in goats aged more than one year 43% and less than one year 57%.

References

- Dauguschies, A. dan M. Najdrowski. 2005. Eimeriosis in cattle: current understanding. *Journal of Veterinary Medicine B Infectious Diseases and Veterinary Public Health*. 52(10):417-27.
- Direktorat Jendral Peternakan. 2010. Epidemiologi Kejadian Penyakit Nematodiasis di Indonesia. Departemen Pertanian. Jakarta.
- Heidari, H., Z. S. Dehkordi, R. Moayedi, and J. Gharekhani. 2014. Occurrence and diversity of *Eimeria* species in cattle in Hamedan province, Iran. *Veterinari Medicine*. 59(6):271-275.
- Herbowo, & Firmansyah, A. (2003). Diare Akibat Infeksi Parasit. *Sari Pediatri*. 4(4):198-203.
- Indraswari, A.A.S., N.I. Suwiti, I.A.P. Apsari. 2017. Protozoa Gastrointestinal *Eimeria auburnensis* dan *Eimeria bovis* Menginfeksi Sapi Bali Betina di Nusa Penida, *Buletin Veteriner Udayana*. 1(9): 112-116.
- Kumar, B., B. R. Maharana, A. Prasad, J. P. Joseph, B. Patel, and J. S. Patel. 2016. Seasonal incidence of parasitic diseases in bovines of southwestern Gujarat (Junagadh), India. *Journal Parasit Disease*. 40(4): 1342-1346.
- Macedo, L. O., M. A. B. Santos, N. M. M. Silva, G. M. M. R. Barros, L. C. Alves, A. Giannelli, R. A. N. Ramos, and G. A. Carvalho. 2019. Morphological and epidemiological data on *Eimeria* species infecting small ruminants in Brazil. *Small Ruminant Research*. 171: 37-41.
- Mumpuni, S., S. Subekti, S. Koesdarto, H. Puspitawati dan Kusnoto. 2007. Penuntun Praktikum Ilmu Penyakit Helminth Veteriner. Edisi 2 Cetakan 3. Fakultas Kedokteran Hewan Universitas Airlangga. Surabaya.
- Om, H., S. Kumar, and P. Singh. 2010. Prevalence of coccidia in the Mathura region of Uttarpradesh. *Veterinary World* 3(11):503-505.
- Purwanta, N. R. P Ismaya, dan Burhan. 2006. Penyakit Cacing Hati (Fasciolosis) pada Sapi Bali di Perusahaan Daerah Rumah Potong Hewan (RPH) Kota Makassar. *Journal Agrisistem*. 5(1):10-21.
- Rophi, A. H. 2015. Identifikasi cacing parasit dan prevalensinya pada ternak kambing di Kelurahan Koya Barat, Distrik muara tami, kota jayapura, provinsi papua. *Novae Guinea Jurnal Biologi*. 6.
- Southwell, J., C. Fisk, and N. Sallur. 2008. Internal Parasite Control in Sheep. Reference Manual. Deborah Maxwell, DPI, and Queensland F, editor. Sheep CRC.
- Zalizar, L. 2017. Helminthiasis Saluran Cerna Pada Sapi Perah. *Jurnal Ilmu-Ilmu Peternakan*. 27(2): 116-122.

Identification and Prevalence of Digestive Tract Endoparasites of Goats in Ujungpangkah, Gresik District

ORIGINALITY REPORT

11%

SIMILARITY INDEX

10%

INTERNET SOURCES

4%

PUBLICATIONS

0%

STUDENT PAPERS

PRIMARY SOURCES

| | | |
|---|--|-----|
| 1 | download.garuda.kemdikbud.go.id Internet Source | 3% |
| 2 | adoc.pub Internet Source | 2% |
| 3 | www.longdom.org Internet Source | 1% |
| 4 | www.hilarispublisher.com Internet Source | 1% |
| 5 | repository.upenn.edu Internet Source | 1% |
| 6 | pathofscience.org Internet Source | 1% |
| 7 | www.scielo.br Internet Source | 1% |
| 8 | jonuns.com Internet Source | <1% |
| 9 | 123dok.com Internet Source | <1% |

10 Reza Kheirandish, Saeid R. Nourollahi-Fard, Zeinab Yadegari. "Prevalence and pathology of coccidiosis in goats in southeastern Iran", *Journal of Parasitic Diseases*, 2012
Publication <1 %

11 www.iosrjournals.org
Internet Source <1 %

12 Poedji Hastutiek, Nunuk Dyah Retno Lastuti, Lucia Tri Suwanti, Agus Sunarso et al. "Coproparasitological examinations and molecular determination of Eimeria species in Madura cattle reared on Madura Island, Indonesia", *Parasitology International*, 2022
Publication <1 %

13 jurnal.fp.unila.ac.id
Internet Source <1 %

Exclude quotes Off

Exclude matches Off

Exclude bibliography On

Identification and Prevalence of Digestive Tract Endoparasites of Goats in Ujungpangkah, Gresik District

GRADEMARK REPORT

FINAL GRADE

/0

GENERAL COMMENTS

Instructor

PAGE 1

PAGE 2

PAGE 3

PAGE 4
