

Profile of Chronic Suppurative Otitis Media Complication in Indonesian Patients Review of 25 Cases

by Artono Artono

Submission date: 06-Apr-2022 05:58AM (UTC+0800)

Submission ID: 1802795776

File name: Media_Complication_in_Indonesian_Patients_Review_of_25_Cases.pdf (1.25M)

Word count: 3320

Character count: 18026

Profile of Chronic Suppurative Otitis Media Complication in Indonesian Patients: Review of 25 Cases

Artono^{1*}, Titiek Hidayati Ahadiyah¹, Rosydiah Rahmawati¹, Nyilo Purnami¹, Edi Handoko²

¹Department of Otorhinolaryngology Head and Neck Surgery, Faculty of Medicine, Universitas Airlangga – Dr. Soetomo General Academic Hospital, Surabaya, Indonesia

²Department of Otorhinolaryngology Head and Neck Surgery, Faculty of Medicine, Universitas Brawijaya – Dr. Saiful Anwar General Hospital, Malang, Indonesia

*Corresponding Author: Artono

Email: artono@fkg.unair.ac.id

ABSTRACT

Background: The number of CSOM complications is increasing every year, especially in developing countries. Indonesia is a developing country with a large population and a large number of CSOM cases.

Objectives: Analysing the profile of CSOM patients with complications in 2017-2018.

Methods: Participants in this study were CSOM patients with complications who underwent surgery in the 2017-2018 period. Participants in this study were divided into 2 groups based on the year of complications. They were identified for demographic data, types of complications, clinical symptoms and comorbid symptoms at admission, radiology, intraoperative findings, and complications. The statistical tests used in this study included Chi Square test, Mann-Whitney test, and Kruskal-Wallis.

Results: The average participant's age was 28.84 ± 15.40 years ($p = 0.468$), with the most in the age range of 11-25 years (48.00%). Most of them were male (76.00%) ($p = 0.364$), high school-educated (48.00%), came from Western Indonesia (76.00%), and students (40.00%). Clinical symptoms were otorrhea and ear pain (68.00%). All participants had cholesteatoma and 60.00% had atticointral perforation in eardrum. Most CSOM complications in 2017 and 2018 was extracranial (55.56%; $p = 1.000$ and 70.59%; $p = 0.785$, respectively). There was no significant comparison between the number of CSOM complications in 2017 and 2018 ($p = 0.326$). Surgical procedures used canal wall down tympanoplasty.

Conclusion: Subperiosteal abscess is the most common extracranial complication, while brain abscess is the most common intracranial complication of CSOM in this study.

Keywords: Cholesteatoma, CSOM complications, extracranial, intracranial

Correspondence:

Artono

Department of Otorhinolaryngology Head and Neck Surgery, Faculty of Medicine, Universitas Airlangga – Dr. Soetomo General Academic Hospital, Surabaya, Indonesia

Email: artono@fkg.unair.ac.id

16

BACKGROUND

Chronic suppurative otitis media (CSOM) with cholesteatoma is one of the most common health problems that can cause morbidity and mortality [1] and must be treated with caution due to possible severe complications [2]. Complications related to CSOM have been greatly reduced by around 0.15-0.04% at the moment. Meanwhile, deaths due to CSOM complications can be reduced from 25% to 8% [3,4]. Even though the incidence of otitis media complications has decreased, life-threatening complications still exist [3].

The above condition applies to developed countries with better socio-economic conditions and health service. However, in developing countries, this condition still causes concern [5,6]. CSOM complications are classified into two, namely extracranial and intracranial. Extracranial complications include mastoid abscesses, petrositis, labyrinthitis, facial nerve paralysis (FNP), and Bezold abscesses. Intracranial complications consist of intracranial abscesses, including extradural, epidural, subdural, perisigmoid sinuses, and brain abscesses; lateral sinus thrombophlebitis (LST), meningitis, and otitic hydrocephalus [2,3].

Dr. Soetomo General Academic Hospital Surabaya, Indonesia, is the main referral hospital in East Java and Eastern Indonesia. The number of CSOM complications the hospital treats every year has increased. Based on this description, the researchers were interested in analysing CSOM patients with complications who visited the hospital.

METHODS

Participants in this study were CSOM patients with complications who underwent surgery in the 2017-2018 period. Participant's inclusion criteria included patients diagnosed with CSOM [1], experienced intracranial and / or extracranial complications [2,3]. Meanwhile, patients with complications caused by other diseases were excluded in this study. Participants received an explanation of the purpose of the study, and those who agreed had filled out the informed consent sheet.

This study employed an observational analysis design with total sampling conducted from 2017 to 2018. The number of participants in this study was 25 participants from 1,618 CSOM patients. Participants in this study were divided into 2 groups based on the year of complications. Participants were identified for demographic data, types of complications, clinical symptoms and accompanying symptoms at admission, radiology and intraoperative findings. This research was conducted in accordance with the ethical test in accordance with the Declaration of Helsinki in Dr. Soetomo General Academic Hospital, Surabaya, Indonesia.

Measurement data were presented in the form of tables and figures. Measurement data were analyzed using IBM SPSS Statistics software version 23.0 (IBM Corp., Armonk, NY, USA). The results were significant if $p < 0.05$. The statistical test used to compare gender was using the chi square test, while age used the Mann-Whitney test. Statistical tests in both the IC and EC groups used the Kruskal-Wallis test.

RESULTS

The average participant's age was 28.84 ± 15.40 years, with a median value of 25.00 (17.00-39.00) years. The youngest participant was 10.00 years old, and the oldest was 67 years old. In 2018, the average participant's age was 30.56 ± 16.78 years, with a median value of 25.50 (17.25-39.50) years. Meanwhile in 2017, the average participant's age was 25.78 ± 12.94 years, with a median value of 21.00 (17.00-33.00) years with $p = 0.468$. Participants were divided into 4 age groups as follows: 1-

10 years (4.00%), 11-25 years (48.00%), 26-45 years (32.00%), and >46 years (16.00%). In 2017, most participants were found in the age range of 11-25 years (44.44%), followed by 26-45 years (33.33%). Meanwhile, the age distribution in 2018 was similar to 2017, with most participants were found in the age range of 11-25 years (50.00%) and followed by 26-45 years (31.25%). Most participants were male (76.00%), consisting of 88.89% male patients in 2017 and 68.75% in 2018 ($p = 0.364$; Table 1).

Table 1. Demographic Characteristics

Variable	2017 (%)	2018 (%)	p
Sex			
Male	8 (88.89)	11 (68.75)	0.364
Female	1 (11.11)	5 (31.25)	
Age			0.468
0-10	1 (11.11)	0 (0.00)	
11-25	4 (44.44)	8 (50.00)	
26-45	3 (33.33)	5 (31.25)	
>46	1 (11.11)	3 (18.75)	
Education			-
Elementary school	1 (11.11)	4 (25.00)	
Junior high school	0 (0.00)	6 (37.50)	
Senior high school	7 (77.78)	5 (31.25)	
Undergraduate	1 (11.11)	1 (6.25)	
Area of origin			-
Western Indonesia	7 (77.78)	12 (75.00)	
Central Indonesia	2 (22.22)	1 (6.25)	
Eastern Indonesia	0 (0.00)	3 (18.75)	
Occupation			-
Housewife	1 (11.11)	3 (18.75)	
Employee	1 (11.11)	2 (12.50)	
Student	3 (33.33)	7 (43.75)	
Farmer	3 (33.33)	3 (18.75)	
Entrepreneur	1 (11.11)	1 (6.25)	

Most participants were high school graduates (48.00%), followed by junior high school (24.00%). In 2017, most participants were high school graduates (77.78%). Whereas in 2018, most participants were junior high school graduates (37.50%), followed by high schools (31.25%). Most participants came from Western Indonesia (76.00%; 77.78% in 2017; 75.00% in 2018),

including Bangkalan, Blitar, Gresik, Jombang, Malang, Palangkaraya, Sidoarjo, and Surabaya. Participants were mostly students (40.00%), followed by farmers (25.00%). In 2017, most participants were students and farmers as much as 33.33% each. Meanwhile, in 2018 most participants were students as much as 43.75% (Table 1).

Table 2. Clinical symptoms and signs of chronic suppurative otitis media with complications

Variable	n (%)
Symptom	
Ear Discharge	25 (100.00)
Ear Pain	17 (68.00)
Accompanying condition	
Hearing Loss	25 (100.00)
Facial Palsy	4 (16.00)
Headache	6 (24.00)
Vertigo	3 (12.00)
Pain Behind the Ear	3 (12.00)
Tinnitus	10
Sign	
Attico antral perforation in eardrum	15 (12.00)
Tubotympanic Perforation in eardrum	7 (28.00)
Posterior marginal Perforation in eardrum	3 (12.00)
Cholesteatoma	25 (100.00)
Granulation Tissue	18 (72.00)
Schuller's X-ray mastoid	
Destruction	5 (20.00)
Sclerotic	15 (60.00)
Not describe	5 (20.00)

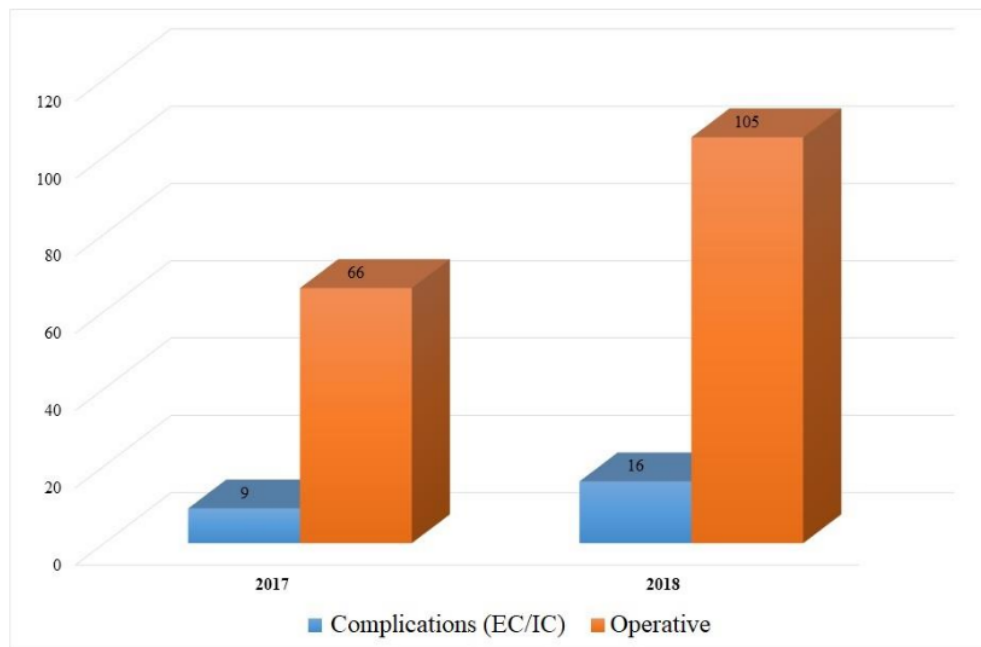


Figure 2. Comparison of the number of patients undergoing CSOM surgery with CSOM patients with complications

Participants had various clinical symptoms. Most of them had otorrhea and pain in the ear (68.00%). All subjects experienced accompanying symptoms of hearing loss and followed by tinnitus (40.00%). Results of Schuller's x-ray mastoid showed that most of the participants were sclerotic (60.00%). A common sign experienced by participants was cholesteatoma, followed by atticoinal perforation in eardrums (60.00%; Table 2). The number of patients experiencing CSOM with complications in 2017 was 13.64% of 66 cases and 15.24% of 105 cases in

2018 (Figure 1). All complications had cholesteatoma in the unilateral ear. Comparison of CSOM complications in 2017 found that most participants (55.56%; $p = 1,000$) experienced extracranial complications. Meanwhile in 2018, most participants experienced extracranial complications as much as 70.59% ($p = 0,785$; figure 2). There was no significant comparison between the number of CSOM complications between 2017 participants and 2018 participants ($p = 0,326$; Table 3).

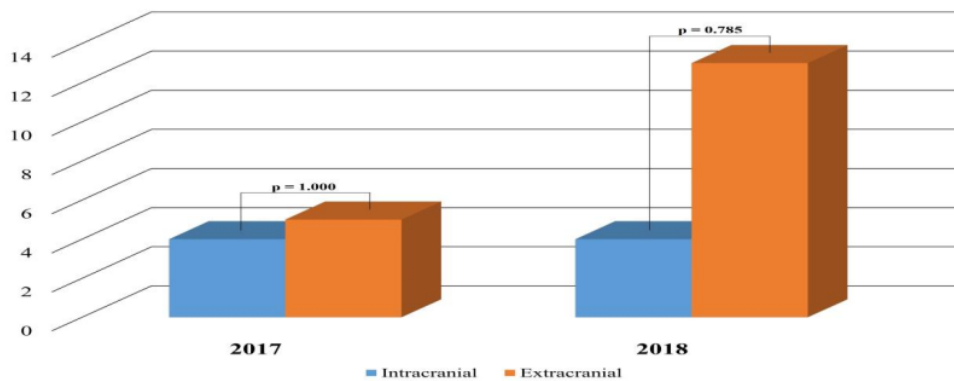


Figure 2. Comparison of CSOM patients with complications in 2017-2018.

Table 3. Distribution of CSOM Complications

Komplikasi	2017	2018	<i>p</i>
Extracranial			
Sub periosteal abscess	3 (33.33)	9 (56.25)	0.326
Paresis Nerves VII	0 (0.00)	3 (18.75)	
Peripheral labyrinthitis	2 (22.22)	1 (6.25)	

Intracranial			
Cerebral abscess	1 (11.11)	3 (18.75)	
Cerebellum abscess	3 (33.33)	0 (0.00)	
Noncommunicating hydrocephalus	1 (11.11)	0 (0.00)	
Sigmoid Sinus Thrombosis + Jugular Vein	0 (0.00)	1 (6.25)	

All cases were given pharmacotherapy treatment and Canal wall down tympanoplasty was performed. The results of pathological tissue eradication showed

participant with dry ears as much as 76.00%, followed by graft take as much as 68.00% (Table 4).

Table 4. Result of Pathological Tissue Eradication and Graft Take Postoperative

Pathological Tissue Eradication	n (%)
Dry Ear	19 (76.00)
Wet Ear	4 (16.00)
Not Describe	2 (8.00)
Graft Take	n (%)
Grow	17 (68.00)
Gap	6 (24.00)
Not Describe	2 (8.00)

DISCUSSION

The frequency of CSOM complications has decreased dramatically with the widespread availability of effective antibiotics, especially in developed countries. However, the situation is different in developing countries, especially for disadvantaged groups with limited access to health service [7]. CSOM complications can involve people of all ages and genders. In this study, the average participant's age was categorised in young adult, and the most cases were found in the age group of <40 years. CSOM is currently common in children, adolescents and young adults, and complications are also more common in this age group [5,8].

This study found that CSOM complications occurred more in male participants than female [3,8-10]. This result corresponds to several other studies. The ratio of CSOM complication cases in men and women is 3:1 [8]. The ratio of CSOM complications between men and women in India is 3: 2. The incidence of autogenic complications is specifically more common in men than women. This is because in general, men have a distinctive character and tend to ignore the complaints they experience and assume that complaints are not serious. Men are also included in the group who like to try new things, are more prone to injury and infection in their daily activities [3].

Most participants in this study were high school graduates. Education has a significant relationship with the social economy of individuals. Previous research stated a significant relationship between education and socio-economic conditions of CSOM patients in developing countries [11]. Low socioeconomic conditions limit the ability of individuals to access quality health services [12]. Low education makes the level of knowledge and ability of individuals to understand new information related to CSOM postoperative care at home is limited and they tend to go to health services when the complication condition is already severe [11,12].

All participants complained of ear discharge and ear pain, with common comorbid complaints of hearing loss and headaches. There are several studies mentioning similar findings [7,10]. All participants experienced more unilateral and extracranial complications compared to intracranial. Extracranial complications in CSOM cases occur more in accordance with some existing reports. One study in 21 countries stated that extracranial complications are still dominant [13]. A similar condition

was also found in postoperative canal wall down mastoidectomy patients in the period 1996 to 2006 in Papua New Guinea [8]. The most complications mentioned by references are facial palsy and extratemporal abscesses [2,8,13]. Frequency of facial nerve paralysis in CSOM reported ranges from 0.16 to 5.1% [14]. All participants with facial nerve paralysis were found to have bone erosion or dehiscence of the facial canal in the tympanic pars. All damage is caused by cholesteatoma. Cholesteatoma directly destroys bones and triggers inflammation and suppresses facial nerve itself. CSOM with cholesteatoma is the most common cause of facial nerve paralysis [7,15,16].

Intracranial complications often found in the participant were cerebral abscess, cerebellum abscess, and sigmoid sinus thrombosis. These findings correspond to some other studies [17]. Brain abscess is the most challenging complication of CSOM. The brain areas that are frequently affected by abscess complications are the temporal lobe and cerebellum [18].

Based on the management of CSOM complications in this study, parenteral antibiotics were given preoperatively for all patients. Parenteral antibiotics help control the process of infection before the surgical procedure. Cholesteatoma is the main surgical finding in CSOM complication. Granulation tissue also has a major role in the spread of intracranial disease [19]. In the case of CSOM, cholesteatoma is a major risk factor which postoperatively can cause severe intracranial complications [7].

Surgery is carried out in two stages. The first stage of drainage surgery must be performed by neurosurgery, and then in the same setting, canal wall down tympanoplasty must be performed. The choice of therapy was also carried out by several other researchers. The purpose of these surgeries is for live saving and achieving dry ear [20]. In otogenic intracranial abscesses, a multidisciplinary approach is essential to reduce the risk of death [18].

This research is used as a reference to identify increasing CSOM problems at Dr. Soetomo General Academic Hospital, Surabaya, Indonesia. Therefore, further study is needed for bacterial culture to determine the causative agent of CSOM complications. The goal is for the efficiency and effectiveness of CSOM management in Indonesia.

CONCLUSION

CSOM can still cause both intra and extracranial complications. Rapid diagnosis, medical and surgical treatment are needed to reduce morbidity. This study found that subperiosteal abscess is the most common extracranial complication, while brain abscess is the most common intracranial complication.

ACKNOWLEDGEMENT

We would like to thank our research assistance, Fis Citra Ariyanto for manuscript editor and Sakinah Ramadhani for helped us in collecting data and assisting in translating our manuscripts.

CONFLICT OF INTEREST

The authors declare that they have no conflict of interest this publication.

FUNDING

None

Authors' Contribution

The authors contributed toward data analysis, drafting and revising the paper, gave final approval of the version to be published and agree to be accountable for all aspects of the work.

REFERENCES

1. Artono, Surarto B, Purnami N, Hutahaen F, Mahardhika MR (2020) The Association of IL-1 Alpha Level and TNF Alpha Expressions on Bone Destruction in Chronic Suppurative Otitis Media and Cholesteatoma. *Indian Journal of Otolaryngology and Head & Neck Surgery* 72 (1):1-7. doi:10.1007/s12070-019-01704-z
2. Yorgancilar E, Yildirim M, Gun R, Bakir S, Tekin R, Gocmez C, Meric F, Topcu I (2013) Complications of chronic suppurative otitis media: a retrospective review. *European Archives of Oto-Rhino-Laryngology* 270 (1):69-76. doi:10.1007/s00405-012-1924-8
3. Sharma N, Jaiswal AA, Banerjee PK, Garg AK (2015) Complications of Chronic Suppurative Otitis Media and Their Management: A Single Institution 12 Years Experience. *Indian Journal of Otolaryngology and Head & Neck Surgery* 67 (4):353-360. doi:10.1007/s12070-015-0836-5
4. Lin YS, Lin L-C, Lee F-P, Lee KJ (2009) The prevalence of chronic otitis media and its complication rates in teenagers and adult patients. *Otolaryngology - Head and Neck Surgery* 140 (2):165-170. doi:https://doi.org/10.1016/j.otohns.2008.10.020
5. Dubey SP, Larawin V, Molumi CP (2010) Intracranial spread of chronic middle ear suppuration. *American Journal of Otolaryngology* 31 (2):73-77. doi:https://doi.org/10.1016/j.amjoto.2008.10.001
6. Deb T, Ray D (2012) A study of the bacteriological profile of chronic suppurative otitis media in agartala. *Indian J Otolaryngol Head Neck Surg* 64 (4):326-329. doi:10.1007/s12070-011-0323-6
7. Ahmed Z, Khan TZ, Rahim DU (2016) Otogenic complications of otitis media: experience at tertiary care hospital. *Pak J Surg* 32 (1):49-53
8. Dubey SP, Larawin V (2007) Complications of Chronic Suppurative Otitis Media and Their Management. *The Laryngoscope* 117 (2):264-267. doi:10.1097/01.mlg.0000249728.48588.22
9. Wahid FI, Khan A, Khan IA (2014) Complications of chronic suppurative otitis media: challenge for a developing country. *Kulak burun bogaz ihtisas dergisi : KBB = Journal of ear, nose, and throat* 24 (5):265-270. doi:10.5606/kbbihtisas.2014.14477
10. Memon M, Thaheem K, Marfani MS (2005) Frequency and complications of cholesteatoma in cases of chronic suppurative otitis media. *Pak J Otolaryngol* 21:48-49
11. Maggon NV, Sethi A, Pimparkar SV (2018) Do Socio-Economic Factors Play a Role in Delayed Presentation of Complicated Chronic Otitis Media (Squamous)? *Bengal Journal of Otolaryngology and Head Neck Surgery* 26 (1):16-22
12. S H C, M M K, Handi P, Khavasi P, Doddmani SS, Riyas M (2014) To Study the Level of Awareness About Complications of Chronic Suppurative Otitis Media (CSOM) in CSOM Patients. *J Clin Diagn Res* 8 (2):59-61. doi:10.7860/JCDR/2014/8009.4008
13. Mostafa BE, El Fiky LM, El Sharnoubi MM (2009) Complications of Suppurative Otitis Media: Still a Problem in the 21st Century. *ORL* 71 (2):87-92. doi:10.1159/000191472
14. Kim J, Jung G-H, Park S-Y, Lee WS (2012) Facial nerve paralysis due to chronic otitis media: prognosis in restoration of facial function after surgical intervention. *Yonsei Med J* 53 (3):642-648. doi:10.3349/ymj.2012.53.3.642
15. Chan K-C, Wang P-C, Chen Y-A, Wu C-M (2011) Facial nerve dehiscence at mastoidectomy for cholesteatoma. *The Journal of International Advanced Otolaryngology* 7 (3):311
16. Yetiser S, Tosun F, Kazkayas M (2002) Facial Nerve Paralysis Due to Chronic Otitis Media. *Otolaryngology & Neurotology* 23 (4):580-588
17. Datta G, Baisakhiya N (2014) Unsafe CSOM still a challenge in rural areas. *Otolaryngology online journal* 4 (2)
18. Penido NDO, Borin A, Iha LCN, Suguri VM, Onishi E, Fukuda Y, Cruz OLM (2005) Intracranial complications of otitis media: 15 years of experience in 33 patients. *Otolaryngology-Head and Neck Surgery* 132 (1):37-42. doi:10.1016/j.otohns.2004.08.007
19. Khan A, Khan MI, Marwat M (2012) Intracranial complications of chronic suppurative otitis media: clinical presentation and outcome of surgical procedures. *Gomal Journal of Medical Sciences* 10 (2)
20. Sennaroglu L, Sozeri B (2000) Otogenic brain abscess: Review of 41 cases. *Otolaryngology - Head and Neck Surgery* 123 (6):751-755. doi:https://doi.org/10.1067/mhn.2000.107887

Profile of Chronic Suppurative Otitis Media Complication in Indonesian Patients Review of 25 Cases

ORIGINALITY REPORT

18%

SIMILARITY INDEX

13%

INTERNET SOURCES

15%

PUBLICATIONS

1%

STUDENT PAPERS

PRIMARY SOURCES

- 1** Smitha B, Swapna U.P, Salilkumar K. "Evaluation of Bacteriological Profile in Active Mucosal Chronic Otitis Media - A Cross-Sectional Study", Journal of Evidence Based Medicine and Healthcare, 2021
Publication 1%
- 2** Zainab Zuhair Ali, Fatimah J. Al-Hasani. "Evaluation of Surface Roughness of Some Biomedical Titanium Alloys by Pack Cementation Coating", Key Engineering Materials, 2021
Publication 1%
- 3** www.thieme-connect.com
Internet Source 1%
- 4** link.springer.com
Internet Source 1%
- 5** www.inabj.org
Internet Source 1%
- 6** journals.lww.com
Internet Source 1%

7	Yeoh T. Long, Ridzo Mahmud, A. Sani, Lokman Saim. "Complications of Otitis Media Requiring Surgical Intervention", Asian Journal of Surgery, 2002 Publication	1 %
8	Sally Mahdiani, Lina Lasminingrum, Bambang Purwanto, Riri Handayani. "Canal wall down in tuberculosis matoiditis: 4 case series", International Journal of Surgery Case Reports, 2021 Publication	1 %
9	Jung, T. T. K., C. M. Alper, S. O. Hellstrom, L. L. Hunter, M. L. Casselbrant, A. Groth, Y. K. Kemaloglu, S. G. Kim, D. Lim, S. Nittrouer, K. H. Park, D. Sabo, and J. Spratley. "Panel 8: Complications and Sequelae", Otolaryngology - Head and Neck Surgery, 2013. Publication	1 %
10	journals.sagepub.com Internet Source	1 %
11	fik.umpr.ac.id Internet Source	1 %
12	synapse.koreamed.org Internet Source	1 %
13	Rama Chandra Rao V, Srilatha K, Visweswara Rao S, Manohar K N. "MICROBIOLOGICAL	1 %

STUDY OF EAR DISCHARGE AND THEIR
ANTIBIOTIC SENSITIVITY PATTERN IN
CHRONIC SUPPURATIVE OTITIS MEDIA",
Journal of Evolution of Medical and Dental
Sciences, 2014

Publication

14

pdfs.semanticscholar.org

Internet Source

1 %

15

Salah Mansour, Jacques Magnan, Karen
Nicolas, Hassan Haidar. "Chapter 9
Complications of Chronic Otitis Media",
Springer Science and Business Media LLC,
2018

Publication

1 %

16

academic-accelerator.com

Internet Source

1 %

17

www.manuscriptmodule.com

Internet Source

1 %

18

Jin Kim. "Facial Nerve Paralysis due to Chronic
Otitis Media: Prognosis in Restoration of
Facial Function after Surgical Intervention",
Yonsei Medical Journal, 2012

Publication

<1 %

19

www.research.manchester.ac.uk

Internet Source

<1 %

20

Lin, J.C.. "Incidence of dehiscence of the facial
nerve at surgery for middle ear

<1 %

cholesteatoma", Otolaryngology - Head and Neck Surgery, 200410

Publication

21 www.scilit.net <1 %
Internet Source

22 cyberleninka.org <1 %
Internet Source

23 gs.amegroups.com <1 %
Internet Source

24 www.e-aps.org <1 %
Internet Source

25 www.hindawi.com <1 %
Internet Source

26 www.rjor.ro <1 %
Internet Source

27 Dian Maharani, Widiana Ferriastuti. "Chronic suppurative otitis media complicated by subdural and Bezold abscesses: A case report", Radiology Case Reports, 2022 <1 %
Publication

Exclude quotes On

Exclude matches Off

Exclude bibliography On

Profile of Chronic Suppurative Otitis Media Complication in Indonesian Patients Review of 25 Cases

GRADEMARK REPORT

FINAL GRADE

/100

GENERAL COMMENTS

Instructor

PAGE 1

PAGE 2

PAGE 3

PAGE 4

PAGE 5
