

## A High Sucrose Diet Affects Calcium Levels and the Number of Osteoblasts in the Wistar Rat Extraction Socket

Christian Khoswanto<sup>1\*</sup>

1. Department of Oral Biology Faculty of Dentistry, Airlangga University Surabaya – Indonesia.

### Abstract

The important role from wound regeneration is the availability of sufficient calcium minerals for the process of mineralization in the bone after tooth extraction. Bone in the mandibulocraniofacial complex is a process of intramembranous ossification, which originally originated from mesenchymal connective tissue. Several studies have shown the role of a diet high in sucrose capable of causing bone loss, promoting osteoclast differentiation and bone resorption. A high diet of sucrose is also able to increase calcium levels in plasma, increasing calcium levels in urine.

The purpose of this research is to know the effect of a high sucrose diet affects calcium levels and the number of osteoblasts in the Wistar rat extraction socket. This study is an experimental laboratory research using The Post-Test Only Control Group Design. 40 male Wistar Rats weigh between 150-200 grams, 3 months of age are being used. Have well condition, food and drink water given ad libitum. The 40 rats are divided into four groups. The data were analyzed statistically using One-Way ANOVA and LSD0.05. Result: The result at 30 day examined via a light beam that is transmitted through the tissue using image magnified 400 times shows a significant decrease ( $p < 0.05$ ) in amount number of osteoblast and bone calcium level when the experimental groups (T3) were compared with the control group (C), T1 and T2.

High sucrose diet decreasing the number of osteoblasts and alveolar bone calcium contents in the Wistar rat extraction socket.

Experimental article (J Int Dent Med Res 2020; 13(1): 134-137)

**Keywords:** Sucrose diet, bone calcium, osteoblast.

**Received date:** 04 May 2019

**Accept date:** 20 October 2019

### Introduction

Tooth extraction is the removal of a tooth from its socket in the bone from the maxilla or mandible, due to tooth decay caused by several factors, such as endodontic treatment failure, advance periodontitis disease, caries that cannot be treated and tooth trauma. This action will cause wound to the alveolar socket. The wound will go through several stages in achieving recovery, including stages of hemostasis, inflammation, proliferation and remodeling.<sup>1</sup>

The important role from wound regeneration is the availability of sufficient calcium minerals for the process of mineralization in the bone after tooth extraction.

Bone in the mandibulocraniofacial complex is a process of intramembranous ossification, which originally originated from mesenchymal connective tissue. This bone complex is very important and is a dynamic organ, the mandibulocraniofacial skeletal structure consists of the outer cortical layer which is part of the bone found on the outer surface for skeletal strength and the inner structure is the inner cancellous layer which plays a role in bone metabolism. Mandibulocraniofacial bone is a high vascularized bone tissue. Bone vasculature plays an important role in regulating the balance in the process of bone homeostasis. Bone vasculature besides providing oxygen and nutrients, it also produces cellular progenitors which play an important role in bone repair.<sup>2</sup>

Bone forming cells are needed for the process of osteogenesis in the process of bone healing. Osteoprogenitor cells respond to molecular stimuli that convert these cells to bone-forming cells. Osteoprogenitor cells come from mesenchymal stem cells in the bone marrow

#### \*Corresponding author:

Christian Khoswanto, c/o: Department of Oral Biology Faculty of Dentistry, Airlangga University. Jln. Mayjend. Prof. Dr. Moestopo No. 47 Surabaya 60132, Indonesia.  
Email : christiankhoswanto@hotmail.com

which have the potential way to differentiate into many different cells, such as fibroblasts, osteoblasts, cartilage cells and muscle cells. Osteoprogenitor cells are found in the external and internal surfaces of the bone and some in the microvascular part that supply bone. These cells include periosteal cells from the inner layer, and endosteal cells in the marrow cavity, haversian canal and volkmann's canal.<sup>3</sup>

Several studies have shown the role of a diet high in sucrose capable of causing bone loss, promoting osteoclast differentiation and bone resorption. A high diet of sucrose is also able to increase calcium levels in plasma, increasing calcium levels in urine. Previous studies have suggested that a diet high in sucrose has an adverse effect on bone, but there is no description how this high sucrose diet affects the alveolar bone following tooth extraction in wistar rats.

The purpose of this research is to know the effect of a high sucrose diet affects calcium levels and the number of osteoblasts in the Wistar rat extraction socket.

### Materials and methods

This study is an experimental laboratory research using The Post-Test Only Control Group Design. 40 male *Wistar Rats* weigh between 150-200 grams, 3 months of age are being used. Have well condition, food and drink water given ad libitum. All animal procedures were approved by the University of Airlangga Surabaya Animal Care and Use Committee. This animal is used because tooth extraction on *Wistar Rats* is easier with less complication.

The choosing of lower incisor is based on the structure and anatomical form of Rat's teeth which enable extraction to be done. The rats were randomly divided into 4 groups (each with 8 rats). Group 1 (C, control group), Group 2 (T1, Treatment group 1) 10% energy supplied from sucrose, Group 3 (T2, Treatment group 2) 20% energy supply from sucrose, Group 4 (T3, Treatment group 3) 40% energy supply from sucrose.

Animal's mandible were decapitated at intervals of 30 days after extraction by median-sagittal cut, samples that had been detached from the body then fixated, Buffered isotonic solution of 10% formaldehyde was used for fixatives. 96% ethanol was used to extracted the

water from the fragment. The ethanol then replaced with a solvent miscible with the embedding medium. In paraffin embedding, the solvent used is xylene. Once the tissue is impregnated with the solvent, it is placed in melted paraffin in the oven at 58-60°C. The heat causes the solvent to evaporate, and the space within the tissue become filled with paraffin. The tissue together within its impregnating paraffin hardens taken out of the oven. Tissues embedded with plastic resin dehydrated in ethanol. The hard blocks containing the tissues are then taken to a microtome, and sliced into thin sections 4-5µm. The sections are floated on water and transferred to glass slide to be stained. Under the light microscope (Olympus, JAPAN) tissue are examined via a light beam that is transmitted through the tissue using image magnified 400 times.<sup>6</sup>

The alveolar bone was dissolved with concentrated acid, the fraction obtained was then dissolved in nitric acid and perchlorate with a 5: 2 ratio of 5ml, then diluted with distilled water to 50ml. The solution is left for 24 hours to remove organic compounds and release chemical bonds. The fraction obtained was measured by absorption with atomic absorption spectrophotometer spectr AA 55 in mg / g sample weight.<sup>7-8</sup>

### Results

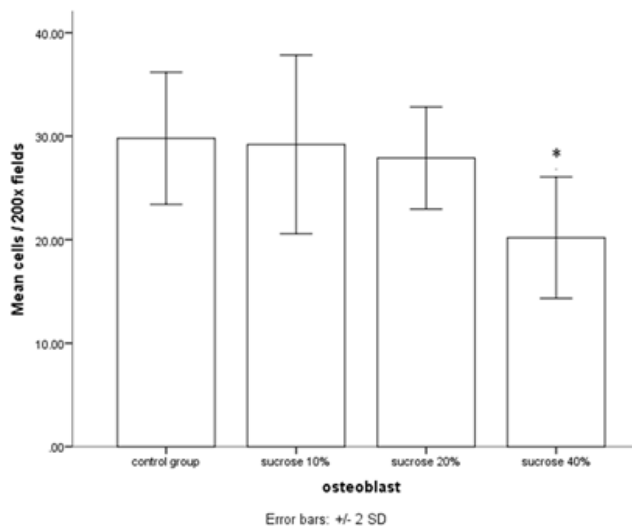
No complications during extraction of *Wistar rat* incisors in this study and none animals died in this experiment from anesthesia and infection. The result at 30 day examined via a light beam that is transmitted through the tissue using image magnified 400 times shows a significant decrease ( $p < 0.05$ ) in amount number of osteoblast when the experimental groups (T3) were compared with the control group (C), T1 and T2. There was no significant ( $p > 0.05$ ) difference between T1 and C, as well as in T2 and C, and T1 and T2 respectively. A significant decrease ( $p < 0.05$ ) in bone calcium level was observed when the experimental groups (T3) were compared with the control group (C), T1 and T2. There was no significant ( $p > 0.05$ ) difference between T1 and C, as well as in T2 and C, and T1 and T2 respectively (Table 1 & 2).

Group	X±SD Day 30
C	29.80 <sup>a</sup> ±2.38
T1	29.20 <sup>a</sup> ±2.98
T2	27.90 <sup>a</sup> ±3.35
T3	20.20 <sup>b</sup> ±3.65

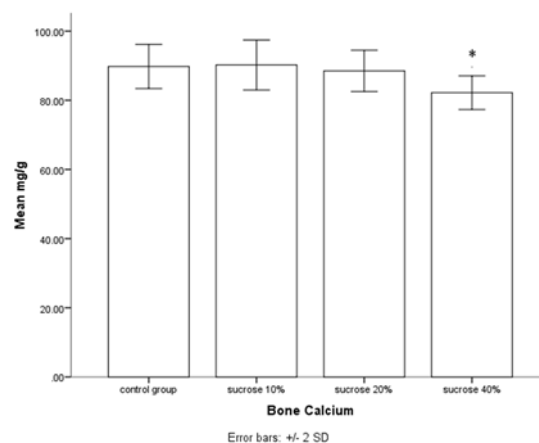
**Table 1.** Histological findings for number of osteoblast in treatment group and control group  
 note: different superscript showed significance difference ( $\alpha < 0.05$ )

Group	X±SD Day 30
C	89.80 <sup>a</sup> ±2.27
T1	90.20 <sup>a</sup> ±3.34
T2	88.50 <sup>a</sup> ±2.58
T3	82.20 <sup>b</sup> ±2.65

**Table 2.** Bone calcium level (mg/g) in treatment group and control group  
 note: different superscript showed a significant difference ( $\alpha < 0.05$ )



**Figure 1.** Data showing the number of Osteoblast per 200 field in treated for 30 days. \* show significant different between control & treatment group ( $P < 0.05$ ).



**Figure 2.** Data showing the number of Bone Calcium (mg/g) in treated for 30 days. \* show significant different between control & treatment group ( $P < 0.05$ ).

### Discussion

There are many factors that can enhance or delay of bone healing. These factors include type of tissue, location and condition of wound, its vascular supply, microbial invasion, and local and systemic factors.<sup>9-11</sup> In the process of wounds healing post tooth extraction, the initial process begins through the formation of vascularization in the wound area, characterized by the presence of HIF1 $\alpha$  and FGF-2 expression, then followed by the formation of alveolar bone through osteoblast cells.<sup>6</sup>

Osteoblasts differentiation and proliferation through the role of Bone Morphogenetic Protein which causes proliferation of mesenchymal cells to differentiate into active osteoblast cells, so that it will improve the alveolar bone better. Osteoblasts are mononucleated cells that synthesize collagen and non-collagen matrix. Osteoblasts originate from mesenchymal cells, producing osteoid or bone matrix, round, oval or polyhedral, separate from the matrix that has undergone mineralization. Osteoblasts have the function of being able to synthesize and secrete bone organic matrix, regulating electrolyte changes in extracellular fluid in the mineralization process. Osteoblasts contain endoplasmic reticulum, golgi membrane and mitochondria.<sup>9-10</sup> Alveol bone is a tissue that is mineralized with a composition of 28% collagen type I and 5% non collagen types such as bone sialoprotein, osteoclastin, osteonectin, osteopontin and

proteoglycans. Several growth factors and serum proteins are also found in the alveolar bone. Alveolar bones are generally known to be of two types, namely cortical bone and trabecular bone. The outer part of the bone is a solid bone called the bone cortex and the inside is the trabecular bone that is arranged like a sponge.<sup>12</sup>

In this study, a diet high sucrose showed a decrease in the number of osteoblasts and alveolar bone calcium levels through the diet group 40% sucrose (figure 1 & 2), in contrast to study by Salau et al (2014) who declared that a 10% diet of sucrose can reduce bone calcium. Changes in plasma calcium levels that were observed in rats fed with different concentrations of sucrose diet shows that the higher the sucrose intake, the higher the plasma calcium as evidenced.<sup>5</sup> One of the mechanisms suggested on how sucrose rich diet alters serum calcium is by losing calcium in urine. The calciuric effect of sucrose is thought to be the result of reduced tubular reabsorption.<sup>13-14</sup> High glucose levels due to a high sucrose diet, also increase the direct effect of inhibiting osteoblasts, osteoblast cultures exposed to glucose for 7 days show resistance to osteoblast cell growth. It is suspected that glucose causes a decrease in putrescine which is a product of ornithine decarboxylase (ODC). ODC is an enzyme that has an important role in cell growth.<sup>15</sup>

Specific downward trend observed in bone calcium in this study indicated that as sucrose consumption increases, bone calcium reduces, though the only significant reduction ( $p < 0.05$ ) was observed in T3 compared with control group, T1 and T2 (Table 1 & 2). The mineralization of bone requires active metabolic work, Fibroblast Growth Factor-23, parathyroid hormone, phosphate and vitamin D. The effect of decrease in tubular reabsorption may induce bone resorption in order to raise serum calcium.<sup>16-19</sup>

### Conclusions

In this study, 40 % high sucrose diet decreasing the number of osteoblasts and alveolar bone calcium contents in the Wistar rat extraction socket.

### Declaration of Interest

The authors report no conflict of interest and the article is not funded or supported by any research grant.

### References

1. Olczyk P, Mencner L & Vassev KK, The Role of the Extracellular Matrix Components in Cutaneous Wound Healing, *BioMed Research International*, 2014:1-8.
2. Buser D, Guided bone regeneration. 2nd ed. Illinois: Quintessence; 2009:30-55.
3. Tortora GJ, Principles of Anatomy and Physiology, 14th ed. Wiley; 2013:25-86.
4. Dong XL, Li CM, Cao SS, Zhou LP, Wong MS, A High-Saturated-Fat, High-Sucrose Diet Aggravates Bone Loss in Ovariectomized Female Rats, *J Nutr* 2016;146(6):1172-9.
5. Salau BA, Ajani EO, Adebayo OL, Atunnise AK, & Osilesi O. High sucrose diet modulates calcium status in male albino rats: Possible implication on cardiovascular disease and dental caries. *Annals of Biological Sciences*, 2014;2(2):45-50.
6. Khoswanto C, Soehardjo I. The effect of Binahong Gel (*Anredera cordifolia* (Ten.) Steenis) in accelerating the escalation expression of HIF-1 $\alpha$  and FGF-2, *Journal of International Dental and Medical Research*, 2018;11(1):303-7.
7. R. Belcher, A.J. Nutler *Quantitative Inorganic Chemistry: A laboratory manual for students and practicing chemist* 2nd Edition, London: Butterworths; 1960:188-9.
8. Brett EM, Hicks JM, Total calcium measurement in serum from neonates, limitation of current method. *Clin. Chem*, 1981;27(10):1733-7.
9. Hatice Balci Yuçe, Nihat Akbulut, Sibel Akbulut, Kemal Özgür Demiralp, Zafer Karaca and Kaan Orhan. Effect of Ankaferd Blood Stopper on Early Bone Tissue Healing in Extraction Sockets: An Experimental In vivo Study. *Journal of Pharmaceutical Research August* 2015;14(8):1469-73.
10. Young B and Heath, JW, *Functional Histology*, 6th ed, London: Churchill Livingstone; 2013:40-8.
11. Blair HC, Larrouture QC, Li Y, Lin H, Stoltz DB, Liu L, Tuan RS, Robinson LJ, Schlesinger PH & Nelson DJ, Osteoblast Differentiation and Bone Matrix Formation In Vivo and In Vitro. *Tissue Engineering: Part B*, 2017;23(3):268-80.
12. Nanci A, *Oral Histology : Development, Structure and Function*. 8th ed. Missouri: Mosby; 2012:12-60.
13. N.U. Nguyen, G Dumoulin, M.T Henriët, S. Berthelay J. Regnard , Carbohydrate metabolism and urinary excretion of calcium and oxalate after ingestion of polyol sweeteners. *J Clin Endocrinol Metab*, 1993;77(2):388-92.
14. Tja'derhane L, Larmas M, A High Sucrose Diet Decreases the Mechanical Strength of Bones in Growing Rats. *Journal of Nutrition*, 1998;128(10):1807-10.
15. Terada M, Inaba M, Yano Y, Hasuma T, Nishizawa Y, Morii H, Otani S, Growth-Inhibitory effect of a high glucose concentration on osteoblast-like cells. *Bone*, 1998; 22(1):17-23.
16. Lanou AJ, Berkow SE, Barnard ND. Calcium, Dairy Products, and Bone Health in Children and Young Adults: A Reevaluation of the Evidence, *Pediatrics*, 2005;115 (3):736-43.
17. Tejwani V and Qian Q, Calcium Regulation and Bone Mineral Metabolism in Elderly Patients with Chronic Kidney Disease, *Nutrients*, 2013;5(6):1913-36.
18. Ericsson Y, Angman-Månsson B & Flores M. Urinary mineral loss after sugar ingestion. *Bone and Mineral*, 1990;9:233-7.
19. Yiemwattana I, The Promising Clinical Applications of Growth Factors in Periodontal Regeneration: A Literature Review. *Journal of International Dental and Medical Research*, 2017;10(3):1021-8.