

A Rare Case of Angiofibroma Mimicking Fibrous Epulis in Posterior Gingival Mucosa

by Ni Putu Mira Sumarta

Submission date: 23-Mar-2022 12:53PM (UTC+0800)

Submission ID: 1790717988

File name: 2128-Article_Text-48949-1-10-20211124.pdf (1.83M)

Word count: 2019

Character count: 11216

A Rare Case of Angiofibroma Mimicking Fibrous Epulis in Posterior Gingival Mucosa

Annete Nabila, DDS,¹ Ni Putu Mira Sumarta, DMD, PhD¹ and Okky Prasetio, DMD²

ABSTRACT

Angiofibromas are highly vascular, locally aggressive but histologically benign tumors. A 40-year-old woman complaint of pedunculated mass in the right gingiva of the posterior region since 7 months earlier. Surgical excisional biopsy under general anesthesia was performed. Histopathological examination showed an angiofibroma. Angiofibromas are localized in the superficial soft tissue and the gingiva could have a similar clinical appearance as an epulis. Definitive diagnosis was determined through histopathological analysis.

Key Words: Angiofibroma, Fibrous Epulis, Gingival Angiofibroma, Gingival Mucosa

13 INTRODUCTION

Angiofibromas are highly vascular, locally aggressive but histologically benign tumors.¹ In the head and neck region, angiofibromas are most frequently seen in the nasopharynx of male patients aged 7-25 years old with the incidence varying between 0.05 and 0.5%.² Extra nasopharyngeal localization of this tumor is rare. The pathogenesis of angiofibroma is not very clear. These mesenchymal tumors can appear as a result of infection, trauma, hormones, and arteriovenous malformation.³

Diagnosing could be a challenge due to a wide spectrum of various mesenchymal tumors reported in the literature with similar clinical and histological features. This may cause relevant problems with the differential diagnosis because of the tumor's rarity, ambiguous clinical presentation, and histologic features. A definitive diagnosis can be determined through histopathological analysis.

The purpose of this case is to report a case of angiofibroma mimicking fibrous epulis in posterior gingival mucosa. We report an interesting and rare case of angiofibroma involving posterior gingival mucosa treated by surgical excision in a 40-year-old female patient.

CASE REPORT

A 40-year-old woman presented in the Oral and Maxillofacial Clinic of Dr. Mohammad Soewandhie General Hospital, Surabaya, Indonesia with a chief complaint of a pedunculated mass in the lower right gingiva of the posterior region in the past 7 months earlier. In the beginning, it was similar to stomatitis with a red and white color pattern, then it grew larger over the past 5 months. There was no sharp tooth edge or filling. Extraoral examination

Paper presented in the Temu Ilmiah Nasional-Internasional ke-8 (TIMNASS 8).

Corresponding author: Ni Putu Mira Sumarta, DMD, PhD

Email: niputu.mira@fkg.unair.ac.id
niputumira.fkgunair@gmail.com

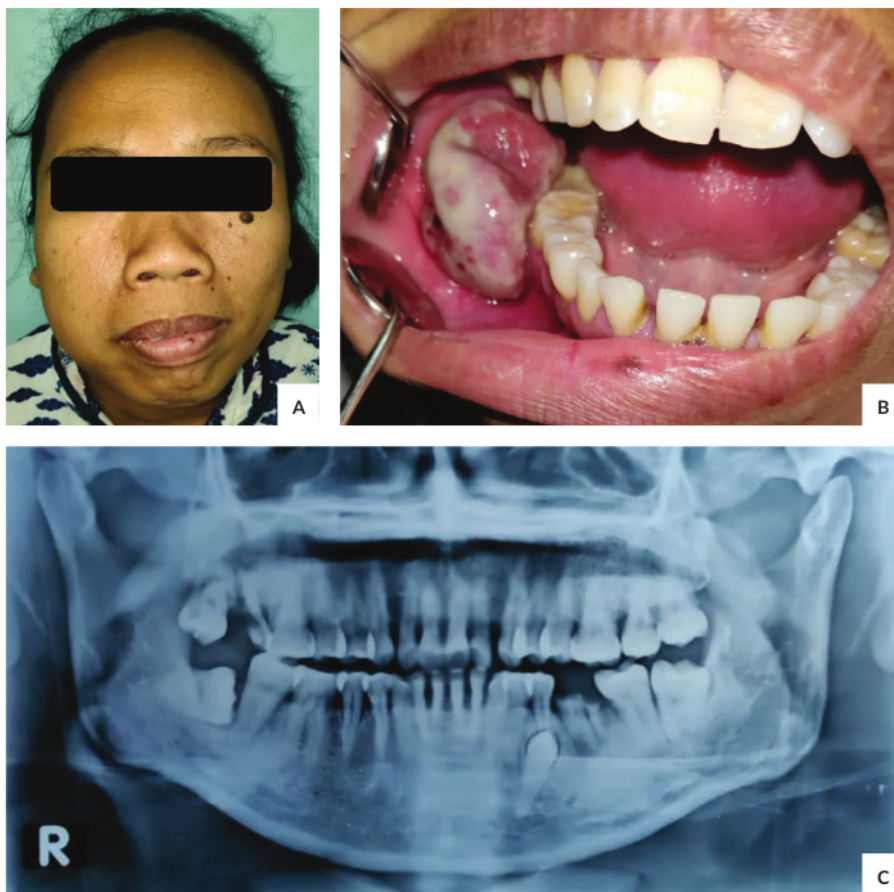

Figure 1. (A) Extraoral clinical view showed an asymmetrical face. (B) The intraoral clinical view showed a pedunculated mass in the right lower gingiva mucosa of the first and second molars region measuring approximately 3x2x1 cm. (C) Panoramic radiograph showed vertical resorption on the alveolar crest on the first and second molar of the right mandible.

showed an asymmetrical face. The overlying skin was normal in color and texture (Figure 1A). Upon palpation, there was a mass on the right side of the mandible with diffuse border and average consistency with no tenderness.

Intraoral examination revealed a pedunculated mass on the right lower gingival mucosa of the first and second molars region measuring about 3x2x1cm (Figure 1B). It was lobulated, showing red and white color pattern covered with a white membrane in some parts of the lesion. Upon palpation, the mass was solid, bled easily, with average consistency, smooth surface, with no tenderness. The first and second molars were mobile. On panoramic view, there was vertical resorption on the alveolar crest of the first and second molars of the right mandible with widened periodontal space (Figure 1C).

Clinical diagnosis of fibrous epulis was made and was confirmed based on cytological analysis using fine-needle

aspiration biopsy. A surgical excisional biopsy was performed under general anesthesia. The mass was ligated from the shaft then excised along with surgical removal of the right mandibular first, second, and third molars (Figure 2). Massive bleeding occurred while removing the mass which was controlled by using electrocautery. The periosteum and periodontal ligament area was then curettage, then sutured with vicryl 4.0. The healing was eventful. The patient was followed up until 4 months with no complaint (Figure 3).

The specimen was submitted for histopathologic analysis. Histopathology revealed a section of tissue covered with stratified squamous epithelium lining (Figure 4). The stroma consists of vascular proliferation with endothelial lining with erythrocytes within its lumen and fibrous cell proliferation with myxomatous degeneration. It was concluded as angiofibroma of the gingiva.

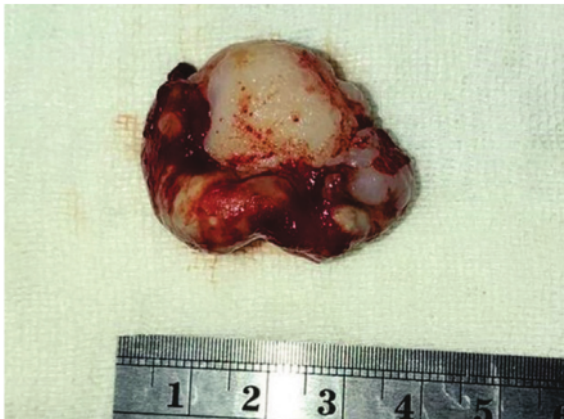


Figure 2. Excised specimen measuring about 3.5x3x2.5 cm with red and white color pattern.

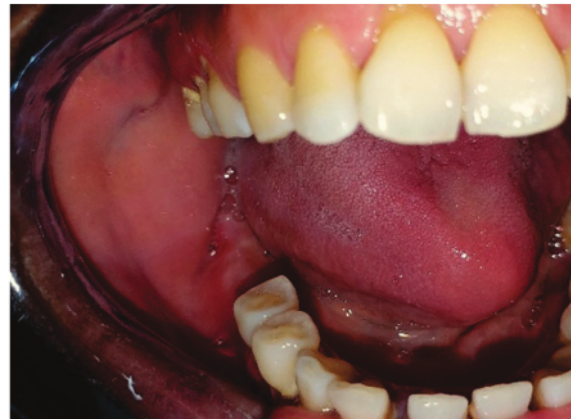

Figure 3. Post-operative view after four months.

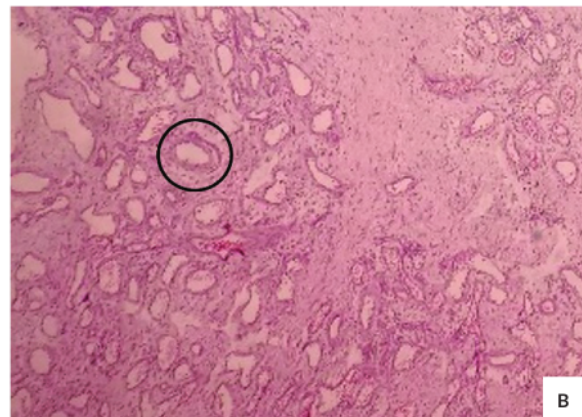
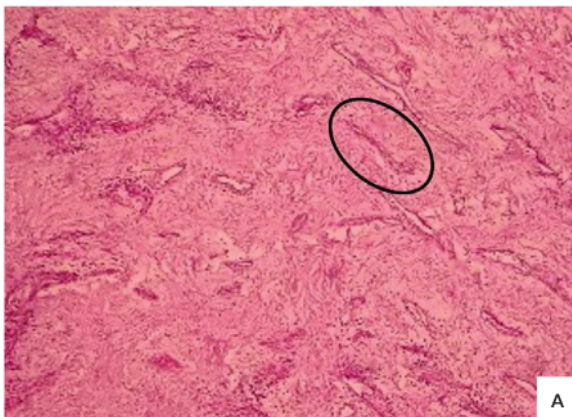


Figure 4. (A) Histopathologic view of fibrous cell proliferation (the oval area) (HE 100x). (B) Histopathologic view of vascular proliferation (the circled area) (HE 400x).

DISCUSSION

¹² Epulis is a relatively frequent benign lesion in the oral cavity.⁴ It may occur at any age but it is most commonly found in patients in their twenties and sixties, and more frequently in women than men.⁵ There are four types of epulis, depending on the prevalent histological component: fibrous, granulomatous (pyogenic granuloma), angiomatous and giant cells epulis. According to several authors, they correspond to different developing stages of a single pathological entity that, at the initial stages, would be rich with vascular and cellular components while the fibrous constituent progressively increases over time.⁴

Fibrous epulis is considered to be one of the most common benign growth occurring on the gingiva.⁴ The most common clinical aspect of the fibrous epulis is the growth of well-delimited tissue, of a smooth surface, usually with

normal colored mucosa, with a sessile or pedunculated base of hard consistency in the interdental papilla.⁶

There was another lesion in the gingiva which is a neoplastic lesion called angiofibroma while fibrous epulis is hyperplastic, but both lesions could be caused by infection. Angiofibroma is a relatively rare tumor. Only a few cases have been reported in the maxillofacial complex in females.⁷ Angiofibromas are commonly well-circumscribed tumors, localized in the superficial soft tissue and characterized by bland spindle-shaped cells arranged within vessels. The diagnosis of angiofibroma is dependent more on histological confirmation due to its close resemblance with other lesions.¹

³ Despite the clinical similarities between the angiofibroma presented in this study and fibrous epulis, both lesions could be differentiated through their histopathological picture although the pathogenesis could be similar. Fibrous

epulis consists of a predominantly hyperplastic stratified squamous epithelium and consists of connective tissue characterized by variable collagen deposition and variable chronic inflammatory infiltration depending on the stage of development.⁸ Angiofibroma consists essentially of two basic and characteristic components: a vascular network and a connective tissue stroma. The vessels comprising the vascular network are of varying caliber, irregular in shape, and generally consisting of a simple endothelial lining. The connective tissue stroma consists of both fine and coarse collagen fibrils. An abundance of mast cells in the stroma and a lack of other inflammatory cells exists. Hyalinized foci are sometimes present, as well as areas resembling myxomatous degeneration.⁹

The histopathological picture described, in our case, was lined with squamous epithelium. The stroma consists of vascular proliferation with endothelial lining with erythrocyte within its lumen and fibrous cell proliferation with myxomatous degeneration. This showed the basic and characteristic of angiofibroma which was a vascular network and a connective tissue stroma. These characteristics could not be found in fibrous epulis.

This case was the first angiofibroma found in the Oral and Maxillofacial Clinic of Dr. Mohammad Soewandhie General Hospital, Surabaya, Indonesia since 2015. This showed the rareness of angiofibroma. On intraoral examination, during the palpation, the mass bled easily which matched the highly vascular character. The authors proposed that chronic infection might be to be the etiology of this case based on anamnesis and clinical examination.

The treatment of choice for angiofibroma and fibrous epulis is surgical excision. The treatment in this case including the extraction of the neighboring teeth considering there was underlying bony involvement. The first and second molars were mobile and there was vertical resorption on the alveolar crest of the first molar and second molars of the right mandible. Massive bleeding occurred while removing the giant mass. It was controlled by using electrocautery. Curettage of the periosteum and periodontal ligament cells area was performed to prevent a recurrence. Thakur *et al.* reported an angiofibroma case that was excised from the base of the peduncle using a diode laser due to superior hemostasis and no sutures were required.¹ Mahmood *et al.* reported the pedicle had been completely transected with bipolar diathermy, with insignificant bleeding which was controlled with electrocautery.¹⁰

The recurrence rate of angiofibroma varies in some series. Sun *et al.* reported the recurrence occurred in 21.7% of the patients with tumor size less than 4 cm and 54.9% of the patients with tumor size more than 4 cm.¹¹ Gaillard *et al.* reported a recurrence rate of 43.75% and the relapse time after surgery ranged from 1 month to 3 years.¹² The recurrence rate of fibrous epulis ranges from 8 to 16%.¹³ Angiofibroma has a higher recurrence rate than fibrous epulis.

CONCLUSION

Angiofibroma of the oral cavity can resemble an epulis. Treatment of choice for angiofibroma and fibrous epulis is by surgical excision. Curettage of the area was done from the periosteum and periodontal ligament cells to prevent recurrences.

Acknowledgment

The authors thank the Faculty of Dental Medicine, Universitas Airlangga and Dr. Mohammad Soewandhie General Hospital, Surabaya, Indonesia.

Statement of Authorship

All authors participated in the data collection and analysis and approved the final version submitted.

Author Disclosure

All authors declared no conflicts of interest.

Funding Source

None.

REFERENCES

1. Thakur RK, Madan E, Tomar A, Arora M. (2014). Angiofibroma on Cheek Mucosa: A Rare Entity and its Management with Laser. *Journal of Cutaneous and Aesthetic Surgery*, vol. 7, no. 4, pp. 227–9.
2. Celik B, Erisen L, Saraydaroglu O, Coskun H. (2005). Atypical angiofibromas: a report of four cases. *International Journal of Pediatric Otorhinolaryngology*, vol. 69, no. 3, pp. 415–21.
3. Bokhari K, Luqman M, Muhammed A, Mohammad S, Mustafa AB, Zaheer K. (2012). Cellular angiofibroma of the buccal mucosa: A rare case report and review of literature. *International Journal of Experimental Dental Science*, vol. 1, no. 1, pp. 23–5.
4. Laus M, Conti MA, Croce A. (2016). Giant Fibrous Epulis: A Case Report of a Benign Mass of the Oral Cavity. *International Journal of Otorhinolaryngology and Head and Neck Surgery*, pp. 228–32.
5. Khzam N, Shah Mansouri R, Poli A, Bakr MM. (2017). Fibrous epulis misdiagnosed for combined periodontic-endodontic lesion. *International Journal of Medical and Dental Sciences*, pp. 1546–52.
6. Jadhav PM, Khale PA, Premchandran R. (2015). Fibrous Gingival Epulis: A Case Report Of A One Year Old Lesion. *International Journal of Current Research*, vol. 7, no. 9, pp. 20148–52.
7. Ul Khaliq MI, Shah AA, Dar N. (2016). A rare case of angiofibroma of the mandible: A case report. *Journal of Oral Biology and Craniofacial Research*, vol. 6, no. 2, pp. 168–70.
8. Fonseca GM, Fonseca RM, Cantin M. (2014). Massive fibrous epulis-a case report of a 10-year-old lesion. *International Journal of Oral Science*, vol. 6, no. 3, pp. 182–4.
9. Shafer AW, Hine MK, Levy BM. (2015). *Shafer's Textbook of Oral Pathology* 7th Edition. New Delhi: Elsevier.
10. Mahmood AN, Sheikh R, Saey HA, Ashkanani S, Ganesan S. (2016). Angiofibroma Originating outside the Nasopharynx: A Management Dilemma. *Case Reports in Otolaryngology*, Article ID 3065657.
11. Sun XC, Wang DH, Yu HP, Wang F, Wang W, Jiang JJ. (2010). Analysis of risk factors associated with recurrence of nasopharyngeal angiofibroma. *Journal of Otolaryngology - Head & Neck Surgery*, vol. 39, no. 1, pp. 56–61.
12. Gaillard AL, Anastácio VM, Piatto VB, Maniglia JV, Molina FD. (2010). A seven-year experience with patients with juvenile nasopharyngeal angiofibroma. *Brazilian Journal of Otorhinolaryngology*, vol. 76, no. 2, pp. 245–50.
13. Neville BW, Damm DD, Allen CM, Chi AC. (2015). *Oral and Maxillofacial Pathology* 4th Edition. Missouri: Saunders Elsevier.

A Rare Case of Angiofibroma Mimicking Fibrous Epulis in Posterior Gingival Mucosa

ORIGINALITY REPORT

17%

SIMILARITY INDEX

7%

INTERNET SOURCES

15%

PUBLICATIONS

0%

STUDENT PAPERS

PRIMARY SOURCES

- 1** cyberleninka.org 3%
Internet Source
- 2** Mohammed Israr Ul Khaliq, Ajaz A. Shah, Nahida Dar. "A rare case of angiofibroma of the mandible: A case report", Journal of Oral Biology and Craniofacial Research, 2016 3%
Publication
- 3** Nabil Khzam, Reza Shah Mansouri, Alexander Poli, Mahmoud M. Bakr. "Fibrous Epulis Misdiagnosed for Combined Periodontic-Endodontic Lesion", International Journal of Medical and Dental Sciences, 2017 3%
Publication
- 4** Pedro Paulo de Andrade Santos, Cassiano Francisco Weege Nonaka, Leão Pereira Pinto, Lélia Batista de Souza. "Immunohistochemical expression of mast cell tryptase in giant cell fibroma and inflammatory fibrous hyperplasia of the oral mucosa", Archives of Oral Biology, 2011 1%
Publication

| | | |
|----|--|------|
| 5 | repository.ubn.ru.nl Internet Source | 1 % |
| 6 | Saverio Capodiferro, Eugenio Maiorano, Carmela Giardina, Maria Grazia Lacaïta, Lorenzo Lo Muzio, Gianfranco Favia. "Osteoblastoma of the mandible: Clinicopathologic study of four cases and literature review", Head & Neck, 2005 Publication | 1 % |
| 7 | downloads.hindawi.com Internet Source | 1 % |
| 8 | Shun Yamaguchi, Taichiro Kosaka, Susumu Eguchi. "Hepatic resection for hepatocellular carcinoma", Hepatoma Research, 2018 Publication | 1 % |
| 9 | hdl.handle.net Internet Source | 1 % |
| 10 | "Encyclopedia of Otolaryngology, Head and Neck Surgery", Springer Nature, 2013 Publication | 1 % |
| 11 | www.omicsonline.org Internet Source | 1 % |
| 12 | scirp.org Internet Source | <1 % |
| 13 | www.hindawi.com Internet Source | <1 % |

14

Uta Flucke, J Han JM van Krieken, Thomas Mentzel. "Cellular angiofibroma: analysis of 25 cases emphasizing its relationship to spindle cell lipoma and mammary-type myofibroblastoma", Modern Pathology, 2010

Publication

<1 %

Exclude quotes Off

Exclude matches < 7 words

Exclude bibliography On

A Rare Case of Angiofibroma Mimicking Fibrous Epulis in Posterior Gingival Mucosa

GRADEMARK REPORT

FINAL GRADE

/0

GENERAL COMMENTS

Instructor

PAGE 1

PAGE 2

PAGE 3

PAGE 4
