

MANAGEMENT OF ANTENATAL HYDRONEPHOSIS. A REPORT OF 2 CASES

by Natalia Kristanti Nugraheni

Submission date: 05-Oct-2021 05:11PM (UTC+0800)

Submission ID: 1665809981

File name: MANAGEMENT_OF_ANTENATAL_HYDRONEPHOSIS._A_REPORT_OF_2_CASES.pdf (365.34K)

Word count: 5188

Character count: 28957

MANAGEMENT OF ANTENATAL HYDRONEPHROSIS. A REPORT OF 2 CASES

Natalia Kristanti Nugraheni¹, Risky Vitria Prasetyo¹, Ninik Asmaningsih Soemyarso¹, Mohammad Sjaifullah Noer¹, Martono Tri Utomo², Risa Etika², Agus Harianto², Agus Sulistiyono³, Tarmono⁴, Lenny Violetta⁵

¹Division of Nephrology, ²Division of Neonatology, Department of Child Health, ³⁰

³Department of Obstetrics and Gynaecology, ⁴Department of Urology, ⁵Department of Radiology, Faculty of Medicine Airlangga University/Dr. Soetomo Hospital Surabaya

ABSTRAK

Angka kejadian hidronefrosis antenatal terus meningkat sejak adanya pemeriksaan ultrasonografi rutin pada saat kehamilan. Penyebab hidronefrosis antenatal bermacam-macam dan tata laksana disesuaikan dengan penyebabnya. Diperlukan deteksi dini terhadap hidronefrosis antenatal karena adanya risiko infeksi saluran kemih dan disfungsi ginjal. Tujuan penelitian ini adalah untuk melaporkan dua kasus hidronefrosis antenatal berfokus pada tata laksana. Seorang ibu dirujuk dari Kendari ke Divisi Fetomaternal di Rumah Sakit (RS) Dr Soetomo karena hidronefrosis antenatal. Pemeriksaan lanjutan mendapatkan bahwa terjadi obstruksi di ureterovesical junction sehingga dilakukan neoplastikasi. Bayi E dirujuk dari RS Murjani ke RS Dr Soetomo karena tumor perut. Didapatkan kista ginjal kanan dan stenosis ureteropelvic junction kanan. Dilakukan nefrostomi perkutaneus yang diikuti oleh nefrektomi kanan. Kedua bayi dipulangkan dalam kondisi baik. Ringkasan: Tata laksana hidronefrosis antenatal terdiri dari pemeriksaan diagnostik untuk menetapkan etiologi dan melakukan rujukan segera untuk intervensi bedah dengan hasil yang baik pada kedua kasus ini. Untuk pemantauan jangka panjang, diperlukan kerjasama antara ahli nefrologi anak, ahli neonatologi, ahli kandungan, ahli urologi anak dan ahli radiologi. (FMI 2013;49:193-201)

Kata kunci: hidronefrosis antenatal, tata laksana

ABSTRACT

The incidence of antenatal hydronephrosis approximately 1-5% of all pregnancies but the number has changed significantly since the inception of fetal sonography. The etiology was various and the management was based on the cause of the hydronephrosis. The risk of urinary tract infection and renal dysfunction requires early detection. The objective of this study was to report two cases of antenatal hydronephrosis focusing on management and clinical course. Baby A's mother was referred from Kendari to Fetomaternal Division at Soetomo Hospital due to antenatal hydronephrosis. She was born by caesarean section and further work-up revealed that it was due to ureterovesical junction obstruction. Neoplastication were done. Baby E was referred from Murjani Hospital to Soetomo Hospital due to suspicious abdominal tumor. The diagnosis was established as right kidney cyst and right ureteropelvic junction stenosis. Percutaneous nephrostomy was done followed by right nephrectomy. Both babies were discharged in a good condition. Summary: The management of antenatal hydronephrosis consisted of work-up to establish the etiology and immediate referral for surgery intervention had resulted in better outcome on both cases. For long term monitoring, a joint follow-up by pediatric nephrologist, neonatologist, obstetrician, pediatric urologist and radiologist is needed. (FMI 2013;49:193-201)

Keywords: antenatal hydronephrosis, management.

²⁴
Correspondence: Risky Vitria Prasetyo, Division of Nephrology, Department of Child Health, Faculty of Medicine Airlangga University/Dr. Soetomo Hospital Surabaya. Jl. Mayjend Prof Moestopo 6-8 Surabaya. Home address: Jl. Kertajaya Indah Tengah 6/14 Surabaya. Phone: 0816507203. Email: kikiprasetyo14@gmail.com

INTRODUCTION

²⁷
Antenatal hydronephrosis (ANH) is a dilation of fetal renal collecting system which can be detected by prenatal ultrasonography (US). US screening during pregnancy has resulted in increasing recognition of fetal abnormalities especially in fetal hydronephrosis (Longpre et al 2012, Piepsz 2007, Belarmino & Kogan 2006, Sinha et al 2013). The detection of urinary anomalies has changed significantly since the inception of fetal sonography. Urinary tract abnormalities reportedly account for 30-50% of fetal anomalies.

⁹
Incidence of ANH is reported in approximately 1-5% of all pregnancies and one of the most common birth defects. Transient or mild in nature hydronephrosis without any clinical sequale is the most common, accounting for 50-70% of the cases ANH. In Dr. Soetomo Hospital from 2007-2013 there were 55 children with hydronephrosis comprised of fourteen (25.5%) patients with mild hydronephrosis, 15 (27.3%) of moderate hydronephrosis, and 26 (47.3%) of severe hydronephrosis (Dudley et al 1997, Estrada 2008, Pereira et al 2011, Nguyen et al 2010, Psooy & Pike 2009, Prasetyo et al 2013).

The etiology of ANH is commonly because of ureteropelvic junction (UPJ) obstruction (10-30%), either due to an adynamic segment, polyp or crossing of lower pole vessels. Other much less common causes of ANH are ureterovesical junction (UVJ) obstruction and posterior ureteral valves. ANH detected from ultrasound shows a wide spectrum of urological conditions, ranging from transient collecting system dilation to clinically significant urinary tract obstruction or vesicoureteric reflux (VUR). The presence of hydronephrosis at any stage of gestation is generally the first indicator of a potential urinary tract anomaly (Estrada 2008, Pereira et al 2011, Yamaçake & Nguyen 2013).

The diagnosis of ANH is defined by measuring the anterior posterior diameter (APD) at the second and third trimester by ultrasonography. The ANH grading consists of mild (APD \leq 9 mm), moderate (APD 9-15 mm) and severe (APD \geq 15mm). Resolving ANH in half of cases before delivery or during the 1st year of life is to be expected. The remaining half require postnatal follow-up as persistent uropathy occur in 12% of mild, 45% of moderate and 88% of severe ANH cases (Estrada 2008, Pereira et al 2011, Nguyen et al 2010, Psooy & Pike 2009, Yamaçake & Nguyen 2013).

The principal of ANH management is etiology-based. Prenatal intervention is relatively uncommon and primarily reserved for fetuses with bladder outlet obstruction with favorable US and urine electrolyte parameters. Successful ANH management requires dependable fetal surveillance, prompt neonatal evaluation, including sonography, and when indicated, referral to a pediatric urologist. Children with mild ANH demonstrated in postnatal US require long-term follow-up to detect progressive obstructive uropathies. Postnatal management may involve pediatric urologist, pediatric nephrologist, radiologist, and neonatologist (Dudley et al 1997, Estrada 2008, Pereira et al 2011, Psooy & Pike 2009, Yamaçake & Nguyen 2013, Kangin et al 2010, Herndon 2006). Early detection and proper management of urinary tract obstruction or reflux are essential prior to complication such as urinary tract infection, kidney stones and renal dysfunction or failure. Long term outcomes are not yet known (Kangin et al 2010, Herndon 2006, Cordero et al 2009, Chertin et al 2006). The aim of this paper is to report 2 cases of antenatal hydronephrosis focusing on management and clinical course of antenatal hydronephrosis.

CASE REPORT

Case 1

A, a baby boy was born by caesarean section on 16th November 2012 in Dr. Soetomo Hospital with indication of secondary arrest, antenatal hydronephrosis and hydroureter. Clinical condition post delivery was normal and unremarkable. Mother was referred by an obstetrician from Kendari, South Sulawesi. Third trimester antenatal care ultrasound showed an abdominal mass which turned out to be bilateral hydronephrosis (Figure 1).

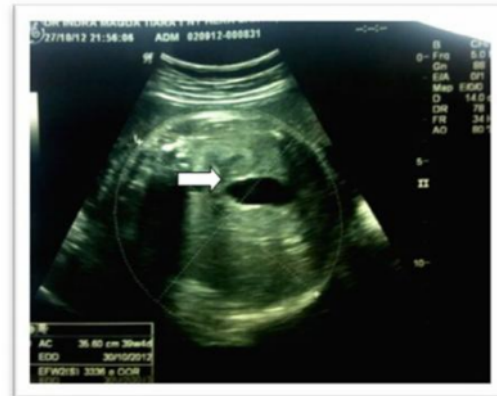

Figure 1. (white arrow) Antenatal ultrasonography showing abdominal mass (bilateral ANH)

Another fetomaternal US showed biparietal diameter (BPD) 9.40 cm ~ 38/39 weeks of gestation, right kidney 4.63 x 2.66 x 0.09 cm (within normal limit), left kidney 6.16 x 4.23 x 3.11 cm and hydroureter reaching the vesicoureteral junction due to suspected obstruction (Figure 2).

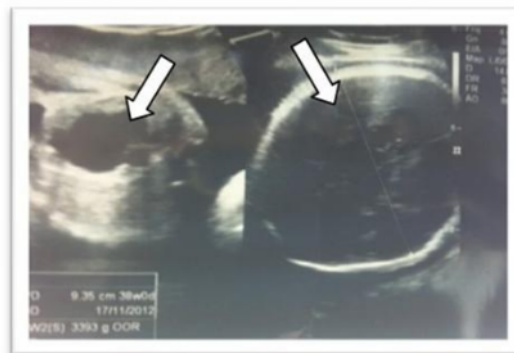


Figure 2. A review of fetomaternal ultrasonography.

Initial physical examination presented normal vital signs (regular heart rate of 140 times per minute, respiratory rate of 40 times per minute and axillary temperature 37.2°C). No anemia, cyanosis, nor icterus were noted. The chest examination was normal. The abdomen was

soft upon palpation with enlarged abdomen. His birth weight and length was 4000 grams and 52 cm consecutively. Based on history taking, initial physical examination and antenatal US, the baby was assessed with term infant (large for Gestational Age) and bilateral antenatal hydronephrosis. Laboratory examination at birth revealed haemoglobin level 17.8 g/dL, hematocrit 50.4%, leucocyte count 21,500/mm³, platelets count 348,000/mm³, serum sodium 139 mmol/L, serum potassium 4.4 mmol/L, serum chloride 109 mmol/L and serum calcium 10.3 mmol/L, BUN 3.6 mg/dl, creatinin 0.57 mg/dl, GFR 41.05 ml/min/1.73m², direct bilirubin 0.51 mg/dL, total bilirubin 11.29 mg/dl, AST 33 U/L, ALT 8 U/L. The urinalysis revealed no blood nor protein, and urine sedimen showed erythrocyte 2-5 /hpf, leukocyte 2-5 /hpf.

Post natal ultrasonography (fourth day of life) showed mild enlargement of the right kidney by 6.2 x 2.7 cm (reference range based on birth length of 50-60 cm is 1.5 - 4.5 cm), renal pelvic diameter (RPD) was 20.8 mm with normal echo intensity, fine echo-cortex with mild ectasis. No renal stone, cyst nor mass were seen. Left kidney was also enlarged by 7.2 x 3.2 cm (reference range based on birth length of 50-60 cm is 3.5-6.5cm), RPD was 52 mm, with normal echo intensity, fine echo-cortex with mild ectasis. No renal stone, cyst not mass were seen. Urinary bladder was normal (figure 3).

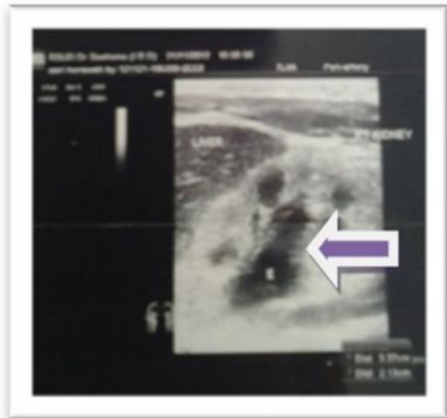


Figure 3. Post natal ultrasonography showing RPD of \geq 15 mm; mild right hydronephrosis and severe left hydronephrosis.

Intravenous pyelography then commenced at the age of 8 days old showing no contrast filling both urinary system in 60 minutes after injection (figure 4).

Based on history taking, physical examination, laboratory findings, ultrasonography and intravenous pyelography, we assessed the baby as mild right

hydronephrosis and severe left hydronephrosis due to left ureteral vesico junction stenosis. On 30th November 2012 the baby underwent surgical intervention when left ureter was implanted with drain kept for 14 days. Post surgery day 1, the baby boy was alert, with urine production of 300cc/17 hour \sim 4.4cc/ kgBW/ hour and minimal drain production.

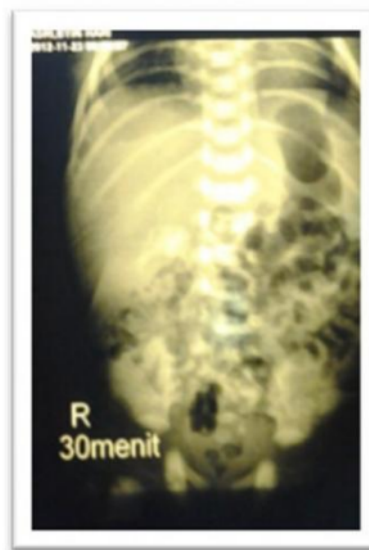

Figure 4. Intravenous pyelography showing bilateral hydronephrosis.

Laboratory examination showed hemoglobin level of 10.9 g/dL, white blood count of 16,000/mm³, platelet level of 433,000/mm³ and hematocrite of 31.2%. Serum sodium level of 129 mmol/l, potassium 5.4 mmol/l, chloride 101 mmol/l. BUN 19 mg/dl, creatinin serum 0.9 mg/dl, GFR 26 ml/ min/1.73m², AST 28 U/L, ALT 28 U/L. Ceftazidim was given according to the urine culture result. (Acinetobacter spp > 10⁵ CFU). On the fourteenth day post surgery, antegrade pyelography (APG) showed left ureter patency without contrast extravasation. Splintography catheter and drain were projected in the pelvic cavity. No visible contrast extravasation seen following contrast (50 cc). Therefore splint and drain were removed and the baby was discharged on the seventeenth day following surgery.

Case 2

E, a baby boy referred from Murjani Hospital Sampit with initial assessment of abdominal cystic tumor. He was delivered by caesarean section on 20th December 2012 due to cephalopelvic disproportion and suspected

abdominal cystic tumor. Birth weight and length were 3500 grams and 50 cm consecutively. Antenatal US by the eight month of pregnancy noted an abdominal cystic tumor. At the age of six days the baby then referred to Dr. Soetomo Hospital for further examination and management. Initial physical examination showed normal vital signs (regular heart rate of 140 times/minute, respiratory rate of 40 times/minute and axillary temperature of 37°C). No anemia, cyanosis, nor icterus were observed.

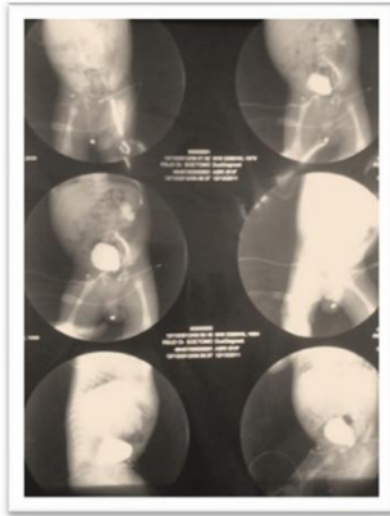


Figure 5. Antegrade urography showed patency of left ureter and without contrast extravasation.

The chest examination was normal. The abdomen was soft upon palpation, appeared enlarged with palpable painless mass of 10 x 10 x 8 cm. Laboratory examination revealed hemoglobin level of 14.9 g/dL, white blood count of 12,000/mm³, platelet level of 293,000/mm³ and hematocrit of 45.4%. Serum electrolyte resulted sodium level of 138 mmol/l, potassium 5.5 mmol/l, chloride 112 mmol/l, calcium 11 mg/dL. BUN 9.4 mg/dl, creatinin serum 0.77 mg/dl, GFR 38 ml/min/1.73 m², AST 37 U/L, ALT 29 U/L, Albumin 4.06 g/dL, CRP 4.7. Urinalysis showed microscopic erythrocyte 0-2/HPF, leukocyte 5-10/HPF. Post natal US showed cystic lesion of 10.6 x 8.6 x 7 cm on the right kidney with undefined cortex and parenchym. Left kidney measurement of 5.83 x 1.93 cm with normal echo parenchymal intensity and apparent sinus cortex. There was pelviocalyceal system ectasis with the largest pelvis renalis of 0.9 cm. No mass, cyst and stone were noted.

Abdominal Multi-sliced computed tomography (MSCT) scan on the sixth day of age revealed enhanced cystic

lesion (12.5 x 11 x 8.3 cm) on the right kidney and showing the liver superiorly. Pelviocalyceal system appeared normal.




Figure 6. Post natal US showing left mild left hydronephrosis and cystic tumor of the right kidney and severe right hydronephrosis.

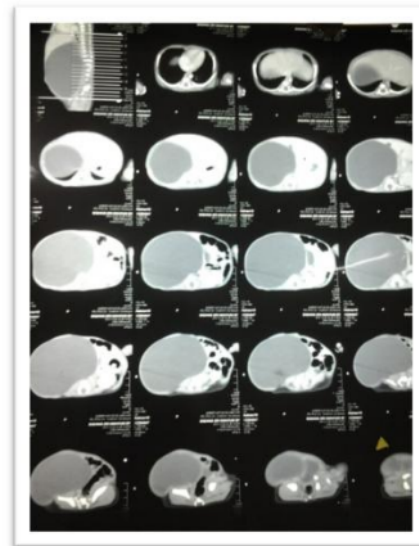


Figure 7. Abdominal MSCT Abdomen showing enhanced cystic lesion.

Antegrade pyelogram showed obstruction at the level of right ureteropelvic junction (figure 9). Laboratory results were as follow: hemoglobin level of 12.7 g/dL, white blood count of 8,100/mm³, platelet level of 195,000/mm³ and hematocrite of 37.8%. Serum sodium level of 138 mmol/l, potassium 5.5 mmol/l, chloride 112 mmol/l, calcium 11 mg/dL. BUN 1.8 mg/dl, creatinin serum 0.59 mg/dl, GFR 38.1 ml/ min/ 1.73 m².

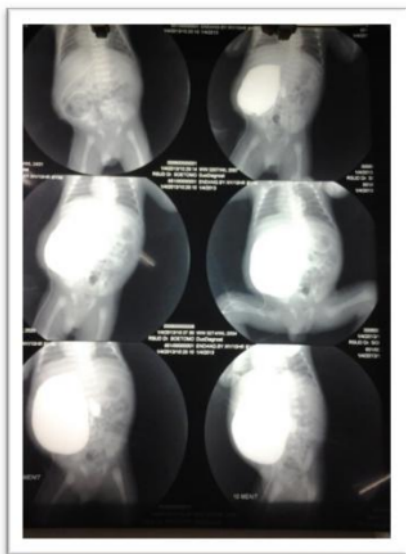


Figure 8. Antegrade pyelography showing right ureteropelvic junction obstruction.

Based on history taking, physical and laboratory examination, urology US, and abdominal MSCT, the baby was assessed as term infant with right kidney cyst and severe right hydronephrosis due to right ureteropelvic junction stenosis and left mild hydronephrosis. Percutaneous Nephrostomy (PCN) was done with clear initial urine output of 300 cc and 600 cc of urine following the initial urine output. After the

procedure ampicillin sulbactam 100 mg/kgbw/day was given twice daily. On 26th day of admission, he underwent right nephrectomy and during surgery no right renal cortex was noted. Histopathological result showed chonic suppurative pyelonephritis with multifocal microabscesses and UPJ stenosis. Local wound infection rose on the seventh day post surgery with swab culture revealing *Pseudomonas aeruginosa* that was sensitive to cefoperazon tazobactam and amikasin. Following treatment, the baby was discharged in a good condition.

DISCUSSION

Both cases were known to present with abdominal mass by antenatal US screening at the third trimester of pregnancy. Ultrasonography is the first imaging method of choice to assess urological condition in infants both antenatally and postnatally. In screening studies using ultrasonography, the frequency of urinary anomalies is usually found between 0.1% and 1%. In the present study, the frequency of congenital anomalies of the kidney and the urinary tracts was 10.5% (Herndon 2006, Tabel et al 2010).

Ultrasound imaging provides adequate anatomic detail in the absence of radiation exposure. However, independently, renal ultrasound is a poor predictor of surgical intervention. In order to standardize evaluations, it is recommended that all images be interpreted in the Society Fetal Urology (SFU) classification system (Nguyen et al 2010, Tabel et al 2010). On post natal US, baby A showed there was mild enlarged of right kidney, normal echo intensity, fine echo cortex, mild ectasis and also enlarged left kidney. Baby E's post natal US showed cystic lesion occupying the right kidney's region with unclear cortex and parenchym; while the left kidney appeared normal in echo parenchymal intensity.

Table 1. Differential diagnosis of prenatal hydronephrosis (Yamaçake & Nguyen 2013)

Etiology	Incidence	Prenatal ultrasound finding
Transient / physiologic	50 – 70 %	Isolated hydronephrosis most often mild
Ureteropelvic junction (UPJ) obstruction	10 – 30 %	Moderately (10 – 15 mm) dilated renal pelvis in the absence of any dilatation of ureter or bladder
Vesicoureteral reflux (VUR)	10 – 40%	Variation in the degree of ANH during the time of US evaluation (in general, there are no specific findings that are pathonomic)
Ureterovesical junction (UVJ) obstruction	5 – 15%	Hydronephrosis and dilated ureter to level of of the UVJ
Posterior urethral valves (PUV)	1-5%	A combination of the following posterior urethral dilatation (key hole sign); a full bladder with thickened wall; oligo or anhydramnios; unilateral or bilateral hydronephrosis; increased renal echogenicity
Ureterocele	1 – 3%	A cystic mass in the bladder and hydroureteronephrosis to the level of obstructing ureterocele

Less common etiology: ectopic ureter, urethral atresia, prune belly syndrome, poly cystic kidney disease and renal cyst

20

Table 2. The Society Fetal Urology grading system for hydronephrosis (Nguyen et al. 2010)

Grade 1	Renal pelvis splitting
Grade 2	Moderate renal pelvis splitting confined to renal border
Grade 3	Significant renal pelvis distention outside of renal border, uniform calyceal distention, renal parenchyma normal
Grade 4	Significant renal pelvis distention, significant calyceal distention, renal parenchyma demonstrates thinning

There was ectasis of pelvicoalyceal system with the largest renal pelvic of 0.9 cm. The grading of ANH by measurement of anteroposterior diameter (APD) of the renal pelvis by using US (Estrada 2008, Pereira et al 2011, Nguyen et al 2010, Yamaçake & Nguyen 2013, Kangin et al 2010, Herndon 2006, Tabel et al 2010).

Table 3. Definition of the grades of ANH

ANH grade	APD second trimester, mm	APD third trimester, mm	% with postnatal pathology
Mild	≤ 7	≤ 9	12
Moderate	7-10	9-15	45
Severe	>10	>15	88

Both cases presented with congenital anomaly of the kidney and the urinary tracts that causes were to be determined by further diagnostic procedure. Some of the possible etiologies vary and may differ from the initial screening (table 4) (Tabel et al 2010). Study by Tabel et al showed the most common CAKUT is transient hydronephrosis then ureteropelvic stenosis, vesicoureteral reflux and multicystic displastic kidney (Tabel et al 2010). In these cases, the first case presented with left UVJ stenosis while the other had right UPJ obstruction.

Both cases were referral cases as per advices proposed in some sources that prenatal monitoring in all fetuses with antenatal hydronephrosis need monitoring through pregnancy, the frequency of which depends on severity of finding and presence of oligohydramnions. Those with oligohydramnions or other systemic abnormalities should be referred to specialized center (Belarmino & Kogan 2006, Sinha et al 2013, Nguyen et al 2010).

Baby A had severe unilateral hydronephrosis. Based on the algorithm, renal US was supposed to be done in the first 48 hours of life, but in this case on the fourth day of birth the US showed RPD > 15 mm with hydroureter and features of obstruction. IVP on the 7th day of his age showed UVJ stenosis, thus required further management from a pediatric urologist.

41

Table 4. Congenital anomaly of the kidney and urinary tracts (CAKUT) (Tabel et al. 2010)

Etiology	First Postnatal screening n (%)	Antenatal abnormal ultrasonography n (%)
Physiological hydronephrosis	17 (2.8)	43 (35.8)
Transient hydronephrosis	0	33 (27.5)
Ureteropelvic stenosis	24 (3.4)	20 (16.6)
Vesicoureteral reflux	14 (2.30)	6 (5)
Multicystic displastic kidney	2 (0.3)	4 (3.3)
Posterior ureteral valve	0	2 (1.6)
Renal Agenesis	3 (0.4)	0
Ektopik kidney	1 (0.1)	0
Normal	557 (92.6)	88 (73.3)
Total	601	120

Abnormalities of the ureterovesical junction (UVJ) were first classified into obstructed, refluxing, or unobstructed and not refluxing by Smith et al, who also subdivided them into primary (congenital) or secondary (acquired). King later published a more practical classification: obstructed, refluxing, non-obstructed and non-refluxing, or both obstructed and refluxing. Congenital UVJ anomalies often present due to the detection of an associated dilated or 'mega'-ureter. Congenital megaureters are twice as common in males, and present with a left-to-right ratio of 1.8:1.3 (Yap et al 2012, Farrugia 2013).

Baby E came with an abdominal mass which turned out to be cystic lesion of the right kidney. The IVP revealed UPJ obstruction and abdominal MSCT showed enlarged right kidney (severe hydronephrosis) due to UPJ obstruction. UPJ stenosis occurs in 13% of children with antenatally diagnosed renal pelvis dilation and is characterized by obstruction at the level of the junction between the renal pelvis and the ureter. The anatomical basis for obstruction includes intrinsic stenosis/valves or crossing vessels. Sonographic diagnosis depends on the demonstration of a dilated renal pelvis in the absence of any dilation of ureter or bladder. It should particularly be suspected when moderate (10-15 mm) or severe (≥ 15 mm) dilation is seen in these circumstances. The degree of hydronephrosis in postnatal period is undoubtedly important to evaluate (Farrugia 2013, Dagli & Ramchandani 2011). Both cases underwent surgical intervention. Neo implantation of the left ureter on the 7th days of life was done in Baby A while Baby E had right percutaneous nephrostomy at the age of 5 days old and proceeded with right nephrectomy due to non functioning right renal. Clinical parameters for surgical intervention are listed in table 5 (Belarmino & Kogan 2006, Dagli & Ramchandani 2011).

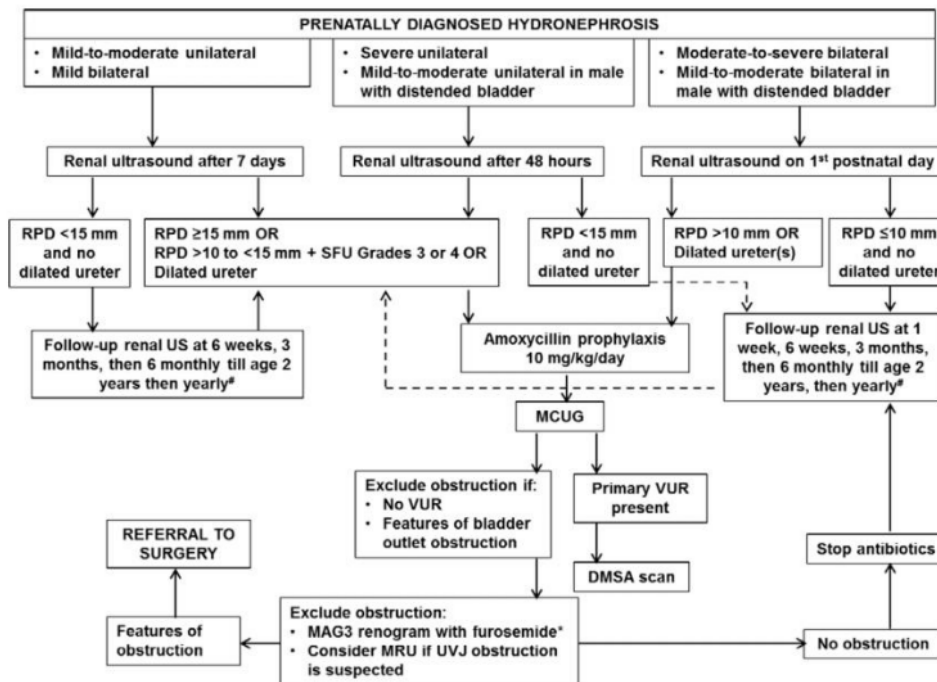


Figure 9. Algorithm for management of prenatally diagnosed hydronephrosis (Yap et al 2011)

Table. 5. Indication of surgical intervention (Belarmino & Kogan 2006)

<ul style="list-style-type: none"> Reduced differential function, less than 40% Deterioration of differential function greater than 5% Sustain or increased hydronephrosis Unilateral gross hydronephrosis, greater than 50 mm Severe hydronephrosis in solitary kidney Severe bilateral hydronephrosis greater than 30 mm Febrile breakthrough infection or symptoms
--

Peters et al showed that repair of an obstructed megaureter in early infancy improves renal drainage as assessed by excretory urography, and therefore offers the potential for preventing renal damage before the development of symptoms or decline in function on the renogram. Ureteric reimplantation allows the aperistaltic, narrow segment to be excised, and the ureter to be tunneled into the bladder in an anti-reflux fashion (Farrugia 2013, Linscott 2011). Ureteric reimplantation in infants below one year of age may be challenging due to the discrepancy between the grossly-dilated ureter and the small infantile bladder, and concern regarding possible iatrogenic bladder dysfunction. De Jong concluded that early major

reconstructions of the lower urinary tract do not damage the urodynamic properties of the bladder and pelvic floor, provided that the surgery is performed by specialized pediatric urological surgeons (Farrugia 2013, Castagnetti et al 2010). Baby E had hydronephrosis due to UPJ obstruction. Enlarged abdomen indicated a growing obstruction with suspected urinary diversion thus percutaneous nephrostomy was done to release obstruction and further evaluation.

Indications for PCN consist of (1) relief of urinary obstruction, (2) diagnostic testing, (3) access for therapeutic interventions, and (4) urinary diversion. In general, because an uninfected obstructed kidney is not acutely threatened, nephrostomy placement is an urgent rather than emergent procedure (Dagli & Ramchandani 2011, Linscott 2011, Kim et al 2010). Internal ureteral stents are an important alternative to external drainage and share many of the same indications as percutaneous nephrostomy (Linscott 2011).

Baby E underwent nephrectomy on the 36th days of age due to non-functioning renal. Nephrectomy is the standard procedure for malignancy of the kidneys or for abnormal kidneys that provide little or no contribution

to overall renal function. The indications for partial or total nephrectomy for urological reasons are not clearly indicated in the paediatric surgical literature. Likewise, there are no guidelines as to when to undertake nephrectomy for benign urological lesions in childhood. Nephrectomy is often considered when relative renal function is 15%. Restorative surgery may be indicated if more than 20% of the total renal function is present in a kidney with hydronephrosis, stone or renovascular disease (Featherstone et al 2011).

No prophylactic antibiotic was given in both cases. Baby A developed urinary tract infection on the 7th days of surgery when ceftazidime was commenced according to the urine culture result (*Acinetobacter* spp). Baby E developed wound infection after nephrectomy with *Pseudomonas* spp that sensitive to cefoperazone sulbactam and amikasin. Both cases had recurrent UTI during their outpatient clinic follow ups. Infants with antenatal hydronephrosis have nearly a 12-fold increased risk of pyelonephritis admission in the 1st year of life compared with infants without antenatal hydronephrosis (Walsh et al 2007, Lee et al 2006, Subotic et al 2012). The ultimate decision to start an infant on Continuous Antibiotic Prophylaxis (CAP) currently centers on parental acceptance aligning with individual health care provider and/or institution protocols. Due to the paucity of published data, the decision is based on partially defined risks and benefits. It would make sense to tailor the prescription of CAP based on specific patient characteristics that affect the odds of experiencing the outcome of interest (Walsh et al 2007, Lee et al 2006, Subotic et al 2012, Szymanski et al 2011, Molina et al 2013).

²² The absolute risk of hospitalization for pyelonephritis in the first year of life in infants with antenatal hydronephrosis was 5%. If a causal relationship is inferred, the proportion of pyelonephritis attributed to the presence of antenatal hydronephrosis is 91.5%. Both parents and healthcare providers of infants with a history of antenatal hydronephrosis should be vigilant for the signs and symptoms of UTI (Walsh et al 2007, Lee et al 2006, Subotic et al 2012, Szymanski et al 2011, Molina et al 2013). Both cases were discharged in good condition and advised to have regular follow up in the pediatric nephrology outpatient clinic. The prognosis of this two babies seemed to be good needing further monitoring in growth and development. Discovery of urinary abnormalities does not always implicate a better prognosis. To comply with that statement, we have found that in infants with antenatally diagnosed hydronephrosis, the subsequent physiological improvement was significantly poorer than the infants with postnatally diagnosed hydronephrosis, possibly due to higher damage in former infants. 24-28 Prognosis

may be poor in bilateral cases associated with oligohydramnios. Postnatal management of these children still remains a controversial topic among the nephrourologic community. Expectancy and close follow-up have progressively gained wide acceptance, although the surgical attitude, either systematic within the first months of life, or on the basis of variable morphological or functional parameters, is still the present attitude for many clinicians (Lee et al 2006, Subotic et al 2012, Szymanski et al 2011, Molina et al 2013, Sidhu et al 2006).

CONCLUSION

Two cases of antenatal hydronephrosis have been reported. On the first case, the antenatally detected hydronephrosis turned out to have severe left UVJ stenosis. After neointegration of left ureter, the baby was discharged in a good condition. On the second case, right kidney cyst was noted antenatally with right UPJ stenosis discovered later postnatally. Following percutaneous nephrostomy and nephrectomy the baby was also discharged in a good condition. Upon follow-ups (6 months to 1 year) after surgery, regular urinalysis, urine culture and US examination were kept in view to monitor the kidney function. Prognosis of this two cases was good nevertheless still require growth and development monitoring in the future.

REFERENCES

- Belarmino JM and Kogan BA (2006). Management of antenatal hydronephrosis. *Early Hum Dev* 82, 9-14
- Castagnetti M, Berrettini A, Cimador M, Sergio M, Rigamonti W, DeGrazia E (2010). Complications of transanastomotic externalized stents in open pyeloplasty: influence of the method of placement, the duration of stenting, and the associated bladder drainage. *Pediatr Surg Int* 26, 309-313
- Chertin B, Pollack A, Koulikov D, Rabinowitz R, Hain D, Hadas-Halpren I, Farkas A (2006). Conservative treatment of ureteropelvic junction obstruction in children with antenatal diagnosis of hydronephrosis: lessons learned after 16 years of follow up. *Eur Urol* 49, 734-738
- Cordero L, Nankervis CA, Oshaughnessy RW, Koff SA, Giannone PJ (2009). Post natal follow up of antenatal hydronephrosis: a health-care challenge. *J Perinatol* 29, 382-387
- Dagli MD and Ramchandani P (2011). Percutaneous nephrostomy: technical aspect and indication. *Semin Intervent Radiol* 28, 424-437
- Dudley JA, Haworth JM, McGraw ME, Frank JD, Tizard EJ (1997). Clinical relevance and implication

- of antenatal hydronephrosis. *Arch Dis Child Fetal Neonatal Ed* 76, F31-F34
- Estrada Jr RC (2008). Prenatal hydronephrosis: early evaluation. *Curr Opin Urol* 18, 401-403
- Farrugia KM (2013). Ureterovesical Junction Anomalies. Available from <http://www.pediatricurologybook.com/ureterovesical.html>. Accessed March 7, 2013
- Featherstone N, Boddy Su A, Murphy FL (2011). Indication and relative renal function for paediatric nephrectomy over a 20-year period. *Pediatr Surg Int* 27, 1227-1231
- Herndon A (2006). Antenatal hydronephrosis: differential diagnosis, evaluation and treatment options. *Sci World J* 6, 2345-2365
- Kangin M, Aksu N, Yavascan O (2010). Significance of postnatal follow up of infants with vesicoureteral reflux having antenatal hydronephrosis. *Iran J Pediatr* 20, 427-434
- Kim J, Hong S, Park CH, Park H, Kim SK (2010). Management of severe bilateral ureteropelvic junction obstruction in neonates with prenatally diagnosed bilateral hydronephrosis. *Korean J Urol* 51, 653-656
- Lee RS, Cedron M, Kinnamon DD, Nguyen HT (2006). Antenatal hydronephrosis as a predictor of postnatal outcome: a meta analysis. *Pediatrics* 118, 586-593
- Linscott L (2011). Pediatric urologic interventional radiology. *Semin Intervent Radiol* 28, 407-414
- Longpre M, Nguan A, MacNeily AE, Afshar K (2012). Prediction of the outcome of antenatally diagnosed hydronephrosis: a multivariable analysis. *J Pediatr Urol* 8, 135-139
- Molina CAF, Facincani I, Muglia VF, de Araujo WM, Cassini MF, Tucci Jr S (2013). Postnatal evaluation of intrauterine hydronephrosis due to ureteropelvic junction obstruction. *Act Cirr Bras* 28, 33-36
- Nguyen HT, Herndon CD, Cooper C, Gatti J, Kirsch A, Kokorowski P, Lee R, Perez-Brayfield M, Metcalfe P, Yerkes E, Cendron M, Campbell JB (2010). The society for fetal urology consensus statement on the evaluation and management of antenatal hydronephrosis. *J Pediatr Urol* 6, 212-231
- Pereira AK, Reis ZS, Bouzada MC, Oliveira EA, Osanan G, Viera Cabral AC (2011). Antenatal ultrasonography anteroposterior renal pelvis diameter measurement: is it a reliable way of defining fetal hydronephrosis. *Obstet Gynecol Int* 2011, 1-5
- Piepsz A (2007). Antenatally detected hydronephrosis. *Semin Nucl Med* 37, 249-260
- Prasetyo RV, Arfianto AR, Kurniawan MR, Soemyarso NA, Noer MS (2013). Clinical profiles of antenatal hydronephrosis at DR. Soetomo Hospital Surabaya Indonesia. Will be presented at 16th International Pediatric Nephrology Association Congress 2013 August 30th – Sept 4th, Shanghai, China
- Psooy K and Pike J (2009). Investigation and management of antenatally detected hydronephrosis. *Can Urol Assoc J* 3, 69-72
- Sidhu G, Beyene J, Rosenblum ND (2006). Outcome of isolated antenatal hydronephrosis: a systematic review and meta analysis. *Pediatr Nephrol* 21, 218-224
- Sinha A, Bagga A, Krishna A, Bajpai M, Sirinivas M, Uppal R, Agarwal I (2013). Revised guidelines on management of antenatal hydronephrosis. *Indian Pediatr* 50, 215-231
- Subotic U, Rohard I, Weber DM, Gobet R, Moehrlen U, Gonzalez R (2012). A minimal invasive surgical approach for children of all ages with ureteropelvic junction obstruction. *J Pediatr Urol* 8, 354-358
- Szymanski K, Oliveira LM, Silva A, Retik AB, Nguyen HT (2011). Analysis of indications for ureteral reimplantation in 3738 children with vesicoureteral reflux: a single institutional cohort. *J Pediatr Urol* 7, 601-610
- Tabel Y, Haskologlu ZS, Karakas MH, Yakinci C (2010). Ultrasonographic screening of newborns for congenital anomalies of the kidney and the urinary tracts. *Urol J* 7, 161-167
- Walsh TJ, Hsieh S, Grady R, Mueller B (2007). Antenatal hydronephrosis and the risk of pyelonephritis hospitalization during the first year of life. *J Urol* 69, 970-974
- Yamaçake KG and Nguyen HT (2013). Current management of antenatal hydronephrosis. *Pediatr Nephrol* 28, 237-243
- Yap HK, K Prabhakaran, Azar M (2012). Management of prenatally diagnosed. In: Yap HK, Liu DI, Tay WC (eds). *Pediatric Nephrology On The Go*, 1st ed., Singapore, Children Kidney Centre, National University Hospital, p 409-415

MANAGEMENT OF ANTENATAL HYDRONEPHOSIS. A REPORT OF 2 CASES

ORIGINALITY REPORT

18%

SIMILARITY INDEX

12%

INTERNET SOURCES

14%

PUBLICATIONS

0%

STUDENT PAPERS

PRIMARY SOURCES

1	www.sepeap.es Internet Source	1%
2	www.indianpediatrics.net Internet Source	1%
3	www.ncbi.nlm.nih.gov Internet Source	1%
4	www.repository.cam.ac.uk Internet Source	1%
5	Marie-Klaire Farrugia, Henrik A. Steinbrecher, Padraig S. Malone. "The utilization of stents in the management of primary obstructive megaureters requiring intervention before 1 year of age", Journal of Pediatric Urology, 2011 Publication	1%
6	docplayer.com.br Internet Source	1%
7	thenurseszone.com Internet Source	1%

8	Congenital Anomalies of the Kidney and Urinary Tract, 2016.	1 %
Publication		
9	Pediatric Nephrology, 2009.	1 %
Publication		
10	de Bruyn, Rosalie, and Lyn Chitty. "Pediatric and prenatal urological ultrasound", Urogenital Ultrasound A Text Atlas, 2006.	1 %
Publication		
11	www.studyblue.com	1 %
Internet Source		
12	"Handbook of Life Course Health Development", Springer Nature, 2018	1 %
Publication		
13	Craig A. Peters, James Mandell, Robert L. Lebowitz, Arnold H. Colodny, Stuart B. Bauer, W. Hardy Hendren, Alan B. Retik. "Congenital Obstructed Megaureters in Early Infancy: Diagnosis and Treatment", The Journal of Urology, 1989	<1 %
Publication		
14	J A Dudley, J M Haworth, M E McGraw, J D Frank, E J Tizard. "Clinical relevance and implications of antenatal hydronephrosis", Archives of Disease in Childhood - Fetal and Neonatal Edition, 1997	<1 %
Publication		

15 Keith E. Britton. "Chapter 10 Renography and renal imaging", Springer Science and Business Media LLC, 1986
Publication <1 %

16 rd.springer.com
Internet Source <1 %

17 Luke Linscott. "Pediatric Urologic Interventional Radiology", Seminars in Interventional Radiology, 2012
Publication <1 %

18 dergipark.ulakbim.gov.tr
Internet Source <1 %

19 www.kdigo.org
Internet Source <1 %

20 "Pediatric Nephrology", Springer Science and Business Media LLC, 2016
Publication <1 %

21 archive.org
Internet Source <1 %

22 www.semanticscholar.org
Internet Source <1 %

23 Pediatric Surgery, 2009.
Publication <1 %

24 juri.urologi.or.id
Internet Source <1 %

25	"Abstracts for IPNA Congress in Shanghai, China 2013", Pediatric Nephrology, 2013 Publication	<1 %
26	"Solid Organ Transplantation in Infants and Children", Springer Science and Business Media LLC, 2018 Publication	<1 %
27	atharvapub.net Internet Source	<1 %
28	"Abstracts for the IPNA Congress, 30 August - 3 September 2013, Shanghai, China", Pediatric Nephrology, 2013 Publication	<1 %
29	coek.info Internet Source	<1 %
30	doaj.org Internet Source	<1 %
31	www.journalofhospitalmedicine.com Internet Source	<1 %
32	www.researchsquare.com Internet Source	<1 %
33	Gunadi, Munawir Makkadafi, Aditya Rifqi Fauzi, Amsyar Praja, Kemala Athollah, Marcellus. "Emergency high ligation in a suspected COVID-19 pediatric patient with	<1 %

incarcerated inguinal hernia: A case report",
Annals of Medicine and Surgery, 2021

Publication

34

Medical Radiology, 2014.

Publication

<1 %

35

Samuel Nef, Thomas J. Neuhaus, Giuseppina Spartà, Marcus Weitz et al. "Outcome after prenatal diagnosis of congenital anomalies of the kidney and urinary tract", European Journal of Pediatrics, 2016

Publication

<1 %

36

Young Hun Choi, Jung-Eun Cheon, Woo Sun Kim, In-One Kim. "Ultrasonography of hydronephrosis in the newborn: a practical review", Ultrasonography, 2016

Publication

<1 %

37

open.bu.edu

Internet Source

<1 %

38

Iosif Mendichovszky, Bernardita Troncoso Solar, Naima Smeulders, Marina Easty, Lorenzo Biassoni. "Nuclear Medicine in Pediatric Nephro-Urology: An Overview", Seminars in Nuclear Medicine, 2017

Publication

<1 %

39

Oktar, Tayfun, Ã–mer Acar, Arda Atar, Emre Salabas, Haluk Ander, Orhan Ziyilan, Ibrahim Kalelioglu, Recep Has, and Atil Yuksel. "How

<1 %

Does the Presence of Antenatally Detected Caliectasis Predict the Risk of Postnatal Surgical Intervention?", Urology, 2012.

Publication

40

Pravin K. Rao, Jeffrey S. Palmer. "Prenatal and Postnatal Management of Hydronephrosis", The Scientific World JOURNAL, 2009

Publication

<1 %

41

Renfang Song, Ihor V. Yosypiv. "Development of the kidney medulla", Organogenesis, 2014

Publication

<1 %

42

Utku Karaarslan, Rana İşgüder, Özlem Bağ, Miray Kışla, Hasan Ağın, Nurettin Ünal. "Alpha lipoic acid intoxication, treatment and outcome", Clinical Toxicology, 2013

Publication

<1 %

43

Vijaya Vemulakonda, Jenny Yiee, Duncan T. Wilcox. "Prenatal Hydronephrosis: Postnatal Evaluation and Management", Current Urology Reports, 2014

Publication

<1 %

44

afju.springeropen.com

Internet Source

<1 %

45

peerj.com

Internet Source

<1 %

46

urofact.com

Internet Source

<1 %

47 www.bibliotecadigital.ufmg.br <1 %
Internet Source

48 www.endocrine.org <1 %
Internet Source

49 www.labome.org <1 %
Internet Source

50 Mohammed S. ElSheemy. "Postnatal management of children with antenatal hydronephrosis", African Journal of Urology, 2020 <1 %
Publication

Exclude quotes On

Exclude matches Off

Exclude bibliography On

MANAGEMENT OF ANTENATAL HYDRONEPHOSIS. A REPORT OF 2 CASES

GRADEMARK REPORT

FINAL GRADE

/100

GENERAL COMMENTS

Instructor

PAGE 1

PAGE 2

PAGE 3

PAGE 4

PAGE 5

PAGE 6

PAGE 7

PAGE 8

PAGE 9
