

Received: 2021.08.25

Accepted: 2021.11.04

Available online: 2021.11.16

Published: 2021.12.27

Laparotomy for Abdominal Adhesion and Removal of Intrauterine Device from Anatomically Distorted Uterus due to Adhesion in a 43-Year-Old Woman with 3 Previous Cesarean Sections

Authors' Contribution:

Study Design A
Data Collection B
Statistical Analysis C
Data Interpretation D
Manuscript Preparation E
Literature Search F
Funds Collection G

ABCE **Brahmana Askandar Tjokroprawiro**

Department of Obstetrics and Gynecology, Dr. Soetomo General Academic Hospital, Medical Faculty – Universitas Airlangga, Surabaya, Indonesia

Corresponding Author: Brahmana Askandar Tjokroprawiro, e-mail: brahmanaaskandar@gmail.com**Financial support:** None declared**Conflict of interest:** None declared

Patient: Female, 43-year-old
Final Diagnosis: Uterine adhesion to abdominal wall
Symptoms: Chronic pelvic pain
Medication: —
Clinical Procedure: Laparotomy
Specialty: Obstetrics and Gynecology

Objective: Unusual clinical course

Background: Adhesion is a complication of cesarean section. Adhesion of the uterus to the bladder or abdominal wall due to cesarean section can cause discomfort and anatomic distortion. Furthermore, removing intrauterine devices (IUDs) becomes challenging with anatomic distortion of the uterus. This report describes the case of a woman with a history of 3 previous cesarean sections who required laparotomy for abdominal adhesion and removal of an IUD from an anatomically distorted uterus due to adhesion.

Case Report: The patient was a 43-year-old woman who presented with pelvic pain. She had an IUD inserted 2 months after her third cesarean delivery 7 years earlier and started to experience chronic pelvic pain with regular and painful menstruation over the last 4 years and worsening since the last 1 year. On clinical evaluation, the thread of the IUD was missing, and ultrasonography confirmed the presence of the IUD inside the uterus. Because the cervix could not be visualized on speculum examination, vaginal removal of the IUD was considered impossible. Since the IUD could not be removed via the vaginal route and hysteroscopy and laparoscopy could not be performed, the patient underwent laparotomy. It was found that the uterus was severely adhered to the abdominal wall, and the IUD was located inside the uterus. Adhesiolysis and IUD removal were performed. The patient was relieved from the chronic pelvic pain.

Conclusions: This report demonstrates the risk of adhesion after multiple cesarean deliveries and the required surgical intervention performed to remove an IUD and adhesiolysis.

Keywords: Contraception • Laparotomy • Pelvic PainFull-text PDF: <https://www.amjcaserep.com/abstract/index/idArt/934530>


1740



—



4



21



Background

Postoperative adhesions are a common long-term complication after cesarean delivery, and an increasing number of cesarean sections confers a higher risk. The incidence of dense adhesions after 3 cesarean deliveries is reportedly 56.4% to 59% [1,2], with most adhesions occurring between the uterus and abdominal wall (53.7%) [1]. Adhesions caused by cesarean delivery can cause pelvic pain, infertility, and anatomical distortion. The only treatment for pain caused by adhesion is surgical adhesiolysis [3]. Several surgical adhesiolysis procedures via laparoscopy and laparotomy have been reported [4]. Anatomical distortion also makes intrauterine device (IUD) removal difficult. Previous studies have reported the removal of malpositioned or migrated IUDs [5-7] but not IUD removal from an anatomically distorted uterus caused by adhesion. Most of the malpositioned IUDs were caused by uterine anomalies, such as a septate uterus, bicornuate uterus, and fibroids [8]. The difficulty in performing IUD removal in our case was due to the anatomical distortion of the uterus caused by the adhesion of the uterus to the abdominal wall.

We report the case of a woman whose IUD thread was found missing due to the anatomical distortion of the uterus secondary to postoperative adhesions. This resulted in attachment of the uterus to the anterior abdominal wall with upward displacement, making it difficult to visualize the cervix during speculum examination. Despite the intrauterine location of the IUD, the patient underwent surgical removal of the IUD and adhesiolysis via laparotomy because the anatomical distortion precluded vaginal removal. This report describes the case of a 43-year-old woman with a history of 3 previous cesarean sections who required laparotomy for abdominal adhesion and removal of an IUD from the anatomically distorted uterus due to adhesion.

Case Report

A 43-year-old woman with a history of 3 cesarean sections visited an outpatient clinic with a 1-year history of intense pelvic pain. The indications for the cesarean sections were a breech presentation, recent cesarean section (within the preceding 2 years), and history of 2 previous cesarean sections. All cesarean sections were performed in a tertiary hospital with a Pfannenstiel incision. Adhesion prevention agents were not used in any of these surgeries. The last cesarean section was performed 7 years before the current presentation, and an IUD (Nova T; Bayer) was inserted 2 months after this delivery. No postoperative infection was observed after surgery and IUD insertion. Moreover, the patient did not develop any abdominal infection after IUD insertion.

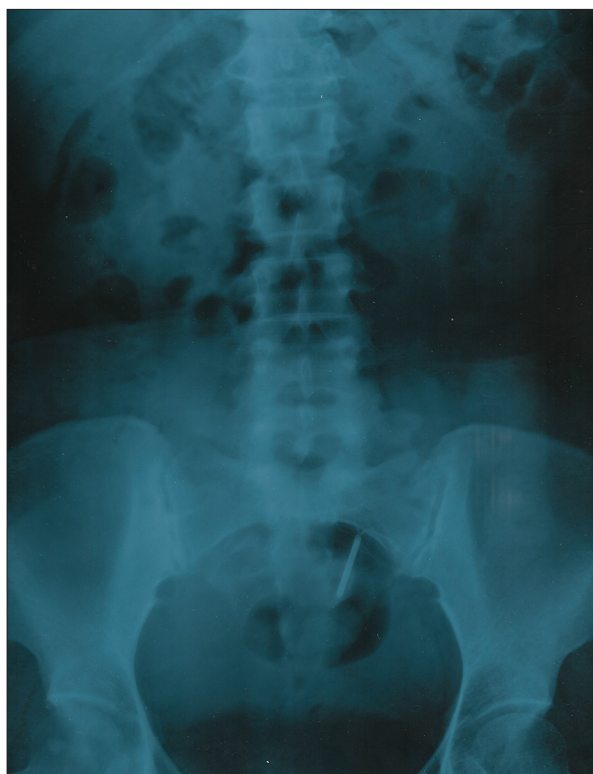

Figure 1. Plain abdominal radiograph showing the intrauterine device, which is to be pulled upward and obliquely because of the anatomical distortion of the uterus due to the adhesion to the abdominal wall.

Four years prior to presentation, the patient developed chronic pelvic pain, which had worsened over the last 1 year. She had not undergone any other surgical interventions. She had a regular menstrual cycle. Two years before the current presentation, the patient visited a gynecologist to have the IUD removed. However, this attempt was unsuccessful. According to the patient, the gynecologist could not reach the cervix. Subsequently, she did not follow up for another attempt at IUD removal.

She continued to experience pelvic pain and visited a gynecologic outpatient clinic to have the IUD removed and convert to oral contraception. At this stage, the patient had a pain score of 8 out of 10 using the Wong-Baker Faces Pain rating scale to describe the pain she experienced. A vaginal examination performed using a Cusco vaginal speculum revealed an upwardly displaced cervix that was not visible on examination. Pelvic ultrasonography revealed an intrauterine IUD; however, visualizing the cervix on the roof of the vagina was challenging because the cervix was pulled upward. Plain abdominal radiography showed that the IUD was in the uterus but had shifted upward in an oblique position because of the anatomical distortion of the uterus due to the adhesion to the abdominal wall (**Figure 1**). Computed tomography (CT)

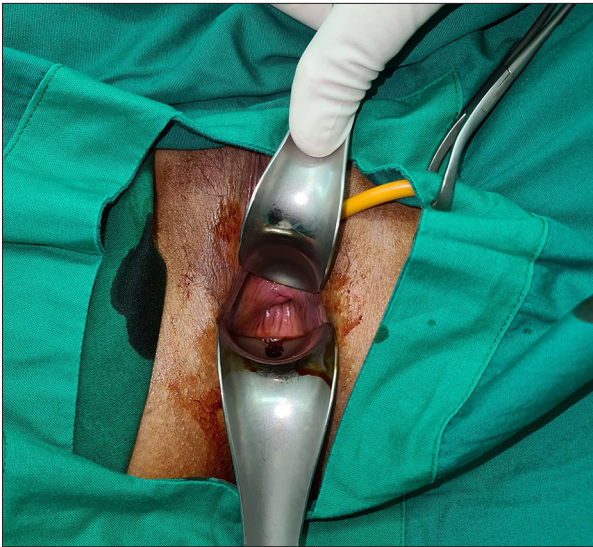

Figure 2. The cervix could not be visualized during evaluation under anesthesia in the operating theater. It was retracted cranially.

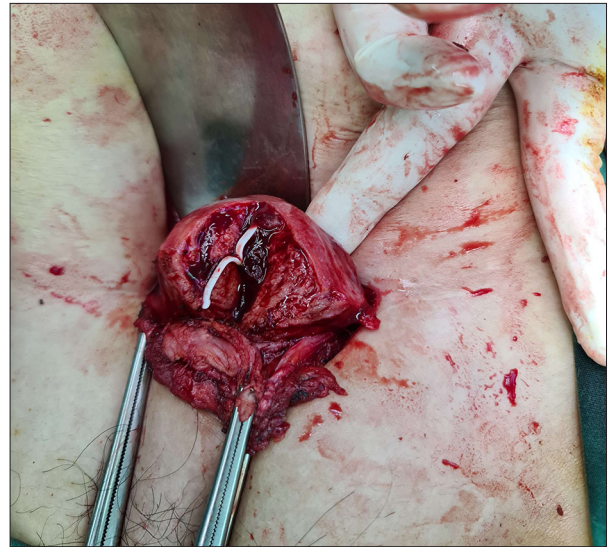


Figure 4. The Intrauterine device is observed inside the uterus after uterine wall incision.

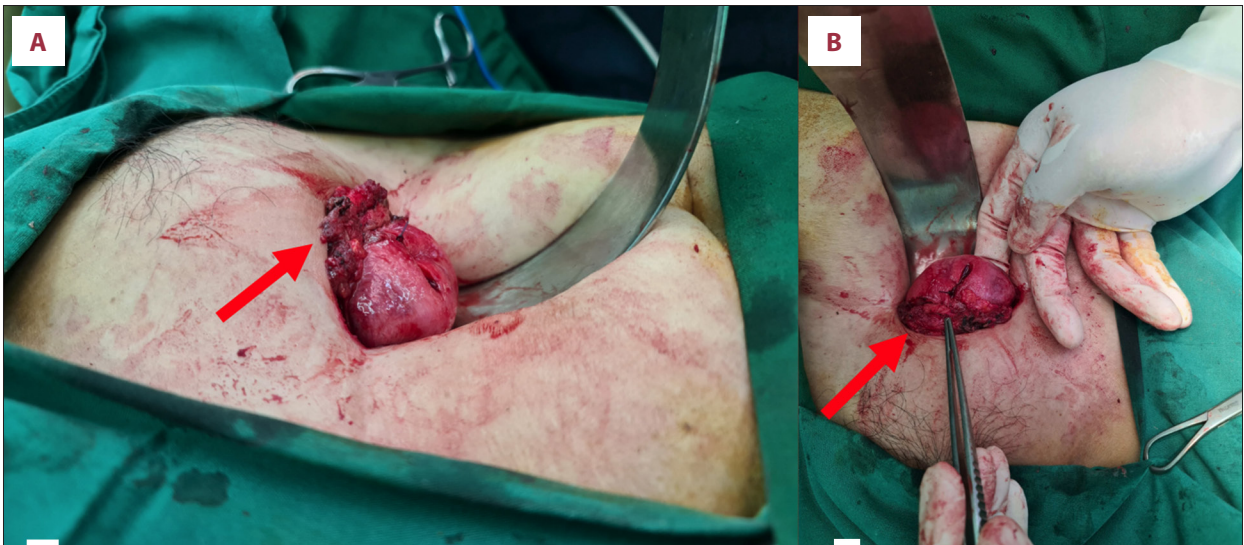

Figure 3. The uterus is pulled upward and adheres to the abdominal wall below the Pfannenstiel incision of the previous cesarean deliveries. The adhesion site (arrow) viewed from (A) left side and from (B) below.

scanning and magnetic resonance imaging (MRI) were not available in this hospital.

The patient was referred to the day-care operating theater for evaluation and IUD removal under anesthesia. In the operating theater, the cervix could not be visualized despite the use of 2 Jackson vaginal retractors (Figure 2). On bimanual examination, the cervix was palpated with difficulty. It appeared very small and was pulled upward. With no visible cervix, traction of the cervix was not possible, making it difficult to insert an instrument through the cervical canal. Downward fundal pressure also failed to help the visualization of the cervix, and it

was subsequently decided that IUD removal via the vaginal approach had failed.

The patient insisted on IUD removal and wished to convert to oral contraception. Hysteroscopic facilities were not available in the hospital where the patient was treated, and she did not want to be referred. In developing countries such as Indonesia, only a few hospitals have hysteroscopy facilities. After explaining the options for surgical IUD removal and the risks of laparoscopy and laparotomy, the patient opted for laparotomy. A Pfannenstiel incision was made. Intraoperatively, a dense adhesion was located just under the Pfannenstiel incision,

which tethered the uterus to the abdominal wall with an upward displacement of the uterus (Figure 3A, 3B). The adhesion site on the uterus was in the anterior portion of the lower segment, where a low-segment cesarean section incision had been made previously. The anterior side of the lower uterine segment was attached to the peritoneum. The size of the uterus was normal. The uterine wall was incised, the IUD was located inside the uterus and was removed (Figure 4), and the uterine wall was closed. Adhesiolysis was performed. A Gynecare Interceed oxidized regenerated cellulose adhesion barrier (Ethicon Inc, Sommerville, NJ, USA) was placed at the adhesion site in the uterus before abdominal closure to prevent subsequent adhesions.

Discussion

Adhesions are the most common complication after cesarean delivery. Pelvic adhesions are associated with secondary infertility, chronic pelvic pain, and anatomical distortion of the reproductive organs [3]. Some cases reported migration of the IUD from the uterus to the bladder [5-7], but here, we report the case of a woman with a history of 3 cesarean deliveries with dense utero-abdominal wall adhesions that precluded vaginal IUD removal despite the intrauterine location of the IUD, which was removed via laparotomy. To the best of our knowledge, this is the first reported case of surgical removal of a uterine IUD due to distortion of the uterus from adhesions.

The pathogenesis of adhesions is multifactorial and includes factors such as tissue ischemia, blood clots, foreign bodies, manipulation, surgical technique, and infection [3,9]. Few studies have laparoscopically evaluated the risk of adhesions in women with previous cesarean sections because laparoscopic surgery is complicated in women after gynecologic surgery. However, Levin and Tulandi [10] reported a case of adhesions between the uterus and abdominal wall observed by laparoscopy in a woman with a history of cesarean section. In their case, there were dense adhesions between the uterus and the abdominal wall tethering the uterus to the abdominal cavity.

The patient in our case had had 3 cesarean sections. Therefore, the risk of adhesions was very high. The incidence of adhesions is reportedly 24.4% to 32% after 1 cesarean section, 42% after 2, and 42.8% to 59% after 3 cesarean sections [1,11]. Other factors that can increase the risk of adhesions after cesarean sections are older age (>35 years), body mass index >30 kg/m², and postpartum infection. Among these factors, the number of cesarean sections is the most critical risk factor [2]. The number of cesarean sections is not only associated with a higher risk of adhesions after cesarean section, but also influences the severity of the adhesions. Women with a history of multiple cesarean sections had more severe adhesions

than those with a history of 1 cesarean section [10,12]. The location of the adhesions after cesarean section also influences the symptoms. In particular, anterior compartment adhesions, such as utero-abdominal wall adhesions, are significantly associated with chronic pelvic pain [13]. The patient in the present case experienced chronic pelvic pain with a pain score of 8 using the Wong-Baker Faces pain rating scale, and this was likely due to adhesions. She had no history of sexually transmitted disease and had never had any other surgical intervention. Cesarean sections were the only surgery she had undergone thus far.

Several case reports of surgical removal of IUDs have been published previously. The indications for surgical removal in these case reports were uterine perforation from the IUD and extrauterine migration of the IUD [14-17]. Laparoscopy, hysteroscopy, and laparotomy have been reported as surgical methods for IUD removal [14,18,19]. Laparotomy was used in only a few cases for surgical IUD removal, and the indications for surgery were all due to extrauterine migration of the IUD [14,20]. In our case, the indication for laparotomy was the anatomical distortion caused by a severe adhesion between the uterus and abdominal wall, resulting in failed attempts at removal vaginally, including under anesthesia, because the uterus was pulled upward, making it impossible to visualize and grasp the cervix. Hysteroscopy facilities are not widely available in developing countries such as Indonesia, and the patient was reluctant to be referred to a tertiary hospital as she felt that this hospital was safer in terms of COVID-19 exposure, whereas the tertiary hospital would have more COVID-19-positive patients. After counseling her regarding the available surgical options, the patient opted for laparotomy to remove the IUD. She considered a laparotomy to be the best option during the pandemic, as she wanted the chronic pelvic pain relieved without delay.

After adhesiolysis, we placed oxidized regenerated cellulose (Gynecare Interceed, Ethicon, Inc.) to prevent subsequent adhesions. Rottenstreich et al reported the effectiveness of absorbable adhesion barriers in cesarean section to prevent postoperative adhesions [21]. Oxidized regenerated cellulose has been approved for use in open gynecologic surgery to prevent adhesions after ensuring hemostasis [3]. Three months after the surgical removal of the IUD, the patient did not report chronic pelvic pain. However, further adhesions might still occur.

Conclusions

This case shows that cesarean sections (multiple cesarean sections in particular) are associated with a risk of severe adhesions and anatomical distortion of the uterus. This complication made IUD removal difficult, caused chronic pelvic pain, and necessitated laparotomy. This case demonstrates the importance

of good surgical techniques and meticulous control of bleeding during cesarean sections to reduce the risk of postoperative adhesions. We recommend that cesarean section should only be considered in the case of strong indications.

References:

1. Tulandi T, Agdi M, Zarei A, Miner L, Sikirica V. Adhesion development and morbidity after repeat cesarean delivery. *Am J Obstet Gynecol.* 2009;201(1):56.e1-6
2. Hesselman S, Högberg U, Råsjö EB, et al. Abdominal adhesions in gynaecologic surgery after caesarean section: A longitudinal population-based register study. *Int J Obstet Gynaecol.* 2018;125(5):597-603
3. Poole JH. Adhesions following cesarean delivery: A review of their occurrence, consequences and preventative management using adhesion barriers. *J Womens Health.* 2013;9(5):467-77
4. Hammoud A, Gago LA, Diamond MP. Adhesions in patients with chronic pelvic pain: A role for adhesiolysis? *Fertil Steril.* 2004;82(6):1483-91
5. Gyasi-Sarpong CK, Maison POM, Morhe E, et al. Intravesical migration of an intrauterine device. *BMC Res Notes.* 2016;9(1):4
6. Vahdat M, Gorginzadeh M, Mousavi AS, et al. Cystoscopic removal of a migrated intrauterine device to the bladder; A case report. *Contracept Reprod Med.* 2019;4:7
7. Liu G, Li F, Ao M, Huang G. Intrauterine devices migrated into the bladder: Two case reports and literature review. *BMC Womens Health.* 2021;21(1):301
8. Gerkowicz SA, Fiorentino DG, Kovacs AP, et al. Uterine structural abnormality and intrauterine device malposition: analysis of ultrasonographic and demographic variables of 517 patients. *Am J Obstet Gynecol.* 2019;220(2):183.e1-e8
9. Walfisch A, Beloosesky R, Shrim A, Hallak M. Adhesion prevention after cesarean delivery: Evidence, and lack of it. *Am J Obstet Gynecol.* 2014;211(5):446-52
10. Tulandi T, Al-Sannan B, Akbar G, et al. Clinical relevance of intra-abdominal adhesions in cesarean delivery. *Gynecol Surg.* 2011;8(4):399-403
11. Nuamah MA, Browne JL, Öry AV, et al. Prevalence of adhesions and associated postoperative complications after cesarean section in Ghana: A prospective cohort study. *Reprod Health.* 2017;14(1):143
12. Nisenblat V, Barak S, Griness OB, et al. Maternal complications associated with multiple cesarean deliveries. *Obstet Gynecol.* 2006;108(1):21-26
13. Moro F, Mavrelos D, Pateman K, et al. Prevalence of pelvic adhesions on ultrasound examination in women with a history of Cesarean section. *Ultrasound Obstet Gynecol.* 2015;45(2):223-28
14. Uysal G, Nazik H, Tanridan Okçu N, et al. Surgical removal of an extrauterine device migrating to appendix. *Case Rep Med.* 2016;2016:4732153
15. Lei Y, Iablakov V, Karmali RJ, Forbes N. Endoscopic removal of migrated intrauterine device: Case report and review of literature and technique. *ACG Case Rep J.* 2019;6(6):e00090
16. Mederos R, Humaran L, Minervini D. Surgical removal of an intrauterine device perforating the sigmoid colon: A case report. *Int J Surg.* 2008;6(6):e60-e62
17. Cheung M-L, Rezaei S, Jackman JM, et al. Retained intrauterine device (IUD): Triple case report and review of the literature. *Case Rep Obstet Gynecol.* 2018;2018:9362962
18. Demir SC, Çetin MT, Ürünsak IF, et al. Removal of intra-abdominal intrauterine device by laparoscopy. *Eur J Contracept Reprod Health Care.* 2002;7(1):20-23
19. Asto MRD, Habana MAE. Hysteroscopic-guided removal of retained intrauterine device: Experience at an academic tertiary hospital. *Gynecol Minim Invasive Ther.* 2018;7(2):56-60
20. Ozgun MT, Batukan C, Serin IS, et al. Surgical management of intra-abdominal mislocated intrauterine devices. *Contraception.* 2007;75(2):96-100
21. Rottenstreich M, Rotem R, Hirsch A, et al. The use of absorbable adhesion barriers to reduce the incidence of intraperitoneal adhesions at repeat cesarean delivery. *Arch Gynecol Obstet.* 2020;302(1):101-8

Declaration of Figures' Authenticity

All figures submitted have been created by the authors who confirm that the images are original with no duplication and have not been previously published in whole or in part.