

**Case report:****DENTIGEROUS CYST AND CANINE IMPACTION AT THE ORBITAL FLOOR****Ferdian Rizky Hutomo<sup>1</sup>, Ellen Satya Pratiwi<sup>1</sup>, Viskasari P. Kalanjati<sup>2</sup>, Andra Rizqiawan<sup>3</sup>**<sup>1</sup>Resident of Oral and Maxillofacial Surgery, Faculty of Dental Medicine, <sup>2</sup>Department of Anatomy and Histology, Faculty of Medicine, Universitas Airlangga, <sup>3</sup>Dental Clinic of Universitas Airlangga Hospital, Surabaya, Indonesia**ABSTRACT**

*Dentigerous cysts are cysts of the epithelial lining of the jaws derived from the dental follicle of unerupted teeth. These cysts are often found during routine radiographic examination along with unerupted teeth. Dentigerous cysts are usually asymptomatic unless the size becomes large, thus causing swelling. This case report describes the management of dentigerous cyst in the upper left canine region with canine impaction to the orbital floor. Dentigerous cyst was treated with cyst enucleation but the impacted canine was not taken because of the magnitude of risk that can occur which was a disruption to the eye muscle. Conclusion. Treatment of dentigerous cysts can be performed by enucleation technique and management related the impacted tooth at the orbital floor needs a further evaluation consideration.*

**Keywords:** *Dentigerous cyst; enucleation; impacted canine*

**ABSTRAK**

*Kista dentigerous adalah kista dari lapisan epitel rahang yang berasal dari folikel gigi gigi yang tidak erupsi. Kista ini sering ditemukan selama pemeriksaan radiografi rutin bersama dengan gigi yang tidak erupsi. Kista dentigerous biasanya tanpa gejala kecuali ukurannya menjadi besar, sehingga menyebabkan pembengkakan. Laporan kasus ini menggambarkan pengelolaan kista dentigerous di daerah kaninus kiri atas dengan impaksi kaninus ke lantai orbital. Kista dentigerous diobati dengan enukleasi kista tetapi taring yang terkena tidak diambil karena besarnya risiko yang dapat terjadi yang merupakan gangguan pada otot mata. Perawatan kista dentigerous dapat dilakukan dengan teknik enukleasi dan manajemen terkait gigi yang terkena dampak di lantai orbital membutuhkan pertimbangan evaluasi lebih lanjut.*

**Kata kunci:** *Kista dentigerous; enukleasi; taring impaksi*

**Correspondence:** Ferdian Rizky Hutomo, Resident of Oral and Maxillofacial Surgery, Faculty of Dental Medicine, Universitas Airlangga, Surabaya, Indonesia. E-mail: drg.ferdian@gmail.com

pISSN:2355-8393 • eISSN: 2599-056x • doi: <http://dx.doi.org/10.20473/fmi.v55i3.15508>  
 • Fol Med Indones. 2019;55:234-238 • Received 25 Jul 2018 • Accepted 6 Dec 2018  
 • Open access under CC-BY-NC-SA license • Available at <https://e-journal.unair.ac.id/FMI/>

**INTRODUCTION**

A cyst is defined as a pathological space filled with liquid, semi liquid materials or gas and is always layered by an epithelial layer and the outer part is layered by connective tissues and blood vessels (Birnbaum & Dunne 2010). A dentigerous cyst is a pathological space that is constricted by epithel or connective tissues that is constricted by layered squamous epithelium that is formed around the crown of the unerupted tooth and contains liquid (Birnbaum & Dunne 2010). Based on World Health Organization (WHO) classification, a dentigerous cyst is a cyst originated from the epithelial layer of the jaw that occurs because the growth process comes from the dental follicle of unerupted tooth or is still in the

eruption process (after calcification process) (Birnbaum & Dunne 2010).

The dentigerous cyst is usually detected in adolescences, teenagers and also adults, although sometimes also found in the elderly (Adams et al 2000). This cyst can occur in the age range of 3-57 years old, and in a study in Brazil 10 out of 17 cases the cyst occurred in children below 15 years old (Damayanti 2003). This cyst is found more in men compared to women and almost 60% of this cyst occurs in the second until the third decade of life. Around 70% of this lesion occurs in the mandible and 30% in the maxilla (Adams et al 2000). Odontogenic cyst is the most common cyst found in the maxilla (Dagistan et al 2007, Dunlap 2000). Almost 62% cases is found in the molar teeth,

12% in premolars, and 12% in the canine and the rest 14% occurs in other sites of the jaw bone. The prevalence of dentigerous cyst in the caucasian population is higher compared to the non-caucasian population (Adams et al 2000).

The clinical signs that occur are slow progressed swelling, without pain, and hard palpation showing cortical expansion. Pain and vast swelling present indicates inflammation. If this cyst is aspirated, a yellowish clear fluid will be obtained (Dunlap 2000). The histological view of the cyst wall shows that the cyst is coated by reduced enamel epithelium. The stroma of connective tissue shows primitive ectomesenchymal image type. This finding depends on the presence of inflammatory component in the cyst. An uninfected cyst has a compact epithelium layer with 2-4 layers composed by primitive ectomesenchymes. This cell layer is more cuboid than columnar and rete pegs (epithelial papil that enters the connective tissue stroma below the epithel) are found. The loose connective tissue stroma is rich with acid mucopolysaccharides. The characteristic of inflammed dentigerous cyst is a hyperplastic rete peg and the cyst wall showing inflammatory cell infiltration (Birnbaum & Dunne 2010). Surgical treatment of choice is usually an enucleation with impacted tooth extraction, however this depends on the case. Here we provide information towards clinicians about a choice of treatment of maxillar dentigerous cyst with canine tooth impaction near the floor of the orbita without extraction of the tooth.

## CASE REPORT

A 20-year-old female patient was admitted to Dr. Soetomo Hospital, Surabaya with a chief complaint of a

recurring bump in the left palate of the mouth. The bump was noticed since 1 month ago. The bump was initially small then it grew bigger, never shrinking, no history of fluid secretion, and no history of pain. Two years ago a marsupialisation surgery was conducted in the same location as the current bump. At that time the bump was diagnosed as a dentigerous cyst. Then the patient was instructed to use removable obturator appliance, but when the patient felt that the bump was gone and healed the patient did not control and the appliance was not used anymore. The patient denied any history of hypertension, diabetes, and drug allergy.

In the physical examination, the patient was in generally good health. From an extra oral clinical examination (Figure 1), there was assymetry of the face, inflammation in left maxilla region with unclear margin, with similar color to the surrounding tissues. From palpation there was a left maxillar region swelling, with a clear margin, 1x1x0,5 cm in size, solid, the temperature was similar to the surrounding tissue, and no pain in palpation was detected.

In the intra oral examination (Figure 2), tooth 23 was not visible, silting of the vestibule was present in the regions of 23 to 25, with uniform color compared to the surrounding tissue. There was a mass in the sinistra palatal region from 23 to 25, with a uniform color compared to the surrounding tissue, in palpation a mass in the vestibulum of 23 to 25 was palpable, with a clear margin, 1x1x0.5 cm in size, solid consistency, cystic impression, and no pain on palpation. The mass on the left palatal regio 23 to 25, with a clear margin, size approximately  $\pm 2 \times 1,5 \times 1$  cm, solid consistency, cystic impression, and with pingpong ball phenomena on the bipalpatation examination of the palatal and buccal masses. No pain on palpation.

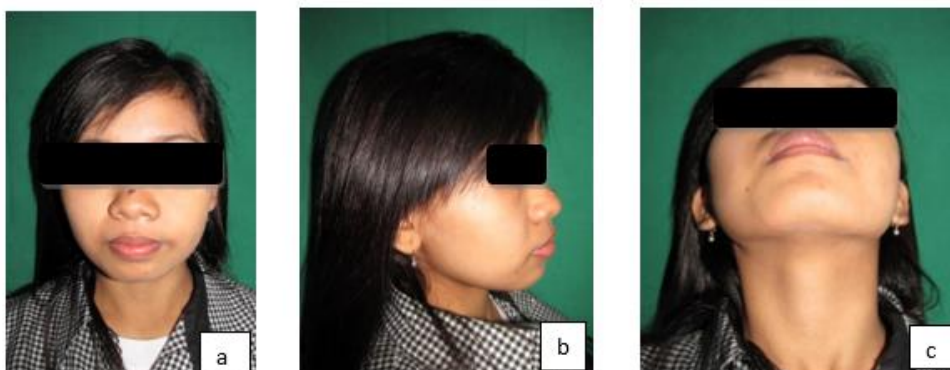


Fig. 1. Extra oral clinical photo: a. Front view, assimetrical face could be detected on the left maxilla region with unclear margin swelling, b. Right view, c. Bottom view.

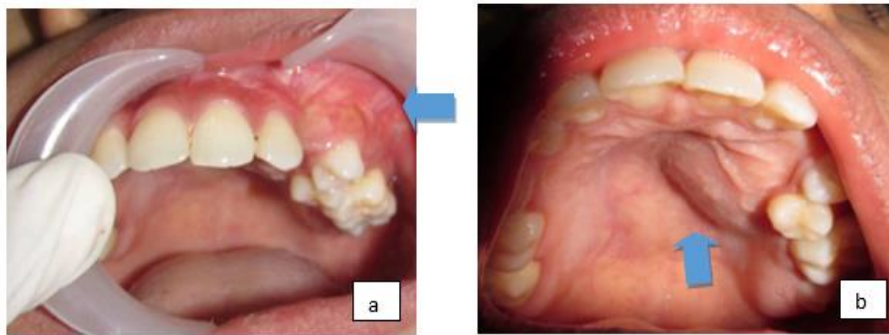


Fig. 2. a. A mass on the buccal vestibulum, b. A mass on the palatum region.

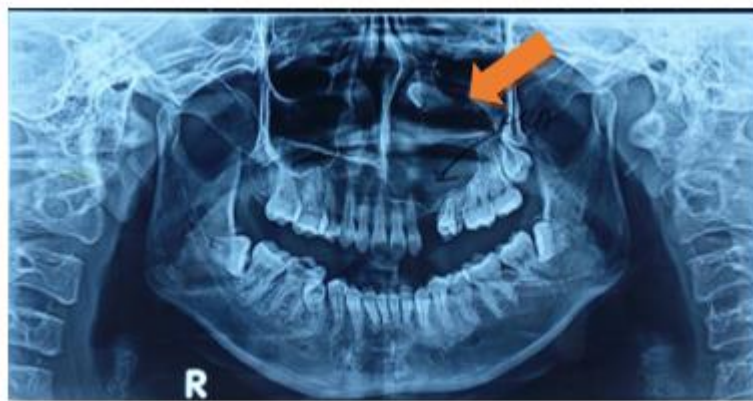

Fig. 3. Panoramic radioimaging showed a radiolucent lesion on the apex of left upper tooth with impaction of 23 at the orbital floor.

From the panoramic imaging, the lesion was radiolucent with a thin radiopaque border, the lesion expanding from 21 to 26 with expansion to the superior direction and reached the floor of the orbita; a radiopaque image from the unerupted canine at the base of the orbita shown.

### CASE MANAGEMENT

From the clinical and radiology examinations in this case, the diagnosis was a dentigerous cyst caused by impacted 23. The management process of the cyst was enucleation because in enucleation the cyst tissue could be taken completely thus minimizing the recurrency of this cyst with one day surgical hospitalization. After the operation, the cyst lesion was sent for histopathology examination; tissue layered by stratified squamous epithelium was identified; no spesific processes or malignant signs; the conclusion was in accordance with a dentigerous cyst.

During the surgery, it was decided the canine was not taken due to the high position of the canine that close to vital facial structures such as the inferior oblique muscle, the ophthalmic vein, and the post-surgical

oedema that may pressure towards the infraorbital nerve. The biopsy results after cyst enucleation showed no specific process or malignancy, thus diagnosed as a dentigerous cyst.

### DISCUSSION

In this case there are no tooth resorbtion around the cyst thus clinically there are no loosening of any teeth, thus no extraction was indicated. The impacted 23 involved in the cyst, is seen to shift apically because it was pressured by the cyst mass superiorly hence resided near the orbital floor. The canine is an important for occlusion, aesthetically and jaw development. The eruption of the canine teeth occurs between the age of 10 to 12 years old. Disruptions that involve the permanent upper canine tooth eruption is common, because the canine can develop inside the bone and needs a longer movement time before erupting in the oral cavity, compared to other teeth. No natural eruption, caused by impaction, could cause dentigerous cyst to occur (Pedulla et al 2015).

The dentigerous cyst is a cyst that connects with the crown of the tooth or unerupted-developing tooth

(Syafriadi 2008). Tooth impaction causes fluid transudation that crosses the capillary walls. The hydrostatic pressure makes the follicle separated from the crown thus causing cyst expansion. Basically this cyst occurs because of normal follicular space dilatation around the erupting crown caused by tissue or blood fluid accumulation. Cyst proliferation occurs because of a hyperosmolarity process that causes destructions from the center part, followed by increased osmotic gradient pressure that would pump the fluid from the outer part of the cyst into the lumen. The cyst will expand and press the surrounding areas including the surrounding soft tissue (Damayanti 2003, Syafriadi 2008).

The dentigerous cyst could easily be identified radiologically because of the typical radiographic view. Usually it is viewed as a simmetrical, unilocular, clear margin, and surrounding unerupted (impacted) tooth crown except for infected cysts which borders are unclear (Shear 2012, Pramono 2006). The slow and regular growth of the cyst, makes the dentigerous cyst have a distinct sclerotic border, with a clear cortex, and marked by a thin radiopaque border, especially if the cyst is relatively large in size or if there was a shift of the tooth position (Pramono 2006, Sudiono 2011).

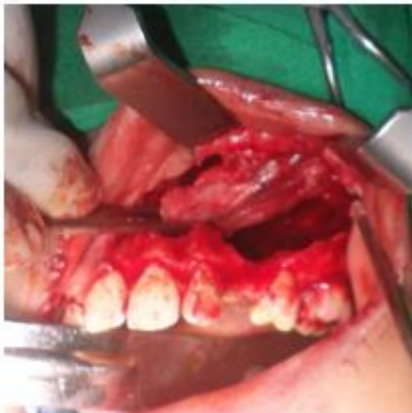

Fig. 4. Cyst space after enucleation.

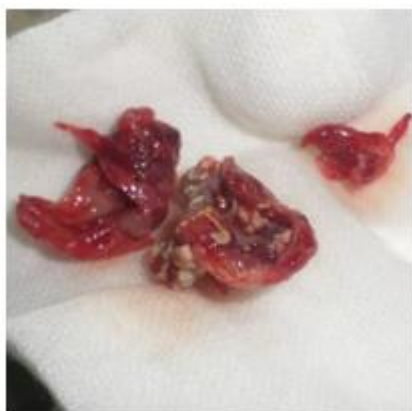

Fig. 5. Dentigerous cyst lesion.

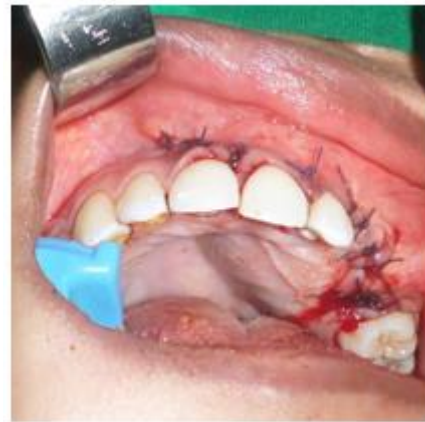

Fig. 6. Intra oral after cyst enucleation.

The dentigerous cyst has a potential of expanding, causing medullary bone destruction and jaw enlargement. The dentigerous cyst has a tendency to push and resorb the adjacent teeth. The cyst generally develops in one tooth, but could also involve a few surrounding teeth if the cyst grows larger. This then might cause a shift of the tooth far from its normal position especially the cysts occur in the upper jaw teeth (Pedulla et al 2015, Mhaske et al 2009, Shear 2012). The shift of the impaction and the dentigerous cyst itself could cause disruption towards the surrounding tissue. The impacted teeth in the maxillary sinus or at the maxillary sinus roof below the orbital floor could cause sinus obstruction that may cause chronic sinusitis. When the cyst in the maxillary sinus becomes symptomatic, the patient would experience sinusitis symptoms including swelling, facial pain, headache, and nasolacrimal duct obstruction (Baykul et al 2006). The anterior palatal region of the tooth obtains innervation from the infraorbital nerve branch which is the superior anterior alveolaris nerve. The impaction position at the orbital floor could injure the infraorbital nerve that might produce a sensation of pain or parasthesia; this injury must also be avoided during the surgery (Barbieri et al 2017, Moore et al 2014). The position of the impaction below the orbital floor is also associated with the angular branch of facial vein. Abscess formation or infection after surgery could spread via this vein and the ophthalmic vein then go into the cavernous sinus, causing cavernous sinus thrombosis (Moore et al 2014, Berkovitz 2016, Wang et al 2009).

## CONCLUSION

One of the proper treatment choices to manage a dentigerous cyst and impacted canine is a cyst enucleation technique, with an odontectomy of the impacted tooth accordingly. In this case the odontectomy of the impacted canine was decided not to be conducted,



because of the location of the canine tooth that was near vital facial structures, including the inferior oblique muscle, ophthalmic vein flow, and infraorbital nerve. If extraction was done, there would be disadvantages towards the patient, thus it was decided not to extract the tooth. Routine evaluations with series of post-surgery panoramic images are conducted accordingly.

## REFERENCES

- Adams GL, Boies LR, Higler PA (2000). Buku ajar penyakit THT. 6 Ed. Jakarta, EGC
- Barbieri D, Capparè P, Gastaldi G, Trimarchi M (2017). Ectopic tooth involving the orbital floor and infraorbital nerve. *Journal of Osseointegration*, 323-5
- Baykul T, Dogru H, Yasan H, Cina AM (2006). Clinical impact of ectopic teeth in the maxillary sinus. *Auris Nasus Larynx* 33, 277-81
- Berkovitz BK (2016). Oral cavity. *Gray's Anatomy*. London, Elsevier
- Birnbaum W, Dunne SM (2010). Diagnosis kelainan dalam mulut: Petunjuk bagi Klinisi. Jakarta, EGC
- Dagistan S, Cakur B and Göregen M (2007). A dentigerous cyst containing an ectopic canine tooth below the floor of the maxillary sinus: A case report. *J Oral Sci.* 49, 249-52
- Damayanti S (2003). Patogenesis, diagnosis dan penatalaksanaan medik sinusitis. *Simposium Penatalaksanaan Otitis Media Supurativa Kronik, Sinusitis Dan Demo Timpanoplasti*, Bali
- Dunlap C (2000). Cysts of the jaws
- Mhaske S, Ragavendra R, Doshi JJ, Nadaf I (2009). Dentigerous cyst associated with impacted permanent maxillary canine. *People's Journal of Scientific Research* 2, 17-20
- Moore KL, Agur AMR, Dalley AF (2014). *Essential clinical anatomy*. Philadelphia, Lippincott Williams & Wilkins
- Pedulla E, Valentino J, Rapisarda S (2015). Endodontic surgery of a deviated premolar root in the surgical orthodontic management of an impacted maxillary canine. *J Endod.* 41, 1730-4
- Pramono C (2006). Kista odontogen dan non odontogen. Surabaya, Airlangga Universal Express
- Shear M (2012). Kista rongga mulut. 3rd Ed. Jakarta, EGC
- Sudiono J (2011). Kista Odontogenik. Jakarta. EGC
- Syafriadi M (2008). Patologi mulut: Tumor neoplastik & non neoplastik rongga mulut. 1st Ed. Yogyakarta, Andi
- Wang CJ, Huang PH, Wang YL, Shyng YC, Kao WB (2009). Dentigerous cyst over maxillary sinus: A case report and literature review. *Taiwan J Oral Maxillofac Surg.* 20, 116-24