

# Recurrent Oral Ulceration Associated to Group A $\beta$ - Hemolytic Streptococcus Reinfection in a Post-Rheumatic Heart Disease Patient

*by* Desiana Radithia

---

**Submission date:** 21-Dec-2018 05:07PM (UTC+0800)

**Submission ID:** 1059935370

**File name:** 36\_D17\_372\_Desiana\_Radithia\_Recurrent.pdf (605.91K)

**Word count:** 2214

**Character count:** 12587

## Recurrent Oral Ulceration Associated to Group A $\beta$ -Hemolytic Streptococcus Reinfection in a Post-Rheumatic Heart Disease Patient

Desiana Radithia<sup>1\*</sup>, Silfra Yunus Kende<sup>2</sup>, Adiastuti Endah Parmadiati<sup>1</sup>, Diah Savitri Ernawati<sup>1</sup>

1. Department of Oral Medicine, Faculty of Dental Medicine, Universitas Airlangga, Surabaya, Indonesia.

2. Resident of Oral Medicine Specialist Programme, Faculty of Dental Medicine, Universitas Airlangga, Surabaya, Indonesia.

### Abstract

Recurrent oral ulceration (ROU) presents as recurrent, round ulcers of yellow or grey surface, single or multiple, with erythematous halo. ROU associated with systemic diseases such as infection, immune defects and degenerative diseases. Rheumatic heart disease (RHD) was a cardiovascular disease due to non-suppurative complications of Group A $\beta$ -Hemolytic Streptococcus (GAS) caused by delayed immune response. Oral Streptococci has been suggested to play important role in oral ulceration. This article reviewed a case of ROU associated to reinfection of GAS in post-RHD patient.

A 21 year female complained of highly ROU which almost never healed since her teenage years. She was diagnosed with RHD at 9 years old and underwent treatment until 15 years old.

Oral ulcers treated with combination of topical anti-inflammatory and antiseptic. Oral hygiene improved by scaling and root planning treatment. Complete blood count and Anti-Streptolysin Titer O (ASTO) tests resulted in 3200 IU/ml of titer (N <200 IU/ml). Referral to the cardiologist was made to confirm RHD reactivation. Patient treated with Penicillin G benzathine injection monthly for a year and advised to avoid tooth extraction.

GAS infection plays a role in the recurrence of oral ulceration and should not be mistreated as recurrent ulcers of other origins.

*Case report (J Int Dent Med Res 2017; 10(2): pp. 392-396)*

**Keywords:** Recurrent Oral Ulceration, Rheumatic Heart Disease, Group A  $\beta$ -Hemolytic Streptococcus infection.

**Received date:** 04 April 2017

**Accept date:** 20 June 2017

### Introduction

Recurrent Oral Ulceration (ROU) is characterized by recurrent ulceration in the oral cavity, either single or multiple, round or ovoid shaped of less than 1 cm in diameter, yellowish or greyish surface with clear regular border with erythematous halo. Unlike recurrent oral aphthae, the recurrence of ROU is associated to systemic diseases such as rheumatic diseases, i.e. Lupus Erythematosus, Sweet's syndrome, Reiter's Syndrome.<sup>1,2,3</sup>

Rheumatic heart disease (RHD) was one of rheumatic diseases following acute rheumatic fever (RF). Group A Streptococcus (GAS) infection manifests after 1-4 weeks, causing non-suppurates pharyngitis, scarlet fever, rheumatic fever, toxic shock syndrome and glomerulonephritis.<sup>4,5</sup>

Chronic multisystem inflammation follow about 50% of acute RF patients.<sup>5,6</sup> Rheumatic Fever (RF) is an acute type 2 hypersensitivity reaction, which IgG and IgM were produced as a result of the binding of antigen to target cell or tissue. In addition, leukocyte chemotaxis resulted in target cell lysis by the role of complement or Fc receptor. The M protein on GAS membrane cross-reacts with human heart tissue. Lipoteichoic and hyaluronic acid capsule in GAS play an important role in bacteremia. GAS-produced Streptolysin O cause blood cell lysis. Antibody against Streptolysin O prevents this action, however fail to induce immunity. High serum titer of Anti-Streptolysin Titer O (ASTO

#### \*Corresponding author:

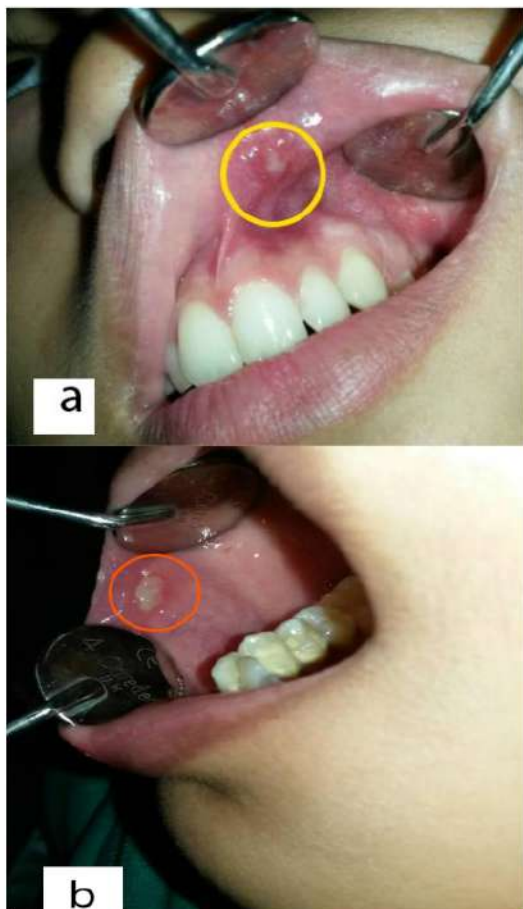
Desiana Radithia,<sup>5</sup>  
Department of Oral Medicine, Faculty of Dental Medicine,  
Universitas Airlangga,  
Jl. Mayen. Prof. Dr. Moestopo No. 47 Surabaya 60132,  
Indonesia.  
E-mail: deisy.radithia@fkg.unair.ac.id;  
alexander.sandro11@gmail.com

>250 unit) indicates a patient is either newly infected or recurrently by GAS.<sup>7,8,9</sup>

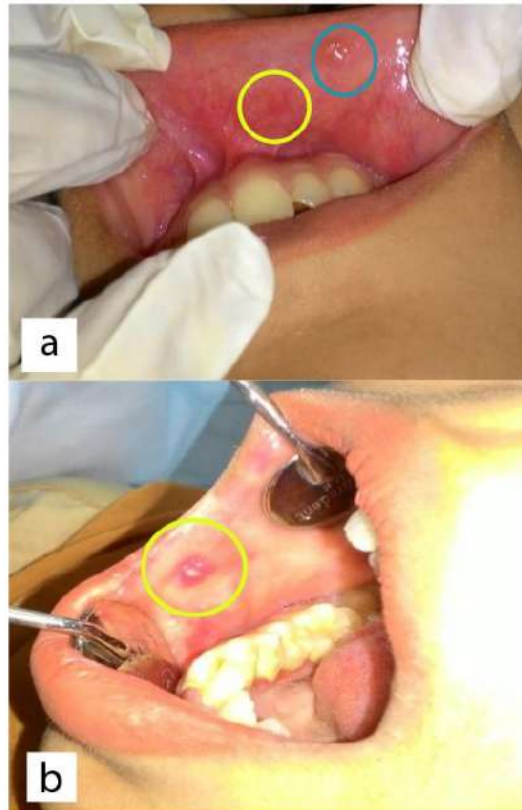
This article presents a case of ROU associated to GAS reinfection in a post-RHD patient.

### Case Report

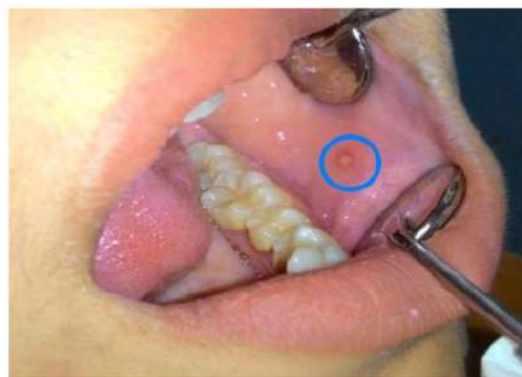A 21 years old female came to Universitas Airlangga Dental Hospital complains highly recurrent oral ulceration. History of recurrence since age 6 and reduced around teen age, but increased again recently.



**Figure 1.** Condition on first visit. Two ulcers at different sites greyish white surface, clear margin with irregular border and surrounded by diffuse erythema, 2x3 mm and 4x6 mm each in diameters (a) on upper vestibulum; (b) on buccal mucosa dextra.

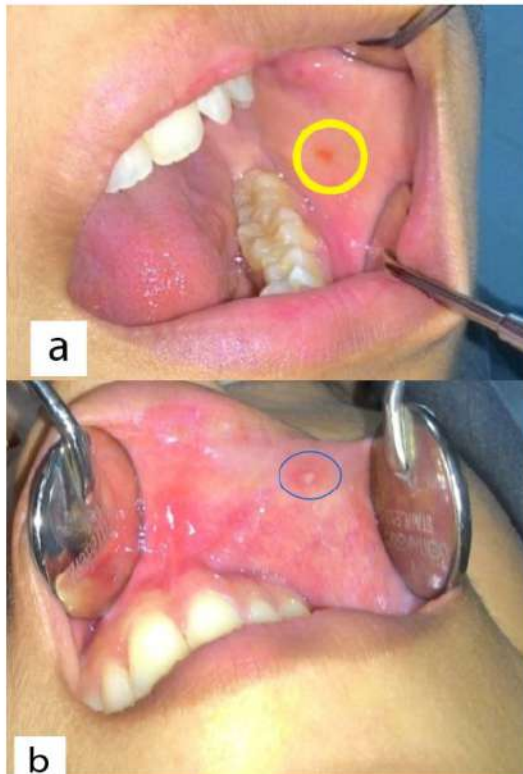


**Figure 2.** Former ulcers (yellow circle) reduced significantly in size and pain, indicating remission. New ulcer appeared (blue circle); classic round white ulcer surrounded by erythematous halo. (a) on upper vestibulum; (b) on buccal mucosa dextra.



**Figure 3.** New ulcer appeared (blue circle) on buccal mucosa sinistra; classic round white ulcer surrounded by erythematous halo.

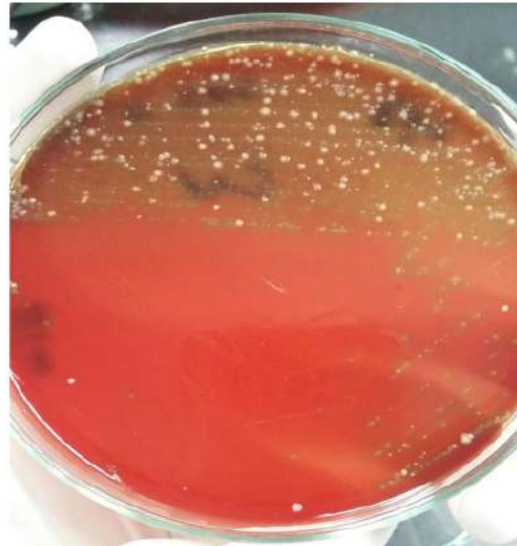
Patient was diagnosed with RHD at age 9. Patient underwent treatment of monthly penicillin injection until age 15, then she was declared cured. Intra oral examination revealed two ulcers at different sites, greyish white surface, clear margin with irregular border and surrounded by diffuse erythema. Oral mucosa generally appeared uneven indicating recurrent ulceration episodes (Figure. 1).



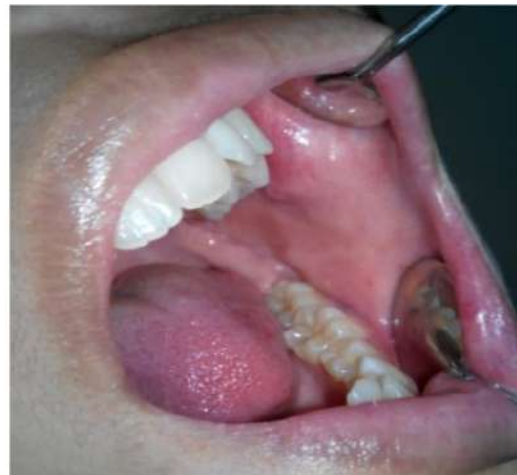**Figure 4.** (a) Former ulcer on buccal mucosa sinistra (yellow circle) underwent healing process; (b) New ulcer appeared on upper vestibulum (blue circle).

Recurrent oral aphthae (ROA) was concluded as working diagnosis on the first visit. Ulcers were sanitized locally with povidone iodine solution (Betadine® solution, Purdue Products L.P. Stamford, CT 06901-3431) and covered with topical triamcinolone acetonide paste (Kenalog® in orabase®, APOTHECON® A Bristol-Myers Squibb Company Princeton, USA). Patient was prescribed topical triamcinolone acetonide to be applied three times daily. These

ulcers underwent significant remission after 7 days of treatment, but new ulcer appeared elsewhere (Figure 2). After another 7 days of treatment, patient returned with former ulcers underwent remission and again new ulcers appeared on a different site (Figure 3 and 4).



**Figure 5.** GAS colony on blood agar.



**Figure 6.** Former ulcer on buccal mucosa sinistra has been healed. Overall oral hygiene has improved. No new ulcer appeared.

The frequency of recurrence was not concomitant with the characteristic nature of ROA, instead it indicated underlying systemic

condition. Based on the patient's history, ASTO test was ordered, and the patient was referred for scaling and root planing to improve oral hygiene. Patient returned with test result showing ASTO titer 3200 IU/ml (normal <200 IU/ml) and colony growth on blood agar positive (Figure 5). Referral to a cardiologist was made, and reactivation of RHD was then confirmed. The final diagnosis was concluded as ROU associated to GAS reinfection and reactivation of RHD. The patient was advised to start penicillin treatment right away and patient started to have ulcer-free periods (Figure 6).

### Discussion

Both ROU and ROA are characterized by recurrent oral ulcerations, however ROA was a result of immune dysregulation, such as antibody cross-reaction between antigen (i.e., microorganism) and oral epithelial cells, due to the expressions of Human Leukocyte Antigen (HLA) (e.g. HLA-A2, A11, B12 and DR2).<sup>1,2</sup> Reduced expression of Heat Shock Protein (HSP)-27 and Interleukin (IL)-10 in ROA patients cause failure of immune system in suppressing inflammation. HSP can block the production of pro-inflammatory cytokines (e.g. TNF, IL-1, IL-6 and IL-8) through inhibition of NF- $\kappa$ B and Mitogen-Activated Protein Kinase (MAPK) pathways, or activate anti-inflammatory cytokines (e.g. Transforming Growth Factor  $\beta$ -1), and therefore control the magnitude of the immune response. IL-1 and IL-6 gene polymorphisms are also associated with an increased risk for ROA. In this case, the patient was first diagnosed with ROA based on clinical appearance and history of recurrence.<sup>9,10</sup>

Group A  $\beta$ -Hemolytic Streptococcus (GAS) is the main cause of Acute Rheumatic Fever (RF) and Rheumatic Heart Disease (RHD). Pathogenesis involves several elements such as specific strain of GAS, host susceptibility and immune competence. GAS is covered by hyaluronic acid capsule, while the cell wall consists of lipoteichoic acid and *N-acetyl- $\beta$ -D-glucosamine*. The M protein and hyaluronic acid capsule plays as virulence factor and anti-phagocytic tool for GAS. The M protein structure, homolog to heart protein myosin and tropomyosin, easily cross-reacts and generates autoantibody. This condition has been known as molecular mimicry.<sup>7</sup> T lymphocyte and antibody

play an important role in the pathogenesis of RHD leading to RHD via HLA class II expression. HLA-DR4, DR7 and DR9 are closely related to the pathogenesis of RF and RHD.<sup>6,7</sup>

GAS spreads via direct contact with infected sputum or open wound. GAS secretes two kinds of hemolysin called streptolysin O (oxygen-labile) and streptolysin S (serum-soluble). Both hemolysin are able to destroy erythrocytes, leukocytes and thrombocytes by penetrate through the cell membrane. Streptolysin O was immunogenic, while streptolysin S was not, but it plays a role in beta-hemolysis.<sup>9,10,11</sup>

Echocardiography was necessary in the diagnosis of valvular disease like RHD. Patients with mild RHD should undergo treatment with Penicillin G for 10 years, while moderate and severe cases may take longer treatment. This patient was diagnosed with RHD at age 9 and underwent penicillin injection until age 15, which was less than 10 years. This might be the reason of RHD reactivation at the age of 21.<sup>9</sup>

In the ROU pathogenesis, bacteria may act either as pathogens or antigens that induce antibody production, which can cross-react with oral mucosal keratinocytes. A 65 kDa HSP released by various streptococcal strains is known to cross-react with peptides in the oral keratinocytes, suggesting streptococci could trigger lesions based on an autoimmune reaction.<sup>11,12</sup>

Diagnosis for ROU in this case was closely related to the diagnosis and treatment of RHD by the cardiologist. The history of recurrent oral ulceration since age 6 was presumably related to GAS infection prior to the diagnosis of RHD was made. The recurrence frequency reduced during penicillin treatment in teenage years, and increased recurrence frequency in the recent years was related to GAS reinfection, leading to the reactivation of her RHD.<sup>13,14</sup>

Treatment for ROU consisted of topical anti-inflammatory and antiseptic, supported by oral hygiene improvement to ensure no secondary infection source.

### Conclusions

Recurrent oral ulceration with non-periodical, high recurrence frequency and no clear predisposing factor should increase suspicion of systemic disease involvement. GAS

reinfection in post-RHD patients manifests as recurrent oral ulceration.

### Acknowledgements

The authors would like to thank the dentists and nurses in Oral Medicine Clinic of Universitas Airlangga Dental Hospital, as well as the administratives of Medical Records Unit.

### Declaration of Interest

The authors report no conflict of interest.

### References

1. Scully C. Aphthae (Recurrent Aphthous Stomatitis), in *Oral & Maxillofacial Medicine. The basis of diagnosis and treatment*. 1<sup>st</sup> ed. Philadelphia: Elsevier Ltd. 2013;226-236.
2. Popovska M, Fidovski J., Vera R.N., Cena D., Lidija P., Aneta M., Natasa T.S., Biljana D. The Effects of NBF Gingival Gel in The Treatment of Recurrent Oral Ulcers: Case Report. *Journal of International Dental and Medical Research*. 2016;9(1):81-85.
3. Ellis E.R., Pradono S.A., Wimardhani Y.S. Successful Treatment of Persistent Oral Ulcers in Patients with HIV / AIDS. *Journal of International Dental and Medical Research*. 2016; 9 (Special Issue, U.I. 1st International Workshop on Dental Research): 398-402.
4. Kumar RK & Tandon R. Rheumatic fever & rheumatic heart disease: The last 50 years. *Indian J Med Res*. 2013;137:643-658.
5. Cunningham M. Pathogenesis of group A streptococcal infections, *clinical microbiology review*. 1<sup>st</sup> ed. Philadelphia: Elsevier Ltd. 2000;470-511.
6. Kumar, Abbas, & Aster. *Infectious diseases, in Robbins and cotran pathologic basic of disease*. 9<sup>th</sup> ed. Philadelphia: Elsevier Saunders. 2015;362-365.
7. Beltrame MH, Catarino SJ, Goeldrer I, Boldt ABW, Reason LMJ. The lectin pathway of complement and rheumatic heart disease, *frontiers in pediatrics*. Brazil: Elsevier Saunders. 2015:1-9.
8. Kumar, Abbas, & Aster. *H. Robbins basic pathology*. Philadelphia: Elsevier Saunders. 2013; 391-394, 557-559.
9. Guilherme L, Kalali J & Cunningham M. Molecular mimicry in the autoimmune pathogenesis of rheumatic heart disease, *Autoimmunity*. Oklahoma City, USA: CV Mosby. 2006; 31-39.
10. Sunarto H., Soeroso Y., Dwiyantri S., Anggraeni E.W., Bachtiar B., Radi B., Suljaya B. Quantitative Measurement of Porphyromonas Gingivalis and Treponema Denticola Levels on Dental Plaque and its Relationship with Periodontal Status and Coronary Heart Disease. *Journal of International Dental and Medical Research*. 2016;9(3):144-150.
11. Bankval M, Sjoberg F, Gale G, Wold A, Jontell M and Ostman S. The oral microbiota of patients with recurrent aphthous stomatitis. *Journal of Oral Microbiology*. 2014; 6(1):1-9.
12. Fike D, and Stevens C. Serological and molecular detection of bacterial infections In *clinical immunology and serology : A laboratory perspective*. 3<sup>rd</sup> ed. USA: Davis Company. 2010:313-316.
13. Brooks GF, Carroll KC, Butel JS, Morse SA, Mietzner TA. *The streptococci, enterococci, and related general*. 1<sup>st</sup> ed. North America: The McGraw-Hill Companies. 2013;209-214.
14. Pardede, SO. Struktur sel streptokokus dan patogenesis glomerulonefritis akut pascastreptokokus, *Sari Pediatri*. Karya Tulis Akhir (KTA) Pediatric Departement. Jakarta: University of Indonesia. 2009;56- 65.

# Recurrent Oral Ulceration Associated to Group A $\beta$ -Hemolytic Streptococcus Reinfection in a Post-Rheumatic Heart Disease Patient

## ORIGINALITY REPORT

16%

SIMILARITY INDEX

10%

INTERNET SOURCES

10%

PUBLICATIONS

0%

STUDENT PAPERS

## PRIMARY SOURCES

1	<a href="http://eprints.ugd.edu.mk">eprints.ugd.edu.mk</a> Internet Source	5%
2	Crispian Scully. "Aphthae (recurrent aphthous stomatitis)", Elsevier BV, 2013 Publication	4%
3	<a href="http://repository.unhas.ac.id">repository.unhas.ac.id</a> Internet Source	2%
4	Ira Arundina, S. Theresia Indah Budhy, Intan Nirwana, Retno Indrawati, Muhammad Luthfi. "Toxicity Test n-Hexane: Ethyl Acetate (3:7) Fraction of Sudamala (Artemisia vulgaris L.)", Procedia Chemistry, 2016 Publication	1%
5	N Purnami, S P P Manyakori. "Reactive oxygen species levels are high risk worker of noise induced hearing loss in hospitals", Journal of Physics: Conference Series, 2018 Publication	1%

6	Devinder Toor, Neha Sharma. "T cell subsets: an integral component in pathogenesis of rheumatic heart disease", Immunologic Research, 2017 Publication	1 %
7	Patricia Witman. "Hornbills, Kingfishers, Hoopoes, and Bee-Eaters", Hand-Rearing Birds, 09/09/2007 Publication	1 %
8	Beltrame, Marcia Holsbach, Sandra Jeremias Catarino, Isabela Goeldner, Angelica Beate Winter Boldt, and Iara JosÃ© de Messias-Reason. "The Lectin Pathway of Complement and Rheumatic Heart Disease", Frontiers in Pediatrics, 2015. Publication	<1 %
9	patient.info Internet Source	<1 %
10	"Essentials of Anatomic Pathology", Springer Nature America, Inc, 2016 Publication	<1 %
11	"Host-Pathogen Interactions in Streptococcal Diseases", Springer Nature America, Inc, 2013 Publication	<1 %
12	Goyette, Philippe, Catherine Labbé, Truc T. Trinh, Ramnik J. Xavier, and John D. Rioux. "Molecular pathogenesis of inflammatory	<1 %



# bowel disease: Genotypes, phenotypes and personalized medicine", Annals of Medicine, 2007.

Publication

---

---

Exclude quotes      Off

Exclude matches      Off

Exclude bibliography      On

# Recurrent Oral Ulceration Associated to Group Aβ-Hemolytic Streptococcus Reinfection in a Post-Rheumatic Heart Disease Patient

---

GRADEMARK REPORT

---

FINAL GRADE

**/0**

GENERAL COMMENTS

**Instructor**

---

PAGE 1

---

PAGE 2

---

PAGE 3

---

PAGE 4

---

PAGE 5

---