

Oral Lichen Planus Erosive Type: a Case Report in Indonesian Male Patient

Diah Savitri Ernawati^{1*}, Alexander Patera N², Adiastruti Endah P¹,
Kus Harijanti¹, Saka W¹, Nur Asmi³

1. Departement Oral Medicine, Faculty of Dental Medicine, Universitas Airlangga, Surabaya, Indonesia.

2. Undergraduate Student, Faculty of Dental Medicine, Universitas Airlangga, Surabaya, Indonesia.

3. Resident of Oral Medicine, Faculty of Dental Medicine, Universitas Airlangga, Surabaya, Indonesia.

Abstract

Oral Lichen Planus (OLP) is an autoimmune disorder with unknown etiology that affects the oral mucous. OLP erosive form considered as precancerous lesion. The diagnosis made by clinical features and biopsy to exclude dysplasia and malignancy.

The aim of this study to know a case of OLP erosive in male patient and to discuss the main aspects of this disease.

47 years old male Javanese patient came with chief complaint of presisten ulcer since 1 year ago. Patient had a history of drug and food allergic reaction, hypertension (170/100 mmHg), and Diabetes Mellitus (HbA1C > 7). Patient often smoke (\pm 24 cigarret daily) and alcoholic since young. Patient sometimes fatigue and stress. Intra Oral (IO) examination showed a white papular lesion, unscrapable, rough, firm, multiple, measuring \pm 1 x 2 cm surrounded by painful erosion with erythematous area, irregular and diffuse, bilateral on buccal mucosa dextra and sinistra.

Patient treated with antiseptic oral rinse, topical and systemic corticosteroid. Patient referred to Patologist Anatomy to get a scrapping test. Patient came for control showing the healing process. Patient showed an improvement after treatment.

OLP erosive form is a precancerous lesion that possible transform to malignancy. Early detection and treatment is necessary.

Case report (J Int Dent Med Res 2017; 10(2): pp. 380-383)

Keywords: Oral Lichen Planus, Precancerous Lesion, Early Detection, Autoimmunne.

Received date: 05 April 2017

Accept date: 03 May 2017

Introduction

Oral lichen planus (OLP) is a common disorder affects the mucous membrane of the oral cavity which is stratified squamous epithelium. OLP occure mostly in the fourth to sixth decades of life, and common in women than men. The Etiopathogenesis is still uncertain. Specific and non-specific mechanisms may be involved in the etiopathogenesis. The specific mechanism involves the presentation of antigen by keratinocytes which auto-cytotoxic T lymphocytes trigger apoptosis of epithelial cells leading to chronic inflammation, and the non-specific mechanism includes degranulation of

mast cells and activation of matrix metalloproteinases (MMPs).¹

OLP Erosive form is considered as precancerous lesion. OLP has potential for malignant transformation and the risk of malignant transformation varies between 0.4 to 5% in a period of observation from 0.5 to 20 years. However, many controversies remain with regard to the risk of malignant transformation. The characteristic clinical aspects are sufficient to make a correct diagnosis. An oral biopsy with histopathologic examination recommended to confirm clinical diagnosis and also to exclude dysplasia and malignancy.²

The aim of this study to know a case of OLP erosive in 47 years old Javanese male patient and to discuss the main aspects of this disease in relation to etiopathogenesis and treatment.

*Corresponding author:

Diah Savitri Ernawati
Department of Oral Medicine, Faculty of Dental Medicine,
Universitas Airlangga. Jl. Mayjen. Prof. Dr. Moestopo No. 47
Surabaya 60132, Indonesia.
E-mail: diah-s-e@fkg.unair.ac.id

Case Report

47 years old male Javanese patient came with chief complaint of presisten ulcers since 1 year ago. Patient had a history of drug and food allergic reaction, hypertension (170/100 mmHg), and Diabetes Mellitus (HbA1C > 7). Patient often smoke (± 24 cigarret daily) and alcoholic. Patients often travel abroad for business, patient sometimes fatigue and stress.

Intra Oral (IO) Examination showed solitary mixed red and white papular lesions, irregular shape, measuring about $\pm 2 \times 3$ cm posterior buccal mucosa extending to anterior, bilateral on buccal mucosa dextra and sinistra, surrounded by painful erosion has central area of erythema surrounded surface by white striae, irreguler and diffuse, on palpation inspection were tender, smooth, and nonscrappable lesion. Patient had poor oral hygiene. Gingiva was observed, generalized gingival inflammation, erythematous, tender, upper and lower side of anterior posterior gingiva had typical white striae (Figure1.)

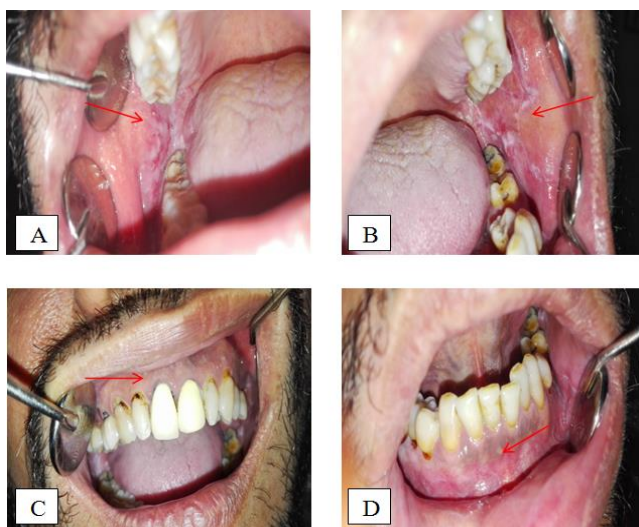


Figure 1. Patient IO examination with OLP before treatment (a) Dextra Buccal Mucosa; (b) Sinitra Buccal Mucosa; (c) Upper Anterior Gingiva; (d) Lower Anterior Gingiva.

Extra Oral (EO) Examination showed no anomaly. Considering history and clinical features Oral Lichen Planus Erosive was considered as Provisional Diagnosis (PD) with the Differential Diagnosis (DD) Phephigus Vulgaris (PV). Patient treated with antiseptic oral rinse, topical and systemic corticosteroid.

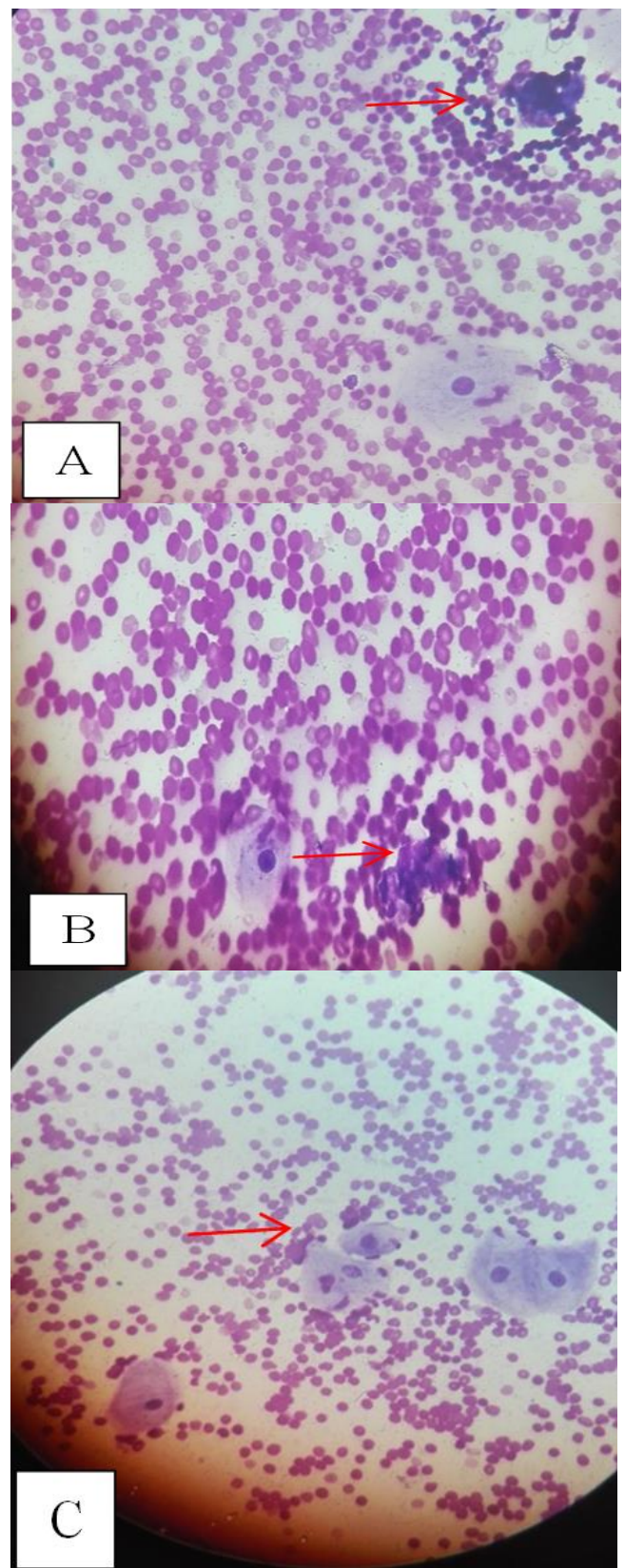


Figure 2. HPA scappting test on OLP lesion result with Hematoxylin Eosin (HE) staining and 100x magnifications, (a,b,c) marked a band like lymphocytes infiltration without cell dysplasia.

Patient referred to Patologist Anatomy to get a scrapping test, marked a band like lymphocytes infiltrate without displasia (Figure 2). Patient came for control shown the healing process. Patient showed an improvement after treatment (Figure 3).

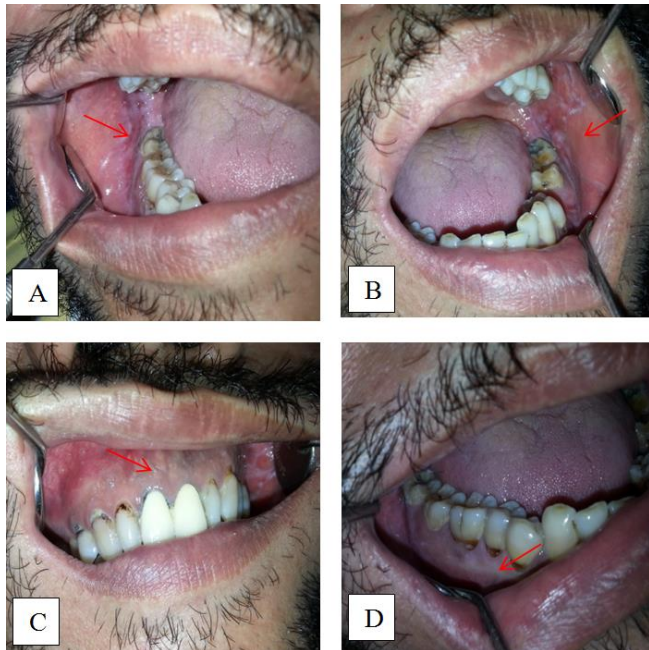


Figure 3. Patient IO examination with OLP after treatment shown healing process (a) Dextra Buccal Mucosa; (b) Sinistra Buccal Mucosa; (c) Upper Anterior Gingiva; (d) Lower Anterior Gingiva.

Discussion

Oral Lichen planus (OLP) is a chronic autoimmune disease with an unknown etiology that is marked by the invasion of lymphocytic infiltrate within the epithelial tissue inducing epithelial cell apoptosis and chronic inflammation. Prevalence OLP in the world about 1-2% of world population. The different etiological factors considered for OLP are genetic background, dental materials, drugs, infectious agent, autoimmunity, immunodeficiency, food allergy, stress, habits, trauma, diabetes, hypertension, malignant neoplasm, and bowel diseases^{2,3,4}.

The pathogenesis of OLP is thought of from four mechanisms Antigen specific cell mediated immune response (Heat Shock Proteins, CD4+ T helper cells, CD8+ cytotoxic T cells) Nonspecific mechanism (epithelial basement membrane, mast cells, chemokines, matrixmetaloproteinases) autoimmune response,

humoral immunity (circulating autoantibodies to desmoglein 1 and 3)^{5,6,7}. OLP is a T-cell-mediated autoimmune disease. Inflammatory cells involved in this process consist of T helper and T cytotoxic lymphocytes, natural killer (NK) cells, and dendritic cells. T-cell activation is central to the pathogenesis of the pathology. Cytotoxic T-cell infiltration into the epithelium results in apoptotic basal keratinocytes. OLP is a complex disease and can be caused or triggered by genetic malfunction and/or environmental factors. The existence of familial cases of LP may suggest a possible genetic predisposition^{8,9}.

The choice of OLP treatment depends on the severity and the discomfort. Unfortunately, there is no treatment to permanently resolve the lesions. The recommended treatment for OLP consists on topical corticosteroids in order to reduce symptoms and improve the quality of life of the patients¹⁰.

Maintenance of good oral hygiene can enhance healing and lessen symptoms, and exacerbating factors should be minimized or removed¹¹. However, in case of persistent lesions, systemic corticosteroids are indicated. Thus, considering the importance of this pathology and the high incidence in the population and can transform to malignancy¹². In some OLP cases, P53 and P16 gene in saliva or serum increase which indicate that OLP can transform into malignancy condition^{13,14}.

In this study patient treated with antiseptic oral rinse 3 times daily (Chlorhexidine Gluconate 0,21% 120ml Minosep® by Minorock Ltd, Indonesia) to improve the Oral Health. Topical corticosteroid were administrated 3 times daily (Triamcinolone Acetonide in orabase 0,1% Kenalog® by Taisho, Indonesia) showed best result. Systemic corticosteroid (Prednison 10 mg) were administered 3 times daily depending on severity of lesion. Systemic steroids are indicated for brief treatment of severe exacerbations of OLP. Corticosteroids have shown to be predictable and effective medications for controlling signs and symptoms¹⁵.

In most of the OLP patients two week course of topical corticosteroids will resolve inflammation and symptoms, however, there are cases which are refractory to the prolonged use of topicalcorticosteroids¹⁵. Although various therapies have been tried in patients with OLP, still the golden standard is topical corticosteroid use which has certain side effects especially

when used for longer period of time. Reported side effects include candidiasis, gastrointestinal disturbances, diabetes, hypertension, moon face and adrenal insufficiency¹¹.

Furthermore, in some cases the use of corticosteroids has proven to be ineffective. Therefore, new OLP treatment options are to be searched. Homeopathic treatment, Methotrexate treatment, Photodynamic Therapy (PDT), application of Stem Cell from Plasma Rich Fibrin, and Surgical management, including cryosurgery and carbon dioxide (CO₂) laser, has been performed on OLP lesions treatment, but surgical excision is not recommended as the first-choice treatment due to the inflammatory condition, which can reoccur^{16,7,18}.

Conclusions

The term OLP is a T-cell-mediated heterogeneous group of disease with associated mucosal lesions with unclear etiology caused by multifactorial agents. OLP has 6 clinical types such as erosive type which is often painful and debilitating. Golden standard for OLP treatment is topical or systemic corticosteroid but has certain side effects especially when used for longer period of time. Therefore, new OLP treatment options are to be searched such as homeopathic therapy, Methotrexate treatment, Photodynamic Therapy (PDT), application of Stem Cell from Plasma Rich Fibrin, and Surgical management, including cryosurgery and carbon dioxide (CO₂) laser. Since there is a close association of OLP with psychological factors like stress and depression psychiatric counseling can also prove to be beneficial in the treatment line. In addition, OLP erosive form is a precancerous lesion that possible transform to malignancy. Early detection and treatment is necessary to improve QoL OLP patient.

Acknowledgements

The authors would like to thank the Universitas Airlangga (UNAIR), Faculty of Faculty Dental Medicine, Dental Hospital Universitas Airlangga Surabaya, East Java, Indonesia.

Declaration of Interest

The authors report no conflict of interest.

References

1. Lukács J., Schliemann S., Elsner P. Lichen planus and lichenoid reactions as a systemic disease. *Clinics in Dermatology*. 2015; 33(5): 512–519.
2. Yulia K. Malignant transformation of oral leukoplakia and oral lichen planus: a retrospective cohort study of 293 Ukrainian patients. *Journal of Education, Health and Sport*. 2017;7(3):273-279.
3. Bakhtiari S., Toosi P., Dolati F., Evaluation of salivary secretor status of blood group antigens in patients with oral lichen planus. *Med Princ Pract*. 2016;25:266-26.
4. Bakhtiari S.A., Toosi P.B., Samadi S.A., Bakhshi M.A. Assessment of Uric Acid Level in the Saliva of Patients with Oral Lichen Planus. *Med Princ Pract*. 2017;26:57-60.
5. Olson M. A., Rogers R. S., Bruce A. J. Oral lichen planus. *Clinics in Dermatology*. 2016; 34(4): 495–504.
6. Ferhi D. Pathophysiology, etiologic factors, and clinical management of oral lichen planus, part I: facts and controversies. *Clin Dermatol*. 2010; 28: 100-108.
7. Payeras M.R. Oral lichen planus: Focus on etiopathogenesis. *Arch Oral Biol*. 2013; 58: 1057-1069.
8. Au J. Oral lichen planus. *Oral Maxillofacial Surg Clin N Am*. 2013; 25: 93-100.
9. Atzmony L., Reiter O., Hodak E., Gdalevich M., Mimouni D. Treatments for cutaneous lichen planus: A systematic review and meta-analysis. *American Journal of Clinical Dermatology*. 2016; 17(1): 11–22.
10. Moraes M., Matos F.R., Pereira J.S., Medeiros A.M.C., Silveira E.J.D., 2009. Oral lichen planus: two case reports in male patients. *Rev. odonto ciênc*. 2010;25(2):208-212.
11. Melzer R.S., Bruna da Fonseca Wastner B.F., Zanferrari F.L., Sassi L.M., Homeopathic treatment in oral lichen planus control: Case Report. *J Oral Diag*. 2017; 01:e20170001. Available on http://www.jordi.com.br/detalhe_artigo.asp?id=61. Accessed May 4, 2017.
12. Rawi H.L., Kawas S.A., Imad O. 2012. Public Awareness and Attitude Toward Oral Cancer Screening In United Arab Emirates. *Journal of International Dental and Medical Research*. 2012;5(3):149.
13. Purwaningsih N.M.S, Sailan A.T, Sinon S.H.M, Jalil A.A. Role of p16 and p53 in Oral Potentially Malignant Disorders and Oral Squamous Cell Carcinoma: A Study in Malaysia. *Journal of International Dental and Medical Research*. 2017;10(1)42-44.
14. Arreaza, A., Rivera, H. & Correnti, M. p53 expression in oral lichenoid lesions and oral lichen planus. *Oral Med Oral Diagn. Oral Pathol*. 2013:69-72.
15. Raj P.R., Rawther N.N., James J., Siyad K.P., Padiyath S., Erosive Lichen Planus of the Oral Cavity: A Case Report. *IJSS Journal of Surgery*. 2015; 1(4): 24-28.
16. Lajevardi V., Ghodsi S. Z., Hallaji Z., Shafiei Z., Aghazadeh N., Akbari Z. Treatment of erosive oral lichen planus with methotrexate. *Journal der Deutschen Dermatologischen Gesellschaft*. 2016; 14(3): 286–293.
17. Muhaxheri G., Boras V. , Gabric D., Terlevic D., Kvesic A.J. No Efficacy of Photodynamic Therapy with Toluidine Blue in Oral Lichen Planus. *Research Journal of Pharmaceutical, Biological and Chemical Sciences*. Available on [http://www.rjpbcs.com/pdf/2017_8\(1\)/\[19\].pdf](http://www.rjpbcs.com/pdf/2017_8(1)/[19].pdf). Accessed on May 04, 2017.
18. Smail S.B., Kumar S.K., Zain R.B. Oral lichen planus and lichenoid reactions: etiopathogenesis, diagnosis, management and malignant transformation. *J Oral Sci*. 2007;49:89-106.