

## ORIGINAL ARTICLE

# Anti Immunogenicity Evaluation of Bovine Demineralized Dentine Membrane Material

Pratiwi Soesilawati<sup>1</sup>, Tantiana<sup>1</sup>, Annisa Zahra<sup>2</sup>

<sup>1</sup> Oral Biology Department of Faculty of Dental Medicine, Universitas Airlangga, Moestopo 47, 60119 Surabaya, Indonesia

<sup>2</sup> Undergraduated Student of Faculty of Dental Medicine, Universitas Airlangga, Moestopo 47, 60119 Surabaya, Indonesia

## ABSTRACT

**Introduction:** Proliferation of fibroblasts in soft tissue occurs relatively faster than hard tissue's regeneration. For this reason, Guided Bone regeneration (GBR) is needed as a barrier to prevent any interventions between both processes in bone regeneration. Demineralized Dentine Material Membrane (DDMM) is a new material as GBR that must be ensured to have good properties. and do not cause a reaction in human body. Some of the influencing factors are still unspecified, which makes it difficult to expect biological responses, for example anti immunogenicity, which could lead to severe side effects. **Methods:** Three DDMM samples were performed by HE staining to see whether there were any residual cells or material. DDMM placed on the object glass. HE staining was stained. The HE method was selected according to the purpose of the study. Microscopic analysis was carried out through the division of the visual field into nine sections. each section is examined, to find the remaining odontoblast cells in the area. **Results:** the entire microscope field of view of the DDMM sample contained mineralized dentin material, with no odontoblast cell remaining. DDMM slices on processing step do not affect the pulp wall. dentine tubules appear to be cut with transverse direction. **Conclusion:** DDMM does not contain any cells or chemical structure that may caused an immunogenic reaction.

**Keywords:** Guided Bone regeneration, Demineralized Dentine Material Membrane, Immunogenic reaction, Dentistry

## Corresponding Author:

Pratiwi Soesilawati, PhD

Email: pratiwi-s@fkg.unair.ac.id

Tel: +081 703968754

## INTRODUCTION

The process of bone healing is a process of reconstruction that can actually reproduce by itself if the area of damaged bone not too broad, because the body has the ability to regenerate bone. However, the process of bone regeneration requires a long period of time (1). Bone regeneration can be done well if osteoprogenitor cells meet the bone defect section without being disturbed by the presence of non-osteogenic cells. In the process of bone healing there are two processes happen, the healing process of soft tissue and hard tissue. Bone healing in large bone defects is often hampered because connective tissue enters the area of the defect and prevents the growth of complete bone regeneration. As a result, Guided Bone Regeneration (GBR) is needed in the process to prevent infiltration of non-osteogenic cells to bone defect area (2).

Some examples of GBR that are commonly used, are Jason Membrane (Bottis), Collprotect, and Bio-Gide. All these GBRs membrane has good biocompatibility (3), but the main material of these membranes come from porcine. Therefore, this study was conducted to find alternatives to the membrane. In this study the membrane which is used is the Demineralized Dentine Material Membrane (DDMM). It is a membrane of bovine dentin that is known to contain a large number of bone growth factors, namely collagen type I and Bone Morphogenetic Proteins (BMPs). Therefore, it is estimated that dentin bovine can be used to develop bone graft material that has capabilities similar to autogenous bone. Bovine teeth are the choice for the basic material for membranes because they are easy sampling, halal material, and the content in the dentine is able to help the process of bone regeneration (4). Dentine contains collagen and Bone Morphogenetic Proteins (BMPs) which can help the wound healing process and can induce bone regeneration because of its osteoinductivity (5,6,7). Antigenicity is the capacity of a chemical structure such as antigen to bind specifically with T cell receptors or antibodies. Membrane as GBR must not cause an antigenicity

reaction (3,13), in order to examine the possibility of the potential reaction, it is necessary to determine whether there is any residual cells or antigen on DDMM.

## MATERIALS AND METHODS

This research was conducted by using two samples of DDMM and Jason Membrane as control samples. DDMM produced by Tissue Bank Dr Soetomo Hospital Surabaya with the size of membrane is 5x5 mm and the thickness is 300 µm. Then the membrane was stained using Hematoxylin Eosin (3). The membrane was immersed in formalin solution for 24 hours and then it was attached to the slide Entelan and stained. Put the slide in Mayer's haematoxylin solution for 15 minutes to dye the cell nucleus, wash with running water to remove excess paint for 20 minutes. Staining with lithium carbonate, the slide is inserted into lithium carbonate for 1-2 minutes to obtain a blue core, washed in running water for 5-10 minutes. Eosin staining is conducted by inserting a slide into the eosin solution for 15 seconds-2 minutes. The purpose of this step is to coloring the cytoplasm. The staining process was aimed to see the presence or absence of residual odontoblasts cells in the membrane. In the control sample, HE staining and microscopic examination was carried out using the same method. Microscopic examination of control samples is intended for examination of fibrocyte cells from pericardium tissue as a basic ingredient of Jason Membrane. To see the result, the CX22LED Microscope (Olympus, Japan) was used with a magnification of 400x. Microscopic analysis was carried out through the division of the visual field into nine sections. Each section is examined, to find the remaining odontoblast cells in the area. Microscopic examination results in all areas were recorded. Photomicroscopes were performed on all samples for research documentation.

## RESULTS

Anti-cellular test is done by HE staining on all of the DDMM samples, then it is investigated through a microscope to check whether there are odontoblast cells left or not. Picture 1a showed dentine of DDMM which is processed as raw material for DDMM (Fig 1a) and HE Staining of Jason Membrane (Bottis) with no residual fibrocytes cells on Fig 1b.

DDMM which has been stained using HE, is examined with a 400x magnification microscope. Based on the pictures above, no residual cells are seen on the DDMM, it's mean no odontoblast cells on this biomaterial. With the same method in which it is also examined by using a microscope with a magnification of 400x, there is no visible cell residue in the form of fibrocytes on Jason Membrane. From this result, could concluded that DDMM production was a good material and able to applicated as biomedical devices.




Figure 1 (a) : No residual odontoblast cells on DDMM (HE staining, 400x)

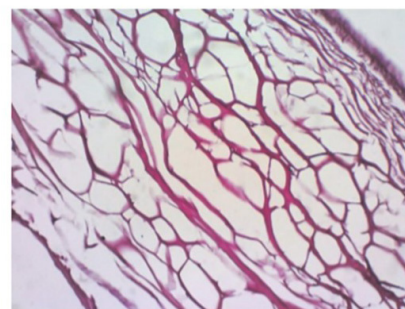


Figure 1 (b) : No residual fibrocytes cells on Jason Membrane (Bottis) (HE staining, 400x)

## DISCUSSION

HE staining is done to see whether there is any residual cell in DDMM. The cell residue left on the membrane can cause reactions at the cellular level, it can activate the specific immune responses in the body, because there are strange objects in other parts of the body (3,12,13). Furthermore, if there is any cell residue left when the membrane acts as a GBR, the body would reject the adaptation process of the membrane. In other words, it can increase the failure risk in the treatment process.

DDMM is made with the basic material of dentine in bovine teeth. Anatomically, dentine is located next to the pulp chamber in which there are many odontoblast cells. The making of DDMM must be done properly so that the pulp chamber in the bovine teeth is not cut and processed into membranes. In addition, the pulp chamber that is processed into the membrane can increase the risk of cell residue in the membrane. In DDMM, odontoblast cells area risk of becoming residual cells.

Immunogenicity is the ability of a particular substance, such as an antigen or epitope, to provoke an immune response in the body of a human. It is also descript as the capability of the substance to induce a humoral and/ or cell-mediated immune responses. The results of staining on the three DDMM samples did not show any odontoblast cells left behind. This shows that DDMM has no potential risk of an immunogen reaction and

can be applied to the body as GBR. The same result goes with Jason Membrane, the results of staining process using HE did not show any residual cells, namely fibrocytes. Undoubtedly, DDMM and Jason Membrane have the same good anti-cellular properties.

## CONCLUSION

The condition that a substance can be used in the human body is not potentially cause an immunogenicity reaction. For this reason, a test is used by Hematoxylin Eosin to ensure if there aren't any residual cell residues. Because the presence or absence of residual cells is a factor that could affect the body's reaction to a material (3).

Bone healing with DDMM as GBR may not change the conformation of immunogenic determinants of bone regeneration but rather changing the surface stereo structure of DDMM (8,11,12). The GBR procedure act as physical barriers to connective cell invasion from the surrounding soft tissues, which exhibit slower migration rate, better conditions to perform bone regeneration (9). Biomaterial preparation should follow rigorous quality guidelines to prevent risks of disease transmission and host rejection (10,14).

Based on our research, DDMM does not contain any cells or chemical structure that may caused an immunogen reaction, meaning that this biomaterial is safe to use as GBR in craniofacial bone therapy in humans.

## ACKNOWLEDGEMENT

Our high appreciation to the research colaborators, Prof. Narofumi Nakamura, DDS., PhD and Prof. Coen Pramono, DMD., MS., OMFS(C) who guided this study. The study was financially supported by Ministry of Research, Technology and Higher Education, Republic of Indonesia, Grant no. 564/UN3.14/LT/2019.

## REFERENCES

1. Li Y, Chen S, Li L, Qin L, Wang X, Lai Y. Bone defect animal models for testing efficacy of bone substitute biomaterials. *Journal of Orthopaedic Translation*. 2015;3:96-104.
2. Elgali I, Omar O, Dahlin C, Thomsen P. Guided bone regeneration: materials and biological mechanisms revisited. *European Journal of Oral Sciences*. 2017;125(5):315-337.
3. Kamadjaja D, Harijadi A, Soesilawati P, Wahyuni E, Maulidah N, Fauzi A et al. Demineralized Freeze-Dried Bovine Cortical Bone: Its Potential for Guided Bone Regeneration Membrane. *International Journal of Dentistry*. 2017;:1-9.

4. Gomes M, Anjos M, Nogueira T, Guimarães S. Histologic Evaluation of the Osteoinductive Property of Autogenous Demineralized Dentin Matrix on Surgical Bone Defects in Rabbit Skulls Using Human Amniotic Membrane for Guided Bone Regeneration. *The International Journal of Oral & Maxillofacial Implants*. 2001;16(4):563.
5. Hart P, Hart T. Disorders of Human Dentin. *Cell Tissue Organ*. 2007;186:70-71.
6. Lieberman J, Daluiski A, Einhorn T. The Role of Growth Factors in the Repair of Bone. *The Journal of Bone and Joint Surgery*. 2002;84(6):1032-1034.
7. Murata M, Akazawa T, Mitsugi M, Um I, Kim K, Kim Y. Human Dentin as Novel Biomaterial for Bone Regeneration. *Biomaterials – Physics and Chemistry*. 2011;:127-130.
8. Wu, K.J., Wang, C.Y. and Lu, H.K., 2004. Effect of glutaraldehyde on the humoral immunogenicity and structure of porcine dermal collagen membranes. *Archives of Oral Biology*, 49(4), pp.305-311.
9. Gardin, C., Ricci, S., Ferroni, L., Guazzo, R., Sbricoli, L., De Benedictis, G., Finotti, L., Isola, M., Bressan, E. and Zavan, B., 2015. Decellularization and delipidation protocols of bovine bone and pericardium for bone grafting and guided bone regeneration procedures. *PloS one*, 10(7).
10. Cruz, G.A.D., Toledo, S.D., Sallum, E.A. and Lima, A.F.M.D., 2007. Morphological and chemical analysis of bone substitutes by scanning electron microscopy and microanalysis by spectroscopy of dispersion energy. *Brazilian dental journal*, 18(2), pp.129-133.
11. El Fadhallah PM, Yuliati A, Soesilawati P, Pitaloka P. Biodegradation and Compressive Strength Test of Scaffold with Different Ratio as Bone Tissue Engineering Biomaterial. *Journal of International Dental and Medical Research*. 2018 May 1;11(2):587-90.
12. Soesilawati P, Notopuro H, Yuliati Y, Ariani MD, Firdauzy MA. The role of salivary sIgA as protection for dental caries activity in Indonesian children. *Clinical, Cosmetic and Investigational Dentistry*. 2019;11:291.
13. Haque N, Fareez IM, Fong LF, Mandal C, Kasim NH, Kacharaju KR, Soesilawati P. Role of the CXCR4-SDF1-HMGB1 pathway in the directional migration of cells and regeneration of affected organs. *World Journal of Stem Cells*. 2020 Sep 26;12(9):938.
14. Soesilawati P, Ambarani EL, Oki AS. Increased Vascular Endothelial Growth Factor (VEGF) Expression in Wistar Rat Oral Mucosa Traumatic Ulcer due to Golden Sea Cucumber (*Stichopus hermanni*) Extract Gel. *Acta Medica Philippina*. 2019 Dec 4;53(6).