

Expression of TNF- and MMP-13 Following Subcutaneous Implantation of Demineralized Freeze Dried Bovine Cortical Bone Membrane in Rat's Dorsum

by Indra Mulyawan

Submission date: 23-Mar-2022 11:53AM (UTC+0800)

Submission ID: 1790675186

File name: d_Freeze_Dried_Bovine_Cortical_Bone_Membrane_in_Rat_s_Dorsum.pdf (536.19K)

Word count: 2899

Character count: 16396

4 Expression of TNF- and MMP-13 Following Subcutaneous Implantation of Demineralized Freeze Dried Bovine Cortical Bone Membrane in Rat's Dorsum

Indra Mulyawan¹, Andra Rizqiawan¹, Pratiwi Soesilowati², David Buntoro Kamadjaja^{1*}

- 5
1. Department of Oral and Maxillofacial Surgery, Faculty of Dental Medicine, Universitas Airlangga, Surabaya-Indonesia.
2. Department of Oral Biology, Faculty of Dental Medicine, Universitas Airlangga, Surabaya-Indonesia.

6 Abstract

Guided Bone Regeneration (GBR) for alveolar bone augmentation requires combination of bone graft and tissue barrier in the form of biodegradable membrane. Bovine pericardium collagen membrane (BPCM) is the most commonly used resorbable membrane. Demineralized freeze dried bovine cortical bone membrane (DFDBCMB) was known to undergo faster biodegradation compared to BPCM. The study attempts to reveal the mechanism of DFDBCMB degradation by analyzing Tumor Necrosis Factor-Alpha (TNF-) and Matrix Metalloproteinase – 13 (MMP-13) expression after implantation of DFDBCMB and BPCM in rat's dorsum.

This experimental study used 60 male rat's which are divided into 2 groups. Subcutaneous implantation of DFDBCMB were done in the first group, while BPCM implanted in the control group. On day 2, 5, 7, 14, 21 and 28 post implantation five rats were sacrificed from each group for immunohistochemistry staining to analyze TNF- α and MMP-13 expression. Comparative and correlation study were done to analyze the two parameters.

There was no significant differences in TNF- α and MMP-13 expression between the two groups over all observation periods. However, no correlation was found between TNF- α and MMP-13 expression in both groups.

The implantation of DFDBCMB does not induce excessive inflammatory response and it undergoes comparable biodegradation process with BPCM until 28 days post implantation. The level of inflammatory response does not correlate with the magnitude of membrane degradation.

Experimental article (J Int Dent Med Res 2021; 14(1): 74-78)

Keywords: Guided Bone Regeneration, Demineralized Freeze Dried Bovine Cortical Bone Membrane, Bovine Pericardium Collagen Membrane, TNF- α , MMP-13.

Received date: 09 November 2020

Accept date: 19 January 2021

Introduction

Augmentation of alveolar bone defect requires guided bone regeneration procedure which combine bone graft particulate and barrier membrane¹. The commonly used membrane for guided bone regeneration is absorbable collagen membrane made from bovine pericardial tissue². As BPCM consists of native type of collagen it undergoes rapid biodegradation. Therefore, its manufacturing process usually requires the procedure of chemical cross-linking in order to inhibit its biodegradation. However, cross-linking itself would hamper vascular tissue ingrowth through the membrane thus would lead to poor

tissue integration³. It was necessary, therefore, to search for alternative type of absorbable membrane able to overcome the shortcoming of BPCM to be used as a GBR membrane.

DFDBCMB is newly developed collagen membrane produced from bovine cortical bone layer through decalcification process. Study showed that it underwent degradation at a rate comparable to BPCM until day 28 post subcutaneous implantation in rat's dorsum⁴. However, the mechanism by which degradation process of the membrane occurs is not clear yet. Although histologic evaluation of few collagen membranes have been studied^{5,6}.

The biologic and biomolecular activities of its biodegradation has not been fully understood so far. As DFDBCMB is xenogeneic type of biomaterial question is raised as to whether it is likely to elicit increased local inflammation which may, theoretically, induce early biodegradation

*Corresponding author:

David Buntoro Kamadjaja
Jl. Prof. Dr. Moestopo 47, Surabaya – Indonesia, 60132
E-mail: david-b-k@fkg.unair.ac.id

through protease enzymes activities especially matrix metalloproteases (MMPs)⁷. However, this is only a hypothesis which needs further study to prove this assumption true.

This study attempts to elucidate the biomolecular activities of degradation process of demineralized freeze dried bovine cortical bone membrane following subcutaneous implantation in rat's dorsum. The study evaluated the expression of TNF- as pro-inflammatory cytokine and MMP-13 as proteolytic protein followed by evaluation to exhibit any correlation possibly existing between the two variables.

Materials and methods

Surgical procedure on experimental animals was done at operating room at Department of Biochemistry, Faculty of Medicine, Universitas Airlangga, Surabaya, approved by Commission on Ethical Clearance, Faculty of Dental Medicine, Universitas Airlangga, Surabaya. Sixty male Wistar rat's used in this study were randomly divided into 2 groups. In experimental group 5 x 5 mm DFDBCMB (produced by Tissue Bank, Dr. Soetomo General Hospital, Surabaya) were implanted in the rat's dorsal subcutaneous tissue while in control group BPCM (Jason Membrane, Botiss GmbH, Germany) was used for the implantation. Five rats from each group were sacrificed at 2, 5, 7, 14, 21 and 28 days after implantation for immunohistochemistry analysis.

Experimental animals were sacrificed at the end of implantation period by over sedating them with ether vapor. The implanted membranes were retrieved by resection of the tissue containing membrane together with their surrounding tissues, fixed in 10 % buffered formalin solution. The tissue samples were subsequently paraffinized and subjected to section of 4 micrometer for histology evaluation and immunostaining. Sections were incubated in 3 % peroxide acid for 30 minutes to block endogenous peroxidase, soaked in 0.025 % trypsin-phosphate buffer saline for 6 minutes and finally washed with aquadest 3 times for 2 minutes. Sections were subsequently stained with rat anti-mouse TNF- α monoclonal antibody or rat anti-mouse MMP-13 monoclonal antibody, with HRP substrate as chromogenic substance. The analysis of positive staining used novocasta detection method under light microscope with x

1000 magnification (Olympus BX-41) equipped with digital camera (DP-70, Olympus, Japan) and Cell D software (Olympus, Japan). Three reviewers performed the counting to obtain the mean value of each group. The data collected was statistically analyzed with T-test or Mann Whitney, whichever is applicable. Additionally, correlation test (Pearson or Spearman, whichever is applicable) was performed to analyze whether there is any correlation of TNF- α and MMP-13 expression between experimental and control groups in all observation periods. Significance was determined at p value of less than 0.05.

Results

The histology result revealed that subcutaneous tissue surrounding DFDBCMB and BPCM were infiltrated with inflammatory cells from day 2 through day 7. Infiltration were noted at periphery of DFDBCMB and both at the periphery and internal porosities of BPCM. At a later stage of healing, no evidence of prolonged inflammation was noted. The tissue was characterized with fibrous tissue encapsulating both membranes. Fibroblast was the predominant cells which increased in density along the observation periods. Macrophages were also evident in the interface tissue at both experimental and control groups.

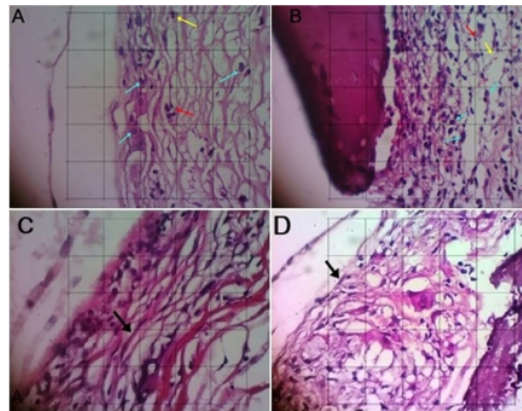


Figure 1. The microscopy of subcutaneous tissue surrounding the membrane. (A) the BPCM and (B) DFDBCMB were scarcely infiltrated with inflammatory cells, i.e. PMN (yellow arrow head), lymphocytes (red), macrophage (blue) indicating no evidence of prolonged inflammation. At 28

days post implantation the tissue was characterized with fibrous tissue encapsulating (C) BPCM and (D) DFDBCMB with fibroblast being the predominant cells (black arrows) (H&E staining, x400 magnification).

The result of immunohistochemical staining showed that the expression of TNF- α was noted in both experimental and control groups from day 2 until day 28 post implantation (figure 1). The TNF- α expression was found to be the highest on day 5 in both groups (Figure 3A) and declined gradually over time and still noted until day 28 post implantation.

The result of the IHC staining also showed that the expression of MMP-13 was noted in both experimental and control groups from day 2 until day 28 post implantation (figure 2). The MMP-13 expression was found to be highest on day 5 in both groups (Figure 3B) and declined gradually until 28 day post implantation.

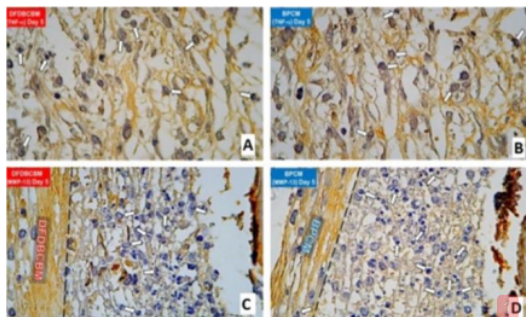


Figure 2. Immuno-staining showing the expression of TNF- α and MMP-13 in subcutaneous tissue surrounding membranes 5 days after implantation. Expression of TNF- α in (A) DFDBCMB and (B) BPCM group; arrow head pointing to positively stained cells (black staining in nuclei and dark brown in cytoplasm). Expression of MMP-13 in (C) DFDBCMB and (D) BPCM group; arrow head pointing to positively stained cells (nuclei in dark blue, cytoplasm light blue).

The result of immunohistochemistry examination revealed that TNF- α and MMP-13 expression in DFDBCMB and BPCM group followed the same pattern. Their expressions were noted on day 2, increased considerably on day 5, followed then by gradual decrease along the observation period (Figure 3).

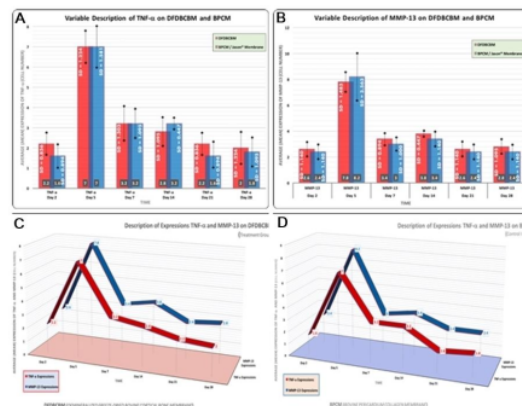


Figure 3. Mean expression of TNF- α dan MMP-13 following implantation of DFDBCMB and BPCM. The peak expression of (A) TNF- α and (B) MMP-13 were both noted at 5 days post implantation followed by gradual decline towards day 28. Correlation of TNF- α and MMP-13 expression post implantation of DFDBCMB and BPCM. (C) Correlation of TNF- α and MMP-13 expression in DFDBCMB group; (D) Correlation of TNF- α and MMP-13 expression in BPCM group.

Time	Group	p Value
Day 2	(n=5) (DFDBCMB)	0.0000
Day 5		0.4361
Day 7		0.7105
Day 14		0.2722
Day 21		0.2053
Day 28		0.6186

Table 1. Correlation test on TNF- α and MMP-13 expression in DFDBCMB group.

Statistical analysis with the use of Mann Whitney or T-test showed that the expression of TNF- α and MMP-13 between DFDBCMB and BPCM groups were found to be not significantly different in all observation days (Figure 3). The result of correlation test revealed that TNF- α and MMP-13 expression in DFDBCMB group were significantly correlated on day 2, whereas no correlation was found on day 5, 7, 14, 21 and 28 (Table 1). The result also showed that TNF- α and MMP-13 expression in BPCM group were significantly correlated on day 7 only, while no

correlation was found on day 2, 5, 14, 21 and 28 (Table 2).

Time	Group	p Value
Day 2	(n=5) (BPCM)	1.0000
Day 5		0.1407
Day 7		0.0305
Day 14		0.1654
Day 21		0.6309
Day 28		0.5993

Table 2. Correlation test on TNF- α and MMP-13 expression in BPCM group.

Discussion

Demineralized Freeze Dried Bovine Cortical Bone Membrane (DFDBCMB) is a novel membrane of xenogenic origin. It is made from bovine cortical bone which, after being treated with acid decalcification, contains only inorganic component mainly collagen type-I fibers. A study by our group revealed that Demineralized Freeze Dried Bovine Cortical Bone Membrane (DFDBCMB) was found to be potentially non-antigenic, non-cytotoxic, elicited normal immune and tissue response and underwent gradual biodegradation process following subcutaneous implantation in rat's dorsum.^{4,16} From the result of the study it was concluded that DFDBCMB membrane is potential to be used as GBR membrane. Nevertheless, the mechanism of DFDBCMB and BPCM biodegradation is still unclear thus far. An assumption holds that the higher the level of tissue inflammation after membrane implantation the higher the magnitude of membrane biodegradation.

In this study analysis of TNF- α expression was chosen as representation of inflammation level because it is one of the major pro-inflammatory cytokines expressed by majority of inflammatory cells. It is expressed by activated macrophages, fibroblast, lymphocyte CD4+, NK cell, neutrophil, endothelial cells, mast cell, eosinophil and even neuron⁸. This type of cytokine is one of the inflammatory mediators that play an important role in extracellular matrix (ECM) degradation, including degradation of collagen [9], by inducing expression of matrix proteolytic enzyme and decreasing extracellular

matrix macromolecule structure such as collagen type-I¹⁰. It also regulates the activities of immune cells, inhibits uptake process of collagen and induction of MMPs¹¹.

Matrix Metalloproteinases (MMP), also called matrixin, constitutes a group of zinc-dependant proteolytic enzymes which play a role in ECM remodeling and degradation mainly collagen. In healthy normal tissue MMPs are expressed by various cells at low level, while their expressions are increased in tissue remodeling and inflammation¹². Different types of MMPs exist such as MMP-1, MMP-8, MMP-13 dan MMP-18. The MMP-13, also referred to as collagenase-3, a member of collagenase subfamily of MMPs family has different form from MMP-1 (interstitial collagenase or collagenase-1) and MMP-8 (neutrophil collagenase or collagenase-2). Structurally, MMP-13 is composed of pro-peptide, catalytic domain and haemopexin-like domain which is involved in collagen degradation especially type-III and some type-I collagen¹³. MMP-13 together with the other MMPs degrade collagen into smaller fragments¹⁴. In this study analysis of MMP-13 expression was chosen because MMP-13 was known to work actively on type-I and type-III collagen as well as synthetic peptide¹⁵ commonly used in studies which are related with collagenase activities.

The result of the study exhibited no significant differences in TNF- α expression between DFDBCMB and BPCM groups from day 2 through day 28. This finding confirms that no excessive inflammatory response occurred after implantation of DFDBCMB in subcutaneous tissue. This is likely due to the fact that the two types of membranes are non-antigenic because they do not contain residual cells, namely osteoblast and osteocyte, as analyzed in our previous study⁴.

The result of the study also revealed that there was no significant difference in MMP-13 expression between the two groups throughout observation period. This finding may be attributed to the fact that both of the membranes contain collagenous material although structurally they are not exactly the same, DFDBCMB consists of collagen type-I, a specific cortical bone collagen, while BPCM is mainly composed of type-I and some type-III collagen.

The result of the study also showed that TNF- α and MMP-13 expressions were strongly increased on day 5 post implantation in both groups which were followed by gradual decrease

thereafter. This finding may be caused by increased activity of macrophage which reach their peaks within few days of acute inflammation and during early repair phase. Within 2 to 7 days of inflammation macrophage massively infiltrate the defect area by release of various enzymes and mediators¹³. This may be the reason for the increase in MMP-13 expression on day 5 post implantation of membranes in both groups.

Correlation analysis between TNF- α and MMP-13 expressions within DFDBCMB group showed that significant correlation was noted only on day 2, whereas in BPCM group correlation was found only on day 7. Based on these results we concluded that no correlation exists between TNF- α and MMP-13 expressions during biodegradation process of both DFDBCMB and BPCM.

Conclusions

Based on the results above we conclude that implantation of DFDBCMB and BPCM, to some extent, do not provoke excessive inflammatory response and they undergo comparable biodegradation process. Additionally, we also conclude that, in this study, there is no correlation between the level of inflammation and the magnitude of biodegradation.

Acknowledgements

⁶
The author would like to thank to Faculty of Dental Medicine, Universitas Airlangga and which has supported the study.

Declaration of Interest

The authors report no conflict of interest.

References

1. Retzepi M & Donos N. Guided Bone Regeneration: biological principle and therapeutic applications. *Clin. Oral Implants Res.* 2010;21(6): 567–76.
2. Bunyaratavej P & Wang HL. Collagen Membranes: A Review. *J. Periodontol.* 2001;72(2): 215–29.
3. Rothamel D, Schwarz F, Sager M, Herten M, Sculean A, Becker J. Biodegradation of differently cross-linked collagen membranes: an experimental study in the rat. *Clin. Oral Implants Res.* 2005;16(3):369–78.
4. Kamadjaja DB, Harjadi A, Soesilawati P, Wahyuni E, Maulidah N, Fauzi A, et al. Demineralized Freeze-Dried Bovine Cortical Bone: Its Potential for Guided Bone Regeneration Membrane. *Int. J. Dent.* 2017;2017:1–10.
5. Rothamel D, Schwarz F, Sager M, Herten M, Sculean A, Becker J. Biodegradation of differently cross-linked collagen membranes: an experimental study in the rat. *Clin. Oral Implants Res.* 2005;16(3):369–78.
6. Arx TV, Broggini N, Jensen SS, Bornstein M, Schenk R, Buser D. Membrane durability and tissue response of different bioresorbable barrier membranes: a histologic study in the rabbit calvarium. *Int. J. Oral Maxillofac. Implants.* 2005;20(6):843–53.
7. Lopresti ST & Brown BN. Host Response to Naturally Derived Biomaterials. *Host Response to Biomaterials.* 2015;2015:53–79.
8. Greenwel P, Tanaka S, Penkov D, Zhang W, Olive M, Moll J, et al. Tumor necrosis factor α inhibits type I collagen synthesis through repressive CCAAT/enhancer-binding proteins. *Mol. Cell. Biol.* 2000;20(3):912–8.
9. Gupta S & Gupta R. Guided Bone Regeneration with Pericardium Membranes. *IOSR J. Dent. Med. Sci.* 2014;13(11):61–5.
10. Hadjidakis DJ & Androulakis II. Bone remodeling. *Annals of the New York Academy of Sciences.* 2006;1092:385–396.
11. Donos N, Kostopoulos L, Karring T. Augmentation of the rat jaw with autogeneic cortico-cancellous bone grafts and guided tissue regeneration. *Clin. Oral Implants Res.* 2002;13(2):192–202.
12. Helling AL, Tsekoura EK, Biggs M, Bayon Y, Pandit A, Zeugolis DI. In Vitro Enzymatic Degradation of Tissue Grafts and Collagen Biomaterials by Matrix Metalloproteinases: Improving the Collagenase Assay. *ACS Biomater. Sci. Eng.* 2017;3(9):1922–32.
13. Johansson N, Ahonen M, Kähäri VM. Matrix metalloproteinases in tumor invasion. *Cell. Mol. Life Sci.* 2000;57(1):5–15.
14. Ye Q. Molecular and cellular mechanisms of collagen degradation in the foreign body reaction. *Groningen.* 2013;2013:215.
15. Knäuper V, López-Otin C, Smith B, Knight G, Murphy G. Biochemical characterization of human collagenase-3. *J. Biol. Chem.* 1996;271(3):1544–50.
16. Ari MDA, Yulianti A, Rahayu RP, Saraswati D. The Differences Scaffold Composition in Pore Size and Hydrophobicity Properties as Bone Regeneration Biomaterial. *J Int Dent Med Res.* 2017;10(2):333-37.

Expression of TNF- and MMP-13 Following Subcutaneous Implantation of Demineralized Freeze Dried Bovine Cortical Bone Membrane in Rat's Dorsum

ORIGINALITY REPORT

16%

SIMILARITY INDEX

9%

INTERNET SOURCES

12%

PUBLICATIONS

1%

STUDENT PAPERS

PRIMARY SOURCES

- 1 Y. Li, Y. Zhang, C. Chen, H. Zhang, C. Ma, Y. Xia. "Establishment of a rabbit model to study the influence of advanced glycation end products accumulation on osteoarthritis and the protective effect of pioglitazone", *Osteoarthritis and Cartilage*, 2016
Publication 2%
- 2 ir.unimas.my
Internet Source 1%
- 3 www.envirobiotechjournals.com
Internet Source 1%
- 4 unair.ac.id
Internet Source 1%
- 5 Tuti Kusumaningsih, Anis Irmawati, Diah Savitri Ernawati, Chiquita Prahasanti, Mohammed Aljunaid, Sarah Amelia. "The differences in the number of fibroblasts and blood vessels after the topical and systemic administration of Lactobacillus casei Shirota

probiotics for the treatment of traumatic ulcers in Wistar rats (*Rattus norvegicus*)", *Veterinary World*, 2021

Publication

6

David Buntoro Kamadjaja, Ni Putu Mira Sumarta, Andra Rizqiawan. "Stability of Tissue Augmented with Deproteinized Bovine Bone Mineral Particles Associated with Implant Placement in Anterior Maxilla", *Case Reports in Dentistry*, 2019

Publication

1 %

7

Cheng Chen, Chi Ma, Ying Zhang, Yuelin Zeng, Yuqing Li, Wanchun Wang. "Pioglitazone Inhibits Advanced Glycation End Product-Induced TNF- α and MMP-13 Expression via the Antagonism of NF- κ B Activation in Chondrocytes", *Pharmacology*, 2014

Publication

1 %

8

Abd Al-Rahman Mohammad Foda, Amira K. El-Hawary, Azza Abdel-Aziz. "Matrix metalloproteinase-13 expression in the progression of colorectal adenoma to carcinoma", *Tumor Biology*, 2014

Publication

1 %

9

worldwidescience.org

Internet Source

1 %

10

Kresnoadi Utari, Ruslianda Diva Amelia, Laksono Harry. "The potential for induction of

1 %

the expression of bone morphogenetic protein-7 and alkaline phosphatase in postextraction tooth sockets using a combination of mangosteen peel extract and DFDBBX", Journal of Applied Pharmaceutical Science, 2022

Publication

11

www.freepatentsonline.com

Internet Source

1 %

12

Utari Kresnoadi, Retno Pudji Rahayu, Maretaningtias Dwi Ariani, Soesanto Soesanto. "The Potential of Natural Propolis Extract Combined with Bovine Bone Graft in Increasing Heat Shock Protein 70 and Osteocalcin on Socket Preservation", European Journal of Dentistry, 2020

Publication

1 %

13

www.tandfonline.com

Internet Source

1 %

14

Zaki, Mohamed M., Hazem M. Ataa, Helpies D. Shenouda, Mohamed M. Yousef, and Nessrein E. Ahmed. "Effect of mesenchymal stem cells administered by two different routes on experimentally induced liver fibrosis in rats :", The Egyptian Journal of Histology, 2011.

Publication

<1 %

15

Joan Montaner. "Matrix metalloproteinase-13 is activated and is found in the nucleus of

<1 %

neural cells after cerebral ischemia", Journal
of Cerebral Blood Flow & Metabolism,
11/05/2008

Publication

16

www.ncbi.nlm.nih.gov

Internet Source

<1 %

17

Hyun Seok, Min Keun Kim, Seong-Gon Kim,
HaeYong Kweon. "Comparison of Silkworm-
Cocoon-Derived Silk Membranes of Two
Different Thicknesses for Guided Bone
Regeneration", The Journal of Craniofacial
Surgery, 2014

Publication

<1 %

18

Mircea Tampa, Simona Roxana Georgescu,
Madalina Irina Mitran, Cristina Iulia Mitran et
al. "Current Perspectives on the Role of Matrix
Metalloproteinases in the Pathogenesis of
Basal Cell Carcinoma", Biomolecules, 2021

Publication

<1 %

19

ebin.pub

Internet Source

<1 %

20

link.springer.com

Internet Source

<1 %

21

dokumen.pub

Internet Source

<1 %

22

e-journal.unmas.ac.id

Internet Source

<1 %

23

Qingshan Yang, Shujin Wu, Xinzhan Mao, Wanchun Wang, Huiping Tai. "Inhibition Effect of Curcumin on TNF-a and MMP-13 Expression Induced by Advanced Glycation End Products in Chondrocytes", Pharmacology, 2013

Publication

<1 %

24

Sindy Cornelia Nelwan, Ricardo Adrian Nugraha, Anang Endaryanto, Frisma Dewi et al. " Effect of scaling and root planing on level of immunoglobulin E and immunoglobulin G in children with gingivitis and house-dust mite allergy: A pilot randomised controlled trial ", Singapore Dental Journal, 2020

Publication

<1 %

25

"1-A1: Lung Cancer 1 : Poster Sessions", Respirology, 2013.

Publication

<1 %

26

Gentaro Uchida. "Tretinoin reverses upregulation of matrix metalloproteinase-13 in human keloid-derived fibroblasts", Experimental Dermatology, 10/2003

Publication

<1 %

27

Pratiwi Soesilawati, Andra Rizqiawan, Retno Indrawati Roestamadji, Ahmad Rizal Arrosyad et al. "In vitro Cell Proliferation Assay of Demineralized Dentin Material Membrane in

<1 %

Osteoblastic MC3T3-E1 Cells", Clinical, Cosmetic and Investigational Dentistry, 2021

Publication

Exclude quotes On

Exclude matches Off

Exclude bibliography On

Expression of TNF- and MMP-13 Following Subcutaneous Implantation of Demineralized Freeze Dried Bovine Cortical Bone Membrane in Rat's Dorsum

GRADEMARK REPORT

FINAL GRADE

/100

GENERAL COMMENTS

Instructor

PAGE 1

PAGE 2

PAGE 3

PAGE 4

PAGE 5
