

# The Potential of Red Dragon Fruit (*Hylocereus polyrhizus*) Rind Extract Accelerates Wound Healing Process Post Tooth Extraction

*by* Hendrik Setia Budi

---

**Submission date:** 13-Jun-2022 07:34AM (UTC+0800)

**Submission ID:** 1855541911

**File name:** 2.\_MJMHS-2020-0222\_Artikel.pdf (828.87K)

**Word count:** 3010

**Character count:** 16185

## ORIGINAL ARTICLE

7

## The Potential of Red Dragon Fruit (*Hylocereuspolyrhizus*) Rind Extract Accelerates Wound Healing Process Post Tooth Extraction

7

Hendrik Setia Budi<sup>1</sup>, Wisnu Setyari Juliastuti<sup>1</sup>, Rini Devijanti<sup>1</sup>, Yuliati Yuliati<sup>1</sup>, Rofillah Putri Andhini<sup>2</sup>

4

<sup>1</sup> Department of Oral Biology, Faculty of Dental Medicine, Universitas Airlangga, Surabaya, Indonesia

<sup>2</sup> Undergraduate Program, Faculty of Dental Medicine, Universitas Airlangga, Surabaya, Indonesia

### ABSTRACT

**Introduction:** Biological process of wound healing in soft tissue injury which include some phase that its highly organized cascade, such as haemostasis, inflammation, proliferation and remodeling. Healing process will be impaired when there is an interference with one of the four of the phase not going well. This study is aimed to proving the role of dragon fruit peel extract towards the interpretation of TGF- $\beta$ , fibroblast cell and formation of new blood vessels during wound healing process. **Methods:** 20 rattus norvegicus wistar strain rats are separated into four groups. The one lower incisor is extracted, afterward the wound post extraction of the treatment group was treated with dragon fruit peel extract gel with the concentration of 15%, 30% and 60%, meanwhile, for the control groups, they are treated with polyethylene glycol gel. On the fourth day, the rats were sacrificed and preparation of immunohistochemical and histopathology are made. Observe under the light microscope with 400x magnification. **Results:** This study shows that the 30% concentration increase the expression of TGF- $\beta$  ( $16.6\pm 2.07$ ), fibroblast proliferation ( $77.6\pm 5.27$ ) and new blood vessels ( $33.8\pm 2.28$ ) compare to the control group, 15% and 60% concentration in a meaningful way ( $p=0.00$ ,  $p=0.00$  and  $p=0.00$ ). **Conclusions:** The dragon fruit peel extract gel may affect the wound healing process of extraction by increasing the expression of TGF- $\beta$ , number of fibroblast and formation of new blood vessels.

**Keywords:** Dragon fruit peel, TGF- $\beta$ , Fibroblast, New blood vessel, Socket wound healing

### Corresponding Author:

Wisnu Setyari Juliastuti, MDS  
Email: wisnu-s-j@fkg.unair.ac.id  
Tel: +62-315030255

Factor (EGF), Insulin-like Growth Factor (IGF), Platelet-derived Growth Factor (PDGF), and Transforming Growth Factor-beta (TGF- $\beta$ ) which have roles in neutrophil chemotaxis, macrophage, mast cell, endothelial cell and fibroblast (6,7).

### INTRODUCTION

The oral soft tissue is often suffered trauma which can create wound in every care measure in dentistry. The tooth extraction is one of the action that is often conducted in dentistry, which causes wounds, both in the soft and hard tissues, therefore, the body responds physiologically with wound healing (1,2). The wound healing process, from the start of the trauma up to the healing, consists of complex stages, they are inflammation phase, proliferation phase and maturation phase (3,4,5).

The platelet is stimulated by collagen to start blood coagulation process, when the blood vessel breaks. The platelet forms clot by closing the exposed vascular and exerts substance that causes the vasoconstriction of capillary blood vessel, then it is continued by endothelial attachment that closes the blood vessel. Those hemostatic components release and activate pro-inflammation cytokine, such as, *Epidermal Growth*

The acceleration of wound healing process is influenced by some factors, such as nutrition. Red dragon fruit (*Hylocereuspolyrhizus*) has peel that contain active compounds, such as cyanidin-3-O-glucoside, flavonoids, thiamine, niacin, pyridoxine, cobalamin, phenolic, polyphenol, terpenoid, carotene, phytoalbumin, betalaine, tannin, saponin and vitamin C (8,9,10).

The result of previous research shows that red dragon fruit peel has higher antioxidant activity if compares to its flesh, therefore, it has the potential to be developed as the source of natural antioxidant (9,11,12).

Some active substance with antioxidant characteristic contained in the peel of dragon fruit may accelerate the wound healing process. Saponin and tannin contents have the role in tissue regeneration in wound healing process. Flavonoid accelerates wound healing by inhibiting lipid peroxidation, so that may increase

collagen fiber and vascularization, and also has the role to intercept the free radicals. Vitamin C as the antioxidant helps wound healing process by influencing collagen synthesis, the integrity of blood vessel walls, fibroblast, and macrophage migration (13,14). Therefore, it needs to be proven whether the peel of red dragon fruit (*Hylocereus polyrhizus*) may increase the expression of TGF- $\beta$ , number of fibroblast cell and new blood vessel during wound healing process.

## MATERIALS AND METHODS

### 4. Samples

This study was approved by the Ethical Committee of the Faculty of Dental Medicine, Universitas Airlangga, Indonesia 278/KKEPK.FKG/XI/2016. This study was experimental with the randomized post test only control group design. The animals study used are 20 *rattus norvegicus* wistar strain rats, male, age 2-3 months, weighing 200-300 grams which are separated into four groups, they are control and treatment groups that are given dragon fruit peel extract gel with the concentration of 15%, 30% and 60%.

### 2. Dragon fruit peel extract preparation

The red dragon fruit peel extract is obtained with maseration method. The dry peel of red dragon fruit is pounded into powder, then, it is inserted into extractor shaker and added with chloroform with the comparison of 1:1 for 24 hours, then, it is strained to obtain filtrate I and residue. Chloroform is added into the residue with the comparison of 1:1 and inserted into the shaker for 24 hours, then, it is strained to obtain filtrate II and residue. Filtrat II is mixed with filtrat I, then, it is embedded into evaporator vacuum (Heidolph, Finland) and evaporated in the temperature of 40-50°C until the chloroform is evaporated, and the extra of red dragon fruit peel is obtained. The preparation of red dragon fruit peel extract gel is made with the concentration of 15%, 30% and 60% with Carboxymethylcellulose (CMC) (Spectrum, US) as the carrier substance.

### Tooth extraction technique and postoperative management

The animals study were adapted for one week, and separated to four groups. The rats were anesthetized using ketamine by inhalation inside the glass box, then, lower right incisor tooth is extracted with special pliers. The socket is irrigated with sterile aquades to cleanse the debris from tooth extraction, and treated topically with red dragon fruit peel extract gel concentration of 15%, 30% and 60%, meanwhile, for the control group, the animals are treated with CMC gel. The rats were sacrificed on the fourth day by using lethal dosage of ketamine. Mandibles were processed to evaluate healing of the extraction socket.

Immunohistochemical and histopathological preparation  
Fixation the tissue into 10% formalin buffer for 24

hours, and inserted into automatic tissue processor (Resilent, Jerman). Dehydrated by alcohol gradually from concentration of 70 to 100% for 15 minutes each. The next process was clearing by inserting the tissue into xylol solution for 2x30 minutes, then, embedding is done with parafin solution in the temperature of 56°C for 2 x 30 minutes. The preparation is made into parafin block and cut with rotary microtome in the thickness of 3 $\mu$ m - 5 $\mu$ m. The immunohistochemical of TGF- $\beta$  expression was conducted with kit rabbit anti-TGF- $\beta$  polyclonal antibody (Bioss, US), and histopathology investigation of fibroblast and new blood vessel are done by Hematoksilin Eosin (HE) staining. We used three tissue sections each animal. The observation was conducted by counting the expression of TGF- $\beta$ , number of fibroblast and new blood vessel using light microscope with 400x magnification on 5 field of view of each group.

### Statistical analysis used

The data was collected and tabulated using Statistical Package for the Social Sciences (SPSS 17) program with the One Way Anova test to know the difference of the effect of red dragon fruit peel extract application towards the enhancement of the expression of TGF- $\beta$ , number of fibroblast and new blood vessel on the extraction wound between groups.

## RESULTS

### Immunohistochemical and histopathological analysis with light microscope

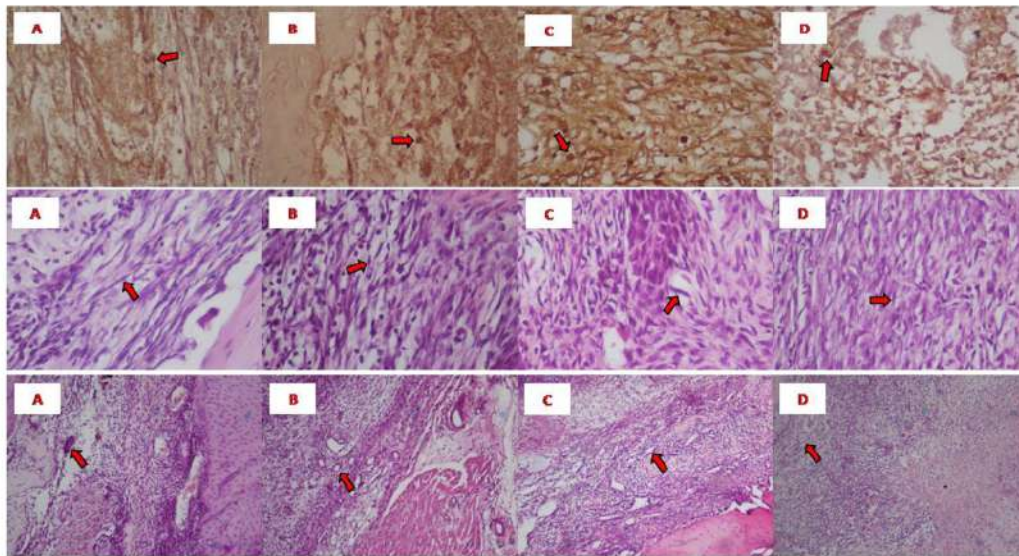
The result shows the increase of TGF- $\beta$  expression if it is compared with the control group on the fourth day of observation. The number of fibroblast cell and new blood vessel show the increase on the groups that are treated with dragon fruit peel extract gel. The illustration of the increase of TGF- $\beta$  expression, fibroblast and new blood vessel between each group (figure 1).

### TGF- $\beta$ expression, fibroblast and new blood vessel in socket wound healing

The staining data of TGF- $\beta$  expression, fibroblast and new blood vessel are tabulated and analyzed to know the difference of each group. The data of TGF- $\beta$  expression, fibroblast and new blood vessel show distributed normally and homogeneous ( $p > 0.05$ ) by Kolmogorof Smirnof and Levene Test. According to the statistic test of the One Way Anova, there are significant differences ( $p < 0.05$ ) between the control group and treatment groups that are treated with red dragon fruit peel extract gel with the concentration of 15%, 30% and 60%, but there is no significant difference between treatment group in the concentration of 15% and 60% (table I).

## DISCUSSION

Physiologically, wound healing process, mainly, consists



**Figure 1: Immunohistochemical and histopathological staining on socket wound healing fourth day.** The expression of TGF- $\beta$ , proliferation of fibroblast and new blood vessel with light microscope at 400x magnification indicated by red arrow of A. Control, B. Concentration of 15%, C. Concentration of 30%, D. Concentration of 60%.

**Table 1: The difference in the number of TGF- $\beta$  expression, fibroblast, and new blood vessel in each group**

Group	TGF- $\beta$ $\pm$ SD	Fibroblast $\pm$ SD	New Blood Vessel $\pm$ SD
Control	8.4 $\pm$ 1.14 <sup>a</sup>	21.4 $\pm$ 3.78 <sup>a</sup>	18.6 $\pm$ 4.45 <sup>a</sup>
15% Concentration	9.8 $\pm$ 1.64 <sup>b</sup>	42.8 $\pm$ 2.86 <sup>b</sup>	26.6 $\pm$ 1.52 <sup>b</sup>
30% Concentration	16.6 $\pm$ 2.07 <sup>cd</sup>	77.6 $\pm$ 5.27 <sup>cd</sup>	33.8 $\pm$ 2.28 <sup>d</sup>
60% Concentration	10.0 $\pm$ 3.39 <sup>bc</sup>	46.0 $\pm$ 6.48 <sup>bc</sup>	23.6 $\pm$ 1.95 <sup>bc</sup>

The difference superscript in each column shows significant difference.

of three phases of which the mechanism is overlapped with the next phase, which are inflammation phase, proliferation phase and remodeling phase. Inflammation, proliferation and remodeling phases are one continuous unity in wound healing process. Inflammation phase happens when the wound occurs and up to three days; proliferation phase happens between three to 10 days; and the last phase, remodeling phase happens between three to 30 days (15,16). This healing process may happen fast or slow depends on some factors, one of the factors is the application of medicinal ingredients; and in this control group, they are treated with carrier gel, which is 2MC, the treatment group 1, 2 and 3 are treated with red dragon fruit peel extract gel with the concentration of 15, 30 and 60%.

The observation is conducted on the fourth day, because there was proliferation of epithelial on the wound surface of the blood coagulation on the third day. Aside from that, the fibroblast from the alveolar bone wall is also proliferated and dispersed into blood coagulation and the granulation tissue on the edge of the socket. On the fifth day, the gap on the wound is filled by granulation tissue with maximum vascularization. The collagen fiber

develops and starts to connect both side of the wound. This collagen fiber protects the epidermis, therefore, the composition and differentiation on the surface cell produce matured epidermal cell and keratin coating is formed on the surface of the socket (17,18).

The flesh and peel of red dragon fruit have the potential of medicinal ingredients due to containing of isianidin 3-ramnosil glucosida 5-glukosida, flavonoid, thiamine, niacin, pyridoxine, cobalamine, phenolic, polyphenol, carotene, fitoalbumin, and betalain (9,19). The other study shows that red dragon fruit peel extract has active substances with antioxidant characteristic, which are vitamin C, flavonoid, tannin, alkaloid, steroid and saponin (10,21).

This study showed that the application of red dragon fruit peel extract gel on each treatment group with the concentration of 15, 30 and 60% can increase the number of TGF- $\beta$  expression, fibroblast and new blood vessel on the extraction wound significantly, compares to the control group. The increase of TGF- $\beta$  expression, number of fibroblast and new blood vessel mostly happened to the group with 30% concentration of red dragon fruit peel extract gel, on the group with 60% concentration, the effect is decreased and on par with the 15% concentration group. Therefore, it can be said that 30% concentration of red dragon fruit peel extract gel is the optimum concentration to increase TGF- $\beta$  expression, number of fibroblast and new blood vessel. The active substance within the peel of dragon fruit, such as, flavonoid, inhibit the arachidonic acid through lipooxygenase channel which follows with the inhibition of the production of prostaglandin,

thromboxane and leucotriene as the inflammation mediator, therefore, leucocyte migration into the inflammation area is decreased. This may accelerate the inflammation process into proliferation phase, that way, the wound healing happens faster. This flavonoid is also able to stimulate the production of TGF- $\beta$ , therefore, during observation, the increase of TGF- $\beta$  is shown. The increase of TGF- $\beta$  expression causes the increase of the number of fibroblast, because TGF- $\beta$  is the main factor that stimulates the formation of fibroblast, (20) moreover, TGF- $\beta$  is also stimulated VEGF for new blood vessel formation (angiogenesis) of which in this study the new blood vessel number is increased following the increase of TGF- $\beta$ .

The others active compound in the peel of dragon fruit also has tannin content. The other study proved that tannin has the ability as antimicrobial, and also accelerate the wound healing with some cellular mechanism, such as, cleanse the free radicals and reactive oxygen, increase the wound healing continuity and capillary new blood vessel formation and also fibroblast (22,23). The vitamin C content in red dragon peel extract has the antioxidant ability which helps with wound healing process by stimulating macrophage migration, the integrity of blood vessel walls, fibroblast proliferation and collagen synthesis (13,14,24).

## CONCLUSION

This conclusion of this study showed that the 30% concentration of red dragon fruit extract has the biggest effect compares to the other treatment groups. Therefore, from this research, it can be concluded that the red dragon fruit peel extract gel increases the expression of TGF- $\beta$ , number of fibroblast and new blood vessel in the wound healing process of extraction wound on *rattus norvegicus* wistar strain.

## ACKNOWLEDGEMENTS

We thank you for the support of the Research Center for the completion of this research.

## REFERENCES

- Rajan SR, Hussain KA, Tarakji B, Azzeghaibi SN, Sirajuddin S. Iatrogenic damage to the periodontium caused by exodontic treatment procedures: An overview. *Open Dent J*. 2015;9:197-9.
- Politis C, Schoenaers J, Jacobs R, Agbaje JO. Wound healing problems in the mouth. *Front Physiol*. 2016;7:507.
- Bielefeld KA, Amini-Nik S, Alman BA. Cutaneous wound healing: recruiting developmental pathways for regeneration. *Cell Mol Life Sci*. 2013;70(12):2059-81.
- Eming SA, Martin P, Tomic-Canic M. Wound repair and regeneration: mechanisms, signaling, and translation. *Sci Transl Med*. 2014;6(265):265sr6.
- Guo S, DiPietro LA. Factors affecting wound healing. *J Dent Res*. 2010;89(3):219-29.
- Gosain A, DiPietro LA. Aging and wound healing. *World J Surg*. 2004;28(3):321-6.
- Broughton G 2nd, Janis JE, Attinger CE. The basic science of wound healing. *Plast Reconstr Surg*. 2006;117(7 Suppl):12S-34S.
- Campos AC, Groth AK, Branco AB. Assessment of nutritional aspects of wound healing. *Curr Opin Clin Nutr Metab Care*. 2008;11(3):281-8.
- Jaafar RA, Rahman ARBA, Mahmud NZC, Vasudeven R. Proximate analysis of dragon fruit (*Hylocereus polyrhizus*). *Am J Appl Sci*. 2009;6:1341-6.
- Ramli NS, Ismail P, Rahmat A. Influence of conventional and ultrasonic-assisted extraction on phenolic contents, betacyanin contents, and antioxidant capacity of red dragon fruit (*Hylocereus polyrhizus*). *Sci World J*. 2014:964731.
- Priliyana R, Syed ZI, Mustapha SK, Aisyah MR, Kamarul RK. Antioxidant study of pulps and peels of dragon fruits: a comparative study. *Int Food Res J*. 2010;17:367-75.
- Adnan L, Osman A, Hamid AA. Antioxidant activity of different parts of red pitaya (*Hylocereus polyrhizus*) seed. *Int J Food Prop*. 2011;14(6):1171-81.
- Gaspar A, Craciunescu O, Moldovan L, Ganea E. New composites collagen-polyphenols as potential dressing for wound care. *Rom J Biochem*. 2012;49(2):173-81.
- Iladiyah I, Prabowo BR. Ethanolic extract of *Predera cordifolia* (Ten.) Steenis leaves improved wound healing in guinea pigs. *Univ Med*. 2012;31(1):4-11.
- Gonzalez AC, Costa TF, Andrade ZA, Medrado AR. Wound healing - a literature review. *An Bras Dermatol*. 2016;91(5):514-20.
- Landin NX, Li D, Stehle M. Transition from inflammation to proliferation: a critical step during wound healing. *Cell Mol Life Sci*. 2016;73(20):3861-85.
- Reinke JM, Sorg H. Wound repair and regeneration. *Eur Surg Res*. 2012;49(1):35-43.
- Kubilius M, Kubilius R, Gleiznys A. The preservation of alveolar bone ridge during tooth extraction. *Stomatologija*. 2012;14(1):3-11.
- Woo KK, Ngou FH, Ngo LS, Soong WK, Tang PY. Stability of betalain pigment from red dragon fruit (*Hylocereus polyrhizus*). *Am J Food Tech*. 2011;6(2):140-8.
- Pakyari M, Farrokhi A, Maharlooeei MK, Ghahary A. Critical role of transforming growth factor beta in different phases of wound healing. *Adv Wound Care*. 2013:215-24.
- Rafieian-Kopaie M, Baradaran A. Plants antioxidants: From laboratory to clinic. *J Nephropathy*. 2013;2(2):152-3.

22. Sheikh AA, Sayyed Z, Siddiqui AR, Pratapwar AS, Sheakh SS. Wound healing activity of *Sesbania grandiflora* Linn flower ethanolic extract using excision and incision wound model in wistar rats. *Int J Pharm Tech Res.* 2011;3(2):895-8.
23. Budi HS, Juliasuti WS, Pitaloka NPC. Antioxidant effect of red dragon fruit peel (*Hylocereus polyrhizus*) extract in chronic periodontitis rats. *J Int Dent Med Res.* 2019;12(4):1363-7.
24. Iqbal K, Khan A, Khattak MMAK.. Biological significance of ascorbic acid (vitamin c) in human health – a review. *Pakistan J Nutr.* 2004;3(1):5-13.

# The Potential of Red Dragon Fruit (*Hylocereus polyrhizus*) Rind Extract Accelerates Wound Healing Process Post Tooth Extraction

## ORIGINALITY REPORT

17%

SIMILARITY INDEX

12%

INTERNET SOURCES

14%

PUBLICATIONS

%

STUDENT PAPERS

## PRIMARY SOURCES

1	"Wound Healing Research", Springer Science and Business Media LLC, 2021 Publication	2%
2	<a href="http://www.neliti.com">www.neliti.com</a> Internet Source	2%
3	<a href="http://www.coursehero.com">www.coursehero.com</a> Internet Source	2%
4	<a href="http://www.sysrevpharm.org">www.sysrevpharm.org</a> Internet Source	1%
5	<a href="http://brief.land">brief.land</a> Internet Source	1%
6	Novi Febrianti, Purwanti P. Purbosari, Triana Hertiani, Sukarti Moeljopawiro, Sofia M. Haryana. "Antioxidant Potency of Red Dragon Fruit Flesh and Peel Prepared by Different Methods", Current Nutrition & Food Science, 2020 Publication	1%

7	<a href="https://news.unair.ac.id">news.unair.ac.id</a> Internet Source	1 %
8	U Dianasari, R Malaka, F Maruddin. "Physicochemical quality of fermented milk with additional red dragon fruit ( <i>Hylocereus polyrhizus</i> ) skin", IOP Conference Series: Earth and Environmental Science, 2020 Publication	1 %
9	<a href="http://www.jidmr.com">www.jidmr.com</a> Internet Source	1 %
10	Widya Hary Cahyati, Nur Siyam, Natalia Desy Putriningtyas. "The potential of red dragon fruit peel yogurt to improve platelet levels in heparin-induced thrombocytopenia in Wistar rats", Potravinarstvo Slovak Journal of Food Sciences, 2021 Publication	1 %
11	<a href="http://so01.tci-thaijo.org">so01.tci-thaijo.org</a> Internet Source	1 %
12	Addion Nizori, Lamtiar. "Study of Red Dragon Fruit Peel ( <i>Hylocereus Polyrhizus</i> ) Extract as Natural Food Colorants to Physicochemical Properties Of Pedada's Jam as Functional Foods", IOP Conference Series: Earth and Environmental Science, 2020 Publication	1 %



13	Internet Source	1 %
14	Sowmya Raghupathy, Lalitha Vaidyanathan, Lokeswari Sivaswamy. "Adult Zebrafish Model of Wound Inflammation to Study Wound Healing Potency of Curcuma longa Extracts Title changed as suggested by the reviewer", Annual Research & Review in Biology, 2017 Publication	1 %
15	Panda, V., and T. Thakur. "Wound Healing Activity of the Inflorescence of Typha elephantina (Cattail)", The International Journal of Lower Extremity Wounds, 2014. Publication	<1 %
16	Rosy Setiawati, M.S. Suarnata, Paulus Rahardjo, Del Grande Filippo, Giuseppe Guglielmi. "Correlation of quantitative diffusion weighted MR imaging between benign, malignant chondrogenic and malignant non-chondrogenic bone tumors with histopathologic type", Heliyon, 2021 Publication	<1 %
17	<a href="http://doc-pak.undip.ac.id">doc-pak.undip.ac.id</a> Internet Source	<1 %
18	<a href="http://biomaterialsres.biomedcentral.com">biomaterialsres.biomedcentral.com</a> Internet Source	<1 %

19

Internet Source

<1 %

---

20

[www.surgicalcosmetic.org.br](http://www.surgicalcosmetic.org.br)

Internet Source

<1 %

---

Exclude quotes Off

Exclude matches < 10 words

Exclude bibliography On