

Primary Laryngeal Tuberculosis

by Aditya Brahmono

Submission date: 10-Mar-2021 12:15PM (UTC+0800)

Submission ID: 1529015830

File name: Primary_Laryngeal_Tuberculosis.pdf (275.79K)

Word count: 2246

Character count: 12116

Case Report

Primary laryngeal tuberculosis

Aditya Brahmono*, Nyilo Purnami, Muhtarum Yusuf

5

Department of Otorhinolaryngology-Head and Neck Surgery, Faculty of Medicine, Airlangga University, Dr. Soetomo Teaching Hospital, Surabaya, Indonesia

8

Received: 04 February 2019

Revised: 14 March 2019

Accepted: 18 March 2019

*Correspondence:

Dr. Aditya Brahmono,

E-mail: adiet_sked@yahoo.co.id

Copyright: © the author(s), publisher and licensee Medip Academy. This is an open-access article distributed under the terms of the Creative Commons Attribution Non-Commercial License, which permits unrestricted non-commercial use, distribution, and reproduction in any medium, provided the original work is properly cited.

ABSTRACT

11

Primary laryngeal tuberculosis (TB) is a very rare disease that became the most common causes of granuloma disease in the larynx. The manifestation of tuberculosis on the laryngeal is commonly local without systemic symptom. This case reported was 21 year old male that complained of hoarseness for 6 months. The results of the fiber optic laryngoscopy (FOL) is generally believed a papilloma of the larynx. Biopsy extraction with microlaryngeal surgery was a mandatory procedure that apparently showing an overview of TB based on the results of histopathology and polymerase chain reaction (PCR). Anti-tuberculosis drugs were given to the patients, the evaluation carried out six months after the patient obtain intensive therapy and continue therapy with good result. Due to the non specific laryngeal sign that was observed on clinical examination, clinicians must consider the possibility of primary laryngeal tuberculosis. Biopsy the lesion on larynx continued with histopathology examination must not hesitate to confirm the diagnosis. PCR can be considered the better way to detect the TB bacteria.

Keywords: Primary laryngeal tuberculosis, Granuloma, Hoarseness, Anti tuberculosis drugs

9

INTRODUCTION

Tuberculosis is a chronic infection caused by *Mycobacterium tuberculosis* (MTB) and a mayor health problem that commonly involving the lung and other human organs.¹ The age group of the patients was being affected by TB on the laryngeal that typically affects the young adolescents, but a recent study showed the incidence of the disease increases in the decade by ages 50 and 60 years. Before the anti TB with high efficacy was obtained, an incidence of extra pulmonary TB was reported by 30%.²

Currently, the primary laryngeal TB cases is reported relatively rare, that estimated only 1% to 10%.² The primary laryngeal TB is represent the most frequent granulomatous diseases and lately laryngeal TB has no longer associated with pulmonary TB. It is because a

patient of laryngeal TB have no complaint in the lung anymore.³

CASE REPORT

A 21 year old male who work at a health facility living in Surabaya was admitted to the otholaryngology at Dr. Soetomo general hospital. The subject were has a symptoms for 6 month history of hoarseness, referred by otorhinolaryngologist with dysphonia diagnosis, hoarseness with cough without phlegm, no fever, night sweats and weight loss. Based on history of the patient had contacted with the TB patients's family. No history of TB in the patient's family, tumor and other malignancy. Also, no history of heart disease, lung disease or diabetes melitus also no smoking habits.

In addition, on the physical examination there were obtained no abnormality. While, on fiber optic

3

laryngoscopy examination we obtained epiglottis and right vocal cord normaly, but there was a rounded mass formation slick redness in left third anterior of the vocal cords (Figure 1) impressive a papilloma. The patient diagnosed as a laryngeal papilloma and planned to undergo extraction and biopsy with micro laryngeal surgery (MLS) procedure.

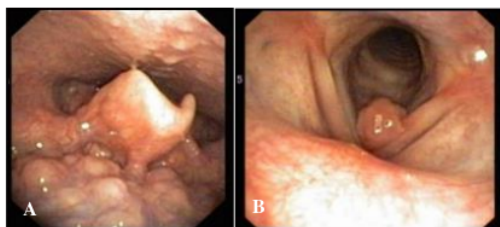


Figure 1 (A and B): Appearance of fiber optic laryngoscope, the mass formation slick of redness in the left third anterior of the vocal cords (white arrow).

MLS extract and biopsy of the mass was revealed a granulation without epithelial lining with proliferation of capillary blood vessels and mononuclear inflammatory cell infiltrates, we also obtained epitheloid cells form granoma with multinucleated giant cell (Figure 2). But, there was no evidence of malignancy. While, the anatomy pathologist concluded that the biopsy tissue was a spesific inflammatory TB process.

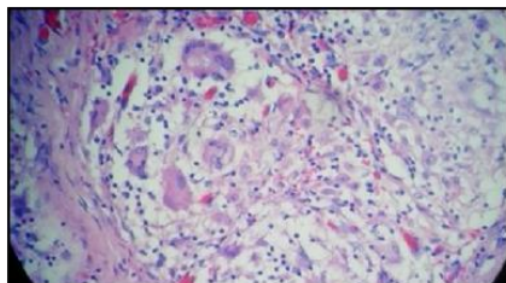


Figure 2: Appearance tissue biopsy; multinucleated giant cell (white arrow).

Laboratory and chest X-ray's result was normal. Polymerase chain reaction (PCR) examine undergo on blood and tissue extraction of the patient. The blood PCR was negative and tissue PCR was positive of MTB.

Based on the results of tissue biopsy and PCR patient's were diagnosed of primary laryngeal TB. A standard six month course of anti tuberculosis therapy and intensive therapy was given for 2 month then followed with 4 month. Later on, the patient was given combination of anti TB included rifampisin, pyrazinamide, isoniazid and ethambutol. The evaluation was performed for 2 and 4 month after receive intensive therapy. After the treatment, the patient's symptoms had show a good resolution.

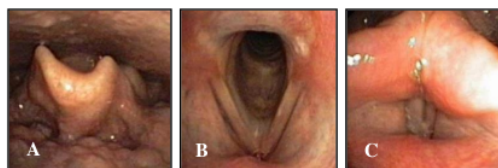


Figure 3 (A-C): Appearance fiber optic laryngoscopy after 2 month therapy.

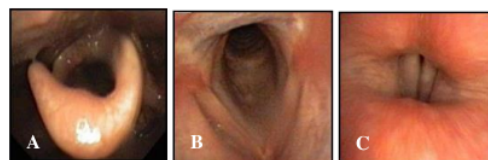


Figure 4 (A-C): Appearance fiber optic laryngoscopy after 4 month therapy.

The fiber optic of laryngoscopy result after 2 and 4 month therapy was showed a normal epiglottis, no mass on the left and right vocal cord also a movement of the left and right vocal cord on a good stated (Figures 3 and 4).

DISCUSSION

10
Laryngeal tuberculosis is a chronic infectious disease of the larynx that caused by MTB. It is known to be the most common form of the granuloma disease of larynx.²

Based on patients data who visited to ortholaryngology at Dr. Seotomo general hospital surabaya early 2012 until the end of 2014, we obtained 13 cases of scondary laryngeal TB and 1 primary laryngeal TB cases during that period. In 2013 up to 2015 it have been reported as 6 cases of primary laryngeal TB and 29 secondary laryngeal TB in Dr. M Djamil hospital Padang. Masashi reported 1 case of primary laryngeal TB and 16 secondary laryngeal TB cases in 2009 through 2013 in the central hospital of Osaka, Japan. The incidence of primary laryngeal TB cases are rare with a numbers less than 20% worldwide, the involvement of the larynx as a secondary infection of pulmonary tuberculosis is more common in the population compared to the involvement of the larynx as a primary infection from MTB.⁴

Masashi reported that this case is more dominant in male that range from 30 to 80 years. While, Nishiike showed laryngeal TB is more dominant in male by a ratio of 2: 1 and an average age of 51 years.⁴ An individuals with HIV infection or immunocompromised, workers in health facilities, immigrants, the elderly and low economic status has a considerable high risk factor to the disease.⁵ In this case the patient profession working in health facilities increases the risk of primary laryngeal TB at a younger age.

The primary laryngeal TB diagnosis could be established based on history, physical examination and investigations. In this case report, the mayor complaint was hoarse voice for 6 months. Smulders said 85% of primary laryngeal TB cases showed symptoms of major hoarse voice without constitutional symptoms. The main symptom of this case is needs to be distinguished from chronic laryngitis and structural disorder such as a laryngeal tumor or malignancy.⁶

Fiber optic laryngoscopy examination of primary laryngeal in TB patients might be demonstrated as laryngeal hyperemia, oedim, mucosal hypertrophy of the posterior third of the larynx, ulcerative lesions with nodules on the vocal cords, papilloma, leukoplakia and granuloma eksofitik.³ The result remain needs to be distinguished from other causes laryngeal lesions such as polyps, papilloma cyst, fungal infections, leprosy, syphilis, granuloma Wegener and laryngeal malignancy.²

The location of primary laryngeal TB lesion could be showed at different site.² Clery and Batsakis mentioned that the location of the lesions in the half anterior part of the larynx was increased twice as often as lesions in the posterior half of the larynx, vocal cords lesions on the most location (50-70%) followed by the vestibular fold (40-50%), epiglottis, subglottic, arytenoid, fold ariepigolitika and komissura posterior (10-15%).⁷ Overview fiber optic examination in patients according to the literature shows a picture resembling papilloma mass in the anterior third of the vocal cords.

The results of examination chest X-ray and complete blood count of patients was shown normal results. Masashi reported 17 cases of laryngeal TB obtained 94.1% of patients with lung abnormalities in the picture on a chest X-ray images and 5.9% with normal lung.⁹ Chen reported 26 cases of laryngeal TB with a picture of abnormalities in the lungs by 92.3% and 7.2% without abnormalities image.¹⁰ Examinations abnormalities in chest X-ray and complete blood count is done to evaluate the possible involvement of pulmonary tuberculosis infection.

An overview of histopathology in these patients was primary laryngeal TB thus granulation tissue without epithelial lining with proliferation of capillary blood vessels and mononuclear inflammatory cell infiltrates, including group of epithelioid cells that arranged to form granulomas and multinucleated giant cell.² Histopathology results of this cases needs to be distinguished from other disease such as sarcoidosis, leprosy infection, granuloma Wegener and Rhinoskleroma.¹¹ Histopathology biopsy lesions of the larynx was suspected as primary laryngeal TB infection that could be performed to enforce diagnosis.⁷

PCR results in this patient was positive for TB. The confirmation of the diagnosis by PCR method has advantages with high sensitivity and specificity that

better than direct microscopy examination. It was also differentiate between DNA strains of MTB with non-tuberculosis Mycobacterium such as Mycobacterium kansasii, Mycobacterium leprae and Mycobacterium fortuitum.¹ PCR that detected TB bacteria could be considered a better way to diagnosis.¹²

The primary laryngeal of TB treatment guidelines in accordance literature was divided into intensive phase for 2 to 3 months and a continuation phase lasts 4 to 7 months.¹ The patients were given anti-TB therapy that in accordance with the literature. The complaints and mass ToF B on the vocal cords no longer found in this patients.

CONCLUSION

It has been reported a rare case of primary laryngeal TB diagnosed with histopathology and PCR on a man 21 years old. Anti tuberculosis drugs was given for six month and showed good result. Six months post treatment evaluation corresponding primary laryngeal tuberculosis treatment guidelines showed resolution of the symptoms and no masses on the vocal cords.

Funding: No funding sources

Conflict of interest: None declared

Ethical approval: Not required

REFERENCES

1. Marian VD, Gandhi A, Newlands SD. Rheumatologic, granulomatous, and other systemic diseases affecting the head and neck. In: Bailey BJ, Johnson JT, Newlands SD, eds. *Bailey's head and neck surgery - otolaryngology*. 15th ed. Vol. One. Philadelphia: Lippincott Williams & Wilkins; 2014: 284-286.
2. Nerurkar NK, Kapre G. Granulomatous diseases of the larynx. In: Kirtane MV, Souza CE, eds. *Laryngology*. 1st ed. Delhi: Thieme; 2014: 202-207.
3. Altman KW, Koufman JA. Laryngopharyngeal reflux and laryngeal infections and manifestations of systemic diseases. In: Snow JB, Wackym PA, eds. *Ballenger's otorhinolaryngology head and neck surgery*. 17th ed. Ontario: BC Decker Inc; 2009: 891.
4. Barbosa LC, Meirelles RC, Atberino CC, Femandes JR, Ferraz FR. Laryngo pharyngeal tuberculosis : case report. *Rev Bras Otorrinolaringol*. 2007;73(6):862-6.
5. Obourn C, Aynehchi B, Bentsianov B. Atypical presentation of laryngeal tuberculosis in a pediatric patient. *International Journal of Pediatric Otorhinolaryngology* 2012;76: 752-53
6. Buyan N, Das AK. Primary laryngeal tuberculosis: a rare cause of chronic laryngitis. *International journal of Advances in Medicine* 2014;1(3):278-81.
7. Cruz S, Ribeiro A, Trigueiros N, Rodrigues MR. Laryngeal tuberculosis: a diagnosis not to be

- overlooked. *Eur Ann Otorhinolaryngol Head Neck Dis.* 2014;131:325-6.
8. Lim JY, Kim KM, Choi EC, Kim YH, Kim HS, Choi HS. Current clinical propensity of laryngeal tuberculosis: review of 60 cases. *Eur Arch Otorhinolaryngol.* 2005;263:838-42.
 9. Kurokawa M, Nibu K, Ichimura K, Nishino H. Laryngeal tuberculosis: a report of 17 cases. *Auris Nasus Larynx.* 2015;42(4):305-10.
 10. Wang WC, Chen JY, Chen YK, Lin LM. Tuberculosis of the head and neck : a review of 20 cases. *Oral Surg Oral Med Oral Pathol Oral Radiol Endod.* 2009;107:381-6.
 11. Dunlap NE, Bass J, Fujiwara P, Hopewell P, Horsburgh CR, Salfinger M, et al. Diagnostic standards and classification of tuberculosis in adult and children. *Am J Respir Crit Care Med.* 2000;161:1376-95.
 12. Hope AJ, McMullen CP, Bagwell K. Granulomatous diseases of head and neck in adults. In: Kountakis SE, ed. *Encyclopedia of otolaryngology head and neck surgery.* 1st ed. Vol. One. Berlin: Springer; 2013: 1037-1038.

Cite this article as: Brahmono A, Purnami N, Yusuf M. Primary laryngeal tuberculosis. *Int J Otorhinolaryngol Head Neck Surg* 2019;5:777-80.

Primary Laryngeal Tuberculosis

ORIGINALITY REPORT

13%

SIMILARITY INDEX

10%

INTERNET SOURCES

11%

PUBLICATIONS

0%

STUDENT PAPERS

PRIMARY SOURCES

1	pdfs.semanticscholar.org Internet Source	3%
2	www.sci-rep.com Internet Source	2%
3	docplayer.net Internet Source	1%
4	www.bgsaims.edu.in Internet Source	1%
5	www.theallergycourse.com Internet Source	1%
6	www.cureus.com Internet Source	1%
7	"Aging Voice", Springer Science and Business Media LLC, 2017 Publication	1%
8	www.mdpi.com Internet Source	1%
9	www.unboundmedicine.com Internet Source	1%

10

Santosh Kumar Swain, Ishwar Chandra Behera, Mahesh Chandra Sahu. "Primary Laryngeal Tuberculosis: Our Experiences at a Tertiary Care Teaching Hospital in Eastern India", Journal of Voice, 2019

Publication

<1 %

11

Surinder K. Jindal, Aditya Jindal, Ritesh Agarwal. "Upper Respiratory Tract Tuberculosis", American Society for Microbiology, 2017

Publication

<1 %

12

S. Cruz, A. Ribeiro, N. Trigueiros, M. Rodrigues e Rodrigues. "Laryngeal tuberculosis: A diagnosis not to be overlooked", European Annals of Otorhinolaryngology, Head and Neck Diseases, 2014

Publication

<1 %

13

www.info.gov.hk

Internet Source

<1 %

14

Nina Zidar, Nina Gale, Antonio Cardesa, Luis Ortega. "Chapter 7 Larynx and Hypopharynx", Springer Science and Business Media LLC, 2016

Publication

<1 %

Exclude bibliography On

Primary Laryngeal Tuberculosis

GRADEMARK REPORT

FINAL GRADE

/100

GENERAL COMMENTS

Instructor

PAGE 1

PAGE 2

PAGE 3

PAGE 4
