

# Polymerase chain reaction and serology test to detect rubella virus in congenital rubella syndrome patients with hearing loss

*by* Sabrina Izzattisselim

---

**Submission date:** 10-Mar-2021 12:23PM (UTC+0800)

**Submission ID:** 1529021866

**File name:** us\_in\_congenital\_rubella\_syndrome\_patients\_with\_hearing\_loss.pdf (561.58K)

**Word count:** 4823

**Character count:** 26304

# Indonesian Journal of Tropical and Infectious Disease

Vol. 8 No. 1 January-April 2020

## Case Report

### Polymerase Chain Reaction and Serology Test to Detect Rubella Virus in Congenital Rubella Syndrome Patients with Hearing Loss

Sabrina Izzattisselim, Nyilo Purnami

<sup>1</sup>Department of Otolaryngology Head and Neck Surgery, Faculty of Medicine, Universitas Airlangga, 60132  
St. Mayjen. Prof. Dr. Moestopo 47, Surabaya Indonesia

<sup>2</sup>Dr. Soetomo General Hospital, 60286 St. Mayjen Prof. Dr. Moestopo 6-8, Airlangga, Gubeng, Surabaya Indonesia

Received: 22<sup>nd</sup> January 2016; Revised: 22<sup>nd</sup> February 2016; Accepted 23<sup>rd</sup> February 2016

#### ABSTRACT

Rubella infections in pregnant women, especially during the first trimester, often lead to manifest as congenital rubella syndrome (CRS). This syndrome consists of several inherited disorders such as deafness, cataracts, and cardiac abnormalities. Deafness is the most common manifestation of CRS, 70-90% of all cases with deafness type are sensory neural deafness. The mechanism of hearing loss due to rubella virus is caused by hypoxia resulting from endothelial vascular damage in cochlea, followed by cell death in the organ of Corti and stria vascularis. Cochlea's stria damage makes alterations in the composition of endolymph. This study aimed to confirm rubella infection using PCR and serological tests in patients with CRS who were clinically deaf. A suspected CRS reported was a 2-month-old patient with an unclear response to surround sound. The patient had been already diagnosed with congenital cataracts before. Prenatal, perinatal and postnatal history was evaluated. Hearing screening was done by OAE (Biological), and AABR (Beraphone). Anti-rubella IgM and IgG was obtained from blood serum. PCR was carried out from a throat swab and the eye-lens specimen. OAE and AABR results 'refer' to both sides of the ear indicated a sensorineural hearing loss. The serological examination of IgM was positive with an index of 15.00 and IgG rubella positive with a titer > 500 IU / ml. Positive results from the rubella virus were identified from the throat swab and lens specimens using the PCR method. Detection of rubella virus in CRS sufferers with clinical deafness of both ears gives positive results using PCR and serology methods. In the future PCR can be potential for prenatal diagnosis of rubella virus aimed at the provision of early prevention.

**Keywords:** Congenital rubella syndrome, hearing loss, OAE, AABR, serology test.

#### ABSTRAK

Infeksi rubela di trimester pertama kehamilan sering menyebabkan bayi yang dilahirkan dapat mengalami sindrom rubela kongenital (CRS). CRS adalah suatu sindrom yang terdiri dari beberapa kelainan bawaan seperti ketulian, katarak, dan kelainan jantung. Ketulian adalah manifestasi yang paling umum dalam kasus CRS dan 70-90% menderita ketulian tipe sensorineural. Mekanisme gangguan pendengaran akibat virus rubela dapat diakibatkan hipoksia, yang terjadi saat kerusakan endotel di koklea, yang diikuti oleh kematian sel di organ Corti dan stria vaskularis. Kerusakan stria vaskularis akan mengakibatkan perubahan komposisi endolimfe. Tujuan dari penelitian ini adalah untuk mengkonfirmasi infeksi virus rubela menggunakan metode PCR dan tes serologi pada pasien CRS yang secara klinis didapatkan ketulian. Dilaporkan sebuah kasus curiga CRS, bayi berusia 2 bulan dengan respons terhadap suara sekitar yang tidak jelas. Pasien sebelumnya telah di diagnosa menderita katarak. Riwayat prenatal, perinatal dan postnatal di evaluasi. Skrining pendengaran dilakukan dengan tes OAE (Biologis), dan AABR (Beraphone). IgM dan IgG anti rubella diperoleh dari serum darah. PCR dilakukan dari spesimen usap tenggorok dan lensa mata. Hasil OAE dan AABR refer pada kedua sisi telinga menunjukkan terdapat gangguan pendengaran tipe sensorineural pada pasien. Pemeriksaan serologi didapatkan hasil IgM positif dengan indeks 15,00 dan

Corresponding Author.  
E-mail: nyilopurnami@gmail.com

IgG rubella positif dengan titer >500 IU/ml. Hasil positif dari virus rubella yang diidentifikasi dari throat swab dan spesimen lensa menggunakan metode PCR. Deteksi virus rubella pada penderita CRS dengan klinis ketulian kedua telinga memberikan hasil positif dengan menggunakan metode PCR dan serologi. Di masa depan PCR dapat berpotensi untuk diagnosis prenatal dari virus rubella yang bertujuan sebagai pencegahan dini.

**Kata kunci:** Sindrom rubella kongenital, gangguan pendengaran, OAE, AABR, tes serologi.

**How to Cite:** Izzattisselim, Sabrina. Pumami, Nyilo. Polymerase Chain Reaction and Serology Test to Detect Rubella Virus in Congenital Rubella Syndrome Patients with Hearing Loss. Indonesian Journal of Tropical and Infectious Disease, [S.l.], v.8, n.1, p.182-189, jan. 2020. ISSN 2085-1103. Available at: <https://ejournal.unair.ac.id/IJTID/article/view/8735>. Date accessed: 09 dec. 2019. doi: <http://dx.doi.org/10.20474/ijttd.v8i1.8735>.

## INTRODUCTION

Rubella is a viral disease that possibly affects children and adults. Rubella infections in children only cause a few complaints or no symptoms. In adulthood, rubella is a self-limiting disease that is transmitted by aerosol. It often causes fever, headache, weakness, and conjunctivitis. Rubella infections in pregnant women, especially during the first trimester, often lead to manifest as congenital rubella syndrome (CRS).<sup>1</sup>

Congenital rubella syndrome consists of several congenital abnormalities such as deafness, cataracts, and cardiac abnormalities. Deafness is the most common manifestation of CRS. As much as 70-90% of all cases are with the deafness type of sensory neural deafness. Other manifestations that can be found are eye disorders such as cataracts, cardiovascular disorders, and mental retardation. This disorder imposes a burden on the family and also for the social and economic condition of a country, especially the developing one.<sup>1,2</sup>

Hearing loss in CRS can be caused by the failure of the development of auditory system. Abnormalities may be present in the cochlea (inner ear), N. VIII or the next auditory pathway. The Joint Committee on Infant Hearing (JCIH) recommends the identification of high-risk infants, including those with intrauterine infections such as TORCH (Toxoplasma, Rubella, Cytomegalovirus, and Herpes), running for a screening of hearing and performing a follow-up audiology evaluation until a definitive diagnosis is established. The gold standard for recommended hearing screening includes otoacoustic emission

(OAE) and automated auditory brainstem response (AABR). Early intervention in hearing loss results in better speech and language skills. Early treatment should be done under the age of 6 months because it will provide optimal results.<sup>3,4</sup>

The national target of Indonesia in 2020 is the control of rubella/CRS that can be achieved with a good surveillance system and reporting of surveillance results. Routine surveillance for CRS focuses on identifying infants less than one year of age. The classification of cases for CRS surveillance purposes based on clinical criteria and laboratory data. Rubella virus infection is routinely diagnosed with rapid and practical serological methods. Virus isolation can also be confirmed by examination of throat swabs and other body fluids.<sup>2,5,6</sup>

A case of CRS was reported in a 2-month-old infant with clinical manifestations of hearing loss, congenital cataracts, and growth disorders. Hearing screening and serological examination of virus isolation from the throat swab and eye-lens specimens have been performed.

## CASE STUDY

A 2-month-old baby referred from a pediatrician to audiology clinic, with suspicion of CRS and microcephaly. Heteroanamnesis was taken from her parents. The mother had a history of fever accompanied by a reddish rash throughout the body during first-trimester pregnancy. Her parents found an unclear response of this patient to surround sound. The patient's right eye appeared cloudy white at the age of 2 months.

At first, the patient was sent to the eye clinic and diagnosed with congenital cataracts. The patient had also performed a blood serology test with a positive result of rubella infection. There was no cardiac abnormality in the patient.

Heteroanamnesis of prenatal history revealed that the mother never had TORCH examination before and during pregnancy. She never received rubella immunization before, also any history of other diseases during pregnancy. Heteroanamnesis of neonatal history revealed that the baby was delivered by caesarian section at 38 weeks gestation with 1900 grams birth weight. The baby was born crying directly, with no asphyxia or no history of respiratory support. Heteroanamnesis of postnatal history showed that the patient was never severely ill until 2 months old, never had a fever accompanied by rash, no history of surgery, and no history of long-term drug use. Motoric development of the patient at 2 months old showed that the patient's hands and feet movement was active. Family history with birth abnormalities was not obtained.

Physical examination of the external ear was normal. Nose and throat examination showed no abnormalities. The patient's right eye was found cloudy. There was no impression of cyanosis on peripheral extremities.

Otoacoustic emission (OAE) examination was conducted when the patient was 2 months old as an initial screening of hearing. The results were 'pass' on the right ear and 'refer' on the left ear. The hearing was retested on 3 months old with OAE result remained 'refer' at one side of the ear. AABR examination results obtained 'refer' to both sides of the ear. The hearing re-examination was scheduled before 6 months old to find the definitive diagnosis of hearing loss and to prepare for further early interventions, such as hearing aids and speech therapy. The patient's speech development in 8 months old was still in the cooing stage, could not imitate sound in one syllable. Response to the surrounding sound was still unclear.

Echocardiography examination was performed when the child was 2 months old, and the result was within normal limits. This patient underwent the first cataract surgery at 3 months old. The right

eye-lens specimen was sent to the laboratory and polymerase chain reaction (PCR) was performed. The first blood serologic examination was performed in this patient at 2 months old. There was positive immunoglobulin M (IgM) result with index 15.00 and positive immunoglobulin G (IgG) rubella with a titer >500 IU/ml. A second blood serologic examination was performed when the patient was 6 months old. There was positive IgM result with the index of 1.27 and positive IgG rubella with a titer > 500 IU/mL.

A throat swab examination was performed at 2 months old and the specimen was sent to the laboratory for rubella virus isolation. Specimens were taken using a cotton swab to rub the throat (between the tonsils and the back of the uvula). The end of the cotton swab was should be prevented from touching the lips, tongue, uvula, and teeth. Cotton swabs were fed into the virus transport medium, thin and the ends were cut to the height of the tube. Virus transport media should be stored at a temperature of 2-8°C (maximum for 24 hours) when the media are transported to the laboratory for examination because the virus is sensitive to high temperatures. Thereafter, the specimen was stored at -70°C. The sample should not be stored at -20°C because clotting and thawing will affect the stability of antibodies and viruses.

Rubella virus isolation from the swab throat material was performed by breeding specimens in Vero cell or SLAM (signaling lymphocyte-activation molecule) monolayer cells. This specimen was inoculated and incubated at 35°C for 3-5 days. Monoclonal antibodies will detect the presence of the rubella E1 glycoprotein in the infected Vero cell. PCR examination was performed with a positive result of the rubella virus from a throat swab and the eye-lens specimen.

## RESULTS AND DISCUSSION

The patient was referred to the Audiology Clinic, Dr. Soetomo Hospital, with suspicion of CRS. Previous clinical manifestations were congenital cataracts and microcephaly. In hetero



anamnesis, there was no history of asphyxia. Motoric development was evaluated at the age of 8 months, showing the ability to prone. The response to the surrounding sound was unclear so that the diagnosis of hearing loss should be immediately obtained. Hearing loss is the most common clinical manifestation in CRS of about 70% to 90%. It can occur unilaterally or bilaterally and most often in the form of sensory-neural deafness as much 58%.<sup>7,8,9</sup>

Hearing screening has been performed when the patient came at 2 months old. Physical examination of the ear found no abnormalities in the auricle, the external acoustic meatus, and the tympanic membrane. The first OAE result was 'pass' on the right ear and 'refer' on the left ear. Re-examination in age 3 months using OAE still showed the same result for the 'refer' side. By using AABR, both ear showed 'refer' result. The gold standard for hearing screening recommended by JCIH included OAE and AABR. Otoacoustic emission was an acoustic product of the movement of cochlear outer hair cells that produces a spontaneous emission, which can be recorded through a microphone in the ear canal, detected when the cochlea and middle ear are functioning normally or nearly normal but do not measure the overall hearing function. It is only as indicators of peripheral hearing function.<sup>10,11</sup> Automated Auditory Brainstem Response (AABR) is an objective, easy, practical, non-invasive and fast auditory electrophysiology of an auditory system of about 5 to 10 minutes. It does not require evoked potential waveform analysis because the recording is very easy to read, only based on a 'pass' or 'refer' criteria. By using a limited stimulus intensity, which was 35 dB and presented monoaurally. The drawback of this system was unable to determine the threshold of hearing and need to proceed with ABR diagnostic.<sup>12,13</sup>

A two-stage screening was performed in this case because the initial OAE examination result did not 'pass'. On the second examination OAE result was also 'refer'. AABR confirmation remained 'refer'. The result of the hearing test at that time lead to a conclusion that there was hearing impairment in the patient. The

two-stage screening protocol aims to minimize false-positive events. The two-stage test protocol was the OAE followed by repetitive AABR.<sup>4</sup> 'Pass' results on OAE tests did not always show a normal hearing sensitivity but excluded severe hearing loss because OAE examinations did not access retrocochlear function.<sup>10,11</sup> The results did not always indicate the loss of hearing, so the examination must be continued as it might have indicated a sensorineural hearing loss.<sup>10,11</sup> AABR test was quite sensitive with a quite low false positive incidence of around 1.9% to 2%.<sup>12,13</sup>

There were no external and middle ear abnormalities found in the patient because the rubella virus mainly affected the inner ear. While the mechanism of rubella-induced hearing loss has not been fully explained, the virus has been recognized to cause direct cochlear damage and cell death in the organ of Corti and stria vascularis.<sup>14</sup> Alterations in the composition of endolymph due to cochlea's stria damage have also been described. Depending on the severity of hearing loss, treatment options include the use of hearing aids and cochlear implantation.<sup>15</sup> The mechanism of hearing loss due to the rubella virus is probably caused by hypoxia due to endothelial vascular damage. Damaged endothelium can act as a source of embolism and lead to thrombosis in small blood vessels. Damage to the intima layer also occurs in large and medium systemic arteries. The virus causes cochlear damage and cell death from organ of Corti as well as stria vascularis. Changes in cochlea's endolymph composition due to stria vascularis damage were also reported in several studies.<sup>7,8,9</sup>

Patients with hearing loss should be obtained enable for hearing before 6 months old because children learn to speak based on what they hear. The critical period of hearing and speech development in children begins in the first 6 months of life and continues until 2 years old.<sup>16</sup> Normal development of speech and language is shown in Table 1.

The development of speech in this 8-month old patient can be regarded as in delayed category because of she was just able to cooing. There was a delay in hearing ability in this case because the patient had not come for an ABR diagnostic

**Table 1.** The Development of Speech and Language in Children.<sup>16</sup>

Age	Receptive	Expressive
6 months old	Turning to the rattling sound. Turns to voice.	Laughing. Speaks a snoring sound like a bird ( <i>cooing</i> ).
9 months old		Laugh and babble meaninglessly ( <i>babbling</i> ), make a syllable sound. A meaningful babble ( <i>true babbling</i> ), Such as “pa...pa, da...da”. Say greetings.

scheduled before the patient was 6 months old. The factor of delay may result from a lack of awareness of the parents on the impact of hearing loss. The common reason is related to the multiple problems in CRS that provided a high burden to the family. The eye problem and other clinical manifestations of CRS might look more prevalent to the parents compared to hearing problem. This patient did not suffer from cardiac abnormalities as confirmed with normal result of echocardiography examination when the patient was 2 months old. This examination considered major abnormalities in CRS, cataract and cardiac problems, except on hearing disorders.<sup>17</sup> The patient had congenital cataracts on the right eye and had surgery twice at 3 and 8 months. This problem was likely the reason behind delayed definitive diagnosis of hearing loss using ABR diagnostic to identify the severity of hearing loss.

The patient's mother had a fever accompanied by a rash during the early trimester of pregnancy so that the patient was likely infected with the rubella virus at the time when an organogenesis disorder occurred. The patient's mother also never got a rubella vaccine during pregnancy. Rubella virus causes the deficiency of cell formation, affecting the disorder of organ formation. The viruses penetrate the placenta and reach the fetal blood circulation. This placental damage causes necrosis in the epithelium of chorionic villi and capillary endothelial cells. Endothelial cells will experience desquamation into the lumen of blood vessels, then the virus is transported into fetal circulation in the form of endothelial cells infected with the rubella virus. Infected endothelial cells can lead to blockage of small blood vessels as well as infections and damage to various fetal organs.<sup>1,17,18</sup>

The initial diagnosis of the patient was clinical CRS because it met two clinical symptoms of group A and group B. Clinical symptoms of group A were congenital cataract and hearing loss, while clinical symptoms of group B were microcephaly and developmental delays. Classification of cases for CRS surveillance purposes was based on clinical, and laboratory symptoms.<sup>2,6</sup> Clinical Criteria of CRS includes at least two clinical symptoms of group A or one and at least one clinical symptom of group B (Table 2).

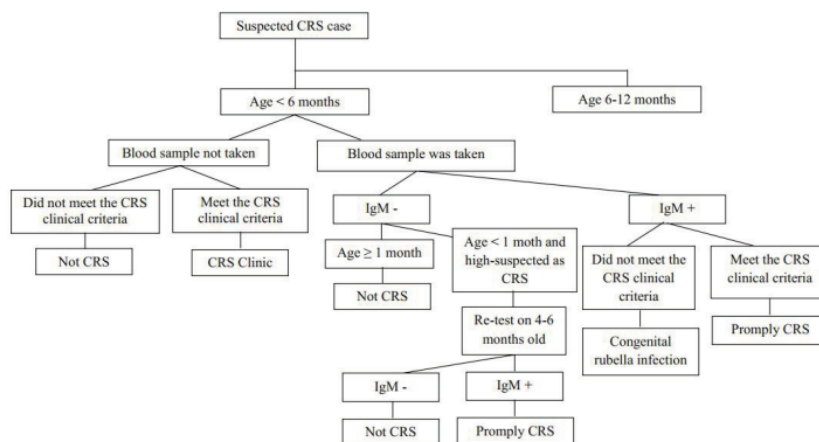
Management of suspicious cases of CRS should be consistent with WHO-defined algorithms based on age groups for less than 6 months (Figure 1) and between 6 and 12 months. The patients in this case was with clinical CRS, so we took her blood samples for confirmation of CRS.

Management of suspicious CRS patients includes specimen taking, recording, and reporting for surveillance purposes. Investigations in CRS cases were broadly divided into serological tests, virus isolation, and viral RNA examination.<sup>9,19,20</sup> Examination materials to determine the presence of rubella virus infection can be taken from throat, blood, urine, and saliva (Table 3).

In this case, the result of examination showed positive IgM rubella test with index 15,00 and positive IgG rubella with a titer >500 IU/ml at age 2 months. When patients turned to age 6 months, she still showed positive IgM results with an index of 1.27 and positive IgG rubella with a titer >500 IU/ml. Blood specimen in the patient was taken as much as 3 ml to obtain 1 ml of serum for serology. Serum specimen was initially taken from the infant when he/she was less than one month old. The second serum specimen was taken at the age of four to six months from which the first results showed negative IgM rubella. Blood

**Table 2.** Clinical Symptoms of CRS.<sup>6</sup>

Clinical Symptoms of Group A	Clinical Symptoms of Group AB
Congenital heart defects	<i>Purpura</i>
Congenital cataract	Microcephaly
Congenital glaucoma	<i>Meningoencephalitis</i>
Retinopathy pigmentosa	24-hour postpartum jaundice
Hearing disorders	<i>Splenomegaly</i>
	Developmental delays
	Round shape bone disease



**Figure 1.** CRS Case Algorithm Age Less Than 6 Months.<sup>6</sup>

**Table 3.** Methods of Specimen Examination to Determine CRS.<sup>19</sup>

No.	Examination type	Specimen types
1.	Virus isolation	Nasopharyngeal graft, urine, saliva, cerebrospinal fluid
2.	Serology	Fetal blood through cordosynthesis, saliva
3.	RNA Virus	Fetal amniotic fluid through amniocentesis, choreal villi, blood, saliva

specimen in children aged six to twelve months with negative IgM results was then collected on a second serum specimen for IgG examination at the age of eight to twelve months. Serologic examination of the patient's blood specimen will detect IgM and IgG rubella at least twice in the age range 6 to 12 months without any rubella vaccine.<sup>6,19,20</sup>

The definition of suspicious case of CRS is an infant with more than one clinical symptom of group A and no other obvious cause or the mother has a history of suspected rubella or rubella during pregnancy whether the baby has symptoms or not.<sup>6</sup> The patient with suspicious CRS in this case had met the CRS clinical criteria and then her blood specimen was taken for serologic examination in accordance with the existing algorithm. Positive IgM results classified the patient into CRS confirmed category. The rubella virus can be detected as much as 60% in infants aged 1-4 months, 30% in 5-8 months, and 10% in 9-11 months.<sup>19,20</sup> The patient's parent should be educated about this evidence because the baby could spread the virus until the age of one year and become the source of rubella outbreak.

Additional serological examination and isolation of the rubella virus from throat swab was



performed when the patient was still two months old. The specimen were sent to a laboratory with virus transport medium at a temperature of 2 to 8°C. Rubella virus isolation was an examination of the confirmation of CRS and the characterization of the rubella virus is required for epidemiological and surveillance purposes. Samples used for viral isolation should be taken simultaneously with the samples used in serological tests. This virus reproduces in the respiratory tract mucosa and surrounding lymph nodes. In this case, the rubella virus had been found to have reproduced as confirmed from swab throat on Vero cell with a positive result of rubella virus, which was followed by immunofluorescence assay (IFA) method. However, in IFA method, the rubella-infected Vero cells were stained green. The background reading should have not been stained green since excessive fluorescence makes the reading difficult. The recommended methods for detecting rubella E1 glycoprotein in infected Vero cells are the monoclonal antibody plus IFA or immunometric examination.<sup>19,20</sup>

Detection of rubella virus with reverse transcription (RT-PCR) or rubella virus isolation should be performed to a suitable clinical sample. Reverse transcription followed by PCR amplification (RT-PCR) is a fast, sensitive and specific rubella RNA virus detection technique. The primer used comes from the glycoprotein E1. The product after PCR amplification is performed by using conventional gel electrophoresis and can also be read in real-time. The main role of the RT-PCR examination was to investigate the genetic characteristics of rubella virus and to detect genomic variation in different regions of the world. Inactive virus particles can also be detected by RT-PCR so that sampling time is longer. The disadvantage of this examination is the need for standardized laboratories and skilled personnel to perform the examination because of the risk of cross-contamination that can cause serious problems.<sup>19,20</sup> In this case PCR examination was performed with a positive result of rubella virus from a throat swab and the eye lens specimen. PCR using amniotic fluid has the potential for prenatal diagnosis. This procedure has limited availability on the national work program for

CRS surveillance. RT-PCR examination was important because the patient still had positive IgM rubella until 8 months old and could be the source of rubella transmission.

## CONCLUSION

A CRS case in a 2-month-old girl with clinical and audiology manifestations of deafness, congenital cataract, and growth disorders is reported. Serological examination and PCR RNA virus revealed positive results. In the future, there is potential use PCR for prenatal diagnosis of rubella that aims to early prevention.

## ACKNOWLEDGEMENTS

Authors are grateful to the respondents and all those who helped complete this research.

## CONFLICT OF INTEREST

There was no conflict of interest.

## REFERENCE

1. McLean HQ, Fiebelkorn AP, Temte JL, Wallace GS. Prevention of measles, rubella, congenital rubella syndrome, and mumps, 2013. *MMWR Recomm Rep*. 2013 Jun; 62(4):1–34. Available from: <https://www.cdc.gov/mmwr/pdf/rr/tr6204.pdf>
2. World Health Organization. Strategic plan for Measles Elimination and Rubella and Congenital Rubella Syndrome Control in the South-East Asia Region. 2020. Available from: [http://apps.searo.who.int/PDS\\_DOCS/B5206.pdf](http://apps.searo.who.int/PDS_DOCS/B5206.pdf)
3. HTA Indonesia. Skrining pendengaran pada bayi baru lahir. Dalam: Kelompok studi THT Komunitas PERHATI-KL (Suwento R, Zizlavsky S, Airlangga T, Suardana W, Anggraeni R, Purnami N, dkk., eds). *Skrining pendengaran pada bayi baru lahir. DITJEN YANMEDIK SPESIALITIK DEPKES RI 2006, Edisi Revisi 2010*. Jakarta: Kementerian Kesehatan RI. hal.1-36.
4. Joint committee on infant hearing. Year 2007 Position Statement : Principles and Guidelines for Early Hearing Detection and Intervention Programs. 2007;898–921.
5. Kementerian Kesehatan Republik Indonesia. Pengendalian rubela melalui surveilans rubela dilaksanakan secara terintegrasi dengan surveilans



- campak. [Internet]. 2015 [cited 2017 Feb 10]. Available from: <http://www.depkes.go.id/article/print/15112700004/pengendalian-rubela-melalui-surveilans-rubela-dilaksanakan-secara-terintegrasi-dengan-surveilans-cam.html>
6. Orenstein WA, Caims L, Hinman A, Nkowane B, Olivé J, Reingold AL. Measles and Rubella Global Strategic Plan 2012 – 2020 midterm review report : Background and summary q. *Vaccine*. 2020;36(2018):A35–42. Available form: DOI 10.1016/j.vaccine.2017.10.065
  7. Report C, Nugroho DA. Tuli kongenital diduga akibat infeksi rubela dan sitomegalovirus. *Medica Hosp*. 2014;2(2):130–6. Available from: <https://doi.org/10.36408/mhjcm.v2i2.106>
  8. Carøça C, Vicente V, Campelo P, Chasqueira M, Caria H, Silva S, et al. Rubella in Sub-Saharan Africa and sensorineural hearing loss : a case control study. 2017;1–7. Available from: DOI 10.1186/s12889-017-4077-2
  9. Adam O, Ali AKM, Hübschen JM, Muller CP. Identification of congenital rubella syndrome in Sudan. 2014;(September 2010):1–5. Available from: DOI 10.1186/1471-2334-14-305
  10. Suwento R, Zizlavsky S, Hendarmin H. Gangguan pendengaran pada bayi dan anak. Dalam: Soepardi EA, Iskandar N, Bashiruddin J, Restuti RD, eds. *Buku ajar ilmu kesehatan telinga hidung tenggorok kepala dan leher*. Edisi 7. Jakarta: Fakultas Kedokteran UI; 2012. hal.30-35.
  11. White KR. Newborn hearing screening. In: Ketz J, Chasin M, English K, Hood LJ, Tillery KL, eds. *Handbook of clinical audiology*. 7<sup>th</sup> ed. Philadelphia: Wolters Kluwer health; 2015. p.437-458.
  12. Stewart DL, Mehl A, Iii JWH, Thomson V, Carroll M. Infant Hearing Impairment and Universal Hearing Screening. 2000;127–30. Available from: DOI 10.1038/sj.jp.7200449
  13. Gibbin KP. Management of the deaf children. In: Graham JM, Scadding GK, Bull PD, eds. *Pediatric ENT*. New York: Springer-Verlag Berlin Heidelberg; 2007;327-336. Available from: <https://www.springer.com/gp/book/9783540699309#aboutBook>
  14. Lee J, Bowden DS. Rubella Virus Replication and Links to Teratogenicity. 2000;13(4):571-87. Available from DOI: 10.1128/cmr.13.4.571-587.2000
  15. Smith RJH, Jr JFB, White KR. Sensorineural hearing loss in children. *Lancet*. 2005; 365(9462):879–890. Available from DOI: 10.1016/S0140-6736(05)71047-3
  16. McLaughlin MR. Speech and language delay in children. *Am Fam Physician*. 2011; 83(10): 1183-1188. Available from: <https://www.aafp.org/afp/2011/0515/p1183.pdf>
  17. Martínez-Quintana E, Castillo-Solórzano C, Torner N, Rodríguez-González F. Congenital rubella syndrome : a matter of concern. *Rev Panam Salud Publica*. 2015 Mar; 37(3):179-186. Available from: <http://www.depkes.go.id/article/print/15112700004/pengendalian-rubela-melalui-surveilans-rubela-dilaksanakan-secara-terintegrasi-dengan-surveilans-cam.html>
  18. Singh S, Bingwor F, Tayler-smith K, Manzi M, Marks GB. Congenital Rubella Syndrome in Fiji , 1995 –2010. *J Trop Med*. 2013;1–5. Available from: DOI: 10.1155/2013/956234
  19. Mendelson E, Aboudy Y, Smetana Z, Tepperberg M, Grossman Z. Laboratory assessment and diagnosis of congenital viral infections : Rubella , cytomegalovirus ( CMV ), varicella-zoster virus ( VZV ), herpes simplex virus ( HSV ), parvovirus B19 and human immunodeficiency virus ( HIV ). *Reprod Toxicol*. 2006;21:350–82. Available from: DOI: 10.1016/j.reprotox.2006.02.001
  20. Darmadi S. Gejala Rubela Bawaan (Kongenital) Berdasarkan Pemeriksaan Serologis Dan Rna Virus ( Congenital Rubella Syndrome Based on Serologic and RNA Virus Examination). *J Clin Pathol Med Lab*. 2007;13:63–71. Available from: <http://www.journal.unair.ac.id/download-fullpapers-PDF%20Vol.%2013-02-06.pdf>

# Polymerase chain reaction and serology test to detect rubella virus in congenital rubella syndrome patients with hearing loss

## ORIGINALITY REPORT

11%

SIMILARITY INDEX

9%

INTERNET SOURCES

7%

PUBLICATIONS

0%

STUDENT PAPERS

## PRIMARY SOURCES

1	<a href="http://statperson.com">statperson.com</a> Internet Source	2%
2	<a href="http://repository.unair.ac.id">repository.unair.ac.id</a> Internet Source	2%
3	Elsa Rosalina, Nyilo Purnami. "Congenital Rubella Syndrome profile of audiology outpatient clinic in Surabaya, Indonesia", <i>Infectious Disease Reports</i> , 2020 Publication	1%
4	<a href="http://apps.who.int">apps.who.int</a> Internet Source	1%
5	Banatvala, J.. "Rubella", <i>The Lancet</i> , 20040403 Publication	<1%
6	<a href="http://www.labome.org">www.labome.org</a> Internet Source	<1%
7	<a href="http://pure.uva.nl">pure.uva.nl</a> Internet Source	<1%
8	<a href="http://www.lebpedsoc.org">www.lebpedsoc.org</a> Internet Source	<1%

<1 %

9

[www.usherbrooke.ca](http://www.usherbrooke.ca)

Internet Source

<1 %

10

[digitalcommons.usu.edu](http://digitalcommons.usu.edu)

Internet Source

<1 %

11

Konrad Konradsson, Magnus Jarvholm.  
"Introducing a national paediatric hearing  
register in Sweden", *Audiological Medicine*,  
2009

Publication

<1 %

12

"Textbook of Clinical Otolaryngology",  
Springer Science and Business Media LLC,  
2021

Publication

<1 %

13

Elise Bouthry, Olivier Picone, Ghada Hamdi,  
Liliane Grangeot-Keros, Jean-Marc Ayoubi,  
Christelle Vauloup-Fellous. "Rubella and  
pregnancy: diagnosis, management and  
outcomes", *Prenatal Diagnosis*, 2014

Publication

<1 %

14

[bmcpublikealth.biomedcentral.com](http://bmcpublikealth.biomedcentral.com)

Internet Source

<1 %

15

[www.heighpubs.org](http://www.heighpubs.org)

Internet Source

<1 %

16

[www.thieme-connect.com](http://www.thieme-connect.com)

Internet Source

<1 %

17

[www.wjgnet.com](http://www.wjgnet.com)

Internet Source

<1 %

18

"Dermatology in Public Health Environments",  
Springer Science and Business Media LLC,  
2018

Publication

<1 %

19

"Pediatric and Congenital Cardiology, Cardiac  
Surgery and Intensive Care", Springer Science  
and Business Media LLC, 2014

Publication

<1 %

20

Brandon E. Cohen, Anne Durstenfeld, Pamela  
C. Roehm. "Viral Causes of Hearing Loss: A  
Review for Hearing Health Professionals",  
Trends in Hearing, 2014

Publication

<1 %

21

[mafiadoc.com](http://mafiadoc.com)

Internet Source

<1 %

22

[www.aafp.org](http://www.aafp.org)

Internet Source

<1 %

Exclude quotes On

Exclude matches Off

Exclude bibliography On



# Polymerase chain reaction and serology test to detect rubella virus in congenital rubella syndrome patients with hearing loss

---

## GRADEMARK REPORT

---

FINAL GRADE

**/100**

GENERAL COMMENTS

**Instructor**

---

PAGE 1

---

PAGE 2

---

PAGE 3

---

PAGE 4

---

PAGE 5

---

PAGE 6

---

PAGE 7

---

PAGE 8

---