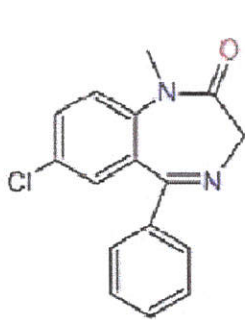


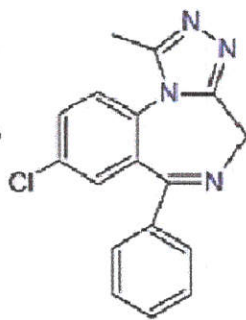


ANAESTHESIA, PAIN & INTENSIVE CARE

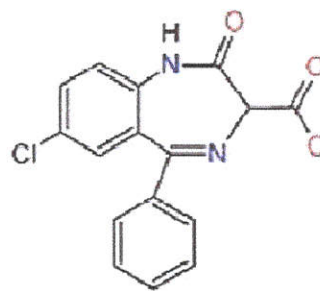
A Bimonthly International Journal of Anesthesiology,
Pain Management, Intensive Care & Resuscitation



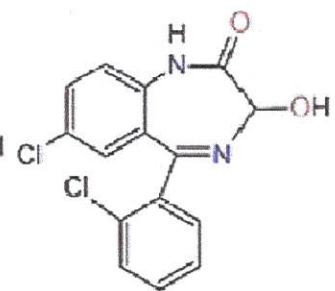
Diazepam



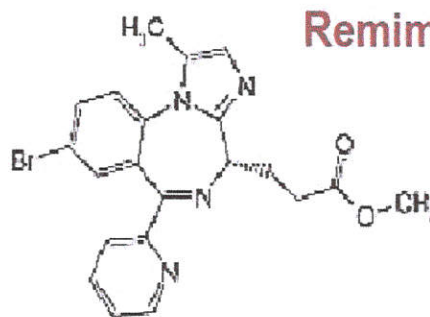
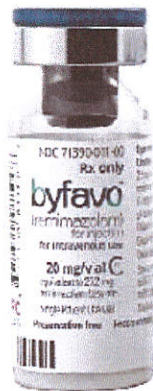Alprazolam



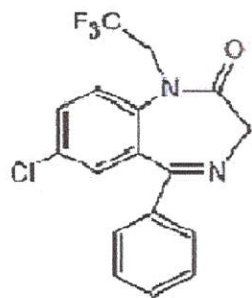
Clorazepate



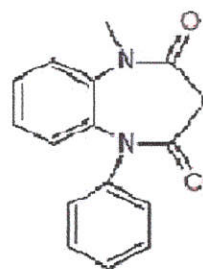
Lorazepam



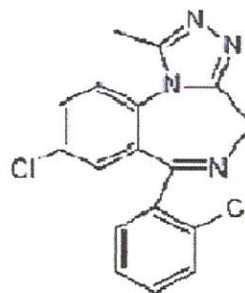
Remimazolam



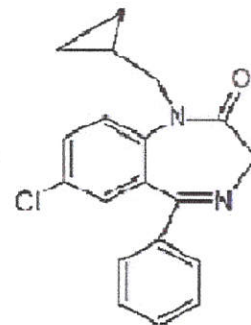
Halazepam



Clobazam



Triazolam



Prazepam



EDITORIAL VIEWS

Remimazolam besylate; overview of a novel benzodiazepine for general anesthesia

277-279

Yasuhiro Morimoto

[PDF](#)

[HTML](#)

OPINION

Does authors' biodata in clinical trials registry affect blind peer review process? For the consideration of medical journal editors

280-282

Tahir Mahmood

[PDF](#)

[HTML](#)

Tramadol vs. pethidine to control perioperative shivering in cesarean section under spinal anesthesia: a double-blind study

283-290

Ahmad Firdaus Yaakop, Mohamad Hasyizan Hassan, Sanihah CHE Omar, Mohd Zulfakar Mazlan, Laila Ab Mukmin, W. Nazaruddin W. Hassan



PDF



HTML

Effect of Pilates based exercises for improving pain and physical function in symptomatic knee osteoarthritis –a randomized controlled clinical trial

291-296

Nadia Saleem, MSOMPT, BSPT, Iqra Waseem, MSMSK, DPT, Farwah Batool, MSPTM, DPT., Tahir Mahmood, MSPTM, DPT, Wajeeha Mahmood, MSNMPT, PPDPT, BSPT



PDF



HTML

A comparative study between femoral nerve block and intravenous ketamine for pain management during positioning for spinal anesthesia in elderly patients with femur fracture

297-303

Mai Essam Mohamed Moussa, Hala Gomaa Salama Awad, Hatem Said Abdel Hamid, Ayman Elsayed Abdellatif, Amr Gaber Sayed Sharaf



PDF



HTML

The relationship between transformational leadership, job satisfaction, and organizational commitment in Jordanian nurses

Thaira Othman, MSN, Huthaifah Khrais, RN, MSN, PhD

304-309

[PDF](#) [HTML](#)

Erector spinae plane block vs. single shot epidural block for postoperative analgesia in lumbar spine surgery: a randomized controlled trial

Hebatallah Salah Abdelhamid, Hala Ahmed ElSabbagh, Shereen Mostafa Amin, Amr K. Abdelhakeem

310-317

[PDF](#) [HTML](#)

A randomized, controlled study to evaluate the effect of parenteral glutamine on the reduction of infection related morbidity in burn patients in ICU

Ashraf M. Eskandr, Hatem A. Attalla, Mona E. Massoud, Alaa-Eldin A. Aiad

318-325

[PDF](#) [HTML](#)

Comparison of normal saline and balanced salt solution as a maintenance fluid on acids-base and electrolyte status in traumatic brain injury patients; a prospective randomized double-blind study

Shephali ., Yashpal Singh, Manjaree Mishra, Sumit Sachan, Naman M. Pathak, Ravi Shankar

326-331

[PDF](#) [HTML](#)

Hyponatremia in elderly patients with fractures around the hip; role of glutamate (CSF glutamate study)

332-337

Hassan Ibraheem Kotb, MD, Alshymaa Hassan, MB BCh, Ayat A Sayed, MD, Mohamed Ismail Seddik, MD, Hatem H Maghraby, MD, Emad Zariief Kamel, MD

 PDF

 HTML

A comparison between propofol, dexmedetomidine and nitroglycerin as hypotensive agents and their effect on blood loss in functional endoscopic sinus surgery (FESS)

338-346

Sarah Abd El Razzak Mohammed Saleh, Hala Gomaa Salama Awad, Adel Mikhail Fahmy Shonoda, Mohammed Sayed El Shorbagy, Doaa Mohammed Kamal El Din

 PDF

 HTML

Intraperitoneal bupivacaine alone or with dexmedetomidine for post-operative analgesia following laparoscopic cholecystectomy: A prospective randomized comparative study

347-351

Shiv Shankar, Bikram Kumar Gupta, Madhup Kumar Singh, Arun Raj Pandey, Vandana Dwivedi, Sumit Sachan

 PDF

 HTML

Comparison of high dose fentanyl, magnesium and lidocaine for effective and consistent attenuation of hemodynamic responses during laryngoscopy and intubation

352-359

Walaa Y. Elsabeeny, MD, Nahla N. Shehab, MD

 HTML

 PDF

Impact of spontaneous vs. controlled ventilation with laryngeal mask airway in pediatric cataract surgery

360-367

Sameh M El-Sherbiny, MD, Amany H EL-Deeb, MSc, Walid M Gaafar, MD, Walid M Gaafar, Assistant Professor, Dep, Medhat Mikhail Messeha, MD



PDF



HTML

Threats to operating room personnel's occupational safety and health: a qualitative study

368-381

Mina Amiri Dore, Camellia Torabizadeh, Zahra Keshtkaran



PDF



HTML

A multinational online survey on the current perioperative practice for the management of patients with diabetes mellitus: a descriptive study

382-390

Tariq Hayat Khan, Habib Md Reazaul Karim, Apurb Sharma, Anuja U. Abayadeera, Md Rabiul Alam



PDF



HTML

SHORT COMMUNICATION

To blunt or not to blunt: Still an outlawed practice in peripheral nerve blocks?

391-393

B M Munasinghe, N. Subramaniam



PDF



HTML

NARRATIVE REVIEW

Current diagnosis and management of carpal tunnel syndrome: A review

394-404

Hanik Badriyah Hidayati, Imam Subadi, Fidiana Fidiana, Vania Ayu Puspamaniar

 PDF

 HTML

The role of platelet rich plasma in knee joint pain

405-409

Cempaka Thursina, Hanik Badriyah Hidayati, Yudiyanta Yudiyanta, Irfan Pranowo, Vania Ayu Puspamaniar

 PDF

 HTML

CASE SERIES

Pneumothorax in COVID-19 patients on non-invasive ventilation: a case series

410-415

Mahima Lakhanpal, Isha Yadav, Ankita Aggarwal, Ritesh Kumar

 PDF

 HTML

CASE REPORTS

Accidental extubation in a patient with Pierre-Robin syndrome: a case report

416-418

Karolina Czajkowska, Liuba Germanova, João Bettencourt

 PDF

 HTML

Neuraxial anesthesia for extended endoscopic urological procedure in a patient with MELAS syndrome: a case report

Muaweih Ababneh, Refaat Al- Shehab, Aiman Suleiman, Aiman Suleiman

419-422

 PDF

 HTML

CORRESPONDENCE

The impact of vaccination on stress level of trainee doctors during COVID-19 pandemic

Anwar ul Huda, Mohammad Yasir, Abdul Sattar Shamsuddin

423-424

 PDF

 HTML

HISTORY

Professor Rustam Ali Nabi - a pioneer in anesthesiology

Tahoor Manzar

425-426

 PDF

 HTML

Editorial Team

PATRON



Brig (Retd) M. Salim, SI (M), DA, FFARCS, FCPS, PhD
Professor of Anesthesiology & Pain Medicine
Founder member, Pakistan Society of Anesthesiologists (PSA)
Founder, Past President & Patron, Society for Treatment & Study of Pain (STSP®)
E-mail: brigsaleem1@gmail.com

EDITOR-IN-CHIEF



Tariq Hayat Khan, MBBS, DA, MCPS, FCPS
Consultant Anesthesiologist & Pain Specialist,
President, Pakistan Resuscitation Society (PARES)
Cell: +92-321-5149709
E-mail: apicarejournal@gmail.com

Senior Editor:



Fauzia Anis Khan, LRCP, MRCS, FRCA, MCPS, FCPS, (Pakistan)
Department of Anaesthesia, The Aga Khan University, Karachi
Ex-HoD/Interim Associate Dean, Postgraduate Medical Education, Aga Khan University, Karachi (Pakistan)
E-mail: fauzia.khan@aku.edu

Associate Editors



AKM Akhtar uz Zaman (Bangladesh)
Professor of Neuroanaesthesia,
Fellowship in Anaesthesia and Pain Medicine in Tokya (Japan).
E-mail: akm.akhtaruzzaman@bsmmu.edu.bd



Pranav Bansal, MBBS, MD (Anesthesiology) (India)
Professor & Head, Dept. of Anesthesiology
BPS Govt. Medical College, Khanpur Kalan, Sonapat, Haryana, (India)
E-mail: pranavbansal1@gmail.com



Logan Danielson, MD, MBA (USA)
Children's Hospital of Michigan, Detroit, MI
Research Assistant for Michigan Pediatric Surgical Associates, Detroit, MI (USA)
E-mail: logandanielson@gmail.com

ASSISTANT EDITORS



Muhammad Faisal Jafar, MBBS, MCPS, FCPS (Pak), FRCA (UK)
Consultant Anaesthetist, St John's Hospital, Livingston, Scotland
Address: 58c Gracemount Drive, Edinburgh, EH17 8DA (UK).
E-mail: faisaljafar@yahoo.com



Somaye Pouy

PhD Student of Nursing Education
Instructor at Guilan University of Medical Sciences, Rasht, Iran
Email: Somayepouy@gmail.com



Mishal Fatima, MBBS, FCPS (I) (Pakistan)

Department of Surgery,
Islamabad Medical Complex, Islamabad (Pakistan)
E-mail: mishalfati@gmail.com

STATISTICIAN

Shamail Alam

Punjab Institute of Cardiology, Lahore (Pakistan)
E-mail: shamailalam@gmail.com

EDITORIAL BOARD Members



Aliya Ahmed, FFARCSI (Pakistan)

Professor of Anaesthesiology
Director, Residency Programme in Anaesthesia, Agha Khan University Hospital Karachi (Pakistan).
E-mail: aliya.ahmed@aku.edu



Arshad Taqi, FCPS, (Pakistan)

Professor of Anesthesiology,
Hameed Latif Hospital & Medical College, Garden Town, Lahore
Consultant Anesthesiologist, Kaul Anesthesia Associates (Pvt) Ltd., Lahore (Pakistan)
E-mail: arshadtaqi@gmail.com

NARRATIVE REVIEW

PAIN MANAGEMENT

Current diagnosis and management of carpal tunnel syndrome: A review

Hanik Badriyah Hidayati¹, Imam Subadi², Fidiana¹, Vania Ayu Puspamaniar³

Author affiliation:

1. Hanik Badriyah Hidayati, ORCID: [0000-0002-6825-1311](https://orcid.org/0000-0002-6825-1311), Department of Neurology, Faculty of Medicine, Airlangga University – RSUD Dr. Soetomo, Surabaya, Indonesia.

2. Medical Rehabilitation Department, Faculty of Medicine Airlangga University – RSUD Dr. Soetomo, Surabaya, Indonesia; E-mail: isubadi@gmail.com.

3. Department of Neurology, Faculty of Medicine, Airlangga University – RSUD Dr. Soetomo, Surabaya, Indonesia; E-mail: fidiana@fk.unair.ac.id

4. Faculty of Medicine, Airlangga University – RSUD Dr. Soetomo, Surabaya, Indonesia; E-mail: miaayu49@yahoo.com

Correspondence: Hanik Badriyah Hidayati; E-mail: hanikhidayati@fk.unair.ac.id; Phone: +6282131035699

Abstract

Carpal tunnel syndrome (CTS) is a condition when median nerve, located in the carpal tunnel, is being suppressed by the surrounding structure. In 1854, the first clinical narration of median nerve compression in a carpal tunnel was found. CTS causes pain, tingling, and weakness in the half ring finger, middle finger, index finger, and thumb. These complaints lead the patients to seek medical help by a visiting doctor. CTS has become the major cause of upper extremity chronic neuropathic pain. CTS affects women 3.6 times more than men. This would cause high costs in medical treatment, rehabilitation, work hours lost compensation, initial pension costs, and new worker training. This makes CTS as a major problem in the field of employment. Carpal tunnel syndrome occurs as a result of chronic repetitive forceful work and other risk factors such as sex, age, heredity, hormonal, and weight. Knowledge of the diagnosis and comprehensive management of CTS are important to the doctor. Recent management based on the newest guidelines are important for clinician knowledge update. Correct diagnosis will lead to appropriate management based on recent CTS guidelines, which in turn will improve the quality of life for patients with CTS. This article will comprehensively discuss the diagnosis and recent management.

Abbreviations: CTS - Carpal tunnel syndrome; NHIS - National Health Interview Study; EDX - Electrodiagnostic studies; SCT - Scratch Collapse Test; CSA - Cross-sectional area; PRP - Platelet-rich plasma; LLLT - Low-Level Laser Therapy; US – Ultrasound; DN - Dry needling; ECTR - Endoscopic carpal tunnel release; PDI - perineural dextrose injection; BCTQ - Boston Carpal Tunnel Questionnaire

Key word: Carpal tunnel syndrome (CTS); neuropathy; pain; numbness; safe working environment; human; disease

Citation: Hidayati HB, Subadi I, Fidiana, Puspamaniar VA. Current diagnosis and management of carpal tunnel syndrome: A review. *Anaesth. pain intensive care* 2022;26(3):394-404. DOI: [10.35975/apic.v26i3.1902](https://doi.org/10.35975/apic.v26i3.1902)

Received: August 16, 2021; **Reviewed:** April 24, 2022; **Accepted:** April 28, 2022

1. Introduction

The carpal tunnel is an osteofibrous canal linking the inside part of the palm and forearm.¹ Carpal tunnel syndrome (CTS) is a neuropathic syndrome related to the compressed median nerve in the carpal tunnel, under the transverse carpal ligament.² The median nerve gives innervation to the small muscles of the hand and sensory innervation to the fingers, which control the touch sensation and reflexes for the right motor function,

especially the hand grip.³ CTS is the most prevalent neuropathic entrapment in the upper extremity.⁴ The symptoms are recognized by pain, numbness, and tingling in the median nerve's division in the hand.⁵ CTS occurs due to chronic repetitive forceful work involving vibration, extreme postures of the wrist, or a combination of them, such as typing or repetitive wrist movement. It is also determined by sex, age, heredity, hormonal, weight, diabetes mellitus, pregnancy, and autoimmune disorders such as rheumatoid arthritis.⁶⁻⁸ Male patients

are more prone to go for surgery than the female patients. CTS is a work-related illness for both sexes. CTS female patients are more sensitive than men based on their reported manifestations. Older age, diabetics, and those with higher BMI are more prone to have bilateral CTS. Age and BMI are separately related to bilateral CTS. There is also a relation between CTS and cardiovascular risk factors in youthful society and with carotid intima-media widening.⁸

In 1854, the initial clinical narration of median nerve compression in the carpal tunnel was found when Paget published two cases of median nerve compression inside the carpal tunnel, one idiopathic and one post-traumatic.⁹ Putnam published the case histories of 37 patients, most of them women, who all had the same symptoms of change of skin sensitivity or numbness. It is recurrent and periodic especially during the night or in very early morning. In some cases, they let the arm hang up from the bed or swing it for a while, then it would make the numbness go away. Phalen published articles containing epidemiology, clinical picture, diagnostic tests, and recommended surgical treatment. Gilliart and Wilson published the tourniquet test in 1953, which is a supporting diagnosis of CTS and the first article of electromyography for this appeared in 1956. In the end, CTS was characterized in the 1950s, and now the research on it has become very extensive.⁹

Neuropathic pain (NP) is a persistent weakening pain induced by a somatosensory system disorder.¹⁰ CTS is the major reason for chronic neuropathic pain in the upper extremity.² The National Health Interview Study (NHIS) estimates the prevalence of CTS in the adult population to be 1.55% (2.6 million); 3.6 times more common in women than in men, and in the age range between 25 and 64 y, with the highest prevalence being in women older than 55 y.¹¹ CTS usually begins at the age of 20-60 y, the prevalence increasing comparably with the age.¹² Overall, the frequency of CTS is higher in the age range of 25-34 y (89.2%). The high prevalence rate incurs high costs on medical treatment, rehabilitation, lost working hours, initial pension costs, and for new workers training. This makes CTS a major problem in the field of employment.¹³

Knowledge of the diagnosis and treatment of CTS is important for the clinicians. The right diagnosis will lead to the right treatment, resulting in a better quality of life for the patients. There have been many studies on CTS, but until now its treatment remains a challenge in the medical world. This article will discuss the diagnosis, starting from the history taking, physical examination (including specific examination for CTS), supporting tests, and recent treatments (including non-pharmacological and pharmacological therapy) of CTS based on the recent research and the guideline.

2. Pathophysiology

The pathophysiology of CTS generally results from a combination of traction and compression mechanisms. A chronic high pressure, venous outflow obstruction, local edema, and median nerve's intraneural microcirculation compromise are the main elements. When the nerve function becomes disturbed, the changed environment produces the lesions of the myelin sheath and the axons. Inflammation occurs in the surrounding connective tissues, which start to lose their normal supportive and protective function. Wrist compression and repetitive traction aggravate the negative environment, then starting injury to the nerve. Inflammation and nerve compression occur in the flexor tendons and median nerve under the carpal tunnel.⁷ Increased carpal tunnel pressure (CTP) leads to median nerve sensory, motor, and pathological transformations.¹⁴

Brain and colleagues reported the symptoms of unforced median nerve compression inside the carpal tunnel. The theory of microvascular insufficiency states that the reduced blood supply causes the lack of oxygen and nutrients to the nerves, so they lose the ability of the nerve impulse transmission. The ischemia probably plays an important part in the pathogenesis of CTS. The development of ischemia depends on the blood supply to the nerve and the systolic blood pressure. Based on the theory of vibration, the CTS symptoms might respond to the vibrating tools used on the median nerve in the carpal tunnel. Some changes recorded were in unmyelinated nerve fibers that serve the sympathetic activity and might lower the flow of micro-vascular blood supply to the median nerve. This leads to disturbance of the myelin sheath and lessen motor conduction speed.¹⁵

Penetration of the transverse carpal ligament by amyloids (such as in multiple myeloma and amyloidosis) or solidification of the connective tissue in mucopolysaccharidosis, acromegaly, rheumatoid arthritis, and hypothyroidism are less common causes. In an older patient, the cause of CTS remains unclear. Dysesthesia and pain in the fingers, known for years as acroparesthesia, are common in old age and were recognized as symptoms of median nerve compression in the early 1950s.

3. Diagnosis

CTS is diagnosed by the history taking, physical examination (including specific tests for CTS), and supporting examinations.

3.1. History Taking

Patients usually complain of tingling, numbness, and pain that exacerbates at night. Weakness, stiffness, and the change in temperature are also frequent. Fingers that are usually affected are the thumb, digits 2 and 3, and the

radial half of the digit 4, but the little finger is seldomly involved because of the ulnar nerve innervation.¹⁵ Pathology of the median nerve affects every nerve function from distal to the site of the lesion, with potential soreness in the proximity of the shoulder.¹⁶ CTS patients are usually positive on the "flick sign" test. This means that the symptoms increase when the patient flicks his hand and wrist. Patients frequently feel relieved with ice, rest, and night splints.⁷ In the middle of the night, many patients report that they are often woken by pain and usually hang their hand up from bed or swing it strenuously so that their pain can be relieved. The symptoms vary depending on the severity.¹⁵

CTS has three stages based on their symptoms.⁵ Patient with the first stage probably wake up from sleep and feel numbness or swelling on his hand, without any noticeable swelling. The patient feels an extremely irritating sensation from the wrist upto the shoulder, alongwith a tingling sensation in the hand and fingers, this is usually called brachialgia paresthetica nocturna. Patients with the second stage may feel the symptoms during the day especially when they engage with a monotonous activity implicating the wrist or hand or if they maintain a fixed position for long times. Patients might also complain of clumsiness while using hands to hold objects and leading them to falling. The terminal stage happens when the thenar eminence starts hypotrophy or atrophy. This stage also compromises the patient's sensory abilities.

3.2. Physical Examination

Mild to moderate CTS patients mostly do not show any findings on physical examination. To exclude other causes, clinician needs to perform a comprehensive examination on the whole upper extremity; from the wrist, elbow, shoulder, and up to the neck. In advanced disease there can be constant sensory and motor loss. A decreased pain sensation (hypoalgesia) can be found on the palmar side of the index finger and it contrasts with the ipsilateral little finger on the effected hand. The absence of two-point discrimination in the hypoalgesia area shows the inability to discriminate among points less than 6 mm distant from each other.¹⁷ Two-point discrimination test is performed by giving stimulation to the patient at two points far apart, then slowly approaching each other until the patient makes a mistake. The normal distance to sense two points is 1 mm on the tip of the tongue, 2-3 mm on the lips, 2-4 mm on the finger tips, 4-6 mm on the back of the fingers, 8-12 mm on the palms, 20-30 mm on the dorsum of the hand, and 30-40 on the dorsum of the feet.¹⁸

Thenar eminence is innervated by palmar cutaneous branch of the median nerve which branches off proximal to the carpal tunnel and it gives the sensory sensation. That's why a decreased sensation on the thenar eminence

shows a lesion in the median nerve proximal to the carpal tunnel. In advanced CTS, signs that can be found are the weakness of thumb abduction and apposition and the thenar eminence atrophy.¹⁷ Figure 1 shows the atrophy of the right thenar muscles in a CTS patient.

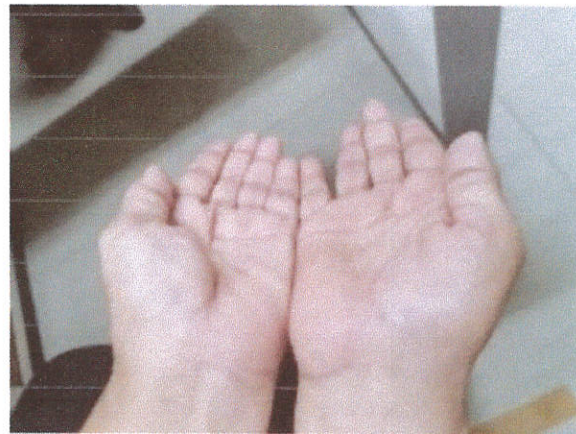

Figure 1: Atrophy of right thenar muscle

The two provocative tests commonly used to diagnose CTS are Phalen's test and Tinel's test. In Phalen's test, the patient is commanded to bend their wrist and maintain it for one minute. If a patient feels any soreness or paresthesia in the median nerve distribution, it is called a positive response. Phalen's test sensitivity is approximately 67% – 83% and its specificity is 40% - 98%. Tinel's test is performed by knocking the volar side of the wrist. If a patient feels pain or paresthesia in the radial side of the ring finger, middle finger, index, and thumb, which are innervated by the median nerve, it is called a positive response. Tinel's test has approximately 48% – 73% sensitivity with 30% – 94% specificity.¹⁹

There are few more tests to diagnose CTS. The Scratch Collapse Test (SCT) evaluates the claudication of shoulder external rotation to a stimulus by carpal tunnel scratching. Sensory stimuli such as finger swipe, scratch, blown air, and deep pressure must generate a response in the particular region of the nerve injury. This is a subjective physical examination so that it is hard to decide how large resistance is applied on the external rotation of the patient's shoulder and how it measures their collapse.²⁰

3.3. Supporting Examination

The diagnosis of CTS used to be a clinical one. However, nowadays, electrodiagnostic studies (EDX) are generally used for diagnosis, since they provide objective parameters for prediction and causal evaluation. It also serves the diagnostic confirmation and grade severity for CTS. EDX, particularly nerve conduction studies (NCS), is currently being observed as the standard of reference

for CTS.²¹ EDX is the most common diagnostic test consisting of NCS and electromyogram (EMG).²²

NCS is judged as the gold standard in the CTS diagnosis since it provides information about the median nerve's physiological health over the carpal tunnel. The comparison of the latency and amplitude between the median nerve section over the carpal tunnel to different nerves that do not go through the carpal tunnel, such as the ulnar or radial nerve, is the basic method. A transcutaneous pulse of electricity stimulates the nerve, inducing an action potential. A recording electrode is placed to detect the wave of depolarization passing by the surface of electrode. This is the most susceptible and precise way with 80% – 92% as sensitivity and 80% – 99% as specificity.⁹

Ultrasonography (USG) is an easily accessible yet non-invasive diagnostic tool. It also provides spatial information and is helpful in patients who need local steroid injection. It helps clinician to exclude external median nerve compression by ganglia, tumors and tenosynovitis. Postoperative complications like scarring, hematoma, and insufficient resection of the retinaculum can be visualized by USG.⁹ This modality has become more popular because of its efficiency, low expense, and diagnostic precision like EDX. In spite of the various limitations, US allows the clinician to lower the water content in the tissue and to diagnose nerve swelling.³

Cross-sectional area (CSA) of the median nerve is one of the useful USG parameters, indicative of CTS. USG measured CSA has been the strongest predictor of CTS severity compared to other variables tested. A recent study showed that USG is more precise for the prediction of severe CTS in younger patients.²¹ A study conducted in 2018 established that CSA gives a sensitivity of 75% and specificity of 87.5% in diagnosing CTS. Nerve CSA can be calculated at different areas around the forearm and wrist by a lineal trace method inside the hyperechoic rim of the nerve sheath. USG can also be used to evaluate median nerve and carpal tunnel dimensions, median nerve location within the tunnel (palmar shifting), and flexor retinacular (volar) bowing and thickness.¹²

Magnetic resonance imaging (MRI) is an alternative diagnostic tool for CTS. A study conducted in 2002 using NCS and diagram of hand pain as the gold standard showed that MRI gives a sensitivity of 96% for the CTS detection, but only 33% for specificity. A study conducted in 2019 compared USG and MRI in healthy volunteers and CTS patients, and established that CSA is specific and sensitive with 0.874–0.997 as the receiver operator curve area (statistically identical with USG-measured CSA).²² MRI is helpful for detecting rare pathological causes of CTS such as ganglion, hemangioma, or a bone deformity. Sagittal images are also helpful in displaying the accurate site and serving the

grade of nerve compression severity with 96% sensitivity, yet the specificity is low at 33% - 38%. MRI may help in predicting patients who will need surgery because of the anomalous nerve signal length on T2-weighted MRI; the median-ulnar sensory latency distinction are preferable predictors for the outcome of the surgery.⁹ The surgeons may think about taking MRI as CTS detailed evaluation if there are symptoms but no proof of nerve conduction test.²³

3.4. Grading based on electrodiagnostic studies

Grading of CTS is divided into four groups based on its electrodiagnostic findings, which are CTS without median neuropathy at wrist, mild, moderate, and severe. Table 1 shows the CTS grading and the chosen interventions.²⁴

Table 1: Grading based on electrodiagnostic findings

Severity of CTS	Findings on Electrodiagnostic	Intervention
CTS with no median neuropathy at the wrist (MNW)	No	Treat the symptoms
Mild	Abnormality in comparison studies or median sensory nerve	Treat the symptoms
Moderate	Prolonged distal motor latency to the abductor pollicis brevis with normal amplitude of APB CMAP	Injections/surgery with progressivity
Severe	Criteria on the above plus either decrement of median to APB CMAP amplitude and/or needle EMG abnormality in the thenar muscles	Surgery if no contraindication

4. Differential diagnosis

CTS can be distinguished from the following:^{17,25}

- **Cervical radiculopathy (especially C6–C7)**

Neck pain, lack of sensation only on the thumb and index finger, positive result of Spurling test. The pain is usually reduced when the neck is rested and increases when the neck is moved. The distribution of sensory disorders is according to the dermatome.

- **CNS disorders**
Such as multiple sclerosis and small cerebral infarction
- **Peripheral neuropathy**
Diabetes mellitus history and the involvement of both lower extremities
- **Pronator syndrome (the compression of median nerve at the elbow)**
Forearm suffering; lack of sensation on top of the thenar eminence; weakness in the flexion of thumb, extension of wrist, and pronation of forearm. The pain on the palm of the hand is more prominent complaint than in CTS, because the median nerve branch to the skin of the palm does not pass through the carpal tunnel.
- **Carpometacarpal arthritis of the thumb**
Soreness in thumb movement, positive result of grind test, findings on radiographic studies
- **Wrist arthritis**
Soreness in wrist motion, radiographic findings
- **de Quervain tendinopathy**
Tenosynovitis of the abductor pollicis longus tendons and extensor pollicis brevis muscles is usually due to repetitive hand movements. The symptoms are pain and tenderness in the distal radial styloid area. Finkelstein's test: palpation of thumb abductor muscle during passive abduction of thumb, positive result if pain increases.
- **Raynaud syndrome**
Manifestations correlated to cold exposure, specific color changes
- **Ulnar compression neuropathy**
Paresthesia's on the ring and little fingers; positive result of Tinel sign and compression tests at the elbow or wrist (Guyon canal)
- **White finger vibration**
Usage of vibrant hand power tools, Raynaud phenomenon manifestations

5. Prevention

A systematic review states that workplace plans can incorporate interventions concentrating on education, workout, ergonomics, physiotherapy, and epidemiological surveillance. Ergonomic interventions such as keyboard, mouse, and wrist rest modifications can be merged with education about ergonomic principles in postural hygiene, participative ergonomics, musculoskeletal disorders, working subject co-responsibility, behavioral changes, and exercise. Ulnar

drift reduction or maintaining a neutral position with interventions such as accessory composition modifications (mouse, keyboard, wrist rest, and workstation) may also lower the CTS risks.²⁶

6. Management

CTS management includes non-invasive therapies, such as non-pharmacological and pharmacological therapies, and invasive therapies such as surgery.

6.1. Non-invasive therapies

6.1.1. Non-Pharmacological Management

The first-line for CTS management is education. The patient needs to be educated about changing some habits including limiting heavy work and excessive wrist movements and using ergonomic work tools to reduce median nerve stress.⁹

For patients with mild CTS symptoms, the modest treatment is a wrist splint at night. This method is known as an inexpensive therapy and has a minimal complication rate. It helps patient avoid the extreme position of the wrist, reduce the pressure on carpal tunnel, refine hemodynamic parameters, lower the edema, and narrow nerve friction and compression.²⁷ Splint therapy is one of the most common complementary interventions. The use of a wrist splint is more beneficial than any other intervention.²⁸

Ultrasound (US) therapy produces localized heat on joint capsules, tendons, ligaments and muscles, and can produce an increased cellular activity and localized vasodilation, thus increasing the supply of nutrients and oxygen, and removing the metabolic waste. This decreases the irritating nociceptive nerve endings and therefore, lowers the pain. The US will not influence the nerve tissue repair process, but it speeds up the fibrotic tissue repair by accelerating the inflammatory substances induction. A combination of US and neural mobilization is more potent to lower the hand dysfunction than a combination of US and passive stretching for CTS patients.²⁹ US therapy produces a sound frequency greater than 20,000 MHz. Generally, it has a frequency between 0.7 to 3.3 MHz, to maximize the energy that enters the soft tissue. The purpose of the US is to reduce pain and stimulate the healing process in the tissue collagen. The tissue stimulation can facilitate the recovery of median nerve compression.^{11, 27} A study conducted in 2017, comparing Low-Level Laser Therapy (LLLT) and US for the therapy of CTS, showed that both LLLT and US are equally effective for the therapy of mild to moderate CTS patients.³⁰

Mobilization exercises are used to refine the axonal transport and nerve conduction, usually performed by tendon gliding and nerve gliding exercises. Tendon and nerve gliding practices could maximize the median nerve

movement in the carpal tunnel, as well as the movement of the flexor tendons relative to each other. The practices include median nerve gliding by moving the wrist and fingers, and tendon gliding by moving a sequence of fingers.²⁷ Tendon gliding is an exercise that is often recommended to prevent tendon adhesions.¹¹ Patients must exercise for ten times in repetitions, three to five times each day. Every position is held for five seconds.²⁷ One of the nerve gliding movements is when the hand is in a fist position, it pushes the superficial flexor digitorum tendon and the flexor digitorum profundus tendon, so it reduces the compression on the median nerve. Nerve mobilization also helps the process of nerve oxygenation to reduce ischemic pain.¹¹

6.1.2. Pharmacological Management

Pain is often an overlooked symptom, still a worldwide problem and continues to be the commonest and strongest motivation for the patients to seek medical help.^{2, 31-33} As a first line pharmacological management, clinicians can give nonsteroidal anti-inflammatory drugs (NSAIDs) to relieve pain in CTS patients. Oral steroids and vitamin B6 can be given as second line therapy.³⁴ A guideline states that oral drugs are not effective in treating CTS patients.³⁵ The recommended dose of pyridoxine is 100-300 mg/day for 3 months.³⁴ Daily dose of 20 mg prednisone orally improves the symptoms and functions as compared to placebo and its relief is sustained for approximately 8 weeks.⁵ Oral steroids are less potent than a steroid injection. NSAIDs, diuretics, and vitamin B6 are not potent for the CTS therapy.¹⁷ Analgesic drugs may not be effective if administered alone, without combining with other drugs, e.g., gabapentin, amitriptyline, diazepam, and vitamins, including B1, B6, and B12 for chronic pain. Combination of analgesic drugs will remarkably lower the adverse effect.² Tricyclic and other antidepressant drugs are frequently used as the neuropathic pain therapy,³⁶ including that of CTS.³⁷ Amitriptyline gives better results as treatment for sensory symptoms in early CTS.³⁸ Gabapentin gives notable analgesia in some neuropathic pains such as trigeminal neuralgia and peripheral diabetic neuropathy. It modulates voltage-dependent calcium channels and glutamate uptake.³⁹ A study review recommends no significant advantage of gabapentin use for symptomatic relief or power strength improvement in mild-to-moderate CTS patients.⁴⁰ Pregabalin has been recommended as first- and/or second-line drug for neuropathic pain in several guidelines. Pregabalin is started at 150 mg daily and titrated up to the maintenance daily dose range. In Japan and USA, pregabalin dose range is 300-600 mg for neuropathic pain.⁴¹

Wrist steroid injections are often successful to treat patients with CTS. This therapy has been known as a well-studied and potent intervention for mild and

moderate CTS patients.⁴² A guideline states that this therapy can be administered after oral therapy.³⁴ Another study stated that the wrist steroid injection combined with a wrist splint is preferred as first line treatment.³⁵ It may lead the symptoms to deteriorate tentatively but generate necessary pain comfort in 60% - 70% of patients for weeks to years. Steroid treatment is effective in reducing inflammation and edema.^{19,43} Dexamethasone 1 - 4 mg or hydrocortisone 10-25 mg or methylprednisolone 20-40 mg is injected into the carpal tunnel using a 23 or 25G needle at 1 cm proximal to the wrist crease medial to the palmaris longus tendon at an angle of 30°. The injections can be repeated in 7 to 10 days for a total of three or four injections. Injections should be used with caution in patients under 30 y of age. The limitations of collagen and proteoglycan synthesis are the major side effects. It limits the tenocytes and lowers the tendon mechanical force. This leads to more decay.¹⁹ The most secure location for injection is still unclear. The local steroid injection was more preferable than decompression surgery for relieving nocturnal paresthesia at 3 and 6 months. Follow up on 12 months proves that local steroid injection was as effective as decompression surgery.¹⁵ Ultrasound guided injection might be more effectual than blind injection because it permits direct visualization to confirm the precise and safe needle insertion.^{27, 44-46} A study conducted in 2021 stated that US-guided injection was better than landmark-guided injection with a higher success rate, and lower side effects for CTS.⁴⁷ A study conducted in 2018 compared local steroid injection with night time splinting. It indicated that a single injection of 20 mg methylprednisolone acetate at 6 weeks was more beneficial in alleviating pain and improving function than night wrist splints.⁴⁸

Injection of one dose of 5% dextrose, also called prolotherapy, has been indicated to be effective in improving the function in CTS. The mechanism of hypo-osmolar 5% dextrose injection has been postulated to produce the analgesic effect on sore peripheral nerves and central nervous system by osmotic effect in regional cells.⁴⁹ Recent studies compared perineural dextrose injection (PDI) and steroid, and expressed significant improvement in pain and disability in CTS patients.⁴⁹ A trial conducted to study the effect of different injectate volumes of PDI on US parameters and the association with the results. PDI with higher volume produced better nerve movement and decreased median nerve CSA, but did not alter nerve elasticity.⁴⁹

Another therapy, which is getting well known, is platelet-rich plasma (PRP) injection. This is an alternative option to surgical therapy because of the regenerative result in CTS patients with demyelination and axonal degeneration. PRP is likely to be more potent three months post-injection based on manifestation, function, electrophysiological, and clinical parameters than

methylprednisolone injection.²⁸ A trial study enrolled PRP injection in 71 moderate CTS patients and stated that it's efficacious for mild-to-moderate CTS. Some factors like lower body weight, distal motor latency, and cross-sectional area values of median nerve gives finer results post-PRP perineural injection in moderate CTS at the 3 - 6 months follow-up.³⁰

A case report gives another innovative therapy for CTS disability, named ultrasound-guided PRP injection with median nerve hydrodissection followed by active tendon and nerve gliding exercises in prompt post-injection phase. The therapy improved the pain and disability in CTS, as well as median nerve function, similar to surgical release and gives better results than non-surgical therapies.³¹

Surgery should be considered if the symptoms persist and there is no relief, or if the motor or sensory deficiency persists. Surgery might be indicated when the symptoms persist for more than six months without any relief with non-surgical treatment.⁵ It is also recommended for patient with severe grade of electrodiagnostic studies finding. Surgical option in CTS patients is on an increase because of the increment of evidence stating that this therapy is potent and more durable.³² It produces an additional space for tendons and median nerve to pass through the carpal tunnel. It frequently eases pain and rectifies the function. The risks of surgery are infections, bleeding, sensitive wounds, nerve injuries to the branches of the median nerve, and trauma to the surrounding blood vessels. The healing after surgical therapy varies from weeks to months. It hinges on the time span of the median nerve compression. Wrist splints and physical therapy are recovery plans aiming to cure and reinforce hand and wrist.⁵ Surgical decompression outcome is better in compromised median nerve distal motor latencies and sensory nerve conduction speed.¹⁵ The long-term results in about 70% - 90% of patients are good to excellent.¹⁹

6.2. Invasive therapy

One of the surgical techniques is carpal tunnel release (CTR) consisting of open surgery and endoscopic techniques. Endoscopic carpal tunnel release surgery (ECTR) has considerably gained popularity during the last two decades because of speedy recovery and less pain with no negative outcomes. It can produce potent decompression for both ulnar and median nerves at wrist. The detachment of transverse carpal tunnel ligament decompresses Guyon's canal and the carpal tunnel. A study showed that the reported results and two-point discrimination test related to ulnar nerve symptoms showed improvement after open carpal tunnel release (OCTR).³³ ECTR and OCTR, both offer satisfactory results in pain relief, patient satisfaction, relief duration, and adverse effects. There is growing evidence about the benefits of endoscopic technique. Some studies

established faster return-to-work and resumption of daily activities with endoscopic technique.³⁴ A study conducted in 2019 compared the efficacy of modified ECTR and OCTR. The authors concluded that modified ECTR for CTS treatment gave better patient satisfaction, shorter surgery and hospitalization time, earlier return-to-work time, and less postoperative scar soreness. Thus, they recommended modified ECTR as an efficacious method for idiopathic CTS.³⁵ Pillar pain is a prevalent postoperative complication of CTR. The cause of pillar pain remains unclear. One of the most common theory is a damage of small palmar cutaneous branches of median nerve after surgical incision. A retrospective study describes a simple change of standard CTR technique in order to decrease neuroma formation and pillar pain. It concludes that modified CTR shows significantly lower incidence and duration of pillar pain, higher rate of patient satisfaction, and earlier return-to-work compared to the standard CTR.³⁶

6.3. Alternative therapy

Now a days, acupuncture is said to be one of CTS management modalities. A study states that acupuncture is more potent than regular therapies, such as anti-inflammatory drugs. Acupuncture effectively relieves pain, numbness, inflammation, and returns motor function. Electromyography established good results, including noticeable improvements in some parameters, such as sensory nerve conduction velocity, sensory amplitude, median nerve sensory latency, motor latency, motor nerve conduction pace, and motor amplitude. The acupuncture mechanism in CTS is the activation of some brain areas including the primary somatosensory cortex, secondary somatosensory cortex and prefrontal cortex. This brain area gives a role in the sensory perception as CTS main manifestations such as paresthesias and pain. Acupuncture rectifies CTS symptoms based on CTS questionnaire - BCTQ (Boston Carpal Tunnel Questionnaire). Acupuncture also improves NCS examination outcomes, such as sensory conduction velocity and motor latency. The most regularly used points are PC7, TE5, PC6, and LI11. PC7 can be found in the middle of the wrist crease among the palmaris longus and flexor carpi radialis tendons. TE5 is located on the dorsal of the forearm at the interosseous space midpoint among radius and ulna which is 2 cun proximal to the dorsal wrist crease. PC6 is located 2 cun above the wrist crease between the palmaris longus and flexor carpi radialis tendons. LI11 point is on the lateral end of the transverse cubital crease when the elbow is flexed. The point selection is based on the anatomy and the abnormality location in median nerve. Acupuncture modalities frequently utilized are manual acupuncture and electro acupuncture.³⁷ Acupuncture therapy can be considered as an alternative management for patients who can't go through for early decompression surgery.³⁸

Cupping therapy has been used to reduce pain.^{10, 31, 59} This is also one of the new breakthrough in the management of CTS. It is the oldest medical practice and alternative method for applying fast, powerful, and rhythmic force to escalate blood supply. It is used for several neuropathic disorders,^{10, 60} and is one of the cost-effective and traditional treatment options. Cupping is differentiated as dry and wet cupping. In dry cupping, the skin is pinched into the cup through vacuum pressure, while in wet cupping, scarification is performed to attract blood into the cup.⁶⁰ Taking cupping therapy as a regular physical therapy can offer symptomatic relief and improve sensory conduction distal to median nerve. It is recommended that cupping is a convenient and cheap methods to be used as a complementary CTS treatment.⁶¹

Dry needling (DN) is useful for overcoming pain.⁶² Dry needling is usually utilized as a treatment for any neuromusculoskeletal pain syndromes involving ligaments, muscles, tendons, subcutaneous fascia, peripheral nerves, scar tissue, and neurovascular bundles.⁶³ Dry needling at specific points under ultrasound guidance is potent therapy for CTS and myofascial hand pain.⁶⁴ This therapy works on CTS by stimulating non-TRP channels.

7. Future direction

CTS is one of the disorders in postmenopausal women with estrogen receptor-positive breast cancer receiving hormone therapy. A trial was conducted in order to study its pathophysiology and encourage the new therapeutic strategies.⁶⁵ The research compared the results of cervical manual therapy plus conservative physical therapy and conservative physiotherapy in CTS patients. The authors stated that by treating cervical spine can decrease the manifestations distally to carpal tunnel. The outcomes proved that conservative physiotherapy merged with cervical manual therapy, was more potent for refining functional capabilities, pain, median nerve motor distal latency, and median sensory nerve conduction pace in CTS patients.⁶⁶

8. Prognosis

The prognosis can be predicted by using electrodiagnostic techniques. In mild cases, conservative therapy generally has a good prognosis. In general, the prognosis of surgery is also good, but as the operation is only performed on patients who have long suffered from CTS, the postoperative recovery is gradual. Conjoint therapy might be more helpful than any singular therapy. A short course of NSAIDs can ease any symptoms but several does not find it is as sufficient advantages.⁷ Although the prognosis of CTS with conservative or operative therapy is quite good, the risk of recurrence

does exist. If recurrence occurs, either conservative or operative therapeutic procedures can be repeated.⁶⁷

9. Conclusions

CTS is the most prevalent neuropathic entrapment of the upper extremity. It results from the median nerve compression as it passes through the carpal tunnel. Patients usually grumble some soreness and paresthesias in the median nerve division. It radiates to the palmar aspect of radial side of the ring finger, middle finger, index, and the thumb. Mostly it is caused by repetitive traction and wrist compression. The diagnosis can be based on the symptoms and signs, and electrodiagnostic modalities such as nerve conduction studies, as well as radiologic techniques such as ultrasonography, CT scan or MRI. CTS management includes non-pharmacological and pharmacological therapy. Surgery is only considered when patient is in moderate to severe stage of the disease.

10. Conflict of interest

The authors declare no conflict of interests.

11. Funding

This research did not receive any specific grant from funding agencies in the public, commercial, or not-for-profit sectors.

12. Authors contribution

HBH: conception of the work, literature research, manuscript drafting

IS: literature research, performed the analysis, manuscript editing

F: conception of the work, literature research, manuscript writing

VAP: literature research, manuscript reviewing and revising

13. References

1. Glazer C, Pantea C. Systematic review of treatment methods for the carpal tunnel syndrome. *Timisoara Phys Educ Rehabil J*. 2019;12(22):7-12. DOI: [10.2478/teperj-2019-0001](https://doi.org/10.2478/teperj-2019-0001)
2. Kadarusman TA, Hidayati HB, Sugianto P. Analgesic drug use for carpal tunnel syndrome. *JUXTA J Ilm Mhs Kedokt Univ Airlangga*. 2019;10(1):1. DOI: [10.20473/juxta.V10I12019.1-4](https://doi.org/10.20473/juxta.V10I12019.1-4)
3. Obuchowicz R, Kruszyńska J, Strzelecki M. Classifying median nerves in carpal tunnel syndrome: Ultrasound image analysis. *Biocybern Biomed Eng*. 2021;41(2):335-51. DOI: [10.1016/j.bbe.2021.02.011](https://doi.org/10.1016/j.bbe.2021.02.011)
4. Talebi GA, Saadat P, Javadian Y, Taghipour M. Manual therapy in the treatment of carpal tunnel syndrome in diabetic patients: A randomized clinical trial. *Caspian J Intern Med*. 2018;9(3):283-9. [PubMed] DOI: [10.22088/cjim.9.3.283](https://doi.org/10.22088/cjim.9.3.283)
5. Genova A, Dix O, Saefan A, Thakur M, Hassan A. Carpal tunnel syndrome: a review of the literature. *Cureus*. 2020;12(3):e7333. [PubMed] DOI: [10.7759/cureus.7333](https://doi.org/10.7759/cureus.7333)

Hidayati HB, et al

carpal tunnel syndrome

6. Setyawan H. Risk factors of carpal tunnel syndrome among food-packing workers in Karanganyar. *Kesmas*. 2017;11(3):123-6. DOI: [10.21109/kesmas.v11i3.1185](https://doi.org/10.21109/kesmas.v11i3.1185)
7. Sevy JO, Varacallo M. Carpal Tunnel Syndrome. In: StatPearls. Treasure Island (FL): StatPearls Publishing; 2022. [PubMed]
8. Cazares-Manriquez MA, Wilson CC, Vardasca R, Garcia-Alcaraz JL, Olguin-Tiznado JE, López-Barreras JA, et al. A review of carpal tunnel syndrome and its association with age, body mass index, cardiovascular risk factors, hand dominance, and sex. *Appl Sci*. 2020;10(10):3488. DOI: [10.3390/app10103488](https://doi.org/10.3390/app10103488)
9. Gyanchandani K, Chaudhry N. Carpal tunnel syndrome: a review. *Int J Sci Res*. 2020;9(3). [FreeFullText]
10. Hidayati HB, Machfoed MH, Kuntoro, Subadi I, Khaerunnisa S, Widjati. Increase in the glutamate transporter 1 and time withdrawal latency following wet cupping therapy in chronic constriction injury in rats. *Anaesth Pain Intensive Care*. 2021;25(1):50-6. DOI: [10.35975/apic.v25i1.1441](https://doi.org/10.35975/apic.v25i1.1441)
11. Hamid A, Fathur Rahman Z, Suherdin S, Widati S, Ardyanto Wahyudiono YD. Factors Related to Carpal Tunnel Syndrome (CTS) Complaints on Employees in the Bank BNI Branch of Palu. *J Ilmu Kesehatan Masy*. 2020;11(01):63-74. DOI: [10.26553/jikm.2020.11.1.63-74](https://doi.org/10.26553/jikm.2020.11.1.63-74)
12. Erickson M, Lawrence M, Lucado A. The role of diagnostic ultrasound in the examination of carpal tunnel syndrome: an update and scoping systematic review. *J Hand Ther*. 2021 Apr 14;S0894-1130(21)00061-2. [PubMed] DOI: [10.1016/j.jht.2021.04.014](https://doi.org/10.1016/j.jht.2021.04.014)
13. Subandi S, Mirawati DK, Erdana Putra S, Hafizhan M, Susilo WA, Danuaji R. The relationship between working period of batik craftsmen and incident of carpal tunnel syndrome. *Malang Neurol J*. 2020;6(2):73-6. DOI: [10.21776/ub.mnj.2020.006.02.5](https://doi.org/10.21776/ub.mnj.2020.006.02.5)
14. Toyoshima Y, Zhou B, Kubo K, An KN, Moran SL, Zhang X, et al. A non-invasive technique for evaluating carpal tunnel pressure with ultrasound vibro-elastography for patients with carpal tunnel syndrome: A pilot clinical study. *J Biomech*. 2021 Feb 12;116:110228. [PubMed] DOI: [10.1016/j.jbiomech.2021.110228](https://doi.org/10.1016/j.jbiomech.2021.110228)
15. Aroori S, Spence RA. Carpal tunnel syndrome. *Ulster Med Soc*. 2008;77(1):6-17. [PubMed] PMID: [PMC2397020](https://pubmed.ncbi.nlm.nih.gov/172397020/)
16. Erickson M, Lawrence M, Jansen CWS, Coker D, Amadio P, Cleary C. Hand pain and sensory deficits: Carpal tunnel syndrome. *J Orthop Sports Phys Ther*. 2019;49(5):CPG1-85. [PubMed] DOI: [10.2519/jospt.2019.0301](https://doi.org/10.2519/jospt.2019.0301)
17. Wiperman J, Goerl K. Carpal tunnel syndrome: diagnosis and management. *Am Fam Physician*. 2016 Dec 15;94(12):993-999. [PubMed]
18. Campbell W. DeJong's: The Neurologic Examination. 7th ed. Philadelphia: Lippincott Williams & Wilkins; 2013. p.527-531, p.541-543.
19. Ibrahim I, Khan WS, Goddard N, Smitham P. Carpal tunnel syndrome: a review of the recent literature. *Open Orthop J*. 2012;6:69-76. [PubMed] DOI: [10.2174/1874325001206010069](https://doi.org/10.2174/1874325001206010069)
20. García-Medrano B, Simón Pérez CL, Corella Montoya MA, Delgado PJ, Corella Montoya F. Objective evaluation of the "scratch collapse test" for the diagnosis of carpal tunnel syndrome. *Injury*. 2021 Jul;52 Suppl 4:S145-S150. [PubMed] DOI: [10.1016/j.injury.2021.01.050](https://doi.org/10.1016/j.injury.2021.01.050)
21. Nkrumah G, Blackburn AR, Goitz RJ, Fowler JR. Ultrasonography findings in severe carpal tunnel syndrome. *Hand*. 2020;15(1):64-8. [PubMed] DOI: [10.1177/1558944718788642](https://doi.org/10.1177/1558944718788642)
22. Tulipan JE, Ilyas AM. Carpal tunnel syndrome surgery: what you should know. *Plast Reconstr Surg Glob Open*. 2020;8(3):e2692. [PubMed] DOI: [10.1097/GOX.0000000000002692](https://doi.org/10.1097/GOX.0000000000002692)
23. Park JS, Won HC, Oh JY, Kim DH, Hwang SC, Yoo JI. Value of cross-sectional area of median nerve by MRI in carpal tunnel syndrome. *Asian J Surg*. 2020;43(6):654-9. [PubMed] DOI: [10.1016/j.asjsur.2019.08.001](https://doi.org/10.1016/j.asjsur.2019.08.001)
24. Sonoo M, Menkes DL, Bland JDP, Burke D. Nerve conduction studies and EMG in carpal tunnel syndrome: Do they add value? *Clin Neurophysiol Pract*. 2018;3:78-88. [PubMed] DOI: [10.1016/j.cnp.2018.02.005](https://doi.org/10.1016/j.cnp.2018.02.005)
25. Alfonso C, Jann S, Massa R, Torreggiani A. Diagnosis, treatment and follow-up of the carpal tunnel syndrome: A review. *Neurol Sci*. 2010;31(3):243-52. [PubMed] DOI: [10.1007/s10072-009-0213-9](https://doi.org/10.1007/s10072-009-0213-9)
26. Trillos-Chacón MC, Castillo-M JA, Tolosa-Guzman I, Sánchez Medina AF, Ballesteros SM. Strategies for the prevention of carpal tunnel syndrome in the workplace: A systematic review. *Appl Ergon*. 2021;93(December 2020). [PubMed] DOI: [10.1016/j.apergo.2020.103353](https://doi.org/10.1016/j.apergo.2020.103353)
27. Utomo P, Surya WA, Hadinoto SA, Sumarwoto T. Current concept management of carpal tunnel syndrome: a case report. *Indones J Med*. 2020;5(1):70-86. DOI: [10.26911/thejmed.2020.05.01.11](https://doi.org/10.26911/thejmed.2020.05.01.11)
28. Hernández-Secorún M, Montaña-Cortés R, Hidalgo-García C, Rodríguez-Sanz J, Corral-De-toro J, Monti-Ballano S, et al. Effectiveness of conservative treatment according to severity and systemic disease in carpal tunnel syndrome: A systematic review. *Int J Environ Res Public Health*. 2021;18(5):1-34. [PubMed] DOI: [10.3390/ijerph18052365](https://doi.org/10.3390/ijerph18052365)
29. Andayani NLN, Wibawa A, Nugraha MHS. Effective ultrasound and neural mobilization combinations in reducing hand disabilities in carpal tunnel syndrome patients. *J Keperawatan Indones*. 2020;23(2):93-101. DOI: [10.7454/jki.v23i2.988](https://doi.org/10.7454/jki.v23i2.988)
30. Ahmed OF, Elkhartbotly AM, Taha N, Bekheet AB. Treatment of mild to moderate carpal tunnel syndrome in patients with diabetic neuropathy using low level laser therapy versus ultrasound controlled comparative study. *BBA Clin*. 2017;8(April):43-7. [PubMed] DOI: [10.1016/j.bbact.2017.07.001](https://doi.org/10.1016/j.bbact.2017.07.001)
31. Hidayati HB, Machfoed MH, Kuntoro K, Soetojo S, Santoso B, Suroto S, et al. Bekam Sebagai Terapi Alternatif Untuk Nyeri. *Maj Kedokt Neurosains Perhimpun Dr Spes Saraf Indones*. 2019;36(2):148-56. [FreeFullText]
32. Hidayati HB, Pranata CA. Pathogenesis and management of pain in amyotrophic lateral sclerosis. *Anaesth Pain Intensive Care*. 2021;25(2):236-43. DOI: [10.35975/apic.v25i2.1478](https://doi.org/10.35975/apic.v25i2.1478)
33. Hidayati H, Kustriyani A. Paracetamol, migraine, and medication overuse headache (Moh). *J Pain Vertigo Headache*. 2020;1(2):42-7. DOI: [10.21776/ub.jphv.2020.001.02.5](https://doi.org/10.21776/ub.jphv.2020.001.02.5)
34. Perhimpunan Dokter Spesialis Saraf Indonesia. Panduan Praktik Klinis Neurologi. Perdossi. 2016;154-6. [FreeFullText]

35. Franklin GM, Friedman AS. Work-related carpal tunnel syndrome: diagnosis and treatment guideline. *Phys Med Rehabil Clin N Am*. 2017;26(3):523–37. [PubMed] DOI: [10.1016/j.pmr.2015.04.003](https://doi.org/10.1016/j.pmr.2015.04.003)
36. Ilmanita D, Hidayati HB. Tricyclic antidepressants in chronic low back pain: a review. *J Islam Pharm*. 2020;4(2):21. [FreeFullText]
37. Khan F, Shehna A, Ramesh S, Sankaran K, Sandhya, Paul R. Subjective symptoms of carpal tunnel syndrome correlate more with psychological factors than electrophysiological severity. *Ann Indian Acad Neurol*. 2017;20(1):69–72. [PubMed] DOI: [10.4103/0972-2327.199909](https://doi.org/10.4103/0972-2327.199909)
38. Ta S, Wazib A, Rahman S, Fn K. Amitriptyline in the treatment of early carpal tunnel syndrome. *Am J Med Med Sci*. 2021;11(1):12–4. [FreeFullText]
39. Erdemoglu A. The efficacy and safety of gabapentin in carpal tunnel patients: Open label trial. *Neurol India*. 2009;57(3):300–3. [PubMed] DOI: [10.4103/0028-3886.53287](https://doi.org/10.4103/0028-3886.53287)
40. Ahmed AM, Hassan OG, Khalifa AA. Gabapentin as an adjuvant therapy to splinting in carpal tunnel syndrome (CTS): a systematic review and meta-analysis of randomized controlled trials. *Egypt J Neurol Psychiatry Neurosurg*. 2020;56(1). DOI: [10.1186/s41983-020-00237-5](https://doi.org/10.1186/s41983-020-00237-5)
41. Hirakata M, Yoshida S, Tanaka-Mizuno S, Kuwauchi A, Kawakami K. Pregabalin prescription for neuropathic pain and fibromyalgia: a descriptive study using administrative database in Japan. *Pain Res Manag*. 2018;2018:2786151. [PubMed] DOI: [10.1155/2018/2786151](https://doi.org/10.1155/2018/2786151)
42. Babaei-Ghazani A, Forogh B, Raissi GR, Ahadi T, Eftekharsadat B, Yousefi N, et al. Ultrasound-guided corticosteroid injection in carpal tunnel syndrome: Comparison between radial and ulnar approaches. *J Pain Res*. 2020;13:1569–78. [PubMed] DOI: [10.2147/JPR.S248600](https://doi.org/10.2147/JPR.S248600)
43. Hidayati HB, Setianti AR, Badriyahhidayati H. Effectiveness of triamcinolone and lidocaine in patient with piniformis syndrome—a case series. *Pharm J Indones*. 2019;5(1):31–5. [FreeFullText]
44. Vij N, Traube B, Bisht R, Singleton I, Cornett EM, Kaye AD, et al. An update on treatment modalities for ulnar nerve entrapment: A literature review. *Anesthesiol Pain Med*. 2020;10(6):1–7. [PubMed] DOI: [10.5812/aapm.112070](https://doi.org/10.5812/aapm.112070)
45. Yang FA, Shih YC, Hong JP, Wu CW, Liao CD, Chen HC. Ultrasound-guided corticosteroid injection for patients with carpal tunnel syndrome: a systematic review and meta-analysis of randomized controlled trials. *Sci Rep*. 2021 May 17;11(1):10417. [PubMed] DOI: [10.1038/s41598-021-89898-7](https://doi.org/10.1038/s41598-021-89898-7)
46. Rifat Yasmin HH, Abidi STF, Shah SAA, Kazmi TH, Hussain H. Knowledge and practice of infection prevention and control among healthcare workers: A COVID-19 pandemic experience. *Anaesth Pain Intensive Care*. 2020;24(6):596–602. DOI: [10.35975/apic.v24i6.1408](https://doi.org/10.35975/apic.v24i6.1408)
47. Wang H, Zhu Y, Wei H, Dong C. Ultrasound-guided local corticosteroid injection for carpal tunnel syndrome: A meta-analysis of randomized controlled trials. *Clin Rehabil*. 2021 Nov;35(11):1506–1517. [PubMed] DOI: [10.1177/02692155211014702](https://doi.org/10.1177/02692155211014702)
48. Chesterton LS, Blagojevic-Bucknall M, Burton C, Dziedzic KS, Davenport G, Jowett SM, et al. The clinical and cost-effectiveness of corticosteroid injection versus night splints for carpal tunnel syndrome (INSTINCTS trial): an open-label, parallel group, randomised controlled trial. *Lancet*. 2018;392(10156):1423–33. [PubMed] DOI: [10.1016/S0140-6736\(18\)31572-1](https://doi.org/10.1016/S0140-6736(18)31572-1)
49. Lin MT, Liu IC, Syu WT, Kuo PL, Wu CH. Effect of perineural injection with different dextrose volumes on median nerve size, elasticity and mobility in hands with carpal tunnel syndrome. *Diagnostics*. 2021;11(5):849. [PubMed] DOI: [10.3390/diagnostics11050849](https://doi.org/10.3390/diagnostics11050849)
50. Shen YP, Li TY, Chou YC, Chen LC, Wu YT. Outcome predictors of platelet-rich plasma injection for moderate carpal tunnel syndrome. *Int J Clin Pract*. 2021 Oct;75(10):e14482. [PubMed] DOI: [10.1111/ijcp.14482](https://doi.org/10.1111/ijcp.14482)
51. Savage NJ, Albano J. Marrying tendon and nerve gliding exercises with hydrodissection following injection for carpal tunnel syndrome - a new treatment approach? *J Orthop Case Rep*. 2020 Dec;10(9):38-46. [PubMed] DOI: [10.13107/jocr.2020.v10.i09.1896](https://doi.org/10.13107/jocr.2020.v10.i09.1896)
52. Thakur M, Genova A, Dix O, Saefan A. Indications, surgical techniques and safety of open versus endoscopic carpal tunnel release. *EC Orthopedics*. 2020;(October).
53. Colakoglu S, Tũaño K, Newhoff D, Rodriguez-Fontan F, Nadeau J, Siddikoglu D, et al. Ulnar two-point discrimination following endoscopic carpal tunnel release. *Medicina (B Aires)*. 2021;81(3):318-322. [PubMed]
54. Orhurhu V, Orman S, Peck J, Urits I, Orhurhu MS, Jones MR, et al. Carpal tunnel release surgery- a systematic review of open and endoscopic approaches. *Anesthesiol Pain Med*. 2020;10(6):e112291. [PubMed] DOI: [10.5812/aapm.112291](https://doi.org/10.5812/aapm.112291)
55. Chen Z, Liu J, Yuan TB, Cai DW, Wang XX, Qin J. Comparison of clinical outcomes between open and modified endoscopic release for carpal tunnel syndrome. *Exp Ther Med*. 2021 Aug;22(2):861. [PubMed] DOI: [10.3892/etm.2021.10293](https://doi.org/10.3892/etm.2021.10293)
56. Mujadzic T, Friedman HI, Mujadzic MM, Gober C, Chen E, Atwez A, et al. Modified carpal tunnel release: a new approach to minimizing pillar pain. *Ann Plast Surg*. 2021 Jun 1;86(6S Suppl 5):S503-S509. [PubMed] DOI: [10.1097/SAP.0000000000002885](https://doi.org/10.1097/SAP.0000000000002885)
57. Djaali W, Simadibrata CL, Nareswari I, Helianthi DR, Abdurrohm K. The role of acupuncture therapy in carpal tunnel syndrome. *Neurona*. 2019;37(1). DOI: [10.52386/neurona.v37i1.103](https://doi.org/10.52386/neurona.v37i1.103)
58. Salehi S, Hesami O, Esehani MP, Khosravi S, Rashed A, Haghghatizadeh M, et al. The effectiveness of exercise therapy and dry needling on wrist range of motion, pinch and grip force in carpal tunnel syndrome: A randomized clinical trial. *Asian J Sports Med*. 2019;10(4). DOI: [10.5812/asjasm.83927](https://doi.org/10.5812/asjasm.83927)
59. Subadi I, Kusumawardani MK, Qonb MF, Susilo I, Hidayati HB. Wet cupping therapy improves mu opioid receptor expression and pain threshold in animal models of inflammation. *Anaesth Pain Intensive Care*. 2019;23(4):348–52. DOI: [10.35975/apic.v23i4.1166](https://doi.org/10.35975/apic.v23i4.1166)
60. Farhat A, Mughal SM. Is there a role of cupping therapy in the treatment of carpal tunnel syndrome in primary care setting? *Cureus*. 2021;13(1):e12954. [PubMed] DOI: [10.7759/cureus.12954](https://doi.org/10.7759/cureus.12954)
61. Mohammadi S, Roostayi MM, Naimi SS, Baghban AA. The effects of cupping therapy as a new approach in the

Hidayati HB, et al

carpal tunnel syndrome

- physiotherapeutic management of carpal tunnel syndrome. *Physiother Res Int* 2019;24(3):e1770. [PubMed] DOI: [10.1002/pri.1770](https://doi.org/10.1002/pri.1770)
62. Hidayati HB, Oktavianti A. Dry needling as a therapy of cervical miofascial pain. *Neurona* 2020;37(4):280–8. DOI: [10.52386/neurona.v37i4.177](https://doi.org/10.52386/neurona.v37i4.177)
63. Dunning J, Butts R, Mourad F, Young I, Flannagan S, Perreault T. Dry needling: a literature review with implications for clinical practice guidelines. *Phys Ther Rev* 2014;19(4):252–65. [PubMed] DOI: [10.1179/108331913X13844245102034](https://doi.org/10.1179/108331913X13844245102034)
64. Bubnov R, Kalika L. Treatment of hand pain and carpal tunnel syndrome using precise dry needling under ultrasound guidance - relevance of treatment of hand pain and carpal tunnel syndrome using precise dry needling under ultrasound guidance - relevance of supinator syndrome. *ISPRM 2018* 2018,(July). [FreeFullText]
65. Collin A, Vein J, Wittrant Y, Pereira B, Amode R, Guillet C, et al. A new clinically-relevant rat model of letrozole-induced chronic nociceptive disorders. *Toxicol Appl Pharmacol* 2021;425:115600. [PubMed] DOI: [10.1016/j.taap.2021.115600](https://doi.org/10.1016/j.taap.2021.115600)
66. Zarrin M, Saadat M, Jafar M, Yazdi S, Ahmadi DS. Efficacy of cervical manual therapy plus conventional physical therapy on clinical outcomes in patients with carpal tunnel syndrome: a double blind randomized controlled trial. *Int J Clin Pr* 2021.
67. Salawati L. Carpal tunnel syndrome. *J Kedokt Syiah Kuala* 2014;14(1):29–37. [FreeFullText]